

Giant lipoma of hand . Case report

ABSTRACT

Lipomas are very common benign tumors which are preferentially located in the neck and trunk, however other locations which are rare but can exist such as the hand and its commissures .

We report one case of a massif lipoma of the first commissural that progressed for 10 years of a 61 year-old woman.

In spite of the size of the tumor and its extensions to others interosseous spaces no nerve compression sign was reported by the patient.

We signal the interest of MRI that allow us to define limits of the mass and to ease the surgical treatment.

The mass was resected in a bloc without any lesions of vessels, nerves or tendons.

Post operative period was uneventful. And the patient had excellent hand and fingers function after a few days of gentle mobilization exercises .

Keywords: Lipoma , Hand , Commissure , surgery , MRI

1. INTRODUCTION

Lipoma is a benign tumor of mesenchymal origin composed of fat cells.

They are very common, since they represent almost 50% of all soft tissue tumors. Superficial lipomas are most often located on the back, shoulders, neck and abdomen, followed by the arms and thighs.

Other locations are unusual but we can find them like the hand and its commissures which only represent 1 to 3.8% of its benign tumors.

We report a case of massive dorsopalmar thenar lipoma invading the entire palm of the hand without clinical signs of neurovascular compression.

2. CASE PRESENTATION

We report the case of A 61-year-old patient who has had large asymptomatic swelling of the thenar space for more than 10 years.

The clinical examination showed a subcutaneous tumor measuring approximately 7 cm in length x 8 cm in width, thus spreading the 1st commissure and making opposition of the thumb very limited or even impossible. (Fig. 1)

This mass of soft consistency, without inflammatory signs and not painful, appears poorly limited, giving tumor extensions of smaller sizes to the palm of the hand next to the 3rd and 4th interosseous spaces.

The patient reports no sensory deficit and the Local neurological examination is normal. X-ray shows the appearance of a tissue image without bone lesions (Fig 2)

The MRI highlights a voluminous tissue formation in T1, T2 hypersignal, well limited, it is developed in the subcutaneous fat of the 1st corner, insinuates itself in front of the last three metacarpals and encompasses the deep and superficial flexor tendons. (Fig 3)

The surgical intervention was carried out under locoregional anesthesia, and under a pneumatic tourniquet at the root of the limb, the approach provided satisfactory exposure over the entire palm of the hand and made it possible to highlight a lipomatous mass. , encapsulated, repressing the vascular-nervous pedicles of the long fingers without invading them and remaining in front of the flexor tendons.(Fig 4)

The tumor was carefully dissected, which made it possible to remove it all (Fig 5) without damaging the noble elements

Complete recovery was achieved after 06 months without any sign of recurrence.(Fig 6)

3. DISCUSSION

Lipomas are benign tumors that are commonly located in the limbs (11.5% to 27% in the upper limbs), its localization in the hand is rare, occurring in 5% of cases [1] .

Hand tumors encompass a variety of pathologies, including cysts, fibromas, schwannomas, neurofibromas, and even malignant neoplasms, which are more common than lipomas, making differential diagnosis crucial.[1]

A lipoma of the fingers or the dorsal aspect of the hand presents as a soft, sometimes lobulated lesion that typically does not affect function [2] .

Palmary lipomas, which are more common, can be either superficial and subcutaneous or deep, beneath the aponeurosis, forming a voluminous, arborizing mass that insinuates between the septa of the hand. They rarely cause signs of nerve compression.

Depending on its location, a palmary lipoma can cause compression of the interosseous nerve in the forearm[4], carpal tunnel syndrome [3], compression of the ulnar nerve in Guyon's canal [5,6], or compression of digital nerves [7], and may even compress the intrinsic muscles of the hand, leading to trigger fingers [8].

This condition must be carefully distinguished from idiopathic bilateral nerve compression, which is typically of neurological origin.

In our case, despite the size of the tumor and the mass effect it could have on the various neurovascular pedicles of the hand, no signs of nerve compression were noted.

X-rays may rarely show bone erosion at the site of contact with the lipoma.

It's a crucial radiological test to begin with to make the difference with osteolipoma to not make the confusion with more serious conditions with a poor prognosis such as malignancy, in addition to the symptoms that can compromise the patient's quality of life due to the compressive syndrome leading to functional limitation, [11]

MRI is very useful for completing the preoperative assessment in cases of diagnostic uncertainty. Due to its high sensitivity, MRI can reveal a lobulated mass with septa, showing hyperintensity on T1-weighted images and isointensity on T2-weighted sequences. It also helps assess the dimensions, relationships, and boundaries of the mass and guides us in determining whether the tumor is benign or malignant

MRI plays a big role to guide the surgical treatment , it allows us to make the differential diagnosis for guiding surgical resection and preserving critical structures.

Surgical treatment of an asymptomatic lipoma is not necessarily imperative if the diagnosis is not regularly made during preoperative assessment. However, only histological examination can rule out a liposarcoma, which remains exceptionally rare before age 40 and should be considered in the presence of rapid tumor growth and neurological signs, as well as other more common benign tumors of the hand, such as synovial cysts or giant cell tumors.

lipomas larger than 5 centimeters, classified as giant lipomas, require surgical excision due to the risk of sarcomatous transformation.[10]

Recurrence is rare and usually results from incomplete initial excision.

This case report is particularly significant due to the extreme rarity of the condition, especially given its unusual location

4. CONCLUSION

Lipomas of the hand are rare benign tumor pathologies. Due to their proximity to vascular and nerve structures, extreme caution should be exercised during surgical dissection. MRI is the most useful exploration, both diagnostically and with a significant impact on treatment. Only histopathological examinations can confirm the histological nature of the lesion.

CONSENT

As per international standards or university standards, patient(s) written consent has been collected and preserved by the author(s).

ETHICAL APPROVAL

I declare on my honor that the ethical approval has been exempted by my establishment.

Disclaimer (Artificial intelligence)

Option 1:

Author(s) hereby declare that NO generative AI technologies such as Large Language Models (ChatGPT, COPILOT, etc) and text-to-image generators have been used during writing or editing of manuscripts.

Option 2:

Author(s) hereby declare that generative AI technologies such as Large Language Models, etc have been used during writing or editing of manuscripts. This explanation will include the name, version, model, and source of the generative AI technology and as well as all input prompts provided to the generative AI technology

Details of the AI usage are given below:

REFERENCES

- [1]. GLICENSTEIN J., OHANA J., LECLERCQ C. -- Lipomes. In : GLICENSTEIN J., OHANA J, LECLERCQ C. : Tumeurs de la main, Berlin, Springer-Verlag, 1988, 78-83.
- [2]. BOGUMILL G.P., SULLIVAN D.J., BAKER G.L -- Tumors of the hand. Clin Orthop, 1975, 108, 214-222.
- [3] Babins DM, Lubahn JD. Palmar lipomas associated with compression of the medial nerve. J Bone Joint Surg 1994;76-A(9):1360-2.
- [4] Higgs PE, Young VL, Schuster R, Weeks PM. Giant lipomas of the hand and forearm. South Med J 1993;86(8):887-90.
- [5] Zahrawi F. Acute compression ulnar neuropathy at Guyon's canal resulting from lipoma. J Hand Surg [Am] 1984;9(2):238-9.
- [6] De Smet L, Bande S, Fabry G. Giant lipoma of the deep palmar space, mimicking persistent carpal tunnel syndrome. Acta Orthop Belg 1994;60 (3):334-5.
- [7] Hoehn JG, Farber HF. Massive lipoma of the palm. Ann Plast Surg 1983;11(5):431-3.
- [8] Brand MG, Gelberman RH. Lipoma of the flexor digitorum superficialis causing triggering at the carpal canal and median nerve compression. J Hand Surg [Am] 1988;13(3):342-4.
- [9] BUTLER E.D., HAMILL J.P., SEIPEL R.S., de LORIMIER A.A. -- Tumors of the hand. A ten-year survey and report of 437 cases. Am JSurg, 1960, 100, 293-302.
- [10] Grivas TB, Psarakis SA, Kaspiris A, Liapi G. Giant lipoma of the chronic-case study and contemporary approach to its aetiopathogenicity. Hand (N Y) 2009;4(2):173-6.
- [11] Panev A, Paneva T, Firoozi B, Petrov SP, Georgiev GP. Giant ossifying lipoma of the hand: case report and review of the literature. Cureus [Internet]. 2024 [cited August 22, 2024];16(4). Available at: <https://pubmed.ncbi.nlm.nih.gov/38715998/>

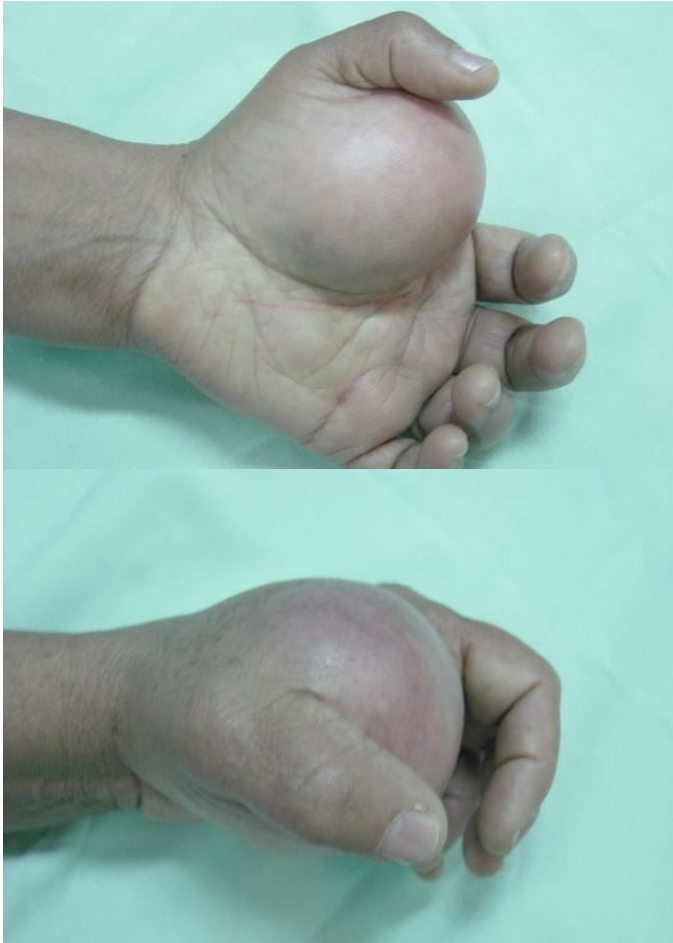

Fig. 1. intraoperative aspect



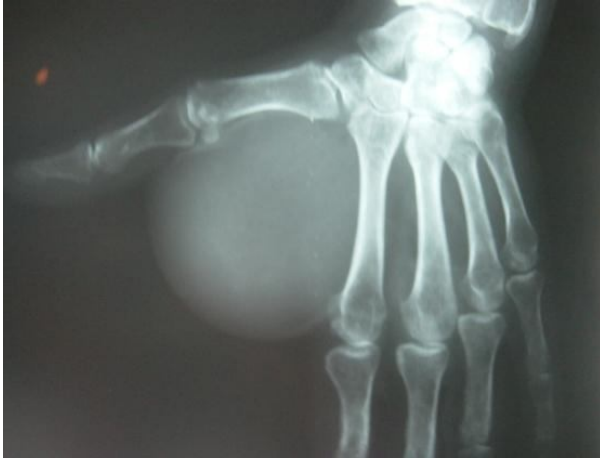


Fig. 2. X-ray : round opacity of the first commissure without bone defect

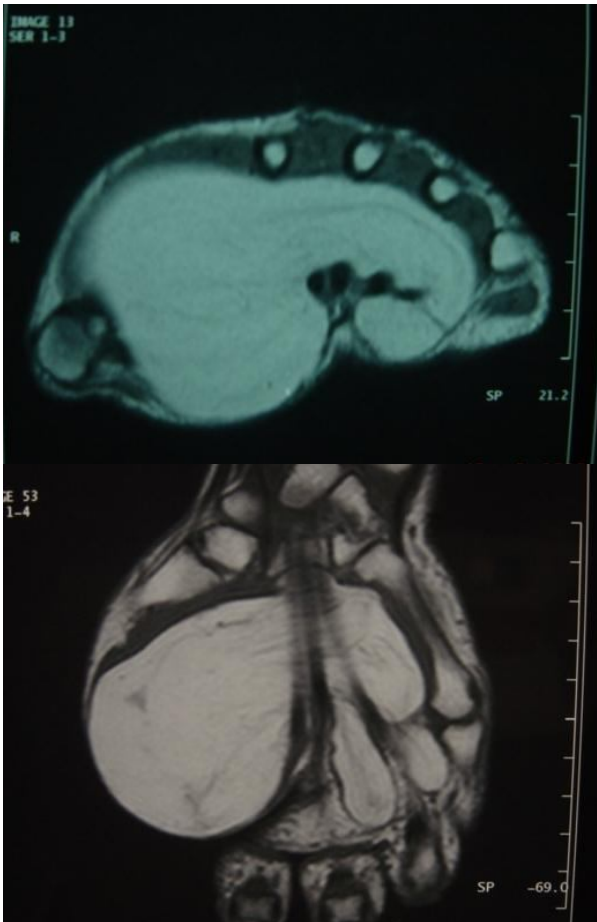


Fig. 3. MRI : typical appearance of a lipoma extending to the entire palm of the hand

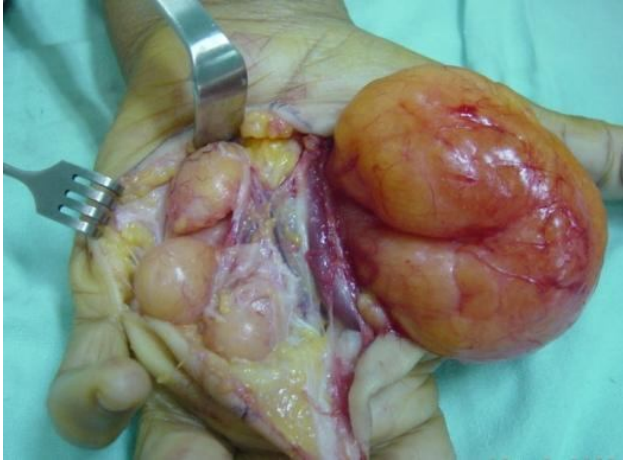


Fig 4 : Intraoperative aspect showing the giant mass and its extensions to the palm

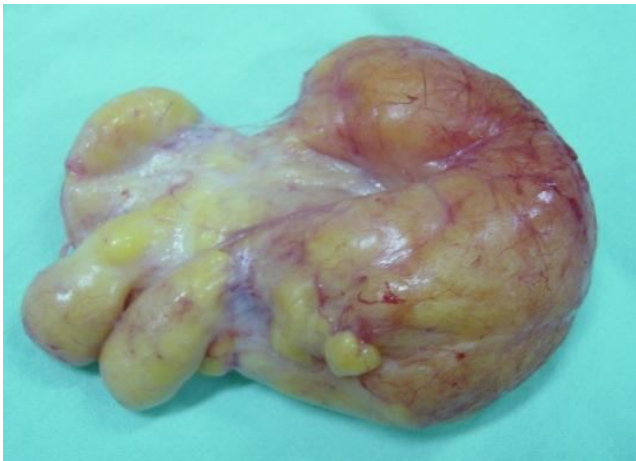

Fig 5 : surgical piece all removed

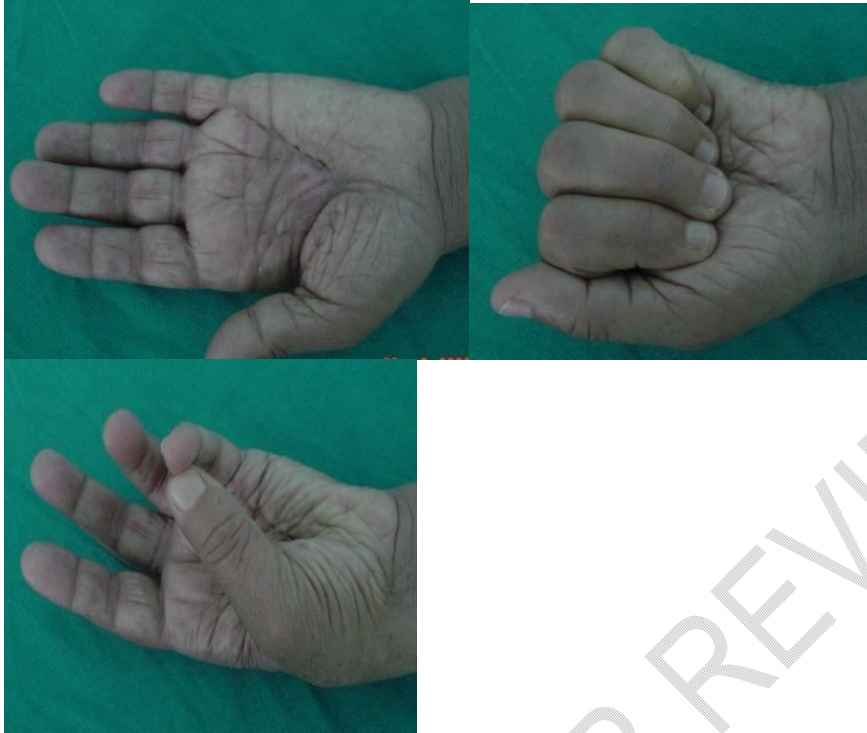

Fig 6 : post operative result

UNDER PEER REVIEW