

## Case reports

# Primary hyperaldosteronism revealed by torsade de pointes: CASE REPORT.

---

### ABSTRACT

**Introduction:**

Primary hyperaldosteronism is a disorder characterised by the excessive production of aldosterone by the adrenal glands. It typically presents as elevated blood pressure and low blood potassium levels. However, the clinical manifestation can be significantly detrimental when metabolic disorders and hypertension result in severe arrhythmias.

**Case report:**

This is a report of a case of primary hyperaldosteronism in a 37-year-old male who was admitted to hospital with syncope, palpitations and dyspnoea. A clinical examination of the patient revealed an unstable condition with tachycardia (180 beats per minute). An electrocardiogram showed evidence of torsade de pointes, which necessitated defibrillation and a return to sinus rhythm. Transthoracic echocardiography demonstrated evidence of ventriculo atrial remodelling and diastolic dysfunction.

**Conclusion:**

Therefore, when faced with life-threatening arrhythmias, it is imperative to induce primary hyperaldosteronism in the context of etiological research, especially when hypokalemia and hypertension exist.

*Keywords: Primary hyperaldosteronism, torsade de pointes, case report.*

## 1. INTRODUCTION

The prevalence of secondary hypertension is estimated to be approximately 33% (42% in women and 27% in men), with primary hyperaldosteronism identified as the primary underlying cause (11.5%).(1)

This condition is typified by diminished plasma renin levels in conjunction with an overactive autonomous aldosterone production, which results in hypokalemia in conjunction with hypertension.

The observation of a haemoglobin level of less than 3.7 mmol/l in a patient with hypertension should prompt consideration of the possibility of hyperaldosteronism.

It is possible that elevated aldosterone levels associated with hypokalemia may be responsible for cardiovascular complications independent of arterial hypertension, such as coronary heart disease, myocardial infarction, stroke, and severe arrhythmias.

In this case study, we present a rare instance of torsade de pointes, which revealed primary aldosteronism in a 34-year-old male with hypertension.

This case emphasises the necessity of investigating primary hyperaldosteronism in all instances of hypertension in young subjects, and/or severe arrhythmias in the context of hypokalemia.

## 2. CASE REPORT

This case study presents the case of a 37-year-old male patient who was under observation for paroxysmal atrial fibrillation and was treated with amiodarone for a period of one year. The patient did not present with any other significant medical history. The patient was admitted to the emergency department for a single episode of syncope, which was associated with a sensation of palpitation and dyspnea, two days prior to admission. No other associated symptoms were reported.

The physical examination revealed that the patient was conscious and stable in terms of hemodynamic and respiratory parameters. During the examination, the patient experienced another episode of syncope with tachycardia at 180 beats per minute and blood pressure of 80/60 mmHg, without evidence of heart failure.

The emergency electrocardiogram revealed the presence of torsade de pointes at a rate of 180 beats per minute (Figure 1).

This was successfully defibrillated, resulting in the restoration of a regular sinus rhythm at 60 beats per minute. However, a notable prolongation of the QT interval was observed, reaching 630 milliseconds (Figure 2).

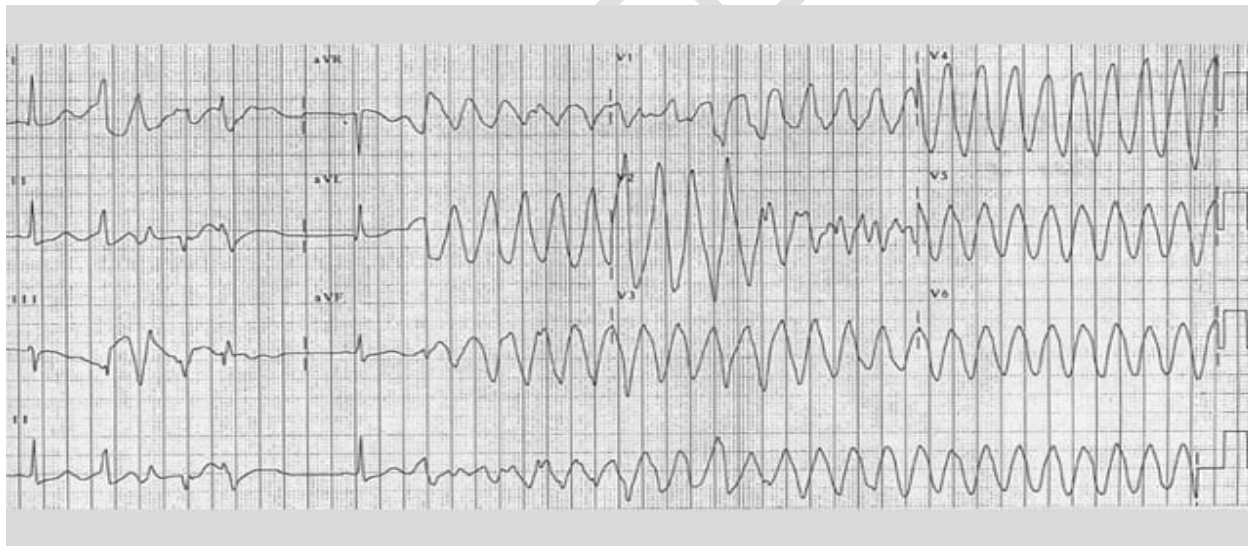


Figure 1: The electrocardiogram (ECG) displays the characteristic appearance of torsade de pointes.

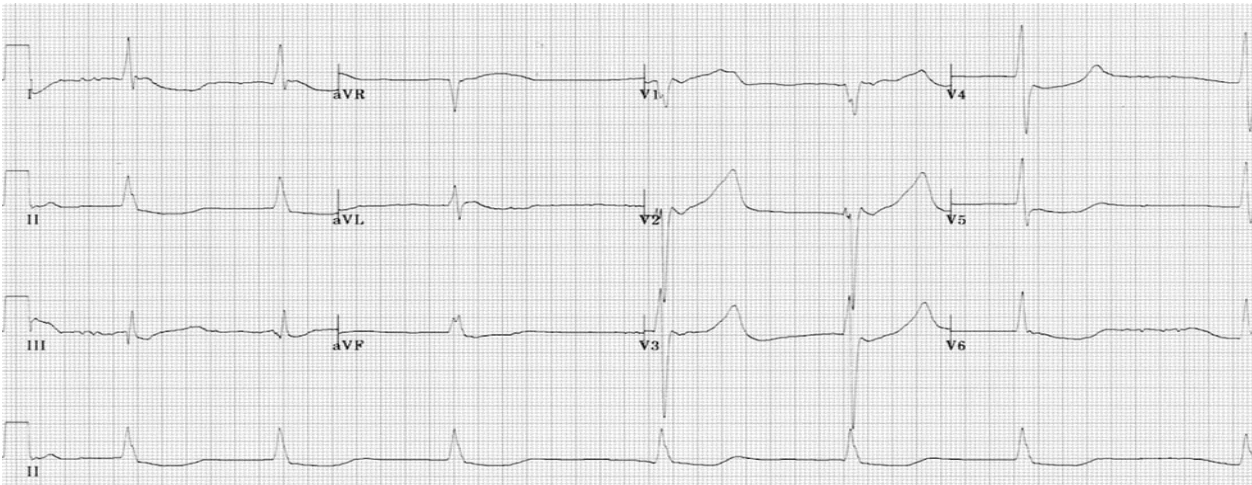


Figure 2: The electrocardiogram (ECG) demonstrates a return to sinus rhythm, accompanied by a prolonged QT interval and a prominent T wave.

Echocardiography revealed the presence of left ventricular remodelling, with a Simpson biplane FEVG value of 55%, minimal mitral leakage, left atrial dilation and a restrictive mitral profile (Figure 3).

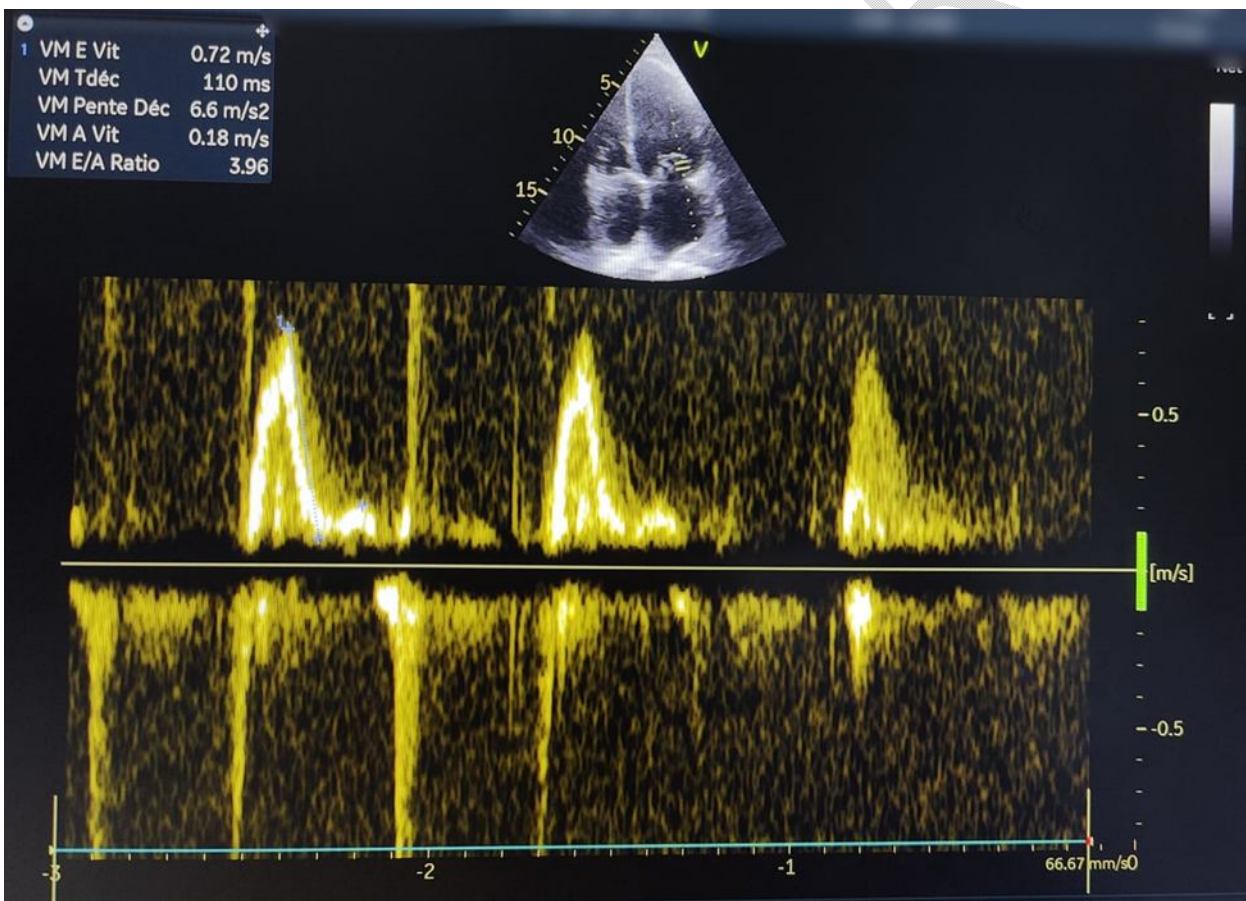


Figure 3: Restrictive mitral profile.

Biological analysis revealed severe hypokalemia (1.9 mEq/L) and hypomagnesaemia (20 mg/L).

An emergency central venous catheter was placed with the objective of correcting the hypokalemia and magnesium deficiency.

The patient's biological evolution has been marked by the correction of potassium and magnesium levels.

A control ECG conducted one week later demonstrated a QTc interval of 402 ms, with no recurrence of arrhythmia (Figure 4).

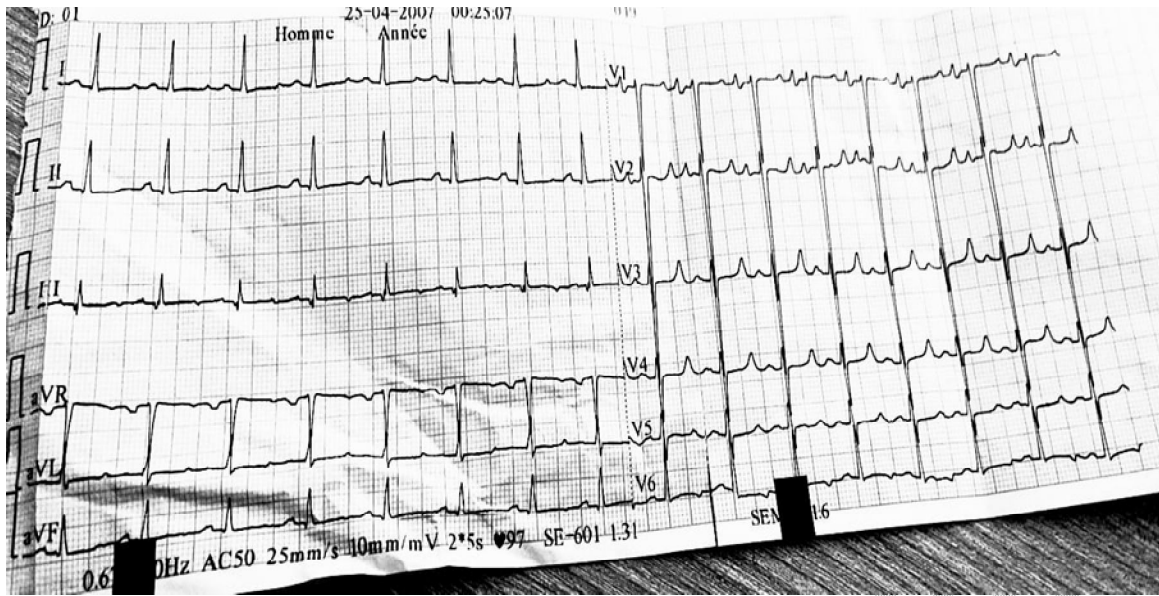


Figure 4: The electrocardiogram (ECG) demonstrates a return to sinus rhythm with an appropriate QT interval.

In order to ascertain the underlying cause of the hypokalemia, an abdominal CT scan was conducted, focusing on a low-signal area of 30 mm x 21 mm at the level of the left adrenal gland.

The biological assessment corroborated the diagnosis of left secretory adrenal adenoma (Conn syndrome), as evidenced by the torsades de pointes. Subsequent to the confirmation of the diagnosis, the patient was transferred to the surgical department for adrenalectomy. It is noteworthy that the amiodarone was also discontinued.

### 3. DISCUSSION

Primary hyperaldosteronism represents the primary etiological factor in endocrine hypertension. (1) The prevalence of primary hyperaldosteronism is variable, with a reported range of 6 to 20% in hypertensive individuals and up to 1 to 30% in expert centers. (3)

The disease known as primary hyperaldosteronism is clinically characterised by hypertension and hypokalemia, in addition to autonomous production of aldosterone by the adrenal cortex. This autonomous production is ensured by unilateral adenoma, Conn's syndrome, or bilateral adrenal hyperplasia. Circulating aldosterone levels above the reference range are associated with increased risk of adverse cardiovascular events, including coronary heart disease, ischaemic stroke, atrial fibrillation, and heart failure [4, 3] → (4, 3)

The proposed mechanism for torsades de pointes involves the inhibition of the delayed rectifier potassium current. This results in an accumulation of positive ions at the cell membrane, which prolongs the repolarisation phase. Should an ectopic beat be generated during this prolonged repolarisation phase, which is known as the R-on-T phenomenon, this can result in torsades de pointes. Both congenital and drug-induced QT prolongation affect the cell membrane in a similar manner, namely by blocking the potassium channel. Torsades de pointes is distinguished from ventricular fibrillation in that it can resolve spontaneously. However, if left untreated, torsades de pointes can eventually progress to ventricular fibrillation. (7)

The majority of cases of acquired QTc prolongation are caused by pharmaceutical agents, including amiodarone. (8)

A diagnosis of hypokalaemia was made in more than 11% of patients, and this was associated with a significantly longer QTc interval (mean 423.5 +/- 40 ms vs 408.5 +/- 31 ms). (9)

Atrial fibrillation is a common presenting feature in patients with primary hyperaldosteronism [5, 6] → (5, 6)

The resulting structural and electrophysiological changes are the underlying causes of LV diastolic and systolic dysfunction and sometimes fatal arrhythmias.

Severe ventricular arrhythmias are exceedingly uncommon, with only a handful of isolated cases of ventricular fibrillation and torsade de pointes documented in the medical literature.

The left ventricular (LV) remodelling observed in patients with acute pancreatitis (AP) is characterised by hypertrophy, increased LV mass, and cardiac fibrosis, with increased volume predominantly in the left atrium.

This remodelling is responsible for diastolic dysfunction, as evidenced by a restrictive mitral profile on echocardiographic examination. This profile is characterised by elevated E/A and E/E' ratios. These findings are corroborated by the existing literature, which documents elevated E/A and E/E' ratios in similar patient groups. These findings are consistent with

those observed in our patient, who presented with ventricular remodelling with a relative wall thickness of 0.46, left atrial dilatation with a left atrial volume of 50 ml/m<sup>2</sup>, and a restrictive mitral profile with an E/A of 3.96 and an E/E' of 11 (Figure 3).

In cases of unilateral involvement, surgical removal of the adenoma is the recommended course of action; in cases of bilateral involvement, medical treatment with mineralocorticoid antagonists is the preferred approach.

Curative treatment has the potential to improve or even reverse myocardial remodelling, as well as to lower or normalise blood pressure and echocardiographic parameters of diastolic dysfunction.

In opposition to medical treatment with aldosterone antagonists, excision also mitigates the probability of atrial fibrillation

[2; 5] → (2, 5)

#### 4. CONCLUSION

It can be concluded that primary hyperaldosteronism, which is often a cause of secondary hypertension, should be investigated in all cases of severe arrhythmia associated with hypertension in young patients, particularly when there is a concurrent hypokalemia. The diagnosis is based on a combination of hormonal tests and imaging in an evocative context. In cases of unilateral involvement, the surgical management option is adrenalectomy.

#### Disclaimer (Artificial intelligence)

Option 1:

Author(s) hereby declare that NO generative AI technologies such as Large Language Models (ChatGPT, COPILOT, etc) and text-to-image generators have been used during writing or editing of manuscripts.

Option 2:

Author(s) hereby declare that generative AI technologies such as Large Language Models, etc have been used during writing or editing of manuscripts. This explanation will include the name, version, model, and source of the generative AI technology and as well as all input prompts provided to the generative AI technology

Details of the AI usage are given below:

- 1.
- 2.
- 3.

**DECLARATIONS:****CONSENT FOR PUBLICATION:**

Written informed consent was obtained from the patients for publication of this case report and any accompanying images.

**AVAILABILITY OF DATA AND MATERIAL :**

All data generated or analysed during this study are included in this published article.

**COMPETING INTERESTS:**

The authors declare that they have no competing interests.

**REFERENCES**

1. Noilhan C, Barigou M, Bieler L, Amar J, Chamontin B, Bouhanick B. Causes of secondary hypertension in the young population: A monocentric study. *Ann Cardiol Angeiol (Paris)*. 2016 Jun;65(3):159-64. doi: 10.1016/j.ancard.2016.04.016. Epub 2016 May 18. PMID: 27209493.
2. MANCIA, Giuseppe, KREUTZ, Reinhold, BRUNSTRÖ M, Mattias, et al. 2023 ESH Guidelines for the management of arterial hypertension The Task Force for the management of arterial hypertension of the European Society of Hypertension Endorsed by the European Renal Association (ERA) and the International Society of Hypertension (ISH). *Journal of Hypertension*, p. 10.1097.
3. MILLIEZ, Paul, GIRERD, Xavier, PLOUIN, Pierre-François, et al. Evidence for an increased rate of cardiovascular events in patients with primary aldosteronism. *Journal of the American College of Cardiology*, 2005, vol. 45, no 8, p. 1243-1248.
4. Hundemer GL, Curhan GC, Yozamp N, Wang M, Vaidya A. Incidence of Atrial Fibrillation and Mineralocorticoid Receptor Activity in Patients With Medically and Surgically Treated Primary Aldosteronism. *JAMA Cardiology*. 2018 Aug 1;3(8):768–74.
5. Chang Y, Liao C, Tsai C, Chen C, Pan C, Chen Z, et al. Left Ventricular Dysfunction in Patients With Primary Aldosteronism: A Propensity Score–Matching Follow-Up Study With Tissue Doppler Imaging. *Journal of the American Heart Association*. 2019 Nov 19;8(22): 013263.
6. Al-Hashedi EM, Zhao X, Mohammed AA, Juvenal H, Yu J. Serum aldosterone effect on left ventricular structure and diastolic function in essential hypertension. *The Journal of Clinical Hypertension*. 2023;25(2):213–22.
7. Baldzizhar A, Manuylova E, Marchenko R, Kryvalap Y, Carey MG. Ventricular Tachycardias: Characteristics and Management. *Crit Care Nurs Clin North Am*. 2016 Sep;28(3):317-29.
8. Tisdale JE. Drug-induced QT interval prolongation and torsades de pointes: Role of the pharmacist in risk assessment, prevention, and management. *Can Pharm J (Ott)* 2016;149(3):139–152.
9. Trojak B, Astruc K, Pinoit JM, Chauvet-Gelinier JC, Ponavoy E, Bonin B, Gisselmann A. Hypokalemia is associated with lengthening of QT interval in psychiatric patients on admission. *Psychiatry Res*. 2009 Oct 30;169(3):257-60. doi: 10.1016/j.psychres.2008.06.031. Epub 2009 Sep 10. PMID: 19747736.