

Case report

Strongyloides Hyperinfection Syndrome and severe malnutrition in an immunocompetent patient.

ABSTRACT

Aims: Strongyloides Hyperinfection Syndrome (SHS) and disseminated *Strongyloidiasis* have been extensively reported in immunocompromised patients. In SHS, large parasitic loads of larvae cause symptoms mainly limited to the gastrointestinal tract and lung, whereas in the disseminated form multiple organs can be affected with high mortality if inappropriately treated.

Case presentation: Here we present an unusual case of a 28-year-old (HIV negative) patient with confirmed untreated *Helicobacter pylori*, symptoms of gastric and pulmonary hyperinfection complicated with severe weight loss, respiratory symptoms with hemoptysis and refeeding syndrome.

Discussion: The diagnosis was based on histological confirmation of the parasite in the gastric mucosal biopsy and stool analysis. The patient was successfully treated with ivermectin and discharged in reasonable medical conditions.

Conclusion: This case illustrates the importance of considering Strongyloides Hyperinfection in immunocompetent patients presenting with chronic vomiting, weight loss and anemia, especially in developmental countries.

Keywords: *Strongyloidiasis, Strongyloides hyperinfection syndrome, albendazole and Ivermectin.*

Comment [Ma1]: Keywords : Strongyloidiasis, Strongyloides hyperinfection syndrome, symptoms of gastric and pulmonary hyperinfection complicated, ivermectin, immunocompetent patients

INTRODUCTION

Strongyloidiasis is a WHO neglected disease caused by infection with the nematode (roundworm) *Strongyloides stercoralis* which are present in soil or (less frequently) by means of oral-fecal contamination. After penetration of the cutaneous tissue, the larvae will first migrate through the venous circulation to the respiratory system. Subsequently, mediated by swallowing of infected respiratory secretions, the larvae will gain access to the gastro-intestinal tract. Once in the small intestines, parasite maturation and egg laying in the intestinal mucosa will occur. This parasite has the unique feature to cause chronic infection described in the literature as the "autoinfection cycle". This cycle allows for chronic infection as rhabditiform larvae in the large intestine develop into filariform larvae which are capable of intestinal mucosal penetration (before being excreted in the stool), by which the cycle is repeated [1–3] (Figure 1).

Comment [Ma2]: References

Comment [Ma3]: References

Symptoms will vary according to the type of organ being infected, parasite load and host immune status. During primary infection, effector cells of the innate immune system (granulocytes and macrophages) are capable of killing the migrating larvae. In addition, the adaptive immune response mediated by T-Cells are important in the prevention of disease progression to SHS [4]. Traditional risk factors for the SHS and disseminated disease are alcoholism, Human Immunodeficiency Virus (HIV) or Human T-Cell Lymphotropic Virus-1 (HTLV-1) infection, malnutrition, immunosuppressive agents (e.g. corticosteroids) and transplant patients [4]. *Strongyloides* hyperinfection or disseminated disease has rarely been reported in immunocompetent patients[5]. Here we present a unique case of a young immunocompetent patient with untreated *Helicobacter pylori* who developed aSHS.

CASE PRESENTATION

A 28-year-old male patient was seen in the emergency department of our clinic with symptoms of chronic vomiting and associated weight loss (approximately 10 kg in the last 3 months). His medical history revealed chronic gastritis due to *Helicobacter pylori*, diagnosed two years earlier, for which he never received treatment. The patient was admitted to the clinic for further investigations. An upper gastrointestinal endoscopy was performed which showed edematous gastric folds and duodenitis. Gastric and duodenal mucosal biopsies showed massive infiltration of *Strongyloides* (**Figure 2**), no signs of malignancy. A colonoscopy was performed which showed internal hemorrhoids without other abnormalities. On admission his laboratories showed a slight normocytic anemia (Hemoglobin 13.0 mg/dl), with normal serum ferritin (117 ng/mL), but low transferrin (35g/L). The patient did not have eosinophilia and an HIV test was negative. Stool analysis showed rhabditiform larvae compatible with *Strongyloides stercoralis*. A tomography of the thorax and abdomen showed bilateral atelectasis, hepatomegaly, dilatation of the extra hepatic tract and the common pancreatic duct respectively. The patient was started initially by the treating physician on albendazole 200mg q12 hours, omeprazole IV, parenteral nutrition and infectious diseases consultation was requested. During hospitalization, the patient showed clinical deterioration with melena, hemoptysis, respiratory distress and altered consciousness.

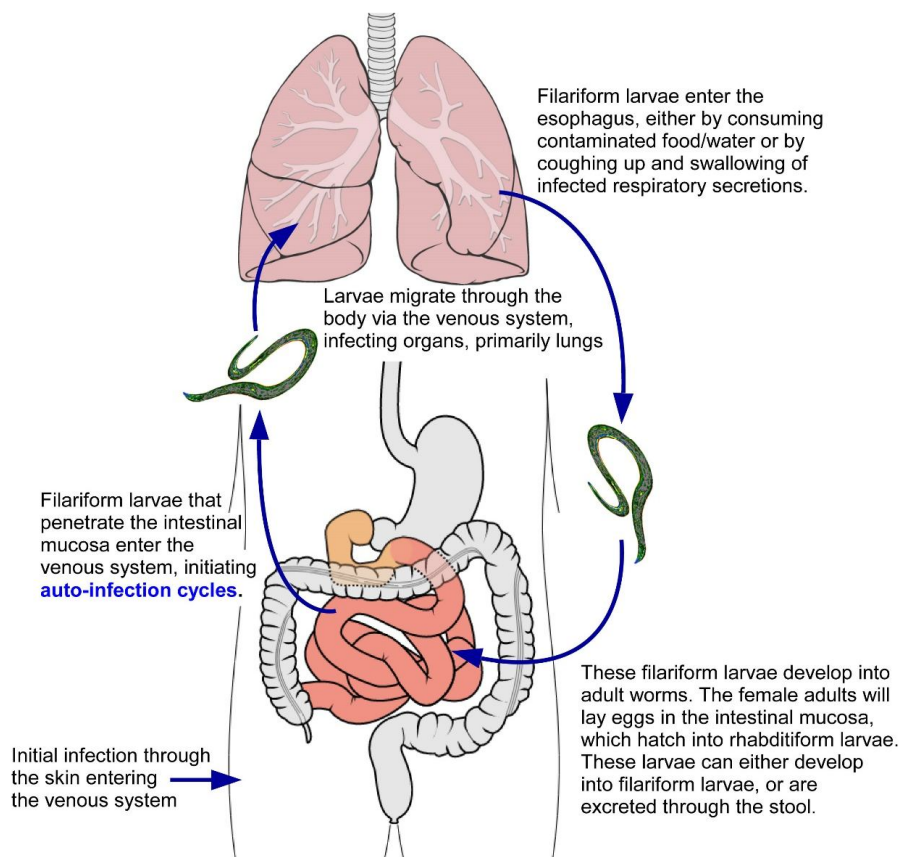


Figure 1: Infection cycle of *StrongyloidesStercoralis*. Filariform larvae can penetrate the skin or large intestinal mucosa and travel through the venous system to the respiratory tract. Infective larvae can enter the digestive tract either via consumption of infected water/food or by up coughing of respiratory secretions. Subsequently, worm maturation in the small intestinal and egg laying in the intestinal mucosa by the female parasite can occur. The young rhabditiform parasites can develop into filariform larvae which are capable of penetration of the (large) intestinal wall (or peri-anal skin) and cause cycles of chronic auto-infection. Alternatively, the rhabditiform larvae can be excreted via the stool.

Comment [Ma4]: Image source ???

Due to a significant decrease in hemoglobin, two units of red blood cells were given. Under the suspicion of SHS, the therapy was switched to ivermectin 200 microgram/kg/day. Pulmonary tuberculosis was ruled out by a PCR performed on sputum. The patient showed symptoms compatible with a refeeding syndrome (altered consciousness, pulmonary edema and severe hyphosphatemia), for which he was admitted to the ICU for electrolyte suppletion and monitoring. The parental feeding was temporary stopped and reinitiated after clinical improvement. A secondary bacteremia was suspected due to a procalcitonin value of 9,9 ng/mL and the patient was started on piperacillin-tazobactam. Ivermectin was continued with resolution of hemoptysis and until elimination of the intestinal parasite on control

stool analysis was confirmed. Subsequently, oral refeeding was carefully reinitiated and the patient was discharged in reasonable medical conditions, with follow up via the outpatient clinic.

DISCUSSION

The global prevalence of infection by *Strongyloidesstercoralis* was previously estimated between 30 and 100 million people. Prevalence numbers are likely to be affected by under reporting of the affected countries, diagnostic methods being used and by the fact that the infection can be asymptomatic. More recently, Buonfrate et al. estimated the global prevalence of strongyloidiasis in 2017 to be 8.1% (95% CI: 4.2%–12.4%), corresponding to 613.9 million infected people. The South-East Asia, African, and Western Pacific Regions accounted for 76.1% of the global infections. Countries in Central America and the northern part of South America had the highest prevalence, particularly Panama (15.7%; 95% CI: 8–23.4%), Costa Rica (15.7%; 95% CI: 8–23.4%), and Colombia (18.4%; 95% CI: 9.4–27.4%)[6]. Severe SHS is primarily a disease of immunocompromised patients, but has rarely been reported in immunocompetent patients [5].

Comment [Ma5]: Number references []

Our patient was initially submitted to the clinic because of chronic vomiting and associated significant weight loss. In one retrospective study about gastric involvement due to *Strongyloidesstercoralis*, the authors found that *Strongyloides* limited to the stomach appears to be rare in the absence of duodenal strongyloidiasis [7]. Biopsies of the gastric and duodenal mucosa in our patient confirmed invasive *Strongyloides*infection (Figure 2).

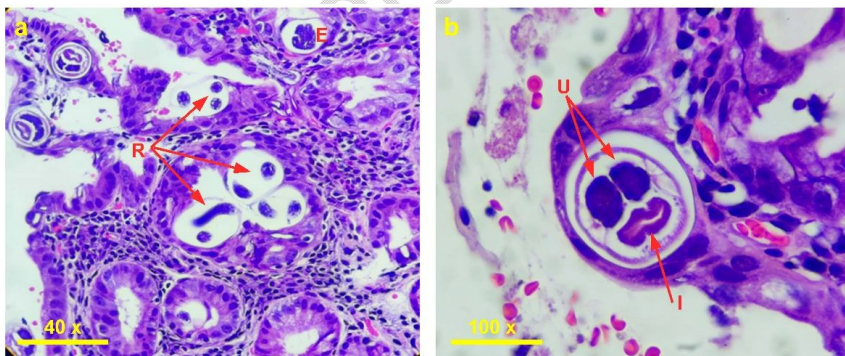


Figure 2: *Strongyloidesstercoralis* various stages of development observed in histological Hematoxylin-Eosin stain (H&E) sections of the gastric mucosa. (a) 40 times magnification: Eggs (E) and Rhabditiform larvae (R) developing in the eggs; (b) 100 times magnification: Female adult parasites, sectioned along the midline showing uterus (U) and intestinal tube (I).

Gerri et al. published the results of a case series of 133 patients with SHS. Immunosuppression was present in 95,5% of patients, mostly long-term corticosteroid treatment. Fever and respiratory symptoms were present in more than 80% of the cases and gastrointestinal symptoms were present in 71.2 % of patients.

Comment [Ma6]: Number references

Shock occurred in 57% and mechanical ventilation was reported in more than 60% of patients and both were associated with high mortality [8].

Our patient did not have known immunodeficiencies, although he was severely malnourished. It is thought that chronic intestinal parasitic infection can cause a malabsorption syndrome and secondary immunodeficiencies [4].

Our case showed clear signs of SHS with pulmonary and gastrointestinal symptoms for which he required ICU. Pulmonary involvement was highly suspected due to persistent cough and hemoptysis [9], but larvae were not observed in the sputum analysis. Pulmonary tuberculosis was discarded by PCR. Remarkably, hemoptysis disappeared rapidly after the treatment with ivermectin was initiated. A secondary bacteremia was suspected based on the elevated procalcitonin level and treated with piperacillin-tazobactam, although blood cultures remained negative.

Comment [Ma7]: Add supporting references

In addition, our case was complicated with a refeeding syndrome with critical hypophosphatemia, which was managed by temporary suspension of parenteral feeding and phosphate supplementation. Combination therapy with albendazole and ivermectin has been proposed to improve the efficiency of mass drug administration targeting both soil-transmitted helminths (STH) and *Strongyloidesstercoralis*. However, there are no clinical trials comparing monotherapy with combination therapy in the setting of SHS [10,11]. Since the patient showed clinical deterioration while receiving albendazole, we decided to change the therapy to ivermectin, which has shown to be more effective as compared to albendazole [12,13]. Singh et al. reported a case of concomitant Mucosa Associated Lymphoid Tissue (MALT) lymphoma associated with *Strongyloidesstercoralis* and *Helicobacter pylori* coinfection [14]. It is unclear whether there is a relationship between *Helicobacter pylori* and *Strongyloides* coinfection. One could argue that chronic ulcerative gastritis due to *Helicobacter* could facilitate colonization and invasive infection with *Strongyloides*, but this association is not supported by histopathological observations.

Anemia is a frequent finding in patients with helminthic infections, with multi-factorial etiology and appears to be at least partly related to gut epithelial and endothelial barrier disruption at the entry site of the parasite [15]. Our patient showed normocytic anemia which was unexpected, as chronic intestinal blood loss would likely result in microcytic anemia, but the result might have been influenced by the blood transfusions which he had received.

CONCLUSION

The patient was initially suspected to have gastric cancer based on endoscopic findings, associated weight loss and anemia. However, his age made this diagnosis less likely and in this tropical country, other causes such as helminthic infections should also be considered and can reliably be ruled out by stool analysis screening.

Comment [Ma8]: conclusions should be in line with the research objectives. suggestions need to be clarified according to the purpose of what the author wants to report.

CONFLICT OF INTEREST STATEMENT

The authors declare that they have no competing financial interests or personal relationships that could have influenced this case report.

CONSENT STATEMENT

Written informed consent for publication was obtained from the patient.

REFERENCES

1. Luvira V, Siripoon T, Phiboonbanakit D, Somsri K, Watthanakulpanich D, Dekumyoy P. Strongyloides stercoralis: A Neglected but Fatal Parasite. *Trop Med Infect Dis.* 2022;7(10):310. doi:10.3390/tropicalmed7100310
2. Yeh MY, Aggarwal S, Carrig M, et al. Strongyloides stercoralis Infection in Humans: A Narrative Review of the Most Neglected Parasitic Disease. *Cureus.* 2023;15(10):e46908. doi:10.7759/cureus.46908
3. Buonfrate D, Bradbury RS, Watts MR, Bisoffi Z. Human strongyloidiasis: complexities and pathways forward. Messenger LA, ed. *Clin Microbiol Rev.* 2023;36(4):e00033-23. doi:10.1128/cmr.00033-23
4. Vasquez-Rios G, Pineda-Reyes R, Pineda-Reyes J, Marin R, Ruiz EF, Terashima A. Strongyloides stercoralis hyperinfection syndrome: a deeper understanding of a neglected disease. *J Parasit Dis.* 2019;43(2):167-175. doi:10.1007/s12639-019-01090-x
5. Chan FLY, Kennedy B, Nelson R. Fatal Strongyloides hyperinfection syndrome in an immunocompetent adult with review of the literature. *Intern Med J.* 2018;48(7):872-875. doi:10.1111/imj.13940
6. Buonfrate D, Bisanzio D, Giorli G, et al. The Global Prevalence of Strongyloides stercoralis Infection. *Pathogens.* 2020;9(6):468. doi:10.3390/pathogens9060468
7. Pecorella I, Okello TR, Ciardi G, Ogwang DM. Is Gastric Involvement by Strongyloides stercoralis in an Immunocompetent Patient a Common Finding? A Case Report and Review of the Literature. *Acta Parasitol.* 2022;67(1):94-101. doi:10.1007/s11686-021-00438-9
8. Geri G, Rabbat A, Mayaux J, et al. Strongyloides stercoralis hyperinfection syndrome: a case series and a review of the literature. *Infection.* 2015;43(6):691-698. doi:10.1007/s15010-015-0799-1
9. Shrestha P, O'Neil SE, Taylor BS, Bode-Omoleye O, Anstead GM. Hemoptysis in the Immunocompromised Patient: Do Not Forget Strongyloidiasis. *Trop Med Infect Dis.* 2019;4(1):35. doi:10.3390/tropicalmed4010035
10. Gandasegui J, Onwuchekwa C, Krolewiecki A, et al. Ivermectin and albendazole coadministration: opportunities for strongyloidiasis control. *Lancet Infect Dis.* Nov;22(11):e341-e347. doi:10.1016/S1473-3099(22)00369-3
11. Palmeirim MS, Hürlimann E, Knopp S, et al. Efficacy and safety of co-administered ivermectin plus albendazole for treating soil-transmitted helminths: A systematic review, meta-analysis and individual patient data analysis. Stolk WA, ed. *PLoS Negl Trop Dis.* 2018;12(4):e0006458. doi:10.1371/journal.pntd.0006458
12. Henriquez-Camacho C, Gotuzzo E, Echevarria J, et al. Ivermectin versus albendazole or thiabendazole for *Strongyloides stercoralis* infection. Cochrane Infectious Diseases Group, ed. *Cochrane Database of Systematic Reviews.* 2016;2016(1). doi:10.1002/14651858.CD007745.pub3

13. Buonfrate D, Rodari P, Barda B, Page W, Einsiedel L, Watts MR. Current pharmacotherapeutic strategies for Strongyloidiasis and the complications in its treatment. *Expert Opinion on Pharmacotherapy*. 2022;23(14):1617-1628. doi:10.1080/14656566.2022.2114829
14. Singh K, Gandhi S, Doratotaj B. Synchronous MALT lymphoma of the colon and stomach and regression after eradication of *Strongyloides stercoralis* and *Helicobacter pylori*. *BMJ Case Rep*. Published online July 3, 2018:2018:bcr2018224795. doi:10.1136/bcr-2018-224795
15. Caldrea S, Ursini T, Santucci B, Motta L, Angheben A. Soil-Transmitted Helminths and Anaemia: A Neglected Association Outside the Tropics. *Microorganisms*. 2022;10(5):1027. doi:10.3390/microorganisms10051027

UNDER PEER REVIEW