

## A CASE REPORT ON RHEUMATIC HEART DISEASE

### Abstract

Rheumatic heart disease is caused secondary to rheumatic fever. Rheumatic fever, a systemic immune response to a beta-hemolytic streptococcal throat infection, remains a significant health issue in developing countries. This is a case report of Rheumatic heart disease in which a 19-year-old female patient was admitted to the hospital with chief complaints of cough with expectoration since for 3 months (sputum of minimal quantity, white to yellowish in colour), bilateral lower limb swelling and joint pains since for 2 months insidious in onset gradually progressive in nature. She did not have any comorbidities. So, based on her signs and symptoms the physician has advised her for CBC, 2D Echo, ECG, C3 & C4 test, chest X-ray, urine routine & analysis, thyroid profile, anti-nuclear antibody test (ANA) and ASLO (antistreptolysin) test. In which her hemoglobin, RBC, WBC and platelets levels were abnormal. Chest X-ray shown presence of cardiomegaly, Urine routine & Analysis shown 4-5 pus cells and 1-2 epithelial cells are seen/hpf. 2D echo shown Dilated chamber, Global LV dysfunction EF- 40%, MVP severe MR: PML (posterior mitral leaflet) calcified, Moderate Aortic regurgitation (AR), Inferior vena cava dilated. ECG shown sinus rhythm, T wave inversion on V1-V3. ASLO test was 549.5 mg/dL which confirms recent streptococcal infection. The treatment was initiated with Antibiotics, Proton pump inhibitors, Antiemetics, Diuretics, Anti-hypertensive, Corticosteroids and NSAID's etc. therefore Rheumatic heart disease can be prevented by preventing streptococcal infections or treating them with Antibiotics when they occurred occur.

**Key words/Keywords:** Rheumatic heart disease (RHD), Rheumatic fever, Beta-hemolytic streptococcal, Cardiomegaly, LV dysfunction, Aortic Regurgitation, Mitral regurgitation (MR), Mitral valve prolapse (MVP).

### Introduction

Rheumatic heart disease is caused secondary to rheumatic fever. Rheumatic fever, a systemic immune response to a beta-hemolytic streptococcal throat infection, causing around 320,000 deaths annually among young people.<sup>1</sup> Acute rheumatic fever (ARF) primarily affects children aged 5-15 and is uncommon in those over 30, about 60% of ARF cases progress to rheumatic heart disease (RHD), which is characterised by Heart Murmurs, Fatigue, Shortness

~~of Breath, Chest Pain, Palpitations, Swollen Joints and Fever~~ Heart Murmurs, Fatigue, Shortness of Breath, Chest Pain, Palpitations, Swollen Joints and Fever characterise. It primarily affects the mitral and aortic valves. The mitral valve is affected in 75-80% of cases, the aortic valve in 30%, and the tricuspid and pulmonary valves in less than 5%.<sup>1</sup>

Mitral Valve Prolapse (MVP) is a condition where the two valve flaps of the mitral valve do not close smoothly or evenly but instead bulge (prolapse) upward into the left atrium during the heart's contraction. This can sometimes lead to blood leaking backward into the left atrium. Mitral Regurgitation (MR) occurs when the mitral valve doesn't close tightly, allowing blood to flow backward into the left atrium when the left ventricle contracts. This backward flow can cause symptoms such as fatigue and shortness of breath, as the heart must work harder to move blood through the body.<sup>2</sup> Dilated cardiomyopathy (DCM) is a heart muscle disorder characterized by a dilated and poorly functioning left ventricle, occurring without abnormal loading conditions (such as hypertension or valve disease) or ischemic heart disease that could cause global systolic impairment.<sup>3</sup>

Antibiotic	Dose	Route	Frequency	Duration
<i>First-line treatment</i>				
Benzathine penicillin (BPG)	1 200 000 U (body weight ≥ 27 kg) 600 000 U (body weight < 27 kg)	Deep intramuscular injection	4weekly, or 3weekly for selected groups	<b>All people with ARF or RHD:</b>  Minimum 10 years after most recent episode of ARF or until age 21 years (whichever is longer)
Amoxicillin	50 mg/kg (Max. 1g)	Intra vascular	Once daily	
<i>Second-line treatment (if intramuscular routine not possible or refused)</i>				<b>Status after initial period has elapsed:</b>

Phenoxyethyl penicillin (penicillin V)	250 mg	Oral	Thrice daily	<ul style="list-style-type: none"> <li>No RHD or mild RHD: discontinue at that time</li> <li>Moderate RHD: continue until age 35 years</li> <li>Severe RHD: continue until age 40 years or longer</li> </ul>
<b>Treatment in cases of documented penicillin allergy</b>				
Clindamycin	20 mg/kg	Oral	Thrice daily	
Azithromycin	12 mg/kg	Oral	Once daily	
Clarithromycin	15 mg/kg	Oral	Twice daily	
Cephalosporin	variable	Oral		
Minimally invasive procedure	valvuloplasty to widen the valve			
Surgery	heart valve surgery Ross procedure			

Table 01: standard treatment for Rheumatic Heart Disease<sup>4</sup>

### Case report

A 19-year-old female patient was admitted in Vijayanagara ~~institute~~ Institute of medical science, Ballari (Karnataka) with chief complaints of cough with expectoration ~~since for~~ 3 months (sputum of minimal quantity, white to yellowish in colour), bilateral lower limb swelling and joint pains since 2 months insidious in onset gradually progressive in nature. On examination, patient was conscious and oriented, BP-120/80mmHg, PR 84 beats/min, P/A-soft, non-tender, no organomegaly and bowel sounds +ve, CVS- S1S2+, R/S-B/L NVBS+. She did not have any comorbidities.

### List 1 :Laboratory Investigations

Laboratory test	Lab parameters	Results
-----------------	----------------	---------

**Comment [DS1]:** Can statistical analysis be used to see the differences in the labs with time?

		D1	D3	D6	D9	D11
Haematology	Haemoglobin(12-16 g/dl)	<b>9.0</b>	<b>8.8</b>	<b>8.6</b>	<b>8.9</b>	<b>11.3</b>
	RBC (3.5-5.0 million/cmm)	<b>5.88</b>	<b>5.64</b>	<b>5.38</b>	<b>5.81</b>	<b>6.74</b>
	WBC (4000-11000 cells/cumm)	<b>17570</b>	<b>14050</b>	<b>23700</b>	<b>17670</b>	<b>16550</b>
	PCV (33-43 %)	<b>32</b>	<b>30.3</b>	<b>29.0</b>	<b>31.4</b>	38.5
	MCV (76-100 fl)	<b>54.4</b>	<b>53.8</b>	<b>53.9</b>	<b>54.0</b>	<b>57.1</b>
	MCH (27-33 pg/cell)	<b>15.3</b>	<b>15.6</b>	<b>16.0</b>	<b>15.3</b>	<b>16.8</b>
	MCHC (33-37 g/dl)	<b>28.0</b>	<b>29.0</b>	<b>29.8</b>	<b>28.3</b>	<b>29.4</b>
	Platelets (1.5-4.5 lacs/cumm)	1.63	<b>4.62</b>	2.24	<b>4.88</b>	<b>7.25</b>
	ESR (0-20 mm/hr)	18				
	LFT	Total protein (6 – 8.3 g/dL)	<b>5.6</b>	<b>5.8</b>	6.3	
Albumin (3.2 - 5.4 g/dL)		<b>2.9</b>	<b>3.0</b>	<b>3.0</b>		
Globulin (2.5 – 3 g/dL)		2.7	2.8	<b>3.3</b>		
A: G (1.2 – 1.5)		<b>1.1</b>	<b>1.1</b>	<b>0.9</b>		
Total bilirubin (0.1-1mg/dL)		<b>1.2</b>	<b>1.3</b>	<b>1.5</b>		
Conj. Bilirubin (0-1.2 mg/dL)		0.5	0.5	0.7		
Unconj. Bilirubin (0.1-0.8))		0.7	0.8	0.8		
ALT (0.35 U/L)		22	16	24		
AST (0-35 U/L)		10	15	10		
ALP (32-120 U/L)		67	63	59		
RFT	Blood urea (20-50mg/dL)	20	<b>16</b>	20		
	Serum creatinine (0.6-1.2mg/dL)	1.0	0.9	0.9		
Thyroid profile	T3 (0.202- 0.443 ng/dL)		<b>0.26</b>			
	T4 (0.92- 1.68 ng/dL)		<b>1.75</b>			
	TSH (0.27- 4.2 mIU/mL)		3.64			
Serology	CRP (0-6 mg/L)	<b>52</b>	<b>114</b>			
	RA factor	- ve				
	C3 (90- 180 mg/dl)	105.4				
	C4 (10- 40 mg/dl)	25.5				
Serum electrolytes	Sodium	139	139	140		
	Potassium	4.1	<b>3.4</b>	3.9		

	Chloride	100	104	99	
Biochemistry	RBS	55	107		
Urine routine & Analysis	Urine microscopy	4-5 pus cells and 1-2 epithelial cells are seen/hpf.			
	Urine sugar	NIL			
	Urine albumin	Present			
	Spot protein	30.9 mgs%			
	Spot creatinine	99.5 mgs%			
	Protein/ creatinine ratio(<0.2)	0.31, 0.75			
ASLO test(Antistreptolysin)	549.5 mg/dl (Upto 200)				
ANA	Weak positive				
2D echo	Dilated chamber Global LV dysfunction EF- 40% MVP severe MR: PML (posterior mitral leaflet) calcified Moderate Aortic regurgitation (AR), Inferior vena cava dilated				
ECG	sinus rhythm, T wave inversion on V1-V3				

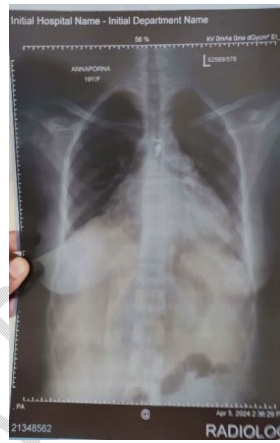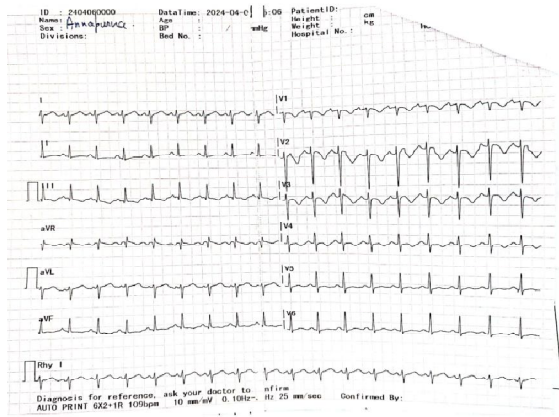


Figure 01: ECG suggestive sinus rhythm, T wave inversion on V1-V3

Figure 02: chest X-ray suggestive of cardiomegaly

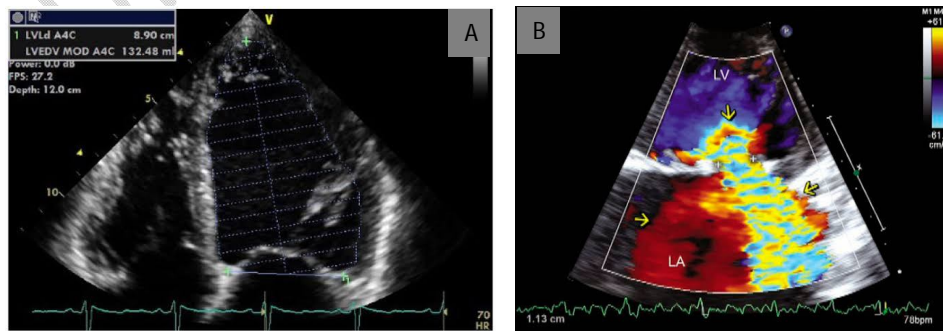


Figure 03: (A) Dilated cardiomyopathy (B) Mitral valve regurgitation

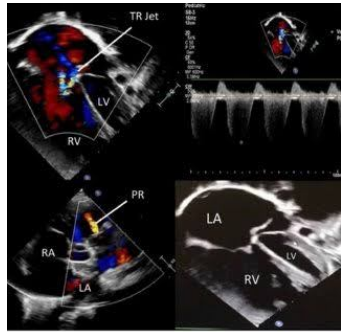


Figure 04: Dilated Inferior vena cava

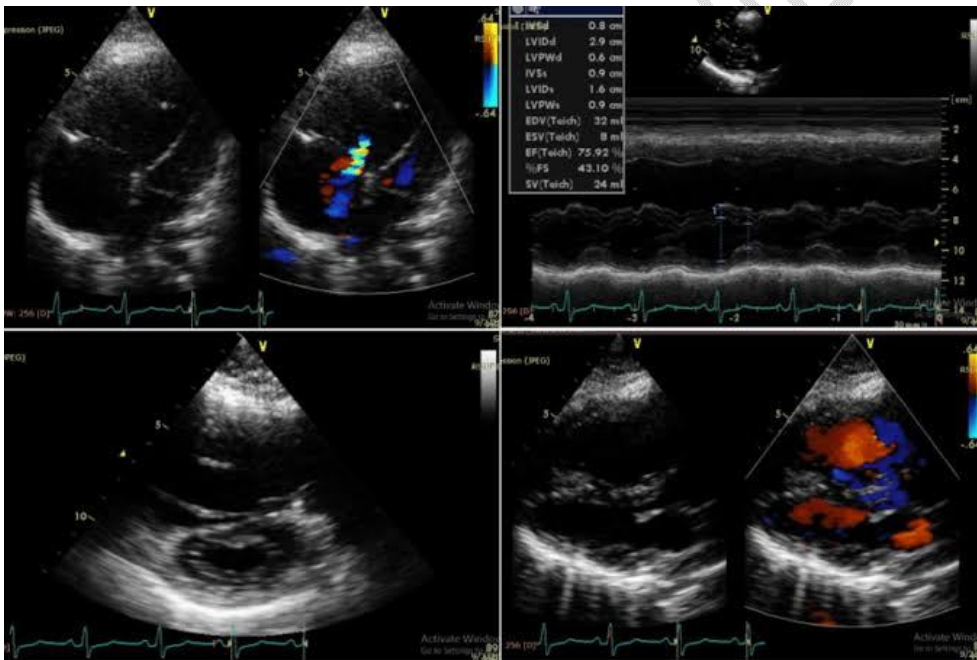


Figure 05: LV dysfunction

Provisional diagnosis: Acute rheumatic fever, post streptococcal glomerulonephritis, nephrotic syndrome (?)

**Final diagnosis: Rheumatic heart disease with mitral valve prolapse and severe mitral regurgitation, dilated cardiomyopathy with severe left ventricular dysfunction.**

**Treatment:** She was started with the following medications

SI No	Name of drugs	Dose	Route	Frequency	Days
1	Amoxicillin & Clavulanate	1.2 g	IV	1-0-1	D1-D11
2	Pantoprazole	40 mg	IV	1-0-0	D1-D11
3	Azithromycin	500 mg	PO	1-0-0	D1
4	Salbutamol	5 ml	PO	1-1-1	D1-D4
5	Neb Duolin&Budecort	6 <sup>th</sup> hrly	PN	1-1-1-1	D1-D2
6	Ondansetron	8 mg	IV	1-0-1 sos	D2-D3
7	Furosemide	20 mg	IV	1-1-0	D3-D11
8	Benzathine Penicillin	1.2 mu	IM		D2
9	Dexamethasone	4 mg	IV	1-1-1	D4-D11
10	Aspirin	300 mg 150 mg	PO	stat 1-1-1-1	D4-D11
11	Metoprolol	25 mg	PO	1-0-1	D11

### Discharge medication

SI no	Name of Medication	Dose	Route	Frequency
1	TAB ASPIRIN	150 mg	PO	0-1-0
2	TAB ATORVASTATIN	40 mg	PO	0-0-1
3	TAB FUROSEMIDE	20 mg	PO	1-1-0
4	INJ BENZATHINE PENICILLIN	1.2 mu	IM	Every 21 days
5	TAB PANTOPRAZOLE	40 mg	PO	1-0-0

### Discussion

Rheumatic heart disease (RHD) is caused secondary to rheumatic fever which is caused due to untreated Group A Streptococcal (GAS) infection. When streptococcal bacteria invade the

body, the immune system typically responds by identifying and eliminating the bacteria. In approximately 97% of cases, this immune response successfully clears the infection. However, in the remaining 2-3% of individuals who are genetically predisposed, the immune system mistakenly targets its own tissues. This occurs because the antigens of the streptococcal bacteria bear structural similarities to human antigens, a phenomenon known as antigenic mimicry. As a result, inflammation and tissue damage can occur, particularly affecting the heart, joints, skin, and central nervous system (CNS).<sup>5</sup> RHD is characterised by chest pain, shortness of breath, fatigue, palpitation, heart murmur, lower limb swelling and cough. It mainly affects valves of our heart particularly mitral and aortic valve and lead to complications of mitral regurgitation, mitral or valvular stenosis, mitral valve prolapse, left ventricular dysfunction and dilated cardiomyopathy. In this case the patient mitral valve was affected.

In this case a 19-year-old female patient was admitted with chief complaints of cough with expectoration since 3 months (sputum of minimal quantity, white to yellowish in colour), bilateral lower limb swelling and multiple joint pains since 2 months insidious in onset gradually progressive in nature. Her past medical history reveals that she did not have any comorbidities so based on her sign and symptoms the physician has advised her for hematology, 2D Echo, ECG, C3 & C4 test, chest X-ray, urine routine & analysis, thyroid profile, anti nuclear antibody test (ANA) and ASLO (antistreptolysin) test. In which her **hemoglobin, RBC, WBC and platelets levels were abnormal**. Chest X-ray shown presence of **cardiomegaly**, Urine routine& Analysis shown **4-5 pus cells and 1-2 epithelial cells are seen/hpf**. 2D echo shown **Dilated chamber, Global LV dysfunction EF- 40%, MVP severe MR: PML (posterior mitral leaflet) calcified, Moderate Aortic regurgitation (AR), Inferior vena cava dilated**. ECG shown **sinus rhythm, T wave inversion on V1-V3**. ASLO test was **549.5 mg/dL** which confirms recent streptococcal infection, ANA shows weak positive and C3, C4, Thyroid tests were normal.

The treatment was initiated with amoxiclav which is a combination of amoxicillin and clavulanate to treat bacterial infection, Pantoprazole to treat gastro-intestinal irritation, azithromycin to treat bacterial infection, salbutamol and nebulisation duolin&budecort to treat breathlessness, ondansetron given as a prophylactic treatment, furosemide to treat edema, Benzathine penicillin to treat streptococcal infection, dexamethasone to treat inflammation, aspirin to treat heart disease, metoprolol to treat hypertension but in this patient tab metoprolol has been prescribed without any indication.

The treatment was initiated as per standard treatment guidelines. ~~Patient~~ Patient's disease condition got improved and discharged from the hospital with the following medications Aspirin to treat heart disease, atorvastatin to prevent high cholesterol levels, furosemide to treat edema, Benzathine penicillin (every 21 days for life time) to treat streptococcal infection and pantoprazole to treat gastro-intestinal irritation. Physician advised patient to review after 10 days.

**Comment [DS2]:** Please explain the parameters on which improvement was measured.

**Comment [DS3]:** Give comparison to other studies and medical treatment commonly used to compare and contrast your results.

## Conclusion

Rheumatic heart disease is a condition where the heart valves have been permanently damaged by Rheumatic fever. Rheumatic heart disease can be prevented by preventing streptococcal infections or treating them with Antibiotics when they occurred. Untreated or under treated strep infections put the patient at increased risk. Treatment depends on how much damage has been done to the heart valves. It may even include surgery to replace a badly damaged valve. The best way to avoid RHD is to treat strep throat when patient has suffering, start using Antibiotic immediately. When strep is treated properly it does not have the opportunity to turn into Rheumatic fever and cause heart problems.

## Reference

1. Rime Abbas, Michael J. Aminoff, et.al. Current Medical Diagnosis & Treatment (CMDT). 63rd ed. San Francisco: McGraw-Hill Education; 2024. Page no 379.
2. Mayo Clinic. Mitral Valve Prolapse [Internet]. <https://www.mayoclinic.org/diseases-conditions/mitral-valve-prolapse/symptoms-causes/syc-20355446>. Accessed June 30, 2024.
3. Amelin F, Hariyanto D, Izzah AZ. Dilated Cardiomyopathy Concomitant with Acute Rheumatic Fever and Sporadic Hereditary Spherocytosis. Health and Medical Journal. 2020 Jul 26;2(2):78-86.
4. Carapetis JR, Brown A, Wilson NJ, Edwards KN. An Australian guideline for rheumatic fever and rheumatic heart disease: an abridged outline. Medical journal of Australia. 2007 Jun;186(11):581-6.
5. Simpson MT, Kachel M, Neely RC, Erwin WC, Yasin A, Patel A, Rao DP, Pandey K, George I. Rheumatic heart disease in the developing world. Structural Heart. 2023 Sep 19:100219. Page no: 1- 9. doi.org/10.1016/j.shj.2023.100219.

UNDER PEER REVIEW

