

Case report

Managing Dual Malaria Infections in Sickle Cell Anemia in Nigeria: A Case Report of *Plasmodium falciparum* and *Plasmodium vivax* Co-infection

ABSTRACT

Introduction: *Plasmodium falciparum* (*P. falciparum*) and *Plasmodium vivax* (*P. vivax*) are the two primary species of parasites that significantly contribute to the global malaria burden. In Nigeria, *P. falciparum* is predominant, whereas *P. vivax* is rare due to the protection conferred by the Duffy-negative red blood cell trait. As a result, co-infection of *P. falciparum* with *P. vivax* is uncommon. The patterns of malaria prevalence are similar to those of sickle cell anaemia (SCA). And in these malaria-endemic areas, infection with the parasite is the most common trigger for sickle cell crises. Therefore, all suspected cases of malaria in SCA should be confirmed through parasite-based diagnostic testing to ensure accurate diagnosis and initiate appropriate treatment.

Presentation of case: An 18-year-old Nigerian male, with SCA presented with fever and mild generalized body pains. Nil history of travel. A positive microscopy and RDT for both *P. vivax* and *P. falciparum* malaria necessitated the use of artemisinin-based combination therapy. Oral primaquine was used for radical clearance of the remaining dormant forms of *P. vivax* in the liver, thus preventing recurrent infections. Treatment was tailored for both malaria and SCA-related complications. He responded to treatment with no significant adverse effects.

Discussion: The accurate and rapid identification of *P. vivax* in a *P. falciparum*-endemic region, facilitated the radical clearance of *P. vivax*. This is particularly important in SCA, as malaria significantly increases morbidity and mortality.

Conclusion: There is need for increased awareness among clinicians regarding the possible diagnosis of mixed *Plasmodium spp.* infections in SCA.

Keywords: *Plasmodium falciparum*, *Plasmodium vivax*, sickle cell anaemia, malaria

1. INTRODUCTION

Plasmodium falciparum (*P. falciparum*) and *Plasmodium vivax* (*P. vivax*), are two predominant species of parasites that cause malaria burdens worldwide¹. In Nigeria, where malaria is endemic, *P. falciparum* accounts

for 89% of infections, while transmission of *P. vivax* is rare². Thus, mixed plasmodium specie infections of *P. falciparum* and *P. vivax* are uncommon in Nigeria. The low prevalence of *P. vivax* is majorly attributed to the resistance to infection created by the Duffy-negative red blood cell inheritance in the region. Despite this genetic historical perspective, there appears to be expanding reports of *P. vivax* infection^{3,4,5}.

The geographical pattern of distribution of *P. falciparum* is identical to that of haemoglobin (Hb) S gene, as the origin of HbS gene is for protection against *P. falciparum* malaria. However, individuals with homozygous inheritance (SS – sickle cell anaemia) do not enjoy such protection against *P. falciparum* malaria. Malaria in sickle cell disease (SCD) is a significant health concern, causing increased morbidity and mortality, particularly in regions where both SCD and malaria are prevalent^{6,7,8}. In these malaria endemic areas, infection with the parasite is the most common precipitating cause of sickle cell crises^{6,7,8}. Individuals with SCD have compromised splenic function, which diminishes the body's natural defense against malaria, and this is combined with the presence of deformed sickle-shaped red blood cells that can block blood vessels and impair blood flow, increasing the risk of severe malaria complications. Thus, the use of life-long malaria chemoprophylaxis is recommended for SCD warriors living in these malaria endemic areas^{6,7,8}.

P. falciparum is responsible for causing the most severe form of malaria while *P. vivax* is thought to cause a less severe benign infection. However, some studies show that where mixed infections of *P. falciparum* and *P. vivax* exist, the severity of *P. falciparum* is reduced by co-infection with *P. vivax*^{9,10}. World health organization (WHO) recommends that before the commencement of treatment, all suspected cases of malaria should be confirmed using parasite-based diagnostic testing via either microscopy or a rapid diagnostic test (RTD)¹. Mixed infections of *P. falciparum* and *P. vivax* are a rare occurrence in Sub Saharan Africa, a non-endemic region for *P. vivax*, highlighting the need for accurate diagnosis, proper clinical management, prevention of relapse and a favorable disease outcome

2. PRESENTATION OF CASE REPORT

An 18-year-old Nigerian male diagnosed with SCA, presented to the hospital's hematology clinic with a 3-day history of fever associated with chills, headache and vomiting. He also gave a history of mild generalized body pains which was somewhat alleviated by taking paracetamol, while the more persistent pain was relieved by taking non-steroidal anti-inflammatory drugs (NSAIDs). He documented a frequency of painful Vaso occlusive episode of 0-1 per year. He was compliant with taking tabs folic acid, 5mg daily and however, not regular on his routine malaria chemoprophylaxis. He had no history of blood transfusions and stable packed cell volume (PCV) was 23%. There was no history of international travel to a *P. vivax* endemic country, no history of recent visit from an international traveler and no history of contact with an infected person with *P. vivax* infection. He lives in Ibadan, Nigeria, about 123 kilometers from the nearest airport and he has no prior history of *P. vivax* infection. In addition, no history of sharing of contaminated needles was noted.

On physical examination, he was mildly pale, mildly icteric and febrile with a temperature of 38.1°C. He had a normal blood pressure, normal respiratory rate and an oxygen saturation of 99% in room air. There was no organomegaly present. No neurological deficits were noted. Pain score was 3/10.

Laboratory investigations revealed a normal white blood cell count (WBC)- $6.2 \times 10^9/L$, normal neutrophil count - $3.2 \times 10^9/L$, normal platelet count (PLT) - $190 \times 10^9/L$, haemoglobin- 7.5 g/dl and PCV -22%. Serum indirect bilirubin was 1.0mg/dL and alkaline phosphatase was 140U/L. **No abnormalities were detected in the kidney function.** His recent high-performance liquid chromatography (HPLC) showed Hb S: 93.7%, Hb F: 3.4% and Hb A2: 2.9% consistent with sickle cell anaemia. Rapid diagnostic test kit (CTK Biotech. Inc, On-Site Malaria Pf/Pv Ab Combo Rapid Test) for malaria parasite revealed a positive result for both *P. falciparum* (Pf- merozoite surface protein (MSP)) and *P. vivax*(Pv-MSP) -Figure 1. Thick and thin blood films were made and stained with Giemsa stain. This showed morphologic forms (ring forms, trophozoites, schizonts and gametocytes) of *P. falciparum* and *P. vivax* with a *P. falciparum* dominance. The level of parasitemia was 3.6 %. Thus, enabling a diagnosis of mixed *P. falciparum* and *P. vivax* infection.

The patient was treated as an outpatient with dihydroartemisinin-piperaquine oral drugs for 3 days, paracetamol and NSAIDs¹¹. He was counselled to continue daily routine drugs as well as liberal oral fluids and to report to the hospital if symptoms do not improve. A week after, he was seen at the clinic where he reported resolution of symptoms and was in a stable clinical state. A repeat combo rapid diagnostic test kit was negative for both *P. falciparum* and *P. vivax*. In addition, Giemsa stained thick and thin blood films did not show any parasite morphological form. The WBC and PLT count were normal and PCV was 23%. To eradicate the hypnozoite forms of *P. vivax*, oral primaquine 30mg daily for 14 days was prescribed¹². This was done after glucose -6-phosphate-dehydrogenase (G6PD) deficiency was excluded via patient's clinic records. He was counselled on ensuring drug compliance with routine malaria chemoprophylaxis- proguanil, as well as the need to use insecticide treated nets to reduce transmission of malaria. The patient showed a positive response to treatment with no significant adverse effects.

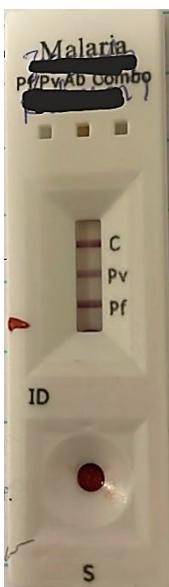


Figure 1: Rapid diagnostic test (RDT) combo kit for malaria parasite showing positive result for both *P. falciparum* and *P. vivax*.

3. DISCUSSION

The *Plasmodium* species responsible for human infections are *P. falciparum*, *P. vivax*, *Plasmodium malariae*, *Plasmodium ovale* and *Plasmodium knowlesi*¹. Each *Plasmodium* species has its own unique epidemiological characteristic; however, *P. falciparum*, *P. vivax* and *Plasmodium malariae* have the most widespread distribution. Of these 3, *P. malariae* infections are less common compared to *P. falciparum* and *P. vivax*. In sub-Saharan Africa, *P. falciparum* has a significant presence¹³ while, *P. vivax* is less common in sub-Saharan Africa but has predominance in Asia, Central and South America, the Middle East, and the Western Pacific¹⁴. The year 2022 WHO world malaria report recorded that Nigeria had the highest malaria burden in the world (27% of all cases and 31% of all deaths)¹⁵. In addition, the year 2023 WHO world malaria report, observed an increase of malaria cases by 5 million with Nigeria (+1.3 million), as the 2nd highest contributor¹⁶.

Nigeria by virtue of its large population, has the largest burden of SCA in the world with a sickle cell carrier rate of 15- 30%^{17,18}. The epidemiology of sickle cell gene mirrors that of *P. falciparum* endemicity with *P. falciparum* accounting for about 95% of infections in Nigeria. This makes it a major public health concern in the region¹. Our patient is a native of Nigeria and lives in Nigeria, an endemic country for *P. falciparum* and SCA. He did not have a travel history to a *P. vivax* endemic country. Thus, it is a rare case of mixed *P. falciparum* and *P. vivax* locally transmitted infection in a SCA individual with *P. falciparum* being the dominant malaria species.

The co-infection of *P. falciparum* with locally transmitted *P. vivax* infection also highlights the need for a review of *P. vivax* epidemiology in the Nigerian population. A study in southwestern Nigeria revealed the presence of *P. vivax* even in individuals who were Duffy-negative³. Majority of the infections were due to *P. falciparum* either as a single infection 85.5% (219/256), or mixed with *P. malariae* 6.3% (16/256) or *P. vivax* 1.6% (4/256)³. Hence, this proposed review is essential because the Duffy-negative trait predominant in the sub region, typically reduces susceptibility to *P. vivax* infection. The Duffy antigen functions as a receptor for *P. vivax*. Therefore, detection of *P. vivax* co-infection in a Duffy antigen negative (Fy-/-) population supports the recent perspective that *P. vivax* may utilize other non-dominant receptors for red cell invasion besides from the Duffy antigen¹⁹. Meaning that the Duffy negativity protection is not absolute¹⁹.

Plasmodium falciparum is responsible for majority of severe and life-threatening cases of malaria such as cerebral malaria, severe anaemia, multi-organ failure and death²⁰. Whereas, *P. vivax* is generally considered less severe, although cases of severe malaria can occur. The occurrence of sickle cell disease and malaria is associated with increased mortality and morbidity. The homozygous form of sickle cell disease (SS) confers an increased susceptibility to the harmful effects of malaria⁷. The increased susceptibility is due to the formation of

abnormal hemoglobin polymers in low oxygen conditions, resulting in red cell sickling. These less flexible sickled cells stick together easily and adhere to the walls of blood vessels, causing blockages and reduced blood flow which leads to vaso-occlusive crises. The consequence of this crisis is severe pain, tissue damage and organ dysfunction. Furthermore, the fragility of the sickled cells makes them hemolyze easily, contributing to chronic anemia. Additionally, malaria can further exacerbate anaemia in individuals with SCA because low PH and low oxygen tension caused by the parasites in the red cells causes its deformation into sickle cells with subsequent lysis. Thus, parasitized sickle cells can precipitate a vaso occlusive pain episode or a sequestration crisis. The vulnerability is also exacerbated by the spleen losing its function of removing parasitized red cells from the circulation due to auto splenectomy and this impaired splenic function still occurs in those individuals with an intact spleen present^{21,22}. Hence, to protect these vulnerable individuals with sickle cell disease from the risks associated with malaria, the use of malaria prophylaxis is recommended⁸. This patient was not regular on his routine malaria prophylaxis- proguanil, however, this would not have prevented a *P. vivax* transmission. Proguanil alone is not an effective prophylaxis for *P. vivax*. Few studies have observed that individuals with mixed *P. falciparum* and *P. vivax* have less severe infections as *P. vivax* can reduce the parasitemia of *P. Falciparum*²³. Proposed explanations include *Plasmodium* species competition within the host and immunomodulatory host defence via cross-reactive antibody protection²³. The index patient did not have features of severe malaria such as prostration, respiratory distress, repeated vomiting or haematocrit < 20% and as such was managed as an outpatient.

The Nigerian government promotes the use of microscopic observation of Giemsa-stained thick and thin blood films or RDT before treating suspected cases of malaria²⁴. Early and prompt detection of *Plasmodium* species via efficient and easily accessible testing techniques allows appropriate drug prescription, better protection against plasmodium relapse and better treatment outcomes. Microscopic examination of Giemsa-stained thick and thin blood film is the gold standard test method recommended by the Center for Disease Control and Prevention (CDC) for the detection and species identification of *Plasmodium*²⁵. Mixed *Plasmodium* species infection (*P. falciparum* and *P. vivax*) recorded in this patient was diagnosed and identified by a well-trained experienced microscopist. It is known that depending on parasite density, there is a risk of misdiagnosis, misidentification and therefore inappropriate management while relying solely on microscopy examination. We had both RDT and microscopic examination of Giemsa - stained thick and thin blood films performed. The RTD used for the index patient detected both *P. falciparum* and *P. vivax* within a single test. World Health Organization (WHO) recommends use of RTD for point of care diagnosis for low resource settings and in areas where good quality microscopy techniques are unavailable²⁶. A major challenge to many healthcare systems in the country is that RDT for non - *falciparum Plasmodium* species is rarely available.

Of important note is that artemisinin-based medications will clear the *Plasmodium* species blood stage infections but not the hypnozoite stage of infection. Thus, with proper *Plasmodium* species diagnosis, our patient was given effective treatment (artemisinin-based regimen) to clear the blood stages of *P.falciparum* and

P. vivax as well as primaquine tablets to radically clear the dormant *P. vivax* parasites in the liver, preventing relapsing malaria. We ensured safe administration of primaquine by checking for the absence of glucose-6-phosphate dehydrogenase (G6PD) deficiency. He was counseled to report to the hospital promptly for treatment whenever he has a fever and advised on mosquito control measures to prevent malaria such as use of insecticide treated bed nets, indoor insecticide use, proper liquid waste disposal and use of malaria chemoprophylaxis.

4. CONCLUSION

Plasmodium falciparum co-infection with *P. vivax* is uncommon in Nigeria, a country where Duffy-negative individuals are less likely to be infected with *P. vivax*. When malaria occurs in SCA, early and efficient diagnosis and species identification with appropriate treatment and prophylaxis measures are crucial for preventing relapse and severe complications. Thus, this case highlights the need for greater clinician awareness, primarily through local language information, education and communication (IEC) and behavior, change, communication (BCC) initiatives. Additionally, there is need for further research to enhance the diagnosis and treatment of mixed *Plasmodium* spp. infections in patients with SCA.

Ethical Approval:

As per international standards or university standards written ethical approval has been collected and preserved by the author(s).

Consent

As per international standards or university standards, patient(s) written consent has been collected and preserved by the author(s).

Disclaimer (Artificial intelligence)

Option 1:

Author(s) hereby declare that NO generative AI technologies such as Large Language Models (ChatGPT, COPILOT, etc) and text-to-image generators have been used during writing or editing of manuscripts.

Option 2:

Author(s) hereby declare that generative AI technologies such as Large Language Models, etc have been used during writing or editing of manuscripts. This explanation will include the name, version, model, and source of the generative AI technology and as well as all input prompts provided to the generative AI technology

Details of the AI usage are given below:

- 1.
- 2.
- 3.

REFERENCES

- 1 <https://www.who.int/news-room/fact-sheets/detail/malaria>(Assessed July 25th 2024).
2. Nigeria National Malaria Elimination Programme, LSHTM and KEMRI-Wellcome Trust Research Programme (2018). Nigeria: A Profile of Malaria Control and Epidemiology, 2018 Overview. A report prepared for the Federal Ministry of Health, Nigeria and the Department for International Development, UK. 2018.
3. Oboh, M.A., Singh, U.S., Ndiaye, D. et al. Presence of additional *Plasmodium vivax* malaria in Duffy negative individuals from Southwestern Nigeria. *Malar J.* 2020;19:229.
4. Oboh MA, Badiane AS, Ntadom G, Ndiaye YD, Diongue K. Molecular identification of *Plasmodium* species responsible for malaria reveals *Plasmodium vivax* isolates in Duffy negative individuals from southwestern Nigeria. *Malar J.* 2018;17:439.
5. Howes RE, Reiner RC Jr, Battle KE, Longbottom J, Mappin B, Ordanovich D, et al. *Plasmodium vivax* transmission in Africa. *PLoS Negl Trop Dis.* 2015;9:e0004222.
6. Konotey-Ahulu FID. Malaria and sickle-cell disease. *British Medical Journal.* 1971;2:710-1.
7. Luzzatto L. Sickle cell anaemia and malaria. *Mediterr J Hematol Infect Dis.* 2012;4:e2012065.
8. Oniyangi O, Omari AA. Malaria chemoprophylaxis in sickle cell disease. *Cochrane Database Syst Rev.* 2006;2006:CD003489.
9. Maitland K, Williams TN, Newbold CI: *Plasmodium vivax* and *P. falciparum*: biological interactions and the possibility of cross-species immunity. *Parasitol Today.* 1997;13:227-31.
10. Mayxay M, Pukrittayakamee S, Newton PN, White NJ: Mixed-species malaria infections in humans. *Trends Parasitol.* 2004;20:233-40.
11. Anekar AA, Hendrix JM, Cascella M. WHO analgesic ladder. In: Statpearls. Treasure Island (FL): Statpearls publishing; 2024.
12. John GK, Douglas NM, von Seidlein L, Nosten F, Baird JK, White NJ, Price RN. Primaquine radical cure of *Plasmodium vivax*: a critical review of the literature. *Malar J.* 2012 Aug 17;11:280.
13. Hay SI, Guerra CA, Gething PW, Patil AP, Tatem AJ, Noor AM, Kabaria CW, Manh BH, Elyazar IR, Brooker S, Smith DL, Moyeed RA, Snow RW. A world malaria map: *Plasmodium falciparum* endemicity in 2007. *PLoS Med.* 2009;6:e1000048.
14. Gething PW, Elyazar IRF, Moyes CL, Smith DL, Battle KE, Guerra CA, et al. A Long-Neglected World Malaria Map: *Plasmodium vivax* Endemicity in 2010. *PLoS Negl Trop Dis.* 2012;6:e1814.

15. World Health Organization. World Malaria Report. Geneva, Switzerland. 2022.
16. World Health Organization. World Malaria Report. Geneva, Switzerland. 2023.
17. World Health Organization. Report by the Secretariat of the Fifty-ninth World Health Assembly A59/9. 2006.
18. Professor Akinyanju O. The National Burden of Sickle Cell Disorder And the Way Forward. Sickle Cell Foundation, Nigeria. 2010.
19. Twohig KA, Pfeffer DA, Baird JK, Price RN, Zimmerman PA, Hay SI, et al. Growing evidence of *Plasmodium vivax* across malaria-endemic Africa. PLoSNegl Trop Dis. 2019;13: e0007140.
20. Zekar L, Sharman T. Plasmodium Falciparum malaria. In: Statpearls. Treasure Island (FL): Statpearls Publishing; 2024.
21. Tubman VN, Makani J. Turf wars: exploring splenomegaly in sickle cell disease in malaria-endemic regions. Br J Haematol. 2017;177:938–46.
22. Brousse V, Buffet P, Rees D. The spleen and sickle cell disease: the sick(led) spleen. Br J Haematol. 2014;166:165–76.
23. Maitland K, Williams TN, Newbold CI: Plasmodium vivax and P. falciparum: biological interactions and the possibility of cross-species immunity. Parasitol Today. 1997;13:227-31.
24. U.S. President's Malaria Initiative Nigeria Malaria Operational Plan FY 2022. Retrieved from www.pmi.gov (assessed August 15th 2024).
25. https://www.cdc.gov/malaria/diagnosis_treatment/diagnostic_tools.html (assessed August 15th 2024).
26. <https://www.who.int/teams/global-malaria-programme/case-management/diagnosis/rapid-diagnostic-tests> (assessed August 15th 2024).