

## Case report

### MPO ANCA positivity in IgA nephropathy: Imposter or Implication??

#### ABSTRACT

**BACKGROUND:** The cause of rapidly progressive glomerulonephritis (RPGN) is pauci immune crescentic glomerulonephritis (GN), followed by Immune complex mediated GN and anti Glomerular basement membrane (GBM) disease. Anti neutrophil cytoplasmic autoantibody (ANCA) is characterised by crescentic necrotizing GN on renal biopsy with minimal deposits. Immunoglobulin A (IgA) nephropathy may present as crescentic GN with mesangial IgA deposits and sometimes around capillary as well.

**CASE PRESENTATION:** This case describes a rare presentation of RPGN which was myeloperoxidase (MPO) positive on enzyme immunoassay (EIA) with central nervous system (CNS) vasculitis presenting as hemiparesis. Patient was treated as ANCA vasculitis, with plasmapheresis (PLEX) and Cyclophosphamide as Standard of care. However, renal biopsy did later revealed features of crescentic IgA nephropathy. However the presence of systemic symptoms makes IgA nephropathy as the sole diagnosis unlikely, hence a possibility of MPO IgA concurrence remains high. Our case is at sustained remission at 6 months after 10 doses of cyclophosphamide as SOC and has been shifted to maintenance on Azathioprine (Aza), given the possibility of relapse and presence of extra renal manifestation.

**CONCLUSION:** Hence MPO ANCA vasculitis and IgA nephropathy is rare concurrence, however may achieve remission when treated in lines of AAV with further maintenance.

**Keywords:** MPO vasculitis; IgA nephropathy; Crescentic GN; RPGN; biopsy

#### INTRODUCTION:

Immunoglobulin A (IgA) nephropathy is the most prevalent primary glomerulonephritis (GN).<sup>1</sup> Antineutrophil cytoplasmic associated vasculitis (AAV) is the most common cause of rapidly progressive crescentic GN.<sup>2</sup> AAV can be of two types according to enzyme immunoassay (EIA): Myeloperoxidase (MPO) or Proteinase 3 (PR3). However, the co existence of these two entities is rarely reported, if so, the mutual effect on one another's pathogenesis is questionable. No more than 30 cases of such AAV and IgA nephropathy have been reported with just two case series.<sup>3,4</sup>

This case reports highlights the presence of overlapping MPO AAV and IgA nephropathy with presence of extra renal systemic manifestation and similar response to therapy as in isolated AAV: hence predominating the clinical picture.<sup>5</sup> Crescentic IgA nephropathy though standard of care (SOC) is similar to AAV; responses is poorer than AAV.<sup>6</sup>

#### CASE PRESENTATION:

A 54 year hypothyroid and hypertensive patient presented with renal dysfunction and dyspnea for one and half months. There was no associated frothiness of urine, oliguria, hematuria, fever or extra renal manifestation.

**Comment [M1]:** What is the sex of patient?

On examination, her blood pressure: 180/110 mm of Hg, pedal edema: ++, pallor: +; Disptick: protein 2+, Blood: moderate.

Baseline investigations revealed: Hemoglobin 6.7 gm/dL, platelets 2.2 lakh/mm<sup>3</sup> and Total count 8,100/mm<sup>3</sup>. Serum sodium was 134 mmol/L, potassium 4.2 mmol/L, urea 110mg/ dL, creatinine 4.1 mg/dL. HBsag HCV HIV1 & 2 were negative. Urine routine examination showed albumin 2+; 2-3 pus cell; Rbc: 20/hpf and 24 hours quantitative urine protein was 957 mg. Ultrasound of abdomen showed normal sized kidneys with slightly raised cortical echogenicity and maintained cortico-medullary differentiation. Echocardiography showed left ventricular ejection fraction of 67% no regional wall motion abnormality, no pulmonary artery hypertension. HRCT thorax shows- mild subpleural atelectatic changes in anterior basal segment of left lower lobe, minimal left sided pelural effusion.

As she was diagnosed as a case of rapidly progressive GN, auto immune profile was sent to look for the etiology. C3:77 (low)→normalised after 1 wk; C4: 24; ANA (hep 2): negative; PR3 levels: normal; MPO: positive (155).

**Comment [M2]:** Please write normal range of your lab data

She was initiated on Plasma exchange (PLEX) being a case of MPO AAV (Renal limited). However after 4 session of Plex; she developed seizures and hemiparesis. MRI brain: showed diffuse multiple small patch of T2 weighted hyperintensity and diffuse restriction seen in bilateral cerebral hemispheres all the lobes in both grey and white matter, some in right cerebellum: hence a diagnosis of Central nervous vasculitis was made. She was then further managed on the lines of systemic AAV with Intravenous Cyclophosphamide.

Renal biopsy done at after completion of PLEX revealed:

Light Microscopy: 11 glomeruli identified; 2 are segmentally sclerosed with adhesion formation. Rest 9 non sclerosed tufts show enlargement, diffuse matrix mesangial expansion and mesangial hypercellularity. Total 6 glomeruli show crescent formation: 4 are circumferential (3 fibrocellular, 1 fibrous) and 2 are segmental (1 fibrocellular, 1 fibrous). GBM fragmented at site of crescent formation. Tubules: mild atrophy. Vessels: arteriolar

medial thickening. Interstitium: mild fibrosis. Focal lymphocytic infiltration in scarred interstitium. IF/ TA: 10% (Picture 1)

Immunofluorescence: 11 glomeruli:- IgG: negative; IgA: 2+ granular mesangial deposit; IgM: negative; C3c: 1+ granular mesangial deposit; C1q: negative; Kappa: 1+ granular mesangial deposit; Lambda: 2+ granular mesangial deposit (Picture 2)

Impression: Crescentic and sclerosing glomerulonephritis with mild tubulointerstitial chronicity. Considering serology and DIF, possibility of combined IgA nephropathy (M1 E0 S1 TO C2) with AAV remains strong.

As crescentic IgA is to be managed on the lines of AAV and possibility of MPO IgA nephropathy overlap in background of systemic features, patient completed 6 doses of Cyclophosphamide Intravenous @12.5mg/kg. Her creatinine stabilised to 1.2 after 2 months and was off dialysis since completion of PLEX. Being MPO titre high positive and presence of extra renal symptoms as CNS vasculitis, she was initiated on maintenance therapy with Azathioprine @2mg/kg on the lines of AAV with no further relapse till date in sustained remission for past 6months.

#### DISCUSSION:

AAV is usually diagnosed by EIA with MPO/PR3 antibody levels and confirmed on biopsy by presence of pauci immune necrotizing and crescentic GN on biopsy. Systemic features may be present in MPO AAV.<sup>7</sup> However in cases of rapidly deteriorating renal function, if high titre of MPO/ PR3 AAV is positive, treatment with plasmapheresis may be initiated without confirmation on biopsy.<sup>8</sup> C3 may be low in about 20% of AAV.<sup>9</sup>

IgA nephropathy usually presents asymptotically or with macroscopic hematuria,<sup>10</sup> RPGN as a presenting feature is rare.<sup>11</sup> Presence of systemic features with IgA nephropathy unlikely encountered.

Concurrent presence of MPO high titres with IgA nephropathy is a rare entity and limited literature regarding this is available.<sup>12</sup> Two possibilities may occur: MPO+ AAV showing features of IgA nephropathy in biopsy<sup>13</sup> or a biopsy proven IgA nephropathy patient develops MPO+ AAV with pauci immune picture on next biopsy.<sup>14</sup>

O'Donoghue observed that 2% of patients with IgA nephropathy showed serum IgG-ANCA positivity.<sup>15</sup> Haas et al. reported findings on six ANCA-positive patients with IgAN, with crescents in more than 50% of glomeruli. The cases resembled ANCA-associated crescentic glomerulonephritis in both histological features and response to aggressive immunosuppressive therapy.<sup>16</sup> Bantiset al. Observed eight ANCA-positive patients with IgAN, with more than 10% crescentic glomeruli, and reported more severe clinical manifestations and histological lesions, but better response to therapy, when compared with ANCA-negative patients.<sup>17</sup>

Whether such concurrence is merely coincidental or has a role in pathogenesis/ predisposition for the other is not yet established. ANCA-associated (pauci-immune) crescentic GN is characterized by lesser endocapillary hypercellularity and more disruption of Bowman's capsule than immune complex-related crescentic GN.<sup>18</sup> Treatment of crescentic IgA nephropathy has been less successful than pauci immune crescentic GN when given similar therapy; hence possibility of a favourable outcome stands in patients of IgA nephropathy who are MPO positive.<sup>19</sup> Treatment has been done in the lines AAV in most previous reports with successful outcome, also the presence of systemic vasculitis favours the role of MPO antibodies and role of maintenance therapy.

Hence, anti-MPO and anti-PR3 serological tests should be done in all cases if a renal biopsy shows a necrotizing and/or crescentic GN with glomerular IgA deposits, particularly if there is limited mesangial and endocapillary hypercellularity. A positive anti-MPO and/or anti-PR3 serological test result in association with such a lesion may be responding better to corticosteroid and cytotoxic therapy.

#### LIST OF ABBREVIATIONS:

RPGN: rapidly progressive glomerulonephritis, GN: glomerulonephritis, GBM: glomerular basement membrane, MPO: myeloperoxidase, EIA: enzyme immunoassay, PLEX: plasmapheresis, IgA: Immunoglobulin A, AAV: ANCA associated vasculitis, SOC: standard of care

#### DECLARATION:

- ❖ Ethics approval and consent to participate: This study has been reviewed by the IPGME&R research oversight ethics committee and has therefore been performed in accordance with the ethical standards laid down in an appropriate version of the Declaration of Helsinki (as revised in Brazil 2013).

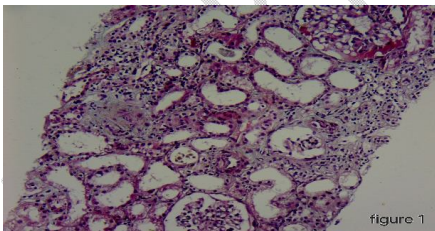
This patient gave her informed consent prior to her inclusion in the study.

- ❖ Consent for publication: Taken
- ❖ Availability of data and materials: The datasets used and/or analysed during the current study are available from the corresponding author on reasonable request.

## REFERENCES:

1. Treatment of IgA nephropathy Barratt, J. et al. *Kidney International*, Volume 69, Issue 11, 1934 – 1938. <https://doi.org/10.1038/sj.ki.5000419>
2. Syed R, Rehman A, Valecha G, El-Sayegh S. Pauci-Immune Crescentic Glomerulonephritis: An ANCA-Associated Vasculitis. *Biomed Res Int*. 2015;2015:402. <https://doi.org/10.1155/2015/402826>
3. Haas M, Jafri J, Bartosh SM et al. ANCA-associated crescentic glomerulonephritis with mesangial IgA deposits. *Am J Kidney Dis* 2000; 36: 709–718
4. Bantis C, Stangou M, Schlaugat C et al. Is presence of ANCA in crescentic IgA nephropathy a coincidence or novel clinical entity? A case series. *Am J Kidney Dis* 2010; 55: 259–268.
5. Allmaras E, Nowack R, Andrassy K et al. Rapidly progressive IgA nephropathy with anti-myeloperoxidase antibodies benefits from immunosuppression. *Clin Nephrol* 1997; 48: 269–273
6. Tumlin JA, Lohavichan V, Hennigar R. Crescentic, proliferative IgA nephropathy: clinical and histological response to methylprednisolone and intravenous cyclophosphamide. *Nephrol Dial Transplant*. 2003 Jul;18(7):1321-9. <https://doi.org/10.1093/ndt/gfg081>
7. Austin K, Janagan S, Wells M, Crawshaw H, McAdoo S, Robson JC. ANCA Associated Vasculitis Subtypes: Recent Insights and Future Perspectives. *J Inflamm Res*. 2022 Apr 21;15:2567-2582. <https://doi.org/10.2147%2FJIR.S284768>
8. *Nephrology Dialysis Transplantation*, Volume 38, Issue 11, November 2023, Pages 2637–2651, <https://doi.org/10.1093/ndt/gfad090>
9. Augusto J-F, Langs V, Demiselle J, Lavigne C, Brilland B, Duveau A, et al. (2016) Low Serum Complement C3 Levels at Diagnosis of Renal ANCA-Associated Vasculitis Is Associated with Poor Prognosis. *PLoS ONE* 11(7): e0158871. <https://doi.org/10.1371/journal.pone.0158871>
10. Gutiérrez E, Carvaca-Fontán F, Luzardo L, Morales E, Alonso M, Praga M. A personalized update on IgA nephropathy: a new vision and new future challenges. *Nephron*. 2020 Nov 2;144(11):555-71. <https://doi.org/10.1159/000509997>
11. Ari Shimizu, Takashi Takei, Takahito Moriyama, Mitsuyo Itabashi, Keiko Uchida, Kosaku Nitta, *Clinical and Pathological Studies of IgA Nephropathy Presenting as a Rapidly Progressive Form of Glomerulonephritis*, *Internal Medicine*, 2013, Volume 52, Issue 22, Pages 2489-2494. <https://doi.org/10.2169/internalmedicine.52.0420>
12. Yang YZ, Shi SF, Chen YQ, Chen M, Yang YH, Xie XF, Zou R, Lv JC, Liu LJ, Zhang H. Clinical features of IgA nephropathy with serum ANCA positivity: a retrospective case-control study. *Clin Kidney J*. 2015 Oct;8(5):482-8. <https://doi.org/10.1093%2Fckj%2Fsv078>
13. Yasukawa M, Kitagawa S, Togashi R, Asakawa S, Nagura M, Arai S, Yamazaki O, Tamura Y, Kondo F, Ohashi R, Uchida S, Shibata S, Fujigaki Y. A Patient with MPO-ANCA-positive IgA Nephropathy Diagnosed with the Clinical Onset of Macrohematuria. *Intern Med*. 2019 Jul 15;58(14):2051-2056. <https://doi.org/10.2169%2Finternalmedicine.2475-18>

14. Natalia Chebotareva, Elena Kamyshova, Nikolay Bulanov, Lidia Lysenko, Sergey Moiseev, Antineutrophil cytoplasmic autoantibody (ANCA) positive immunoglobulin A (IgA) nephropathy: Case reports and review of literature, *The Egyptian Rheumatologist*, Volume 42, Issue 3, 2020, Pages 251-254, ISSN 1110-1164. <https://doi.org/10.1016/j.ejr.2020.06.002>
15. O'Donoghue DJ, Nusbaum P, Noel LH et al. Antineutrophil cytoplasmic antibodies in IgA nephropathy and Henoch-Schönlein purpura. *Nephrol Dial Transplant* 1992; 7: 534–538
16. Haas M, Jafri J, Bartosh SM et al. ANCA-associated crescentic glomerulonephritis with mesangial IgA deposits. *Am J Kidney Dis* 2000; 36: 709–718
17. Bantis C, Stangou M, Schlaugat C et al. Is presence of ANCA in crescentic IgA nephropathy a coincidence or novel clinical entity? A case series. *Am J Kidney Dis* 2010; 55: 259–268
18. Savige J, Davies D, Falk RJ, Jennette JC, Wiik A: Antineutrophil cytoplasmic antibodies and associated diseases: A review of the clinical and laboratory features. *Kidney Int* 57:846-862, 2000
18. Roccatello D, Ferro M, Coppo R, Giraudo G, Quattrocchio G, Piccoli G: Report on intensive treatment of extracapillary glomerulonephritis with focus on crescentic IgA nephropathy. *Nephrol Dial Transplant* 10:2054-2059, 1995
19. Lv J, Yang Y, Zhang H, Chen W, Pan X, Guo Z, Wang C, Li S, Zhang J, Zhang J, Liu L, Shi S, Wang S, Chen M, Cui Z, Chen N, Yu X, Zhao M, Wang H. Prediction of outcomes in crescentic IgA nephropathy in a multicenter cohort study. *J Am Soc Nephrol*. 2013 Dec; 24(12):2118-25. <https://doi.org/10.1681/ASN.2012101017>



Picture 1 Focal lymphocytic infiltration in scarred interstitium

Picture 2 Granular mesangial deposit

