

Review Article

Transabdominal versus Transvaginal Sono-elastography, which is more valuable in GI-RADS Classification of Different Adnexal Masses?

Abstract

Background: Ovarian cancer is the most lethal gynecological malignancy and the fifth most common cause of cancer-related death in women, accounting for a wide range of histological diagnoses. Ultrasound is frequently the first-line imaging modality for evaluating masses because it is widely available, inexpensive, and noninvasive, with no radiation hazards. **The current study aimed** to assess the diagnostic performance of trans-vaginal versus trans-abdominal sono-elastography in Gynecologic Imaging Reporting and Data System (GIRADS) of adnexal masses and detect cut-off values for malignancy in both methods. The current study enrolled 40 females, during the period from October 2022 to the end of January 2023, after approval of ethical committee of our institution.

Results: Forty female patients were enrolled in this study, their ages ranged from 28 to 72 years old, with mean \pm SD (48.6 \pm 12.96). Distribution of GI-RADS scores of the studied cases was as follows; GI-RADS III was in (12 patients; 75%) and, less commonly IV in (4 patients; 25%), while malignant masses were mainly of GI-RADS V that was noted in (20 patients; 83.2%) and less commonly IV in (4 patients; 16.8%). A statistically significant correlation was detected in the present study between the GI-RADS score and the transabdominal sono-elastography and transvaginal sono-elastography with, (p-value=0.002*), (p-value=0.001*) respectively.

Conclusions: Trans-vaginal elastography has higher diagnostic performance than trans-abdominal (TA) elastography in assessment of adnexal masses, with malignancy cut-off values were, strain ratio (SR) of trans-abdominal elastography were 3.85, and for trans-vaginal (TV) were 4.75.

Keywords: Gynecological Imaging Reporting and Data system, GIRADS, Sono-elastography, Adnexal masses, ovarian cancer, elasticity score, strain ratio (SR), trans-vaginal.

Introduction:

Ovarian cancer is a lethal malignancy within the category of gynaecological malignancies. In Egypt, ovarian cancer accounted for 2.2 percent of all newly diagnosed cancers and 4.4 percent of newly diagnosed female cancers (1). Pelvic ultrasonography is frequently performed in either symptomatic and asymptomatic women of reproductive as well as menopausal ages. Although pelvic ultrasonography has a high sensitivity for detecting adnexal masses, it has a lower specificity for diagnosing cancer (2). The imaging properties of adnexal lesions vary depending on whether they are completely cystic, solid, or cystic with solid components. Some cystic lesions have septations, bleeding, or thick walls. Whether a malignant lesion is solid-only or contains both solid and cystic components, its imaging characteristics vary. In ovaries, it is difficult to distinguish benign from malignant lesions (3). Based on the sonographic characteristics of the lesions, GI-RADS classification provides a wealth of information as well as an estimated risk of malignancy (4). This system possessed a number of ultrasonic morphological and clinical characteristics. According to laterality, echogenicity, solid components, wall thickness, solid papillary projections, presence of ascites, and intra-lesional color doppler flow, the GI-RADS classification ranges from GI-RADS 1 to GI-RADS 5, and a higher level indicates that the mass is more likely malignant (5,6).

Elastography is an innovative non-invasive imaging technique that measures tissue stiffness based on differences in the elasticity of different tissues (7,8). When compressed, stiff tissues deform or strain less than soft tissues, as measured qualitatively by a color-coded map and quantitatively by strain ratio (9,10).

Methods

Study population

This prospective cross-sectional study was conducted on 40 patients in the period from 1st October 2022 to the end of January 2023, after approval of ethical committee of our institution. Written informed consent was approved by all patients. Privacy was considered for all patients' data.

Inclusion criteria

Patients with suspected malignant adnexal masses based on clinical and/or laboratory findings as elevated tumor markers (as CA125), patients with indeterminate ovarian lesions in ultrasonography, and patients with malignant ascites in aspiration cytology.

Exclusion criteria:

Space 5 degree :[21DS]Comment

Need correction :[22DS]Comment

Remove :[23DS]Comment

Patients who refused to perform the examination, Virgins and patients with vaginal atresia were excluded from performing transvaginal examination and underwent transabdominal technique, as well as patients with bilateral ovarian masses infiltrating the pelvic walls (because in these patients there wasn't a normal pelvic tissue to be as a reference for performing the strain ratio).

All patients were subjected to the following:

Complete history taking of symptoms as abdominal mass, pelvic pain, irregular vaginal bleeding, full clinical examination by clinician of 16 years' experience in gynecological oncology field and laboratory investigations of tumor markers (CA125), inflammatory markers as (CRP, ESR). Radiological assessment using aplio XG system, as follows; transabdominal and transvaginal ultrasound including grey scale, color doppler and pulsed doppler study. All parameters were adjusted as follows; dynamic range 4; frame rate M; smoothing 2; density 2; noise rejection 2; Persistence 6; frame rejection 4. Color overlays were used to represent the malformation on the B-mode images. Then, the scanner was switched into elastographic mode. Greyscale sonogram and elastogram images were displayed simultaneously in the dual mode. Local strain was achieved by freehand technique with vertical compressions–decompressions. The quality of compression was indicated on a scale between 1 and 7 using a quality feedback bar. At least five bars of the indicator should be active for optimal compression. Tissue stiffness was displayed on a color-coded map where red areas indicate soft tissue parts; green areas indicate intermediate and blue areas indicate hard-tissue parts. All static images were recorded and stored in the local sonography device for later review. Transabdominal and transvaginal sono-elastography were performed for all studied cases with assessment of (color code maps and strain ratios). All patients' pelvises were examined by transabdominal ultrasound in the supine position using a 3.75-MHz sector transducer and transvaginal ultrasound in lithotomy position using endo-vaginal transducer, in transverse and longitudinal plane, the left hand was used to hold the anterior pelvic wall, while the right hand was used to compress the lesion. The color scale, which ranged from blue to red, indicating the relative stiffness or + softness of tissue within the region of interest (ROI) as a whole: Green represented tissue with an average strain, dark blue represented hard tissue, light blue represented moderately hard tissue, yellow represented moderately soft tissue, and red represented the soft tissue. Trans-abdominal and trans-vaginal strain ratios were calculated for all lesions. For standardized calculations, the first region of interest (ROI) was placed on a reference tissue part as the softest area coded as red (E1)

What this numbers mean ?? :[24DS]Comment

adjacent to the lesion. The second ROI was positioned over the entire lesion region (E2). The placement of ROIs was performed during the sono-elastography examination of patients. Strain ratio (E2/E1) was automatically calculated by the scanner, and stored DICOM images were reviewed and analyzed by two radiologists with 3 and 12 years of experience in female imaging, respectively, before final decisions were made by a professor with 25 years of experience in the field of female imaging. All cases were analyzed and categorized regarding their morphological and elastographic findings, by Gynecologic Imaging Report and Data System (GI-RADS) classification system. GI-RADS 1: Definitive benign (Normal ovaries identified and no adnexal mass seen), GI-RADS 2: Very probably benign, GI-RADS 3: Probably benign, GI-RADS 4: Probably malignant, GI-RADS 5: Very probably malignant.

Statistical analysis

The IBM SPSS software version 28.0 was used to analyze the obtained data. Use of numbers and percentages was used to describe qualitative data in this study. Mean, standard deviation, median, and interquartile range (IQR) were used to summarize quantitative data (IQR). The obtained data were given a significant level of 5%. The used tests were Chi-square test For categorical variables, Monte Carlo test, Student t-test For normally distributed quantitative variables, Mann Whitney test For abnormally distributed quantitative variables, Receiver operating characteristic curve (ROC) for assessing the diagnostic performance.

Results:

The study included 40 females who were referred for evaluation of indeterminate ultrasonographic findings for adnexal lesions, suspected ovarian tumors, elevated tumor markers for ovarian cancers as CA125, for characterization of lesions and assessment of their elasticity.

Regarding the patients' sociodemographic and clinical data. The patients' age ranged from 28 to 72 years old, with a mean of 48.6 ± 12.96 years. Regarding comorbidities, 12 patients (30%) were diabetics, 16 patients (40%) had hypertension, and 18 patients (45%) had dyslipidemia. Twenty-eight patients (70%) were postmenopausal. The age of menarche ranged from 10 to 16 years, with a median of 13 years old. Ten patients were asymptomatic (25%) and discovered incidentally, 14 patients (35%) complained of vaginal bleeding, 6 patients (15%) complained of pelvic pain, 4 patients (10%) had low back pain, and 6 patients (15%) had abdominal swelling, change in bowel habits, and infertility (two patients each), as shown in (table 1).

Table (1):Distribution of the studied cases according to demographic data

Demographic data (n=40)	No.	%
Age (years)		
Min. – Max.	28 – 72	
Mean ± SD.	48.6 ± 12.96	
Median (IQR)	49 (39.5 – 62.5)	
Comorbidities (n = 40)		
Diabetics	12	30
Hypertension	16	40
Dyslipidemia	18	45
Menopause (n = 40)		
Yes	28	70
No	12	30
Age of menarche (years)		
Min. – Max.	10– 16	
Mean ± SD.	13.6 ± 2.7	
Median (IQR)	13 (14 – 14.5)	
Laterality (n = 40)		
Unilateral	30	25
Bilateral	10	75
Complaint		
Abdominal swelling	2	5.0
Asymptomatic	10	25.0
Vaginal bleeding/menorrhagia	14	35.0
Change of bowel habits	2	5.0
Infertility	2	5.0
Low back pain	4	10.0
Pelvic pain / heaviness	6	15.0
Risk factors		
Early menopause	4	10.0
Family history	8	20.0
Long term hormonal therapy	2	5.0

Nullipara	6	15.0
Obesity	10	25.0
Smoking	6	15.0
None	4	10.0

Comparison between ultrasound data of benign and malignant masses revealed no detectable statistically significant differences between benign and malignant masses regarding ultrasound consistency (p-value=0.17), while there was a statistically significant difference in the criteria of cystic masses (p-value<0.001*), with higher frequency of thick septations and nodular soft tissue. Also, significant difference was shown in the Doppler appearance (p-value<0.001*), with higher frequency of high/moderate grade and central location of vascularity in malignant masses. However, no statistically significant difference was found in the mean values of RI (p-value=0.1). Concerning GI-RADS classification, malignant lesions were most commonly diagnosed as GI-RADS V lesions (p-value<0.001*). All cases of ascites and pathologically enlarged lymph nodes were those having malignant lesions, as mentioned in (table 2).

Table (2):Comparison between benign and malignant masses in the ultrasound finding.

	Mass		Test of sig.	P
	Benign (n = 16)	Malignant / Borderline Malignant (n = 24)		
Consistency				
Cystic / mixed cystic	12 (75)	22 (91.7)	$\chi^2=1.88$	0.17
Solid	4 (25)	2 (8.3)		
Criteria of cystic/mixed cystic masses				
No	4 (25)	0 (0)	$\chi^2=21.06$	<0.001*
Nodular soft tissue	4 (25)	20 (83)		
Thin septations	4 (25)	0 (0)		
Thick septations	0 (0)	14 (58.3)		
Vascularity				

Degree	High	0 (0)	10 (83)	$\chi^2=17.1$	<0.001*
	Moderate	2 (12.5)	4 (33.3)		
	Mild	8 (50)	2 (8.3)		
Site	Central	2 (12.5)	22 (91.7)	$\chi^2=16.7$	<0.001*
	Peripheral	14 (87.5)	2 (8.3)		
Resistive index					
Mean \pm SD.		0.35 \pm 0.14	0.46 \pm 0.15	t = 1.6	0.1
GIRAD classification					
III		12 (75)	0 (0)	$\chi^2=15.3$	<0.001*
IV		4 (25)	4 (17)		
V		0 (0)	20 (83)		
Associated findings					
Ascites	Mild	0 (0)	8 (20)	--	
	Moderate	0 (0)	6 (15)		
Enlarged pelvic lymph nodes		0 (0)	14 (35)		

N= number, %= percentage, t: Student t-test, χ^2 : Chi-square test, SD: Standard deviation, *: Statistically significant at $p \leq 0.05$

On comparison between sono-elastography data of benign and malignant lesions, there were statistically significant differences in the distribution of transabdominal and transvaginal color pattern (p-value<0.001*), with malignant lesions most commonly showing higher scores of color pattern (scores 4,5). Significantly lower mean transabdominal (p-value=0.031*) and transvaginal (p-value=0.02*) SR values were noted in patients with malignant lesions, as mentioned in (table 3).

Table (3):Comparison between benign and malignant lesions regarding sono-elastography findings.

	Masses (total number 40)		Test of sig.	P
	Benign (n = 16)	Malignant / Borderline Malignant (n = 24)		
Elasticity score (transabdominal): n (%)				

1	6 (37.5)	0 (0)	$\chi^2=12.4$	<0.001*
2	2 (12.5)	2 (8.3)		
3	4 (25)	6 (25)		
4	2 (12.5)	6 (25)		
5	2 (12.5)	10 (41.6)		
Elasticity score (transvaginal): n (%)				
1	6 (37.5)	0 (0)	$\chi^2=14.9$	<0.001*
2	6 (37.5)	2 (8.3)		
3	4 (25)	4 (16.7)		
4	0 (0)	6 (25)		
5	0 (0)	12 (50)		
Strain ratio (transabdominal)				
Mean ± SD.	4.95 ± 2.24	3.1 ± 1.3	t = 1.85	0.031*
Strain ratio (transvaginal)				
Mean ± SD.	5.98 ± 2	3.94 ± 1.6	t = 2.5	0.02*

Regarding the distribution of GIRAD scores of the studied lesions. Most of benign lesions were of GIRADs III (12 patients; 75%) and, less commonly IV (4 patients; 25%) that were 2 ovarian fibromas and 2 broad ligament fibroids (due to their higher elasticity scores and more tissue hardness than other benign tumors), while malignant masses were mainly of GIRADs V (20 patients; 83.2%) and less commonly IV (4 patients; 16.8%), as mentioned in (table 4).

Table (4): Distribution of the pathological diagnosis of the studied masses according to GIRADs (n = 40)

Pathological Diagnosis	GIRADS			Total	Percentage
	GIRADS III	GIRADS IV	GIRADS V		
*Benign					
Serous cystadenoma	2	0	0	2	5%

Mucinous cystadenoma	2	0	0	2	5%
Dermoid cyst	4	0	0	4	10%
Hydrosalpinx	2	0	0	2	5%
Ovarian fibroma	0	2	0	2	5%
Broad ligament fibroid	0	2	0	2	5%
Endometrioma	2	0	0	2	5%
*Borderline epithelial Neoplasms	0	2	2	4	10%
*Malignant					
Serous cystadenocarcinoma	0	0	6	6	15%
Mucinous cystadenocarcinoma	0	2	4	6	15%
Krukenberg tumor	0	0	2	2	5%
Clear cell carcinoma	0	0	2	2	5%
Germ cell tumor	0	0	2	2	5%
Endometroid carcinoma	0	0	2	2	5%
*Total	12	8	20	40	100%

t: Student t-test, χ^2 : Chi-square test, SD: Standard deviation, *: Statistically significant at $p \leq 0.05$, N= number, %= percentage,

Concerning tissue types by final histopathological results, the benign masses were serous cystadenoma (2 masses; 5%), mucinous cystadenoma (2 masses; 5%), dermoid cyst (4 masses; 10%), hydrosalpinx, ovarian fibroma, broad ligament fibroid and endometrioma (8 masses, 5% of each), Meanwhile, the malignant masses, serous and mucinous cystadenocarcinoma (6 masses each; 15%), Krukenberg tumor, Clear cell carcinoma, Germ cell tumor, and Endometroid carcinoma (2 patients each; 5%), as shown in Table (5).

Table (5): Final histopathological diagnosis of the studied lesions

Final Histopathological data	No.	%
Pathological classification of the lesions		
Benign	16	40
Borderline	4	10
Malignant	20	50
Final pathological diagnosis of the adnexal masses		

Benign	Serous cystadenoma	2	5
	Mucinous cystadenoma	2	5
	Dermoid cyst	4	10
	Hydrosalpinx	2	5
	Ovarian fibroma	2	5
	Broad ligament fibroid	2	5
	Endometrioma	2	5
Borderline	Borderline epithelial tumors	4	10
Malignant	Serous cystadenocarcinoma	6	15
	Mucinous cystadenocarcinoma	6	15
	Krukenberg tumor	2	5
	Clear cell carcinoma	2	5
	Germ cell tumor	2	5
	Endometroid carcinoma	2	5

Correlation analysis was performed and revealed a statistically significant relation between the GIRADS score and the transabdominalelastography ($p=0.002^*$) and transvaginal elastography ($p=0.001^*$), with ROC curves demonstrates the correlation between GIRADS and TA SR as well as TV SR respectively, as shown in Table 6 and figures 1,2.

Table (6):Correlation between GIRADs and other parameters (RI, SR)

	GIRADS	
	R	P
RI	0.29	0.21
SR (TA)	0.55	0.002*
SR (TV)	0.64	0.001*

R: Pearson correlation coefficient, **P-value** is a value for statistically significant difference, *: Statistically significant at $p \leq 0.05$, **RI**= Resistive index, **SR**= Strain ratio, **TA**= Trans-abdominal, **TV**= Trans-vaginal

Figure (1):ROC (Receiving operating curve) demonstrate the correlation between GIRADs and SR (TA)

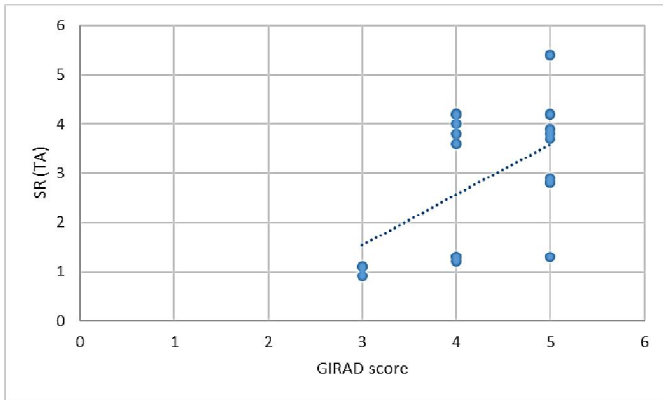
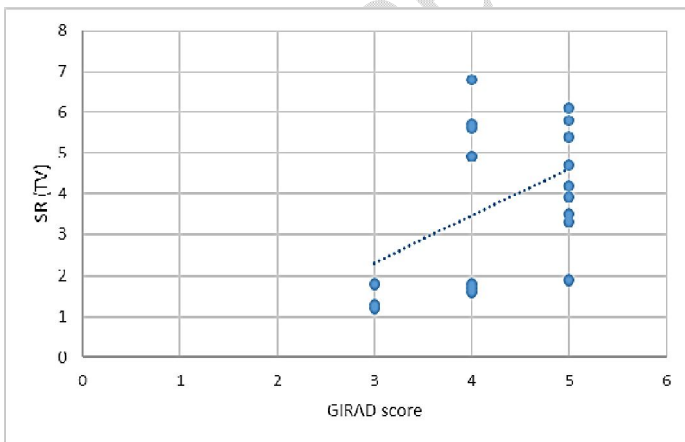


Figure (2):ROC (Receiving operating curve) demonstrate the correlation between GIRADs and SR (TV)



There was substantial kappa agreement between sono-elastography and pathological diagnosis= 0.783 and P-value (<0.001*). ROC curve analysis to assess the diagnostic values of SR (TA), SR (TV), and RI to predict the malignant cases. SR (TA) and SR (TV) showed statistically significant performance in diagnosis of malignant patients ($p=0.014^*$ and

0.007*). SR (TV) showed the highest AUC (0.87), sensitivity (93%), and specificity (91%), followed by SR (TA) that had AUC (0.83), sensitivity (83%), and specificity (88%), the cut-off value of malignancy for SR (TA) = 3.85 and cut-off value of malignancy for SR (TV) = 4.75), as mentioned in (table 7 and figures 3 and 4).

Table (7): The diagnostic performance and cut-off values of SR (TA), SR (TV) and RI of adnexal masses.

	AUC	p	95% C.I.	Cutoff	Sensitivity	Specificity
SR (TA)	0.83	0.014*	1-0.65	3.85	83%	88%
SR (TV)	0.87	0.007*	1-0.68	4.75	%93	%91
RI	0.67	0.22	0.41-0.92	0.41	77%	63%

AUC: Area under curve, *: Statistically significant at $p \leq 0.05$, C.I.: Confidence intervals, RI= Resistive index, SR= Strain ratio, TA= Trans-abdominal, TV= Trans-vagina

Figure (3):ROC (Receiving operating curve) for SR (TA)'s diagnostic performance to discriminate malignant from benign lesions.

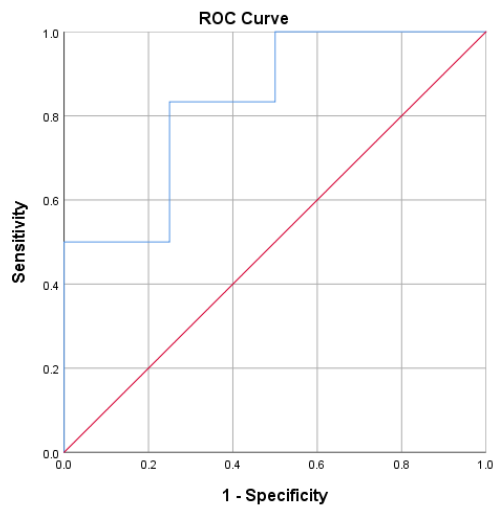


Figure (4):ROC (Receiving operating curve) for SR (TV)'s diagnostic performance to discriminate to discriminate malignant from benign lesions.

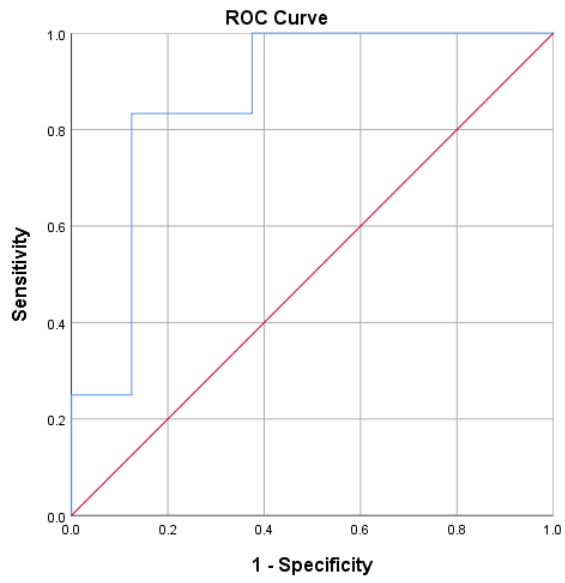
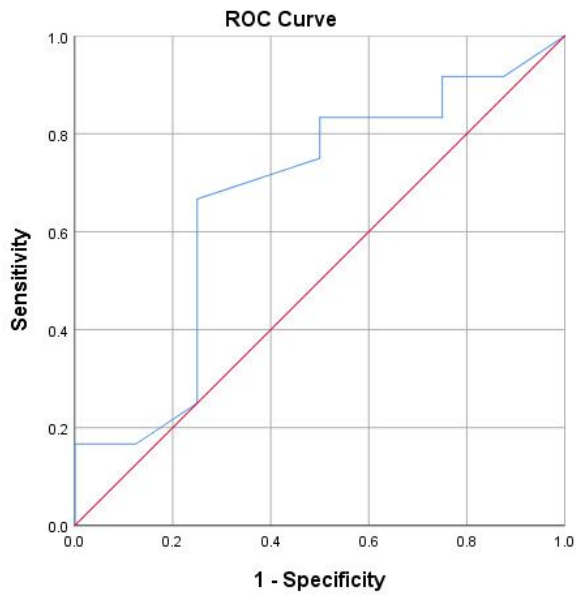


Figure (5):ROC (Receiving operating curve) for RI's diagnostic performance to discriminate malignant from benign lesions.



Discussion

In obstetrics and gynecology, ultrasound is the most often utilized imaging diagnostic modality. Examination of a suspected pelvic mass, identification of endometrial abnormalities in a patient with postmenopausal hemorrhage, and characterization of ovarian lesions are currently the most important uses of ultrasound in gynecological oncology⁽¹¹⁾.

Based on ultrasonographic findings of patients with adnexal lesions, several studies have proposed various scoring systems such as logistic regression models, examiner's subjective impression, mathematically developed scoring systems, and Gynecologic Imaging Reporting and Data System (GI-RADS)⁽¹²⁾.

Elastography has played an important role in assessment of gynecological lesions due to its ease of use, noninvasiveness, and consistency. Notably, elastography techniques can identify changes in tissue compressibility produced by specific clinical or physiological events.⁽¹³⁾ All elasticity testing and imaging procedures primarily involve mechanical excitation and monitoring of tissue response⁽¹³⁾.

This cross-sectional study that was carried out at the Radio diagnosis Department, Tanta University Hospital. The patients' age ranged from 28 to 72 years old, with a mean of 48.6 ± 12.96 years. Our data were close to the previously reported patients' age as in the study of **Sakr et al. (2020)**⁽¹⁴⁾, where the age of patients ranged from 21 to 66 years, with a mean age of 46.6 ± 10.3 years old, as most adnexal masses occur at the reproductive age.

Comparing the demographic data of patients, the present study revealed that patients with malignant / borderline malignant masses had significantly older mean ages (55.6 ± 9.8 years old versus 38 ± 9.8 years old in patients with benign masses, $p\text{-value}=0.001^*$) and were predominately postmenopausal females.

In agreement with our findings, **Zhou et al. (2019)**⁽¹⁵⁾ who retrospectively analyzed 224 patients with ovarian tumors and found that patients with benign adnexal masses aged 42 ± 14.68 years & those with malignant masses aged 53 ± 12.73 years. (**National Cancer Institute, 2022**)⁽¹⁶⁾ reported also that age is an important risk factor for gynecological malignancies, and mostly associated with the menopausal state and its hormonal disturbances.

A statistically significant difference was also shown in the distribution of other risk factors ($p\text{-value}=0.003^*$). Patients with malignant / borderline neoplasms had higher

incidence of positive family history (25% versus. 12.5%), hormonal therapy (41.7% versus. 0%), nullipara (25% versus. 0%), and smoking (16.7% versus. 12.5%).

These findings are consistent with the American Society of Clinical Oncology's assertion (**Murakami et al. 2020**)⁽¹⁷⁾ who reported that inherited disorders account for around 10 percent of gynecologic malignancies.

The significant association between smoking and ovarian malignancy was also found by the recent study of **Lycke et al. (2021)**⁽¹⁸⁾. A rising number of research as (**Faber et al., 2013**)⁽¹⁹⁾ had evaluated cigarette smoking as a potential ovarian cancer risk factor. The biggest link appears to be with mucinous ovarian cancers, however other studies have found an increased incidence of serous ovarian tumors and borderline mucinous tumors among smokers.

Concerning GIRADS classification, in the present study; most benign lesions (75%) were GIRADS III, while majority of malignant masses (83%) were GIRADS V, (p-value<0.001*). Prior research has highlighted the need of adopting a synoptic reporting tool for the effective treatment of adnexal lesions. However, a non-structured reporting system may result in unwarranted concern for both clinicians and patients (**Behnamfar et al., 2019**)⁽²⁰⁾. In this study, the utility of recently developed so-called GI-RADS system in this field have been evaluated.

Meanwhile, in the current study a comparison between sono-elastography data of benign and malignant lesions explored that there were statistically significant differences between transabdominal and transvaginal color pattern (p-value<0.001*), with malignant lesions most commonly showing higher scores of color pattern than benign lesions.

Similar findings of sono-elastography in diagnosis of malignant masses was identified by Stasiv et al. (2021) who reported that trans-vaginal elastography is more sensitive and accurate than trans-abdominal in O-RADS classification of ovarian lesions, because to its higher transducer frequency, greater tissue resolution, and proximity to pelvic organs⁽²¹⁾.

Regarding the pathological diagnosis of the studied lesions; half of masses were malignant (50%). In accordance with our findings, **RAI et al. (2019)**⁽²²⁾ found that ovarian epithelial tumors were the most commonly prevalent adnexal masses. the prevalence of malignant ovarian lesions was 19.3%. Also, **Javdekar et al. (2015)**⁽²³⁾ reported a prevalence rate of 9.5%.

Correlation analysis was performed and revealed a statistically significant relation between the GIRADS score and the transabdominalelastography ($p=0.002^*$) and transvaginal elastography ($p=0.001^*$), this correlation empathized the accuracy and diagnostic performance of both TA and TV sono-elastography in the diagnosis of adnexal masses. In view of our knowledge, no previous studies assessed such a correlation.

Conclusions:

The GI-RADS is a helpful reporting system that improve language communication between radiologists and physicians, that raise and improve the clinical decision-making and patient care. Trans-vaginal elastography has higher sensitivity, specificity, accuracy than trans-abdominal elastography in assessment of adnexal masses, with SR cut-off values between benign and malignant lesions, SR (TA)=3.85, SR(TV)= 4.75 .

Limitations:

This work was limited by the relatively small sample size. However, according to our knowledge our study is the first to assess the performance of trans-abdominal versus trans-vaginal sono-elastography in evaluation of adnexal masses.

Recommendation:

Elastography technique is inexpensive, simple in use, non-invasive, does not consume plenty of time in the routine study, safe, so we recommend it as a routine technique in sonographic evaluation of adnexal masses. additional multicenter studies on a large geographical scale and with larger sample sizes are also required to provide better insight into the diagnostic performance of elastography.

List of abbreviations:

- **GI-RADS**= Gynecologic Imaging Reporting and Data System, **RI**= Resistive index, **SR**= Strain ratio, **US**= Ultrasonography, **TA**= Trans-abdominal, **TV**= Trans-vaginal, **AUC**= Area under curve, *****= Statistically significant at $p \leq 0.05$, **C.I.**= Confidence interval,

References:

1. Gharib MA, El-Shoeiby MH, Metwally NM, et al. Epidemiology of ovarian cancer in Assiut Governorate, Egypt. International Journal of Reproduction, Contraception, Obstetrics and Gynecology. 2018; 7 (11): 4575-4581.

remove :[25DS]Comment

2. Tehranian A, Ghahghaei-Nezamabadi A, Seifollahi A, et al. Ovarian mature cystic teratoma with malignant transformation: two case reports. *Journal of Medical Case Reports*. 2021; 15(1): 1-6.
3. Andreotti RF, Timmerman D, Benacerraf BR, et al. Ovarian-adnexal reporting lexicon for ultrasound: a white paper of the ACR Ovarian-Adnexal Reporting and Data System Committee. *Journal of the American College of Radiology*. 2018 Oct1;15(10):1415-29.
4. Khalaf LM, Desoky HH, Seifeldein GS, et al. The diagnostic efficacy of Gynecology Imaging Reporting and Data System (GI-RADS): single-center prospective cross-sectional study. *Egyptian Journal of Radiology and Nuclear Medicine*. 2019; 50 (1): 1-9.
5. Guo W, Zou X, Xu H, Zhang T, et al. The diagnostic performance of the Gynecologic Imaging Reporting and Data System (GI-RADS) in adnexal masses. *Annals of Translational Medicine*. 2021; 9 (5). 345-352
6. Flicek KT, VanBuren W, Dudiak K, et al. Borderline epithelial ovarian tumors: what the radiologist should know. *Abdominal Radiology*. 2021 Jun;46(6):2350-66.
7. Sigrist RM, Liao J, El Kaffas A, et al. Ultrasound elastography: review of techniques and clinical applications. *Theranostics*. 2017; 7 (5): 1303.
8. Zheng H, Tie Y, Wang X, et al. Assessment of the diagnostic value of using serum CA125 and GI-RADS system in the evaluation of adnexal masses. *Medicine (Baltimore)*. 2019 Feb;98(7): e14577.
9. Varga I, Miko M, Kachlik D, et al. How many cell types form the epithelial lining of the human uterine tubes? Revision of the histological nomenclature of the human tubal epithelium. *Annals of Anatomy-AnatomischerAnzeiger*. 2019; 224: 73- 80.
10. Dietrich CF, Barr RG, Farrokh A, et al. Strain elastography-how to do it? *Ultrasound international open*. 2017; 3 (4): 137-149.
11. Crestani A, Theodore C, Levailant JM, et al. Magnetic Resonance and Ultrasound Fusion Imaging to Characterise Ovarian Masses: A Feasibility Study. *Anticancer Research*. 2020 Jul 1;40(7):4115-21.
12. Flicek KT, VanBuren W, Dudiak K, et al. Borderline epithelial ovarian tumors: what the radiologist should know. *Abdominal Radiology*. 2021 Jun;46(6):2350-66.
13. Yang JY and Qiu BS. The advance of magnetic resonance elastography in tumor diagnosis. *Front Oncol*.2021;11:722703.

rewrite the information :[26DS]Comment

14. Sakr DM, Hassan RT and Sakr LK. Role of ultrasonography in diagnosis of adnexal masses. *Sci J Al-Azhar Med Fac Girls* 2020; 4:579-85.
15. Zhou L, Xuan Z and Wang Y. Diagnostic value of ultrasound score, color Doppler ultrasound RI and spiral CT for ovarian tumors. *Oncology letters* 2019; 17: 5499-5504.
16. National Cancer Institute. Cancer Stat Facts: Ovarian Cancer. SEER. Available online at: <https://seer.cancer.gov/statfacts/html/ovary.html> (accessed on January 28, 2022).
17. Murakami K, Kotani Y, Nakai H, et al. Endometriosis-associated ovarian cancer: The origin and targeted therapy. *Cancers*. 2020; 12(6): 1676.
18. Lycke M, Ulfenborg B, Lauesgaard JM, et al. Consideration should be given to smoking, endometriosis, renal function (eGFR) and age when interpreting CA125 and HE4 in ovarian tumor diagnostics. *Clinical Chemistry and Laboratory Medicine (CCLM)*. 2021 Nov 1;59 (12):1954–62.
19. Faber MT, Kjær SK, Dehlendorf C, et al. Ovarian Cancer Association Consortium. Cigarette smoking and risk of ovarian cancer: a pooled analysis of 21 case-control studies. *Cancer Causes Control*. 2013 May;24(5):989-1004.
20. Benhamfar, Fariba, et al. Diagnostic accuracy of gynecology imaging reporting and data system in evaluation of adnexal lesions. *Journal of Research in Medical Sciences*. June 2019; 24 (1):57
21. Stasiv, Iryna. The Use of Compression Sono-elastography in Multiparametric Ultrasound Examination in Cases of Benign Ovarian Formations. *Journal of Education, Health and Sport*. 2021, 11.10: 229-241.
22. Rai R, Bhutia PC and Tshomo U. Clinicopathological profile of adnexal masses presenting to a tertiary-care hospital in Bhutan. *South Asian J Cancer*. 2019 Jul-Sep;8(3):168-172.
23. Javdekar R and Maitra N. Risk of malignancy index (RMI) in evaluation of adnexal mass. *J ObstetGynaecol India*. 2015; 65:117–21.

all references should be in one :[27DS]Comment style

Appendix:

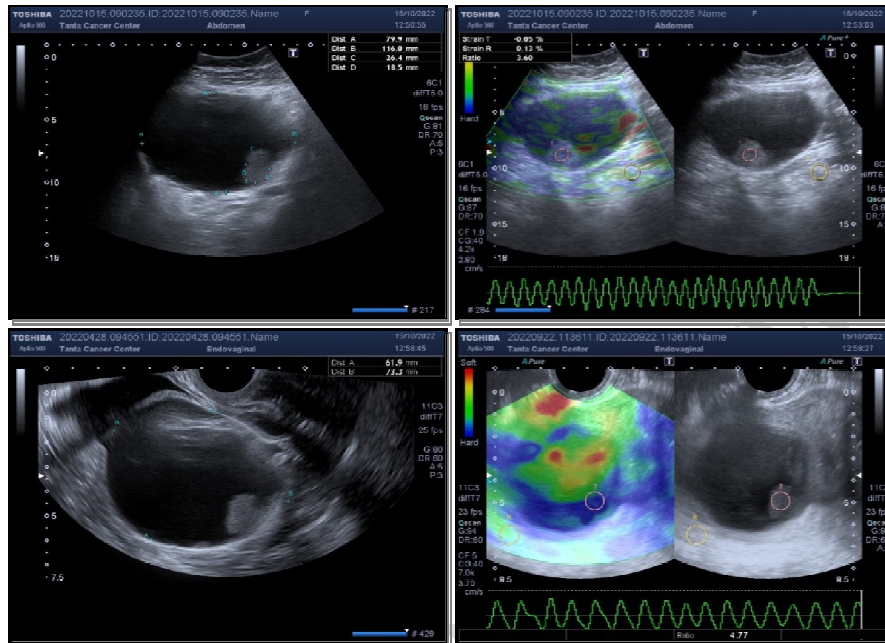


Plate 1: A seventy-two years old female patient complained of post-menopausal vaginal bleeding, progressive abdominal enlargement for 5 months.

TA B-mode ultrasound image (A) shows well-defined cystic lesion measuring 7.9 X 11.6 cm. shows peripheral nodularity with soft tissue solid component measures about 2.6x1.8cm, TA elastogram color coded map (B) shows that the lesion had an elasticity score of 4 and strain ratio was 3.6. TV B-mode ultrasound image (C) shows well-defined cystic lesion with peripheral nodularity of soft tissue solid component. TV elastogram color coded map (D) shows that the lesion had an elasticity score of 3 and strain ratio was 4.7.

Radiological sono-elastography diagnosis was suspicious looking ovarian lesion (GIRADS IV). Confirmed by histopathological results to be clear cell carcinoma)

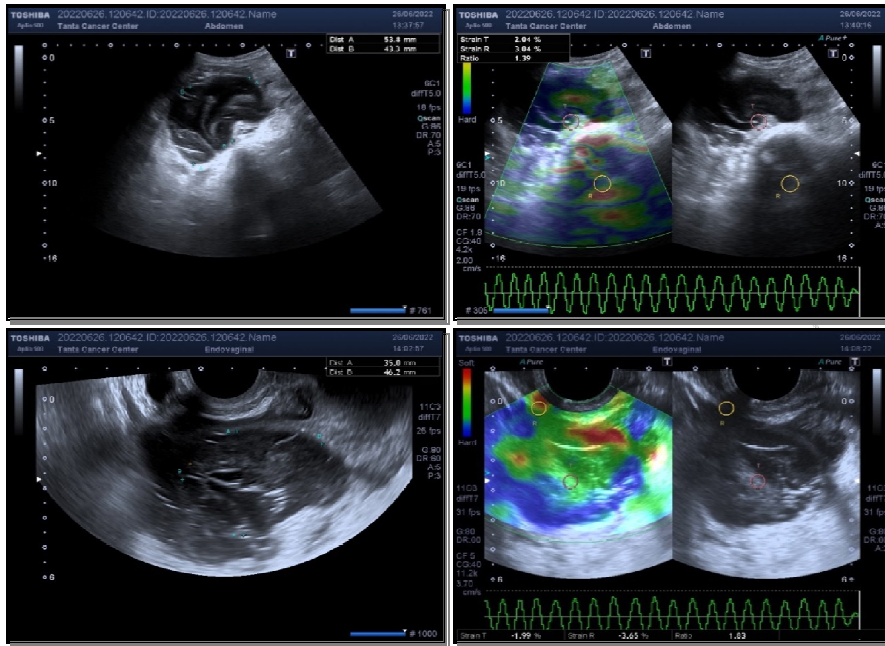


Plate 2: A twenty-nine years old female patient complained of infertility.

TA B-mode ultrasound image(A) shows well-defined complex cystic and solid lesion showing multiple thick septation measuring 5.3x4.3 cm. TA elastogram color coded map(B) shows that the lesion had an elasticity score of 3 and strain ratio was 1.3. TV B-mode ultrasound image(C) shows well-defined complex cystic and solid lesion. TV elastogram color coded map(D) shows that the lesion had an elasticity score of 2 and strain ratio was 1.8.

Radiological diagnosis was benign looking lesion likely dermoid cyst (GIRADS III) and confirmed by histopathology to mature cystic teratoma).

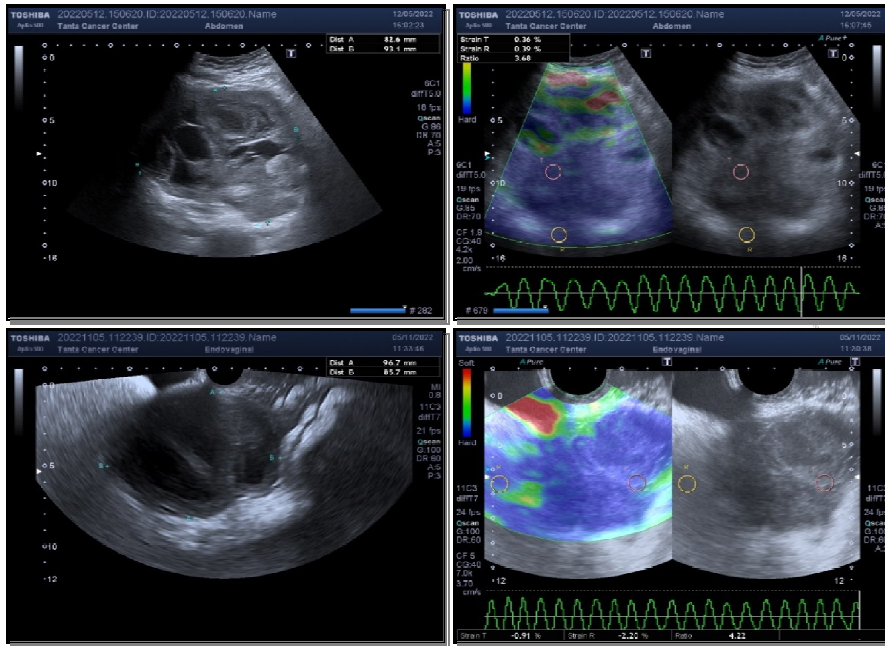


Plate 3: A sixty-nine years old female patient complaining of vaginal bleeding & low back pain.

TA B-mode ultrasound image (A) shows well-defined iso-echoic soft tissue lesion with internal hypoechoic cystic changes measuring 8.2x9.3 cm. TA elastogram color coded map (B) shows that the lesion had an elasticity score of 5 and strain ratio was 3.6. TV B-mode ultrasound image (C) shows well-defined iso-echoic soft lesion. TV elastogram color coded map (D) shows that the lesion had an elasticity score of 5 and strain ratio was 4.2. **Radiological diagnosis** was highly suspicious looking lesion (GIRADS V) and confirmed to be malignant cystadenocarcinoma by biopsy.

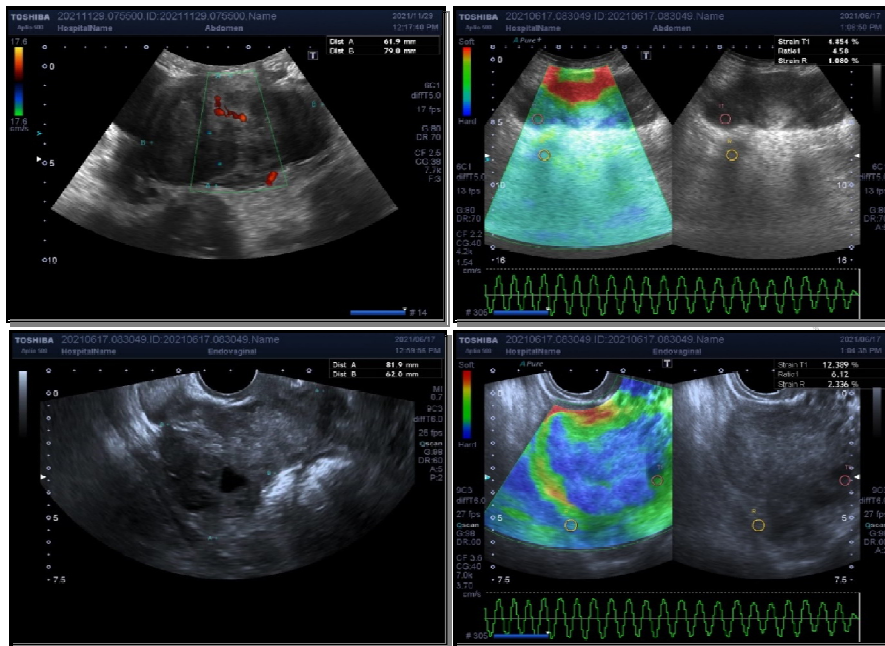


Plate 4: A sixty-five years old female patient with history of pelvic mass and pain for 3 months.

TA B-mode ultrasound image (A) shows ill-defined soft tissue solid adenaxial mass lesion with internal hypoechoic cystic changes and areas of breakdown, it is measuring 6.1x7.9 cm. TA elastogram (B) shows that the lesion had an elasticity score of 4 and strain ratio was 4.5. TV B-mode ultrasound image (C) shows ill-defined soft tissue mass lesion with internal cystic changes. TV elastogram (D) shows that the lesion had an elasticity score of 5 and strain ratio was 6.1.

Radiological diagnosis was highly suspicious looking lesion (GIRADS IV), confirmed to be krukenburg tumor.

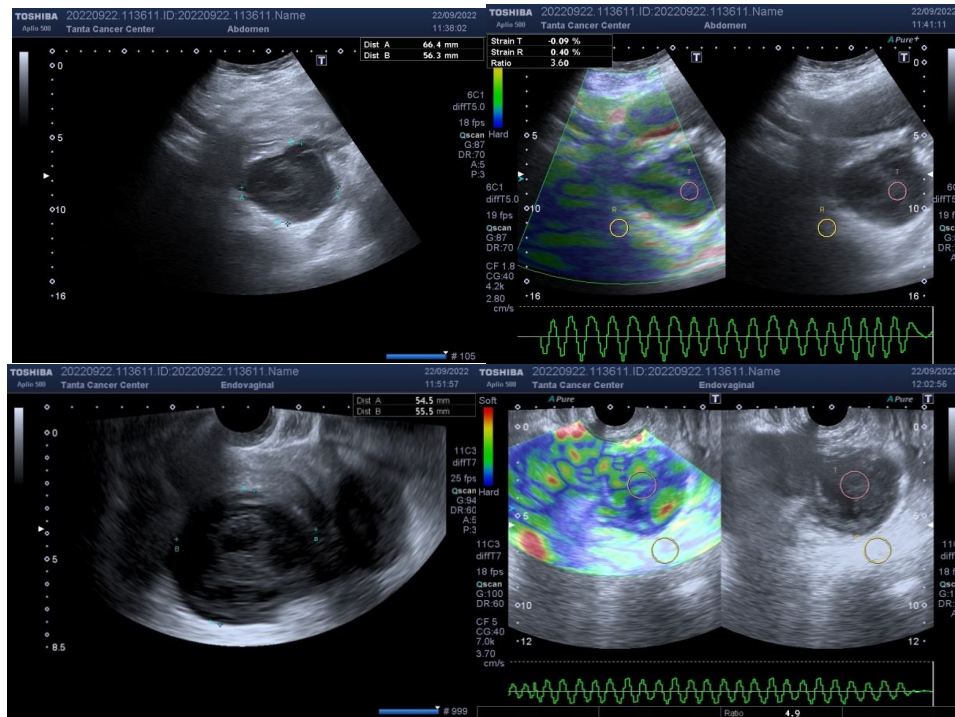


Plate 5: A fifty-four years old female patient pelvic pain with vaginal bleeding and pelvic pain.

TA B-mode ultrasound image **(A)** shows well-defined rounded hypo echoic soft tissue lesion measured 6.6x5.5 cm in the left adnexal region. TA elastogram **(B)** shows that the lesion had an elasticity score of 3 and strain ratio was 3.6. TV B-mode ultrasound image **(C)** shows well-defined rounded hypo echoic soft tissue lesion measures about 5.4x5.5 cm. TV elastogram **(D)** shows that the lesion had an elasticity score of 4 and strain ratio was 4.9.

Radiological diagnosis: benign looking lesion with high elasticity score and high strain ratio (?? fibrous tissue with less compressibility). Final histo-pathological diagnosis confirmed to broad ligament fibroid.