

# Case report

## EFFECT OF OZONE THERAPY ON PAIN AND MOUTH OPENING AFTER THIRD MOLAR SURGERY: CASE REPORT

---

### ABSTRACT

**Objectives:** The aim of this study was to evaluate the efficacy of ozone therapy in reducing pain and its effect on mouth opening after third molar surgery.

**Case presentation:** The cases reported in this paper are part of a randomized, triple-blind, "split-mouth" clinical study, where surgery was performed using the conventional technique on one side (G1- Control Group), and using ozone therapy on the other side (G2- Test Group), as a means of comparison. In this study, five patients were selected with indications for bilateral extraction of lower third molars with similar positions, and who did not present characteristics of infection. In the immediate preoperative period, pain levels were assessed using the VAS scale and mouth opening using a pachymeter; this was repeated in the immediate postoperative period and after 72 hours. The patient's perception of pain, mouth opening and analgesic intake were assessed.

**Results:** Ozone therapy (G2) reduced postoperative pain, reduced the intake of analgesics and achieved better control of mouth opening when compared to the conventional technique (G1).

**Conclusion:** Ozone therapy can be an effective, biocompatible and safe alternative for pain control and mouth opening after third molar surgery, helping to improve patients' quality of life and bringing new perspectives to dentistry. However, due to the small sample size, it is very important to carry out more clinical studies on the subject.

*Keywords: Odontology, Ozone Therapy, Third Molar, Pain, Oral Surgery.*

### 1. INTRODUCTION

Third molar extraction is the most common surgical procedure performed by specialists in Oral and Maxillofacial Surgery and Traumatology [1]. All surgical procedures in themselves are traumatic, as they damage structures and remove substances [2]. And this surgical trauma naturally leads to a post-operative inflammatory process, with the release of chemical mediators of pain and inflammation, which clinically present as edema and/or trismus, as well as pain. The pain, which is normally controlled with analgesics and anti-inflammatory drugs, starts soon after extraction, when the local anesthetic stops working, and tends to subside after the third day [3].

In this context, and with an ever-increasing view to reducing drug consumption and providing comfort to patients, ozone therapy has emerged as a method that has been approved for use in dentistry since 2015 by the Federal Council of Dentistry in Brazil, and which is based on the action of a gaseous mixture of ozone and oxygen for various therapeutic purposes. Ozone therapy triggers many actions in the body, such as: improving angiogenesis; increasing blood oxygenation to tissues; increasing the amount of cellular antioxidant enzymes; reducing inflammatory mediators; modulating

the immune system through neutrophil activation and releasing cytokines. In this way, it is able to reduce immunological mediators of pain and eliminate microorganisms that can cause infections [4,5,6,7].

In oral surgery, ozone can be administered in various forms (gas, water and oil) and concentrations, which will be determined according to the objective to be achieved. Ozone gas is produced by a specific generator, which converts pure oxygen into ozone by means of a gauntlet which, coupled to the generator, releases the gas into a syringe for subsequent application to the patient. Ozone gas can be applied systemically (sublingually or auricularly) or locally (subcutaneous, intramuscular or intra-alveolar infiltration [8,9].

The best-known liquid form, ozonated water, is produced by a specific generator connected to a medical oxygen cylinder that produces ozone gas and takes this gas to the ozonation column, containing a device that bubbles the ozone gas into the water and stores it in a glass container [9,10]. It can be used for antiseptics, mouthwash and irrigation [9,11,12]

Another widely used form is the oily form. Ozonated oil is produced by a specific generator, which bubbles ozone gas into vegetable oil, such as olive or sunflower oil. It is available ready to use, sold by specialized manufacturers. In third molar surgery, ozonized oil can be applied to the operated area or to mucosal lesions [9,12].

Regarding the risks of using ozone therapy, Bastos et al. (2022) reported in a systematic review that it is a safe treatment method, as no complications were reported in the studies evaluated. In addition, they highlight ozone's biocompatible characteristics, its wide applicability and its low cost. And studies show that ozone therapy is painless and non-invasive, and that it is well accepted by patients [13].

This work is a series of cases that make up a clinical study, authorized by the Research Ethics Committee, under registration number 4.138.244 (caae:32833420.5.0000.5053), and which is being carried out in the Dentistry course at the Federal University of Ceará - Sobral Campus, with the aim of evaluating the effectiveness of ozone therapy in reducing pain and the effect on mouth opening after third molar surgery.

## **2. PRESENTATION OF CASES**

We selected a sample of 5 patients, both men and women, treated in the extension project "Project O3 - Ozone Therapy applied to Dentistry", in the Dentistry course at the Federal University of Ceará, Sobral Campus, and who were part of a randomized, triple-blind, "split-mouth" clinical study, where surgery was performed using the conventional technique on one side (G1 - Control Group), and using ozone therapy on the other side (G2 - Test Group), for comparison.

Patients had to be healthy and without systemic alterations or comorbidities. Exclusion criteria were those with glucose 6 phosphate dehydrogenase deficiency (favism), pregnancy, hyperthyroidism, a history of heart attack, anemia and pericoronaritis in the tooth to be extracted. The patients were instructed not to drink alcohol or take drugs in the 24 hours before surgery, which would also exclude them from the sample. A panoramic radiograph confirmed the need for third molar extraction and a clinical examination by the surgeon was carried out to determine which patients would take part in the study.

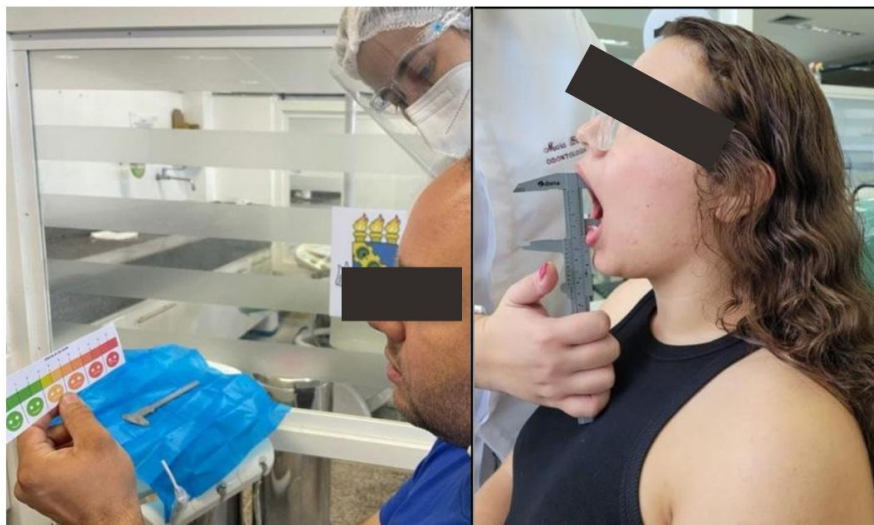
The surgeries were performed at the university by a single professional specializing in oral and maxillofacial surgery. The surgeries took place between April and October 2023. A lottery was

held to assess which surgery would be performed first (G1 or G2), and a 45-day wait was made for the second surgery.

Before the surgery, an anamnesis was taken, the patients were given all the information about the procedure and the study, all their doubts were clarified and they signed the informed consent form (Appendix A). Patients were then asked to indicate on the pain analog scale (VAS) the score that best described their current state of pain, and mouth opening (MO) was measured with a caliper by a single trained examiner (Figure 1).

Figure 1- Pain Assessment (VAS) and Mouth Opening (MO). Source: Project O3 (2023).

Figure 1A: Pain assessment (VAS). Figure 1B: Mouth opening (MO).



The conventional technique (G1) followed protocols using chlorhexidine as an extra- and intraoral antiseptic and saline as irrigation, while the ozone therapy technique (G2) used ozonized water instead of saline and chlorhexidine. However, the surgical techniques and instruments were similar for all surgeries.

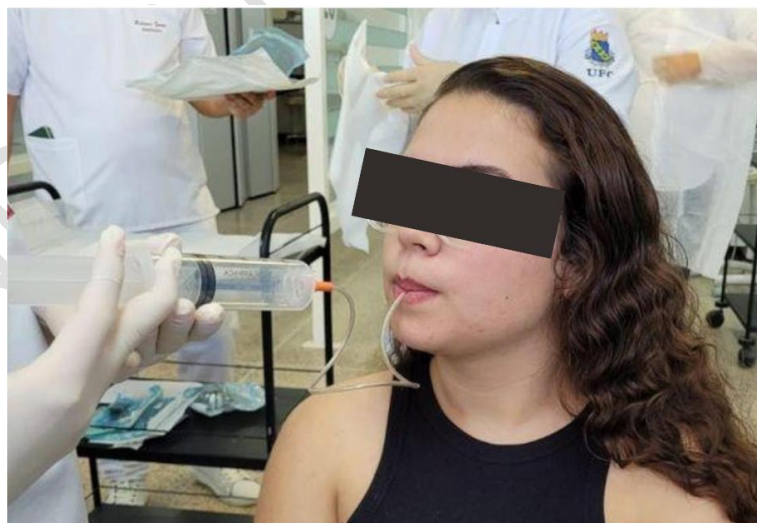
A modern, ANVISA-certified generator (Philozon®, Balneário Camboriú, Santa Catarina, Brazil) was used to produce the ozone (Figure 2).

Figure 2 - Ozone generator connected to the hospital oxygen cylinder and the water ozonization tower (Source: O3 Project, 2023).



In the Test Group (G2), ozone gas was applied sublingually for a systemic effect. This was done using a syringe attached to a No. 8 probe with 60 ml of ozone at a concentration of 40mcg, and the patient was instructed to mouthwash the gas for 1 minute (Figure 3).

Figure 3- Sublingual systemic application of ozone gas.



Afterwards, the patient was given a 25ml mouthwash with ozonized water at a concentration of 60mcg. The patient was instructed to rinse for 1 minute. Next, antisepsis was performed with ozonized water at a concentration of 60mcg. Before anesthesia, 1ml was applied using intradermal syringes 13x03mm 5mcg of ozone gas was applied around the tooth to be extracted (Figure 4). During the surgery, ozonized water (60mcg) was used for irrigation, and after the suture, ozone gas was applied again around the surgical area, ending with the application of ozonized oil over the suture (Figure 5).

Figure 4 - Local Application of Ozonized Gas.

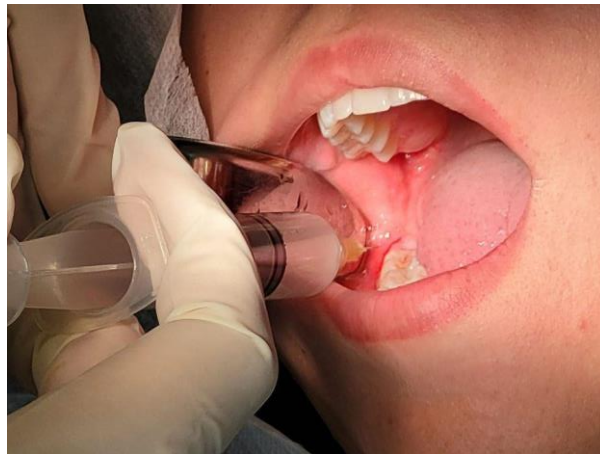

Figure 5 - Ozonized sunflower oil - Topical application on the suture.



The patients were given the usual instructions and post-operative care, such as rest and cold compresses. Paracetamol 500mg every 6 hours was prescribed as the analgesic of choice, with the observation that the patient should only take the medication if they felt pain. As an anti-inflammatory, ibuprofen 600mg every 8 hours for 3 days was prescribed. Patients were also given a glass of ozonized oil to apply over the suture every day, 3 times a day, for 7 days. The patient was monitored daily for pain and the amount of medication ingested.

## **RESULTS**

The analysis of the results shows a lower intake of analgesics by the Test Group (G2) when compared to the Control Group (G1) (Table 1). It was also observed that there was a lower perception of post-operative painful symptoms for G2 (Table 2). There was also a difference in terms of mouth opening, with better results for G2 (Table 3). No infections, alveolitis or other complications were observed in either group.

Table 1- Amount of Analgesics Ingested

PATIENT	G1 AMOUNT (INITIAL)	G2 AMOUNT (INITIAL)	G1 AMOUNT (OVER 72H)	G2 AMOUNT (OVER 72H)
1	0	0	2	1
2	0	0	51	50
3	0	0	5	2
4	0	0	5	2
5	0	0	6	1

Table 2- Pain assessment using the Pain Analog Scale (VAS)

PATIENT	G1 EVA (INITIAL)	G2 EVA (INITIAL)	G1 EVA (IMMEDIATE POST)	G2 EVA (IMMEDIATE POST)	G1 EVA (72H)	G2 EVA (72H)
1	0	6	1	0	5	0
2	6	4	2	0	6	4
3	2	1	2	0	3	0
4	1	2	1	0	3	2
5	3	4	0	0	4	1

Table 3- Mouth opening control (AB)

PATIENT	G1 AB (INITIAL)	G2 AB (INITIAL)	G1 AB (IMMEDIATE POST)	G2 AB (IMMEDIATE POST)	G1 AB (72H)	G2 AB (72H)
1	40	40	36	50	45	50
2	61	61	51	61	58	62
3	58	58	56	58	57	59
4	48	48	49	51	50	52
5	46	46	48	52	51	53

### 3. DISCUSSION

In this study, care was taken to standardize the procedures as much as possible. The surgeries were performed and monitored by the same team, the operator is a specialist in oral and maxillofacial surgery, and all the teeth operated on had the same clinical and radiographic characteristics. All steps were strictly controlled. It is believed that this standardization offered security and reliability in the results found.

The trauma caused by surgical procedures generates an inflammatory process in the post-operative period, with the release of chemical mediators of pain and inflammation, which clinically present as edema, leading to altered mouth opening and pain. These symptoms are usually controlled by analgesics and anti-inflammatories. However, with a view to reducing drug consumption and offering better patient comfort, ozone therapy can be an excellent adjunct, as shown in this study, which showed better results in reducing pain and the amount of analgesics ingested, when compared to the conventional technique.

Glória (2020) evaluated ozone irrigation in comparison with double-distilled water after third molar extractions and observed that there was a significant improvement in the pain of patients in the ozone group, concluding that the use of ozone water had satisfactory effects in the management of pain, edema and trismus after surgical removal of the third molar. These results were corroborated by those found in this study, in which there were fewer painful symptoms, better control of mouth opening and less analgesic intake in the ozone therapy group.

Ozone therapy triggers many actions in the body, such as: improving angiogenesis; increasing blood oxygenation to tissues; increasing the amount of cellular antioxidant enzymes; reducing inflammatory mediators; modulating the immune system through neutrophil activation and releasing cytokines. In this way, it is able to reduce immunological mediators of pain and eliminate microorganisms that can cause infections [4,6,7,10].

Ozone obtains various by-products in its reactions, depending on the environment in which it is found, including oxygen. By increasing the rate of oxygen reaching the tissues, it is able to generate and stimulate enzymes that capture free radicals and protect the cell walls and, consequently, encourage tissue repair, which allows it to be used as an antiseptic in oral surgery,

and in treatment of oral infections [15,16,17]. This may have contributed to the results obtained in this study.

Regarding the risks of using ozone therapy, studies report that it is a safe treatment method for use in dentistry, as no complications have been reported with the use of ozone therapy for this purpose, which was also observed in this study, as there were no interurrences or complications in the cases studied [7,13]

In addition, authors emphasize the biocompatible characteristics of ozone, its wide applicability in dentistry, its low cost and good patient acceptability, as was observed in this study [13].

However, in order to take advantage of all the benefits of ozone therapy, the Federal Council of Dentistry (CFO) regulates that it must be applied by a professional who is qualified to handle ozone correctly for each clinical situation. Therefore, only qualified professionals were selected for this study.

Furthermore, ozone therapy has demonstrated its high potential as a substitute for pharmacological substances that add to the costs of public and private clinics and generate the need for tenders in clinics maintained by the SUS, causing delays in stock disposal and inequity in distribution, as well as putting thousands of patients at risk by performing emergency surgeries without at least microbiological control of the oral cavity due to the lack of substances such as Chlorhexidine 0.12% and Iodine, for example. [4,8,12]. All these findings agree with the results of the reduction in drug consumption presented in our study, which is a strong indication of the therapeutic action of ozone.

#### **4. CONCLUSION**

In conclusion, in the cases studied, ozone therapy reduced postoperative pain, reduced the intake of analgesics and achieved better control of mouth opening when compared to the conventional technique. It could therefore be an effective, biocompatible and safe alternative for the post-operative treatment of third molar surgeries, helping to improve patients' quality of life and bringing new perspectives to dentistry. However, due to the small sample size, it is very important to carry out more clinical studies on the subject.

#### **ETHICAL APPROVAL**

All authors hereby declare that all experiments have been examined and approved by the appropriate ethics committee and have therefore been performed in accordance with the ethical standards laid down in the 1964 Declaration of Helsinki." This work deals with a series of cases that make up a clinical study, authorized by the Ethics and Research Committee, under registration 4.138.244 (caae:32833420.5.0000.5053).

## REFERENCES

1. Oliveira, C. C., Maugin, C., Oliveira, É. C. F. D., Melo, F. D. P., Silva, F. D. C. D. A., Dias, F. E. D. J., ... & SANTOS, R. D. P. (1997). Pain and the control of suffering. *Psychophysiology Magazine*, 1(1), 1-28.
2. Gregori, C. (1996). Cirurgia buco-dento-alveolar. In *Cirurgia buco-dento-alveolar* (pp. 272-272).
3. Hupp, JR, Tucker, MR, & Ellis, E. (2013). *Contemporary Oral and Maxillofacial Surgery-E-Book: Contemporary Oral and Maxillofacial Surgery-E-Book*. Ciências da saúde Elsevier.
4. Velio, B. (2005). Ozone-A new medical drug. *Netherlands: Springer*, 20, 83.
5. Velio, B. (2005). Ozone-A new medical drug. *Netherlands: Springer*, 20, 83.
6. de Moraes, C. M., & Teixeira, A. W. B. C. (2022). Ozone therapy in the healing of chronic lower limb wounds: a case series. *Global Academic Nursing Journal*, 3(2), e254-e254.
7. Bastos, P. L., Ottoboni, G. S., Karam, A. M., da Silva Sampieri, M. B., & de Araújo, E. F. (2022). Ozone therapy in dentistry: systematic literature review. *Research, Society and Development*, 11(4), e46711427474-e46711427474.
8. SCHWARTZ, A., SÁNCHEZ, G. M., & SABAH, F. (2010). MADRID DECLARATION ON OZONE THERAPY. *FACULDADE DO CENTRO OESTE PAULISTA. MADRID. DISPONÍVEL EM: [HTTPS://WWW.ABOZ.ORG.BR/BIBLIOTECA/MADRIDDECLARATION-ON-OZONE-THERAPY/210](https://www.aboz.org.br/biblioteca/madriddeclaration-on-ozone-therapy/210)*.
9. Tiwari, S., Avinash, A., Katiyar, S., Iyer, A. A., & Jain, S. (2017). Dental applications of ozone therapy: A review of literature. *The Saudi Journal for Dental Research*, 8(1-2), 105-111.
10. Bocci, V. (2004). Ozônio como Janus: This controversial gas can be toxic or medically useful. *Inflammation mediators*, 13 (1), 3-11.
11. Velio, B. (2005). Ozone-A new medical drug. *Netherlands: Springer*, 20, 83.
12. Nogales, C. G., Ferrari, P. H., Kantorovich, E. O., & Lage-Marques, J. L. (2008). Ozone therapy in medicine and dentistry. *J Contemp Dent Pract*, 9(4), 75-84.
13. Sen, S., & Sen, S. (2020). Ozone therapy, a new perspective in dentistry: integrated review. *Medical gas research*, 10 (4), 189-192.
14. Glória, JCR, Douglas-de-Oliveira, DW, e Silva, LDA, Falci, SGM, & Dos Santos, CRR (2020). Influence of ozonated water on pain, edema and trismus during impacted third molar surgery: a randomized, triple-blind clinical trial. *BMC oral health*, 20, 1-9.
15. Lopes, I. M. C. (2020). Ozone therapy for acne. *PQDT-Global*.
16. AHMEDI, Jehona *et al.* Efficiency of Gaseous Ozone in Reducing the Development of Alveolitis after Surgical Extraction of Third Molars. *European Journal of Dentistry*, v. 10, n. 3, p. 381-385, Jul-Set 2016.
17. Araújo, M. S., Prado, J. C. S., Aguiar, F. L. L. D., Silva, F. D. A., Viana, Y. N., Dantas, J. P., ... & Barbosa, F. C. B. (2024). Antifungal and Antibiofilm Activities of Ozonated Sunflower Oil against *Candida albicans* Strains: A Pilot Study and Clinical Perspectives. *Archives of Current Research International*, 24(5), 494-502.