

Anesthesia Management In An Eclampsia Patient

ABSTRACT

Eclampsia is always considered as a very serious complication of pregnancy which is responsible for numerous maternal and perinatal mortality in global setting. Eclampsia is characterized by seizures in a pregnant or postpartum patient as a result of hypertension. It is an escalation of preeclampsia, which is characterized by high blood pressure associated with pregnancy and is usually accompanied by protein in the urine. This report a case of eclampsia diagnosed in a pregnant woman which underwent anaesthesia management prior to section caesarea. The case is being reported to improve awareness regarding this life threatening entity in women.

Case Presentation: A 27 years old (G2P0A1) patient at 36 weeks of gestation, referred to our ER with a history seizure, reduced consciousness with a bitten tongue and gestational hypertension. Her vital signs: NIBP 185/115 mmHg, HR: 90 beats/minute, RR 38x/minute, SpO2 96-97% on NRM 10 lpm. The patient has been infusion with a 5% Dextrose + 6 g MgSO4 (2 g IV + 4 g drip) and a 100 ml Dower Catheter from the regional general hospital. Working diagnosis when admitted to our hospital was 36 weeks of pregnancy G2P0A1 with severe eclampsia and gestational hypertension.

Physical and laboratory examinations showed that the lungs showed smooth wet rhonchi (+/+), then on the extremities there were bilateral leg edema with hemoglobin of 10.8 g/dL, hematocrit 33.9%, platelet count was 85.000/mm³, and proteinuria +2. The clinico-pathologic features were consistent with the diagnosis of eclampsia. The patient was planned for Sectio Caesaria (SC) Cito with general anesthesia. After 7 minutes incision, the baby was born with an APGAR score 6/9. The operation procedure took 40 minutes. After surgery the patient transferred to ICU room, connect to ventilator, infusion of MgSO4 was continued, hemodynamic improvement, awareness, extubated, and then discharge from ICU because the anticipated medical complications did not arise and the patient has been deemed fit for step down care.

Keywords: seizure, gestational hypertension, proteinuria, sectio caesaria, general anesthesia, intensive care unit

1. INTRODUCTION

Pre-eclampsie and eclampsia are hypertensive complications account for 6–8% of pregnancies [1] and are a significant contributor to maternal and perinatal morbidity and mortality [2]. In the United States, preeclampsia is one of the three main causes of death in pregnant women [3]. Sub-standards handling is often the main cause of increased risk of morbidity and mortality in pregnant women [4]. Preeclampsia is characterized by hypertension, hypoalbuminemia, and edema which occurs suddenly in pregnancy after 20

weeks [3,4], while eclampsia is the worsening condition of preeclampsia followed by seizures where there was no previous neurological disorder [5].

The emergency of pre-eclampsia in pregnancy occur when definite neurological symptoms appear, e.g., persistent severe headaches, blindness and seizures [5,6]. Those condition usually preceded by worsening hypertension [7] and proteinuria [8] at the end of pregnancy; events that can explain the neurological symptoms of severe pre-eclampsia and Eclampsia precede the occurrence of a reversible posterior encephalopathy syndrome when blood pressure rises [9]. These events occurs in pre-eclampsia which is caused by failure of autoregulation [10].

Theoretically, the main therapy for this condition is to terminate the pregnancy [11]. In the context of anesthesiology, a clear understanding of the pathogenesis of preeclampsia and eclampsia is a must. This current case report is about the anaesthesia management of an eclampsia patient.

2. PRESENTATION OF CASE

The following case presented in the form of anaesthetic management for the condition of eclampsia in a pregnant woman who was referred to our hospital from the regional general hospital (RSUD). A 27 years old (G2P0A1) patient at 36 weeks of gestation, body weight (BW) 65 kg, body height (BH) 155 cm, body mass index (BMI): 27.05 kg/m², Consciousness: Somnolence. The patient was referred with a history of seizures, decreased consciousness with a bitten tongue, and gestational hypertension.

Her vital signs as follows: non-invasive blood pressure (NIBP) was 185/115 mmHg, heart rate (HR) was 90 beats/minute, respiratory rate (RR) was 38/minute, peripheral oxygen saturation (SpO₂) 96-97%, fever was 37C, and on non rebreather mask (NRM) was 10 lpm. The patient has been given with an intra venous (IV) 5% Dextrose + 6 g MgSO₄ (2 g IV + 4 g drip) and a 100 ml Dower Catheter from the Regional General Hospital. Working diagnosis when admitted to our hospital was 36 weeks of pregnancy G2P0A1 with severe eclampsia and gestational hypertension.

Physical and laboratory examinations showed that the lungs showed smooth wet rhonchi (+/+), then on the extremities there were bilateral leg edema with hemoglobin of 10.8 g/dL, hematocrit 33.9%, platelet count was 85.000/mm³, and proteinuria +2. The patient was planned for Sectio Caesaria (SC) Cito with general anesthesia. The patient was administered oxygenation 10/lpm (NRM) from emergency room (ER) to the operating room (OT).

The first patient placing in the supine position who has taken in the operating room. Routine monitoring was performed on the patient (NIBP, EKG, SpO₂). All equipment is prepared. Asepsis and antisepsis are carried out lege artis, and then the patient wrapped in a sterile manner by the surgeon

- Before induction the patient was administered preoxygenation, and then followed Propofol 100 mg with atracurium 20 mg and Fentanyl 100 mcg.

- The patient was intubated with a 6.5 cuffed endotracheal tube (ETT). Anesthesia was administered with 50% O₂/air and a minimum alveolar concentration (MAC) of 1 with Isoflurane.

- After 7 minutes incision a baby was born with an APGAR score of 6/9 and given 20 international units (IU) of oxytocin. The baby was transferred to the neonatal intensive care unit (NICU). As soon as the baby is born, the anesthesia was maintained with 30 % O₂/N₂O and 1,5 MAC of Isoflurane. The operation duration: 45 minutes and during surgery hemodynamics was stable. The patient did not have any bleeding that required transfusion.

- Liquid: input of ringer lactate (RL) solution 800 ml and output: bleeding 300 ml with urine 100 ml

- After the operation was completed, 40 minutes, the patient's blood pressure (NIBP) decreased to 140/90 mmHg and HR: 90 beats/minute. The patient was transferred to the intensive care unit (ICU) for close monitoring, while still intubated, connect to ventilator using mode synchronous intermittent mandatory ventilation-pressure support (SIMV-PS) and IV MgSO₄ infusion was continued. The patient after approximately 4 hours in ICU room hemodynamic at normal limit, awareness, and contact were good. Soon after that, the mode of ventilator was changed became continuous positive airway pressure (CPAP) for during 3 hours, and finally extubated.

Post extubated hemodynamic at normal limit: NIBP 115/76 mmHg; HR: 72 beats/minute; SpO₂: 98% and infusion of MgSO₄ is continued for 24 hours postoperatively. On the following day, due to the sign of hemodynamic improvement with full awareness of the patient, then the patient was extubated, and then discharge from the ICU because the anticipated medical complications did not arise and the patient has been deemed fit for step down care.

3. DISCUSSION

The Ministry of Health of the Republic of Indonesia (Kemenkes RI) through Infodatin in 2014 [12], divided hypertension in pregnancy (HIP) into 4 (four) types, namely preeclampsia-eclampsia, chronic hypertension, preeclampsia in chronic hypertension which is a combination of preeclampsia with chronic hypertension, and gestational hypertension. [12]

Hypertension in Pregnancy, especially preeclampsia, is one of the most important problems in the realm of public health [13] and perinatal medicine [14]. Globally, preeclampsia is the biggest contributor cause of maternal morbidity and mortality [15], which is defined as hypertension that appears after 20 weeks of pregnancy [16] when it is first diagnosed and is accompanied by the presence of protein components in the urine or what is called proteinuria [17]. Eclampsia is the worsening of preeclampsia which is complicated by generalized tonic-clonic seizures [18]. Currently, HIP has been classified as a subtype of toxemia in pregnancy [19] which consists of one or more symptoms in the form of hypertension, proteinuria, and edema during pregnancy. The incidence of HIP, especially preeclampsia and eclampsia, is now at 5-15% [2], and is one of the highest causes of maternal mortality in Indonesia besides infection and bleeding [21].

Preeclampsia is a type of HIP that has a specific diagnosis [22], namely divided into mild and severe preeclampsia. The diagnostic criteria for mild preeclampsia [23] are as follows: hypertension which marked by blood pressure $\geq 140/90$ mmHg but still less than 160/110, or Increase in systolic blood pressure ≥ 30 mmHg or increase in diastolic blood pressure ≥ 15 mmHg. That derangement in blood pressure accompanied with proteinuria 0.3 g/L in 24 hours or qualitatively up to +2.

The diagnosis of severe preeclampsia [24] is made if one or more symptoms are present as follows: (1) Systolic blood pressure ≥ 160 mmHg and diastolic ≥ 110 mmHg. Blood pressure and this does not decrease even though the patient has been treated and is on full bed rest; (2) Proteinuria more than 5 g/L in 24 hours or qualitative +4; (3) Oliguria, a condition marked by the amount of urine production of less than 500 cc in 24 hours and accompanied by an increase in blood creatinine levels; (4) possible subjective complaints in the form of: Visual disturbances: dizziness in the eyes [25]; Cerebral disorders: headache [26]; Epigastric pain in the right upper quadrant of the abdomen and Hyperreflexia [27]; (5) The presence of

HELLP syndrome [28], which consists of several symptoms that include hemolysis, increased liver enzymes, and low platelet count; (6) Cyanosis [29]. In most cases of preeclampsia, proteinuria is almost always present. Proteinuria is defined as the excretion of 300 mg or more protein in 24 hours, or a minimum protein/creatinine ratio of 0.3 mg/dl, which is equivalent of 24-hour protein excretion. A protein reading on a +1 dipstick is also a sign of proteinuria, but because this qualitative method has many false positive and negative results, it is recommended that this measurement only be used if there is no quantitative means of diagnosis.

Pathophysiologically, preeclampsia can be explained as follows:

- Cardiovascularly: The endothelium secretes vasoactivity which is dominated by vasoconstrictors [30], such as endothelin [31] and thromboxane A₂ [32]. In addition, there is a decrease in renin, angiotensin I and angiotensin II levels [33] compared to normal pregnancy.
- Metabolic shift: (1) Decreased reproduction of prostaglandins [34] released by the placenta; (2) Changes in the balance of prostaglandin production which leads to increased thromboxane [35] which is a strong vasoconstrictor, decreased production of prostacyclin [35] which functions as a vasodilator and decreased production of angiotensin II-III which causes increased sensitivity of blood vessel muscles to vasopressors; (3) These changes cause vasoconstriction of blood vessels and vasa vasorum [36], resulting in damage, necrosis of blood vessels, and resulting in increased permeability [37] and increased blood pressure [7,13,20,21,30,32] (4) Damage to blood vessel walls causes and makes it easier for platelets [32] to aggregate and adhesion and ultimately narrows the lumen and further disrupts blood flow to vital organs; (5) Efforts to overcome these platelet deposits result in lysis, which can reduce the blood and coagulation systems

In women with preeclampsia there is always thrombocytopenia [38], decreased levels of several clotting factors, and also reduced erythrocytes count with morphologically have an abnormal shape [39]; a condition which facilitates hemolysis. Injury to the endothelium [30,31,37] can cause increased platelet aggregation, reduce their survival time, and suppress antithrombin III levels which facilitates bleeding easier.

Homeostasis of body fluids showed in pre-eclampsia [40], sodium retention [41] occurs due to increased secretion of deoxycorticosterone [42] which is the result of progesterone conversion [43]. In pregnant women who experience severe preeclampsia, the extracellular volume will increase and manifest as edema [44] that is more severe than in normal pregnant women.

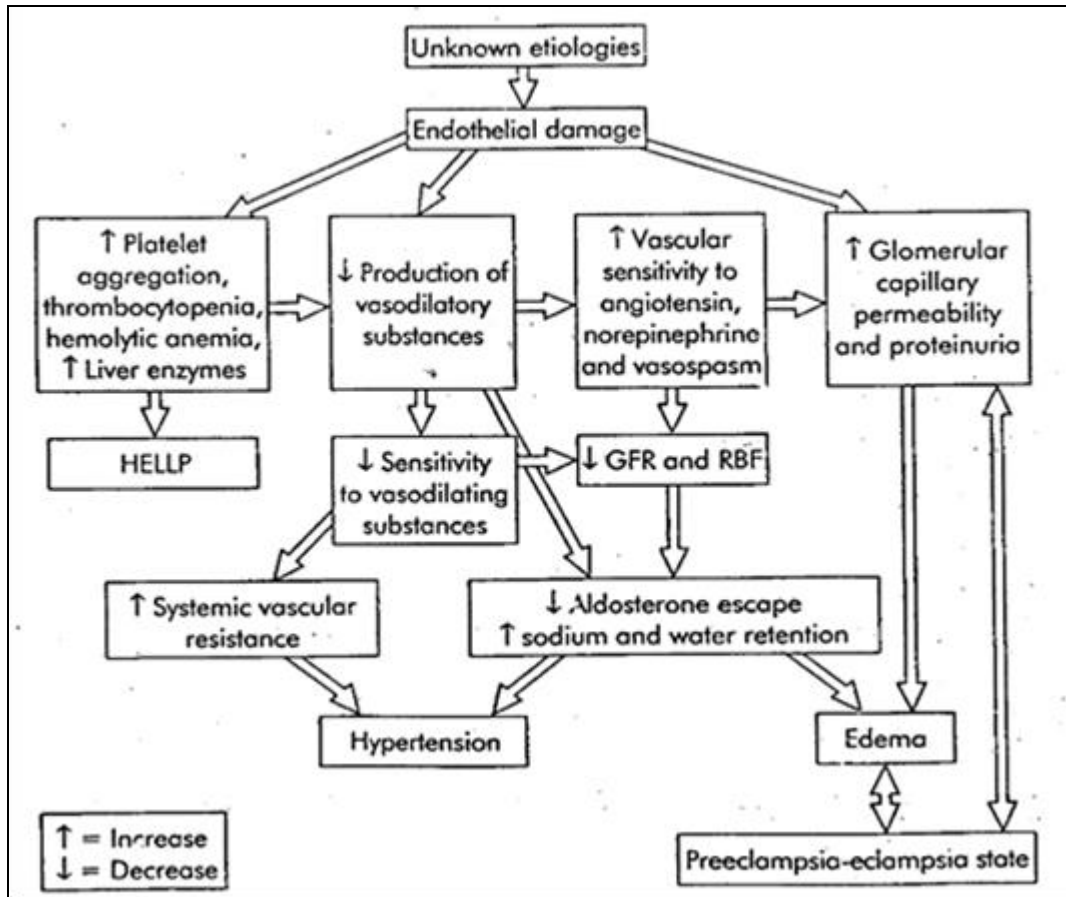


Fig. 1 Pathway of preeclampsia- eclampsia

Cesarean section (SC) is a way of delivering a fetus by making an incision in the uterine wall through the front wall of the abdomen. CS delivery is indicated when normal birth is unsafe, related to problems with the mother's pelvis or the birth canal in the reproductive canal which has the potential to endanger the newborn and the mother [45]. There are two etiologies of SC, namely etiology originating from the mother and etiology originating from the fetus.

Indications for caesarean section are divided into three types, namely absolute, relative and social indications. Complications that can arise during caesarean section are:

- a. Puerperal (postpartum) infection [46], which is divided into three, namely mild with a rise in temperature for only a few days, moderate with a higher rise in temperature, accompanied by dehydration and a slightly bloated stomach and severe with peritonitis, sepsis and paralytic ileus.
- b. Bleeding [47], caused by many blood vessels being cut and open, uterine atony and bleeding in the placenta.
- c. Injury to organs near the uterus (bowel, bladder, ureters, blood vessels) [48]. Bladder injuries can be recognized immediately, but ureteral injuries are often discovered too late. Uterine infections are relatively common after CS.

- d. It is possible that spontaneous uterine rupture [49] will occur in the next pregnancy

During the operation, perioperative monitoring [50] is carried out to help the anesthesiologist obtain information on the function of vital organs during perioperation, so they can work safely. Fluid Monitoring helps anesthesiologists [51] conduct more efficient continuous patient observation to maintain patient hemodynamics. Administration of Dextrose 5% + MgSO₄ (2 g IV + 4 g drip) to prevent seizures and refractory seizures. Dextrose is used for the management and prevention of hypoglycemia, parenteral nutrition and rehydration [52]. Meanwhile, antenatal use of magnesium sulfate does not show serious side effects such as maternal death, cardiac arrest or respiratory arrest. Magnesium sulfate (MgSO₄) [53] is a calcium antagonist that works in the smooth muscle of blood vessels which will cause a decrease in intracellular calcium so that it will relax the arteries, relieve vasospasm, and reduce arterial blood pressure, such as the aorta and smaller resistance vessels including the mesenteric, skeletal muscle, uterus, and cerebral arteries.

After all the anesthesia and resuscitation equipment and anesthesia and resuscitation drugs are ready, the patient is given preoxygenation with 10 lpm NRBAG oxygen [54]. In general, the target of anesthetic management is to maintain the patient's airway to maintain ventilation. Because maternal oxygen reserves decrease in pregnancy, significant arterial desaturation will occur if the patient becomes apneic for even a short time. The mechanical ventilator must be adjusted to maintain PCO₂ in the range of 30 to 32 torr.

Administration of analgesics and sedatives [55], namely propofol, atracurium, and fentanyl for the treatment of postoperative pain, must be carried out. If not treated, it can cause agitation, tachycardia, and increased pulmonary complications during the operation. with fast-acting analgesia and opioid agents, the aim is to ensure that the patient's hemodynamics remain stable during the operation

After the patient's surgery, she was treated in the ICU, the patient was controlled with a ventilator. This aims to provide early and intensive multidisciplinary monitoring and diagnosis in an ICU setting to prevent complications and reduce morbidity and mortality. The most common causes for intubation and mechanical ventilation [56] are respiratory failure, hemodynamic instability, and a history of emergency cesarean section.

4. CONCLUSION

A 27 years old (G2P0A1) patient at 36 weeks of gestation. Patient is a referral from the Regional General Hospital (RSUD) to the ER RSUD UKI with a history of seizures, loss of consciousness with the tongue bleeding from being bitten, and gestational hypertension. With vital signs as follows: NRM 185/115 mmHg, HR: 90x/minute, RR 38x/minute, SpO₂ 96-97% on NRM 10 lpm. The patient has been given an infusion of Dextrose 5% + MgSO₄ (2 g IV + 4 g drip) and D.C 100 ml from regional general hospital (RSUD). The patient was undergoing Sectio Caesaria (SC) Cito with general anesthesia. The baby was born with APGAR score 6/9. Duration of surgery of 40 minutes. After baby was born and the operation was completed the patient's NIBP 140/90 mmHg, HR: 90x/minute. The patient was treated in the ICU, connect to ventilator with mode SIMV-PS, infusion of MgSO₄ was continued, hemodynamic improvement, awareness, mode ventilator synchronizes to CPAP, and then extubated. Post extubation Vital Signs, namely NIBP 115/76 mmHg; HR: 72x/minute; SpO₂: 98%, infusion of MgSO₄ continues. Administration of infusion Dextrose 5% + MgSO₄ (2 g IV + 4 g drip) to prevent seizures and the possibility of refractory seizures. Dextrose is used for the management and prevention of hypoglycemia, parenteral nutrition and rehydration. In the patient of the following case, various actions and administration of medication were carried out appropriately and immediately to prevent further complications from the eclampsia condition she was experiencing. Severe preeclampsia, eclampsia and HELLP

syndrome are serious and life-threatening conditions faced by pregnant women. Immediate treatment in the following cases will provide a better prognosis.

CONSENT (WHERE EVER APPLICABLE)

"author declare that 'written informed consent was obtained from the patient (or other approved parties) for publication of this case report and accompanying images. A copy of the written consent is available for review by the Editorial office/Chief Editor/Editorial Board members of this journal."

ETHICAL APPROVAL (WHERE EVER APPLICABLE)

authors hereby declare that "Principles of laboratory animal care" (NIH publication No. 85-23, revised 1985) were followed, as well as specific national laws where applicable. All experiments have been examined and approved by the appropriate ethics committee"

REFERENCES

1. Report of the National High Blood Pressure Education Program Working Group on High Blood Pressure in Pregnancy. *Am J Obstet Gynecol.* 2000 Jul;183(1):S1–S22.
2. Ford ND, Cox S, Ko JY, et al. Hypertensive Disorders in Pregnancy and Mortality at Delivery Hospitalization — United States, 2017–2019. *MMWR Morb Mortal Wkly Rep* 2022;71:585–591. <http://dx.doi.org/10.15585/mmwr.mm7117a1>
3. Karrar SA, Martingano DJ, Hong PL. Preeclampsia. [Updated 2024 Feb 25]. In: StatPearls [Internet]. Treasure Island (FL): StatPearls Publishing; 2024 Jan-. Available from: <https://www.ncbi.nlm.nih.gov/books/NBK570611/>
4. US Preventive Services Task Force. Screening for Preeclampsia: US Preventive Services Task Force Recommendation Statement. *JAMA.* 2017;317(16):1661–7. <https://doi.org/10.1001/jama.2017.3439>
5. Makrigiannakis A, Petsas G, Chrousos GP. Eclampsia and Pre-Eclampsia. Ed(s): Fink G. *Encyclopedia of Stress (Second Edition)*, Academic Press, 2007, pp 880-4, ISBN 9780123739476, <https://doi.org/10.1016/B978-012373947-6.00480-3>.
6. Miller EC, Vollbracht S. Neurology of Preeclampsia and Related Disorders: an Update in Neuro-obstetrics. *Curr Pain Headache Rep.* 2021 Apr 7;25(6):40. <https://doi.org/10.1007/s11916-021-00958-z>.
7. Wiles K, Damodaram M, Frise C. Severe hypertension in pregnancy. *Clinical Medicine*,2021; 21(5): e451-e456, <https://doi.org/10.7861/clinmed.2021-0508>.
8. Fishel Bartal M, Lindheimer MD, Sibai BM. Proteinuria during pregnancy: definition, pathophysiology, methodology, and clinical significance. *Am J Obstet Gynecol.* 2022 Feb;226(2S):S819-S834. <https://doi.org/10.1016/j.ajog.2020.08.108>.
9. Shaikh N, Nawaz S, Ummunisa F, Shahzad A, Hussain J, Ahmad K, Almohannadi HS, Sharara HA. Eclampsia and posterior reversible encephalopathy syndrome (PRES): A retrospective review of risk factors and outcomes. *Qatar Med J.* 2021 Feb 16;2021(1):4. <https://doi.org/10.5339/qmj.2021.4>.
10. van Veen TR, Panerai RB, Haeri S, Singh J, Adusumalli JA, Zeeman GG, Belfort MA. Cerebral autoregulation in different hypertensive disorders of pregnancy. *Am J Obstet Gynecol.* 2015 Apr;212(4):513.e1-7. <https://doi.org/10.1016/j.ajog.2014.11.003>.

11. Mark K, Flanagan N, Hurvitz J, Chawla K. Abortion in women with severe preeclampsia and eclampsia prior to 24 weeks gestation. *Contraception*. 2021 Jun;103(6):420-422. <https://doi.org/10.1016/j.contraception.2021.01.012>.
12. Kementerian Kesehatan RI: Info Datin Ibu. Diakses pada 23 Juli 2018. 2014. Pp 1-3. <http://www.depkes.go.id/folder/view/01/structure-publikasi-pusdatin-infodatin.html>
13. Luger RK, Kight BP. Hypertension In Pregnancy. [Updated 2022 Oct 3]. In: StatPearls [Internet]. Treasure Island (FL): StatPearls Publishing; 2024 Jan-. Available from: <https://www.ncbi.nlm.nih.gov/books/NBK430839/>
14. Belay Tolu L, Yigezu E, Urgie T, Feyissa GT (2020) Maternal and perinatal outcome of preeclampsia without severe feature among pregnant women managed at a tertiary referral hospital in urban Ethiopia. *PLoS ONE*, 2020; 15(4): e0230638. <https://doi.org/10.1371/journal>.
15. Souza JP, Day LT, Rezende-Gomes AC, Zhang J, Mori R, Baguiya A, et al. A global analysis of the determinants of maternal health and transitions in maternal mortality. *Lancet Glob Health*. 2024 Feb;12(2):e306-e316. [https://doi.org/10.1016/S2214-109X\(23\)00468-0](https://doi.org/10.1016/S2214-109X(23)00468-0).
16. Dahlia R, Peterson E. A Critical Review of Early-Onset and Late-Onset Preeclampsia. *Obstetrical & Gynecological Survey*, 2011; 66(8):p 497-506, <https://doi.org/10.1097/OGX.0b013e3182331028>
17. Müller-Deile J, Schiffer M. Preeclampsia from a renal point of view: Insides into disease models, biomarkers and therapy. *World J Nephrol*. 2014 Nov 6;3(4):169-81. <https://doi.org/10.5527/wjn.v3.i4.169>
18. Cipolla MJ, Kraig RP. Seizures in Women with Preeclampsia: Mechanisms and Management. *Fetal Matern Med Rev*. 2011 May;22(2):91-108. <https://doi.org/10.1017/S0965539511000040>.
19. Purkerson ML, Vekerdy L. A History of Eclampsia, Toxemia and the Kidney in Pregnancy. *Am J Nephrol* 1 April 1999; 19 (2): 313–319. <https://doi.org/10.1159/000013467>
20. Bello NA, Zhou H, Cheetham TC, Miller E, Getahun DT, Fassett MJ, Reynolds K. Prevalence of Hypertension Among Pregnant Women When Using the 2017 American College of Cardiology/American Heart Association Blood Pressure Guidelines and Association With Maternal and Fetal Outcomes. *JAMA Netw Open*. 2021 Mar 1;4(3):e213808. doi: 10.1001/jamanetworkopen.2021.3808. Erratum in: *JAMA Netw Open*. 2021 Apr 1;4(4):e2112000. <https://doi.org/10.1001/jamanetworkopen.2021.12000>.
21. Akbar MIA, Bachnas MA, Mose JC, Dachlan EG, Ernawati, Dekker GA, et al. Cahpter 28. The massive problem of preeclampsia in indonesia: In need of a redesigned national health care system. *Pregnancy Hypertension*, 2018; 13(1):S16, <https://doi.org/10.1016/j.preghy.2018.08.051>.
22. Duhig K, Vandermolen B, Shennan A. Recent advances in the diagnosis and management of pre-eclampsia. *F1000Res*. 2018 Feb 28;7:242. <https://doi.org/10.12688/f1000research.12249.1>.
23. Kaaja RJ, Moore MP, Yandle TG, Ylikorkala O, Frampton CM, Nicholls MG. Blood pressure and vasoactive hormones in mild preeclampsia and normal pregnancy. *Hypertens Pregnancy*. 1999;18(2):173-87. <https://doi.org/10.3109/10641959909023077>.
24. Aracil Moreno I, Rodríguez-Benitez P, Ruiz-Minaya M, Bernal Claverol M, Ortega Abad V, Hernández Martin C, et al. Maternal Perinatal Characteristics in Patients with Severe

- Preeclampsia: A Case-Control Nested Cohort Study. *Int J Environ Res Public Health*. 2021 Nov 10;18(22):11783. <https://doi.org/10.3390/ijerph182211783>.
25. Wiedemann J, Altay L, Neugebauer A, Krohne T, Cursiefen C. Visual complaints in pregnancy: (pre)eclampsia as a chameleon. *GMS Ophthalmol Cases*. 2022 Nov 21;12:Doc21. <https://doi.org/10.3205/oc000208>.
 26. Miller EC, Vollbracht S. Neurology of Preeclampsia and Related Disorders: an Update in Neuro-obstetrics. *Curr Pain Headache Rep*. 2021 Apr 7;25(6):40. <https://doi.org/10.1007/s11916-021-00958-z>.
 27. Narkhede AM, Karnad DR. Preeclampsia and Related Problems. *Indian J Crit Care Med*. 2021 Dec;25(Suppl 3):S261-S266. <https://doi.org/10.5005/jp-journals-10071-24032>.
 28. Khalid F, Mahendraker N, Tonismae T. HELLP Syndrome. [Updated 2023 Jul 29]. In: StatPearls [Internet]. Treasure Island (FL): StatPearls Publishing; 2024 Jan-. Available from: <https://www.ncbi.nlm.nih.gov/books/NBK560615/>
 29. Chaiworapongsa T, Chaemsathong P, Yeo L, Romero R. Pre-eclampsia part 1: current understanding of its pathophysiology. *Nat Rev Nephrol*. 2014 Aug;10(8):466-80. <https://doi.org/10.1038/nrneph.2014.102>.
 30. Lamarca B. Endothelial dysfunction. An important mediator in the pathophysiology of hypertension during pre-eclampsia. *Minerva Ginecol*. 2012 Aug;64(4):309-20.
 31. Saleh L, Verdonk K, Visser W, van den Meiracker AH, Danser AH. The emerging role of endothelin-1 in the pathogenesis of pre-eclampsia. *Ther Adv Cardiovasc Dis*. 2016 Oct;10(5):282-93. <https://doi.org/10.1177/1753944715624853>.
 32. Liel N, Nathan I, Yermiyahu T, Zolotov Z, Lieberman JR, Dvilansky A, Halushka PV. Increased tlet thromboxane A2/prostaglandin H2 receptors in patients with pregnancy induced hypertension. *Thromb Res*. 1993 May 1;70(3):205-10. [https://doi.org/10.1016/0049-3848\(93\)90126-9](https://doi.org/10.1016/0049-3848(93)90126-9).
 33. Irani RA, Xia Y. Renin angiotensin signaling in normal pregnancy and preeclampsia. *Semin Nephrol*. 2011 Jan;31(1):47-58. <https://doi.org/10.1016/j.semnephrol.2010.10.005>.
 34. Kellie FJ. Prostaglandin A for treating pre-eclampsia. *Cochrane Database Syst Rev*. 2017 Jun 13;2017(6):CD009657. <https://doi.org/10.1002/14651858.CD009657>.
 35. Wang Y, Zhang Y, Canzoneri BJ, Gu Y, Philibert L, Lewis DF. Prostacyclin and thromboxane levels in women with severe preeclampsia undergoing magnesium sulfate therapy during antepartum and postpartum periods. *Hypertens Pregnancy*. 2008;27(1):17-27. <https://doi.org/10.1080/10641950701825721>.
 36. Martínez-Martínez MM, Fernández-Travieso J, Gómez Muñoz N, Varela Mezquita B, Almarcha-Menargues ML, Miralles Martínez A. Cerebral hemodynamics and vasoconstriction in preeclampsia: From diagnosis to resolution. *Pregnancy Hypertens*. 2021 Dec;26:42-47. <https://doi.org/10.1016/j.preghy.2021.08.114>.
 37. Bergman L, Acurio J, Leon J, Gatu E, Friis T, et al. Preeclampsia and Increased Permeability Over the Blood–Brain Barrier: A Role of Vascular Endothelial Growth Receptor 2. *American Journal of Hypertension*, 2021; 34(1):73–81, <https://doi.org/10.1093/ajh/hpaa142>
 38. Mangla A, Hamad H. Thrombocytopenia in Pregnancy. [Updated 2022 Nov 30]. In: StatPearls [Internet]. Treasure Island (FL): StatPearls Publishing; 2024 Jan-. Available from: <https://www.ncbi.nlm.nih.gov/books/NBK547705/>
 39. Giosheva I, Strijkova V, Komsa-Penkova R, Krumova S, Langari A, Danailova A, et al. Membrane Lesions and Reduced Life Span of Red Blood Cells in Preeclampsia as

- Evidenced by Atomic Force Microscopy. *Int J Mol Sci.* 2023 Apr 12;24(8):7100. <https://doi.org/10.3390/ijms24087100>.
40. Gyselaers W, Vonck S, Staelens AS, Lanssens D, Tomsin K, Oben J, Dreesen P, Bruckers L. Body fluid volume homeostasis is abnormal in pregnancies complicated with hypertension and/or poor fetal growth. *PLoS One.* 2018 Nov 1;13(11):e0206257. <https://doi.org/10.1371/journal.pone.0206257>.
 41. Hu CC, Katerelos M, Choy SW, Crossthwaite A, Walker SP, Pell G, et al Pre-eclampsia is associated with altered expression of the renal sodium transporters NKCC2, NCC and ENaC in urinary extracellular vesicles. *PLoS One.* 2018 Sep 24;13(9):e0204514. <https://doi.org/10.1371/journal.pone.0204514>.
 42. Marques P, Tufton N, Bhattacharya S, Caulfield M, Akker SA. Hypertension due to a deoxycorticosterone-secreting adrenal tumour diagnosed during pregnancy. *Endocrinol Diabetes Metab Case Rep.* 2019 May 3;2019:18-0164. <https://doi.org/10.1530/EDM-18-0164>.
 43. Meher S, Duley L. Progesterone for preventing pre-eclampsia and its complications. *Cochrane Database Syst Rev.* 2006 Oct 18;2006(4):CD006175. <https://doi.org/10.1002/14651858.CD006175>.
 44. MacGillivray I, Campbell DM. The relevance of hypertension and oedema in pregnancy. *Clin Exp Hypertens* (1978). 1980;2(5):897-914. <https://doi.org/10.3109/10641968009037148>.
 45. Sung S, Mahdy H. Cesarean Section. [Updated 2023 Jul 9]. In: StatPearls [Internet]. Treasure Island (FL): StatPearls Publishing; 2024 Jan-. Available from: <https://www.ncbi.nlm.nih.gov/books/NBK546707/>
 46. Feruza, N. and Wang, Z. (2023) Evaluation of Puerperal and Postpartum Infections after Cesarean Section and Their Clinical Outcomes. *Open Journal of Internal Medicine*, 13, 330-350. <https://doi.org/10.4236/ojim.2023.134030>.
 47. Fawcus S, Moodley J. Postpartum haemorrhage associated with caesarean section and caesarean hysterectomy. *Best Pract Res Clin Obstet Gynaecol.* 2013 Apr;27(2):233-49. <https://doi.org/10.1016/j.bpobgyn.2012.08.018>.
 48. Ahmed F, Al-Wageeh S, Badheeb M, Altam A, Alsharif A. Iatrogenic Ureteral and Colonic Injuries During Emergency Cesarean Section: A Lesson Learned from a Surgical Catastrophe – A Case Report. *Int Med Case Rep J.* 2023;16:251-256. <https://doi.org/10.2147/IMCRJ.S407241>
 49. Togioka BM, Tonismae T. Uterine Rupture. [Updated 2023 Jul 29]. In: StatPearls [Internet]. Treasure Island (FL): StatPearls Publishing; 2024 Jan-. Available from: <https://www.ncbi.nlm.nih.gov/books/NBK559209/>
 50. Zeleke ME, Chekol WB, Kasahun HG, Mekonnen ZA, Filatie TD, Melesse DY, et al. Perioperative management of surgical procedure during pregnancy: a systematic review. *Ann Med Surg (Lond).* 2024 Apr 16;86(6):3432-3441. <https://doi.org/10.1097/MS9.0000000000002057>.
 51. Mercier FJ. Cesarean delivery fluid management. *Curr Opin Anaesthesiol.* 2012 Jun;25(3):286-91. <https://doi.org/10.1097/ACO.0b013e3283530dab>.
 52. Rijs K, Mercier FJ, Lucas DN, Rossaint R, Klimek M, Heesen M. Fluid loading therapy to prevent spinal hypotension in women undergoing elective caesarean section: Network meta-analysis, trial sequential analysis and meta-regression. *Eur J Anaesthesiol.* 2020 Dec;37(12):1126-1142. <https://doi.org/10.1097/EJA.0000000000001371>.

53. Ma S, Zhang Y, Li Q. Magnesium sulfate reduces postoperative pain in women with cesarean section: A meta-analysis of randomized controlled trials. *Pain Pract.* 2022 Jan;22(1):8-18. doi: <https://doi.org/10.1111/papr.13022>.
54. Weekley MS, Bland LE. Oxygen Administration. [Updated 2023 Jul 18]. In: StatPearls [Internet]. Treasure Island (FL): StatPearls Publishing; 2024 Jan-. Available from: <https://www.ncbi.nlm.nih.gov/books/NBK551617/>
55. Liu H, Wang Y, Li F, Ren W, Yuan L. Analgesic and Sedative Effects of Different Doses of Dexmedetomidine Combined with Butorphanol in Continuous Analgesia after a Cesarean Section. *Front Surg.* 2022 May 4;9:896536. <https://doi.org/10.3389/fsurg.2022.896536>.
56. Alvarado AC, Panakos P. Endotracheal Tube Intubation Techniques. [Updated 2023 Jul 10]. In: StatPearls [Internet]. Treasure Island (FL): StatPearls Publishing; 2024 Jan-. Available from: <https://www.ncbi.nlm.nih.gov/books/NBK560730/>

UNDER PEER REVIEW