

Review Article

A review on toxic effects of pesticides on physiological aspects of fish

Abstract

Pesticides are notorious for staying and spreading in the environment, and they can accumulate and disturb the food web, which endangers both animals and humans. This study summarizes the available information on the eco-toxicology of pesticides in fish. The majority of pesticides are released into the environment, and very few that are applied reach their biological goal; where they can accumulate and be hazardous to organisms that are not their intended targets. Their entry into aquatic ecosystems causes disastrous effects on flora and fauna. An attempt has been made to critically review the harmful effects of different pesticides on different fish species. This review will focus on the various alternations or changes in fish behavior (like as increased surface breathing, tremors in their fins, air gulping, irregular swimming and operculum movement), biochemical characteristics (such as antioxidant defense system damage caused by the production of ROS, altered levels of several oxidative stress indicators, including MDA, GST, SOD, CAT, GSH and GPx levels), blood parameters (like altered levels of RBC, WBC, MCH, MCV Hct and Hb contents) and histopathological changes (in liver, gills, intestine, kidney and gonads) caused by various pesticides. Higher concentrations of pesticides in the water bodies can lead to the mortality of fish species while sub-lethal concentrations have long-lasting effects.

Keywords: pesticides, behavior, hematology, antioxidant defense, histology

Introduction

Pesticides are synthetic chemicals that humans create to protect plants from pests and diseases [1]. A few detrimental effects of pesticide use are the emergence of resistant pest populations, and the decline in important keystone species such as earthworms, pollinators, and predators [2]. Chemical pesticides are regarded as strong pollutants in aquatic environments. These pollutants enter aquatic environments naturally as a result of several processes [3]. They come in different types depending on what they target or what they are made of, such as insecticides, herbicides, fungicides etc. When they are widely used, pesticide residues often end up in water bodies through farm and city runoff [4], wind drift, or direct spraying, and they can harm aquatic animals that are not meant to be affected, especially in densely populated areas where the levels are too high. Insecticides are the main source of contamination for many water habitats. They enter the water systems through rain, runoff, and wind. They end up in ponds, lakes, and rivers [5] and harm various non-target aquatic organisms. The health of fish and other aquatic animals is endangered by the reduced water quality caused by harmful substances such as pesticides. Fish

is the most vital vertebrate that serves as food for humans. They have significant economic, aesthetic, nutritional, industrial, religious and medicinal values. Fish provides livelihood for millions of people around the world. The high usage of pesticides shows that more than one active ingredient threatens 64% of the world's farmland with pesticide contamination, and 31% faces a high risk. Also, pesticide pollution is likely to grow soon [6].

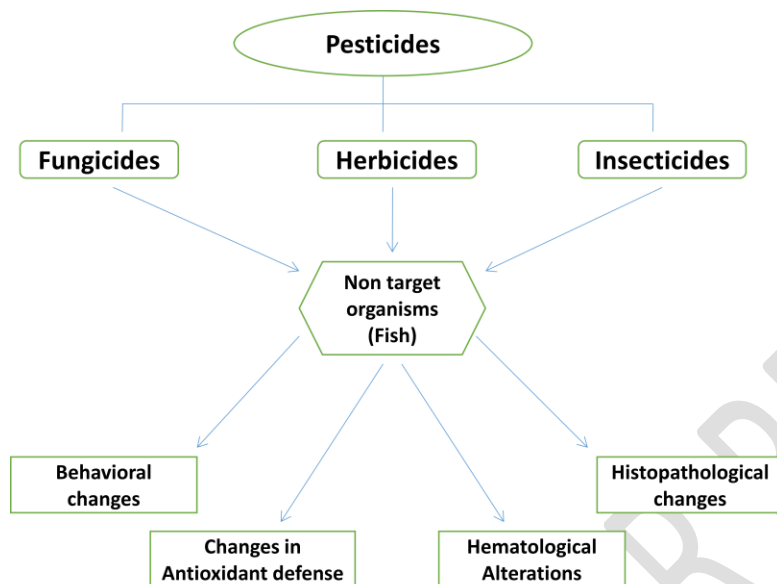


Fig 1: Effects of different pesticides on behavior, hematology, histology and antioxidant defense system of fish.

Examples of pesticides include fungicides, herbicides and insecticides. Fungicides are a type of pesticide that destroys harmful fungi and their spores. They are usually made of chemicals, but some may use biological agents or substances that inhibit fungal growth. Fungicides can have detrimental impacts on aquatic species that are not the intended target when they spread from the target habitat to various aquatic settings, such as wetlands and streams [7]. Insecticides differ from other organic pollutants in that they are made to be toxic to specific organisms. Because many of the places they affect are similar across different groups of living things, they can also harm non target organisms like fish. These chemicals stayed in the environment for a long time, built up in living things, and harmed fish a lot. Pyrethroids are more favored than other kinds of insecticides, as Lu *et al.*, [8] stated because they are very effective, less toxic to mammals, more selective to pests, and degrade quickly in the environment. Pesticides affect the antioxidant enzyme system of fish by making more and more reactive oxygen species (ROS) and by degrading antioxidant enzymes that shield fish against ROS. A crucial tool for identifying the harmful impact that toxicants may have on organisms is behavior. Pesticides can alter the molecular structure of neurotransmitters and block the enzymes necessary for their manufacture or break down. Pesticides induce several behavioral alterations in fish like surface breathing, tremors in their fins, air gulping, irregular swimming, operculum movement, and hypersecretion

of mucus [9]. Pesticides induce hematological alternations by affecting RBC, WBC and platelets count and histopathological alternations by damaging internal organs of fish such as liver, kidney, gills, intestine and gonads.

Behavioral changes in fish caused by pesticides

Behavior is the physical manifestation of the animal's internal neural, hormonal and metabolic processes necessary for survival [10] working together with both central and peripheral nervous systems [11]. It makes it possible for a living thing to adjust to stimuli from within as well as outside to survive in a changing environment. Behavioral disruption may be detected in aquatic organisms at the concentration of pollutants present in the field. The majority of pesticides disrupt fish neurological systems as well as sensory receptors, which can alter fish behavior and cause abnormalities in how fish react to environmental cues. A study on the behavioral aspects of fish *A. lineatus* after exposure to cypermethrin revealed a range of behavioral alterations during the trial, such as convulsions, violent gasping for air, irregular swimming, and loss of balance. The findings demonstrated that *A. lineatus's* behavioral features can be acutely affected by cypermethrin, even at low doses [12]. The tertiary level of physiological reactions to a toxicant, and behavior responses (like swimming ability) might be utilized as a biomarker of stress. According to Yalsuyiet *al.* [13], the fish (*C. carpio*) preferred to swim close to the water outflow when the level of glyphosate was raised; on the other hand, when the glyphosate level was lowered, the fish swam closer to the water introduction. Zebra fish *Danio rerio* behavior after exposure to the fungicide carbendazim demonstrated aberrant swimming and the gulping of air at the water's surface, reduced aggressiveness, and first aroused slow swimming before eventually causing fast swimming [14]. *Clarias batrachus* showed significant behavioral alterations after treatment with chlorpyrifos and cypermethrin which included altered schooling behavior, positioning at the bottom, aberrant and uneven swimming patterns, frequent surface visits, caudal bending and a delayed reaction to touch [15]. The morphological alterations included thinness of the body, increased mucus discharge, and body decolorization. Exposure to two organophosphate compounds (dimethoate and chlorpyrifos) to *C. carpio* resulted in various alternations in behavior patterns [16]. These changes were observed using different behavioral indices such as tail and opercular beat frequency, fin and eye deformities and swimming velocity and activity index. We can say that different pesticides influence differently on behavioral parameters in fish. These behavioral alternations include excess mucus secretion, loss of body balance, altered opercular movements, loss of movement directions, fast and sometimes backward swimming and higher concentrations of pesticides leading to hemorrhage and ultimately lead to death.

Changes in the antioxidant defense system of fish caused by pesticides

ROS are responsible for the oxidative damage that fish exposed to herbicides experience. Fish have both enzyme-based and non-enzyme-based antioxidant defense systems. Antioxidant defense system activity against ROS is thus indicated by changes in antioxidant enzyme activities and non enzyme antioxidant levels [17]. Hence variations in the antioxidant defense

system of fish act as useful and crucial markers of pesticidal toxicity. One of the most important biological acceptors of electrons for cellular processes is oxygen. Notwithstanding its advantageous characteristics, it is responsible for the unfavorable generation of various kinds of reactive oxygen species (ROS). Cells rely on a series of antioxidant enzymes—including glutathione peroxidase (GPx), glutathione reductase (GR), glutathione S-transferase (GST), xanthine oxidase (XOD), catalase (CAT), and superoxide dismutase (SOD)—to combat reactive oxygen species (ROS) as their initial defense mechanism. Cellular injury and oxidative stress are caused by an imbalance between the activity of cellular enzymes that fight oxidative stress and ROS generation. There's a greater chance of oxidative damage if the antioxidant system cannot get rid of or balance off the surplus ROS.

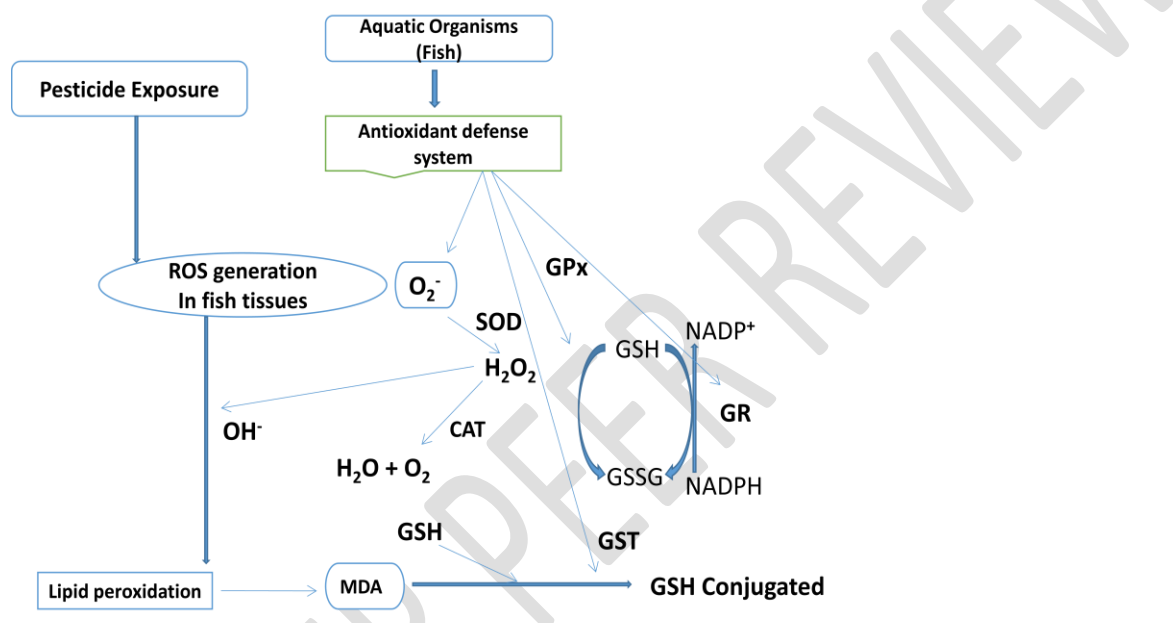


Fig 2: Role of antioxidant defense enzymes to combat the oxidative stress produced due to over-production of ROS after pesticide exposure.

Fishes collected from pesticide-contaminated Ganga River showed an increased amount of CAT, SOD and GST activities [18]. *Mugil capito* exposure to different concentrations of meothrin, lambda-cyhalothrin, permethrin, fenpropathrin, and esfenvalerate to *Mugil capito* showed increased levels of MDA [19]. Impact of Persistent Application of Methomyl Pesticide on Antioxidant Defense System in Tilapia Testis (*Oreochromis niloticus*) showed a significant increase in the GPx, CAT, GST, GR, SOD, GSH and GSSG at low concentrations but a significant decrease at higher concentrations [20]. Oxyfluorfen (herbicide) exposure to Catfish, *C.garipepinus*, there was a notable decline in the activities of SOD, GSH, GPX, and CAT along with the rise in MDA levels [21]. Treatment of juveniles (*Astyanax altiparanae*) with herbicide atrazine showed elevated malondialdehyde (MDA) and protein levels indicators in the liver, muscle and gills, indicating an elevated oxidative unbalance [22]. Additionally, they noted that the antioxidant enzyme GST was more active in the liver and SOD and CAT were more active in

the muscles and gills. The activities of CAT, GPx and SOD in juvenile fish, *Oreochromis mossambicus* were suppressed by carbaryl and dimethoate [23]. The glyphosate exposure to *Galatea paradoxa* resulted in increased activities of GST, LDH, CAT and SOD [24]. Additionally, the data showed reduced GSH concentration and elevated GPx activity in fish *Galatea paradoxa*. The brains of the zebra fish exposed to the highest quantity of glyphosate showed a marked increase in CAT and SOD activity [25]. Additionally, glyphosate-treated fish showed a concentration-dependent suppression of γ -GCL in their brain, which was accompanied by a marked drop in GPx levels. The brains of the animals exposed to the greatest dose of glyphosate showed a marked rise in lipid peroxidation, which was ultimately indicative of this changed profile of the antioxidant defense system. **Therefore, pesticide exposure to fish leads to oxidative stress and there is a significant increase in some oxidative enzymes which can lead to oxidative stress in fish.**

Hematological alternations in fish caused by pesticides

It has been established that hematological indicators are useful instruments for tracking fish health and identifying pesticide toxicity. Both internal and external variables may have an impact on the primary hematological parameters in fish, such as mean corpuscular volume (MCV), mean corpuscular hemoglobin (MCH), mean corpuscular hemoglobin concentration (MCHC), hemoglobin (Hb), and red blood cell (RBC) counts. White blood cell (WBC) counts, red blood cell counts and blood cell histology are all altered by fatal and sub-lethal amounts of different pesticides. An essential diagnostic technique for identifying anomalies in the liver and other tissues is the measurement of blood biochemical markers. Freshwater catfish *Mystus keletius* exposed to Ekalux (EC-25%), Impala (EC-55%), and Neemstar (EC-15%) were found to exhibit decreased values for hematological parameters such as RBC, Hb, and Hct packed cell volume as the duration of pesticide exposure increased [26]. Conversely, values for parameters such as WBC, MCHC, MCV and MCH substantially increased. Anemia symptoms included reduced and malformed erythrocytes along with a decline in hemoglobin levels and packed cell volume (PCV). Anemia symptoms were also noted in the form of malformed erythrocytes. Fish *Clarias Batrachus* treated with imidacloprid showed hematological changes in their blood; the concentrations of Hb, RBCs, packed cell volume (PCV), MCV and MCH were all decreased, while the amounts of WBCs were elevated [27]. According to Das *et al.* [28] hematological measures such as total erythrocyte count (TEC) and Hb count were observed to be lowered while TLC was elevated in freshwater fish, *Labeo rohita* intoxicated with malathion. Zeinab *et al.*, [29] observed changes in hematological indices of *Ctenopharyngodon idella* treated with insecticide profenofos including a rise in TLC and monocytosis, lymphocytosis, and moderate neutrophilia. Major observations that were noted after the exposure were extreme microcytic hypochromic anemia. African catfish (*Clarias gariepinus*) are exposed to sub-lethal concentrations of pesticides that are frequently used in agriculture, including abamectin, carbofuran, chlorpyrifos, cypermethrin, deltamethrin, dichlorvos, dimethoate, fipronil, lambda-cyhalothrin, and paraquat

[30]. Significant variations were found between the mean hematological parameters of the treated and control catfish, including WBC, RBC, Hb, Hct, MCH, and MCHC. Malathion exposure in silver barb fish *Barbonymus gonionotus* was found to cause a concentration and time-dependent increase in WBC, a significant decline in Hb, PCV, and RBC levels, as well as a marked rise in the prevalence and severity of micronucleus during the whole experimental period whereas MCV, MCH, and MCHC readings displayed inconsistent patterns [31]. Hence pesticides have numerous effects on the blood parameters, resulting in changes in RBC, WBC, MCH, MCV and Hb contents which can make fish anemic and immunologically sick.

Histopathological alternation in fish caused by pesticides

Toxicological research and the observation of water pollution might benefit from histopathological examinations of various fish tissues that have been subjected. Tissue changes in fish exposed to different pesticide doses are a functional response of the organisms and describe the specific type of contaminant. We may learn about the condition and operation of organs through histology. Organ tissue harm and trauma can lead to decreased growth, survival, and physical fitness, poor reproductive outcomes, or increased vulnerability to pathogenic agents.

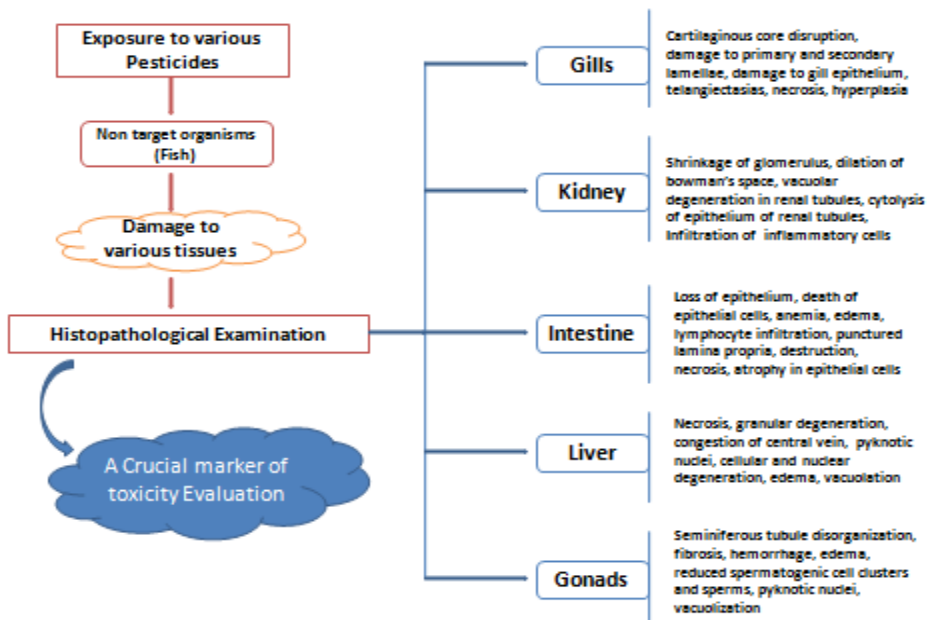


Fig 3: Effects of pesticides on histology of gills, kidney, intestine, liver and gonads offish

Gills

With secondary lamellae on either side, each gill is made up of primary lamellae. In fish under control conditions, normal blood vessels and epithelial cell linings with isolated pillar cells are

observed in the major gill filament which performs various functions including exchange of gases, ammonia and ions. Majumder and Kaviraj [32] observed changes in the histology of the gills of *O. niloticus* after the treatment with cypermethrin. Gill lamellae exhibited intra-lamellar space, necrosis on both sides of the secondary lamellae, and clustered epithelial cells at their base. Along with increased intra-lamellar space on primary gill lamellae, the higher concentration of this pesticide caused tissue death within primary and secondary gill lamellae, degeneration of the secondary lamellae's epithelium, and constricting of secondary lamellae. Different researchers observed similar histopathological alterations after treating different concentrations of cypermethrin on the gills of *C. carpio* [33]. Freshwater fish *C. mrigala* treated with pesticides (Chlorfenapyr, Dimethoate, and Acetamiprid) showed several histological changes in gills such as secondary gill lamellae fusion, secondary gill lamellae epithelium raising, hypertrophy of the gill epithelium, and secondary gill lamellae curving [34]. With the increase in the time of exposure, the extent of the histological changes which included telangiectasias, secondary gill lamellae shortening, cartilaginous core disruption, lamellar disorganization, and lamellar atrophy was also increased in all treated groups. Impacts of synthetic pyrethroid on the histology of gills of common carp showed several alterations like fusion of secondary gill lamellae, degenerated lamellae, vacuolization, necrosis, hyperplasia, ruptured secondary lamellae, vacuolization of gill rakers and vasodilation of central sinus were noticed after the treatment with different concentrations of this pesticide [35]. Research conducted by Shah and Parveen [18] on pesticide-polluted Ganga River on gills of *C. carpio* and *Rita rita* showed sloughing and degradation of lamellar epithelium, vessels dilation, lamellar congestion, gill bridging, inflammatory cell infiltrate, necrosis and hypertrophy in smooth muscles of the gills. Vali *et al.*, [36] studied alterations in the gills of Grass Carp (*Ctenopharyngodon idella*) administered with different amounts of diazinon. Fish gills showed primary lamellar edema, hyperplasia of secondary lamellae, hypertrophy, hemorrhage, shortening and sloughing of secondary lamellae and hypertrophy. Gills of fish exposed to dimethoate exhibited alterations like hyperplasia in the primary lamellae epithelium, shortening, fusion and curling of secondary gill lamellae fusion, infiltration of inflammatory cells hemorrhage and epithelial edema and telangiectasis [37]. Therefore, pesticide damage to gills can result in the breathing ability of fish and the exchange of ions and ammonia, ultimately leading to fish mortality.

Kidney

The kidney of the control fish is constructed from numerous renal tubules and fully formed glomeruli. The kidney helps in discarding body waste and osmoregulation. Majumder and Kaviraj [32] observed changes in the histology of the kidney of *Oreochromis niloticus*. Cypermethrin caused hyaline atrophy in the renal tubular epithelium, glomerulus compression, widening of the gap between the glomerulus and Bowman's capsule, dilatation of the tubular lumen and vacuolation in the epithelium of renal tubules. Nile Tilapia (*Oreochromis niloticus*), carbofuran sub-lethal dosages resulted in glomerular capsule separation, proximal and distal

tubule necrosis, and lack of intercellular space [38]. Nile tilapia treated with sumithion showed a notable morphological alteration in the kidney tissue; glomerular enlargement, dilatation of Bowman's space, pyknotic nuclei, patch atrophy, vacuolation, and a rise in the diameter of the renal tubules were identified at low and high concentrations [39]. Hassan *et al.* [37] investigated changes in the histology of the kidney of Nile tilapia after exposure to dimethoate. Pesticide-exposed kidney showed shrinkage of the glomerulus, dilation of Bowman's space, vacuolar degeneration and cytolysis of renal tubule epithelium and infiltration of inflammatory cells. Hence damage to the kidney structure results in the accumulation of waste material in the fish body which ultimately leads to kidney dysfunctioning.

Intestine

The gut is a multifaceted, intricate organ. The intestine is essential for immunity, digestion and metabolism, water and electrolyte balance, and the breakdown and absorption of food. Numerous contaminants are absorbed and metabolized in large part via the intestines [40]. Vacuolation, tissue necrosis, hemorrhage, degeneration of epithelium, loss of the intestinal villi, aberration, and death of epithelial cells are the common signs that can be seen in the intestinal tissue after the treatment with different pesticides. Butachlor-induced histopathological changes in the intestinal tissue of *Clarias batrachus* showed vascularization in the sub mucosal areas, hemorrhagic areas, up surge in goblet cells and lymphocyte infiltration in the absorptive region of the intestine [41]. Significant degradation of the villi's brush border, punctured lamina proportion, high degree of lymphocytic infiltration in the mucosa layer, damaged basal lamina, and the existence of many vacuoles in the sub-mucosal and muscular layer are all signs of the significant deterioration in the brush border region. Histological effects of lindane, an organochlorine pesticide, on the intestinal tissue of the teleost fish *C. punctatus* were observed by Bhattacharjee and Das [42]. According to this study, lindane exposure resulted in edema in epithelial cells, expansion in Goblet cells, invasion of inflammatory cells into intestinal tissues, and necrosis. The toxicity of chlorpyrifos impacted the diversity of the gut microbiota and promoted the growth of pathogenic microorganisms that compromise the intestinal immune system and lead to infection [43]. Pesticides can damage intestinal structure which can lead to various disorders like digestion and absorption of food, electrolyte imbalance and loss of immunity which can make fish sick.

Liver

The liver shields the body against substances ingested through the gastrointestinal system, gills, and skin that may be hazardous. Necrosis, hemorrhage, degeneration of cytoplasm and nuclei, infiltration of blood cells, hypertrophy, congestion of nuclei and heterochromatin distribution are some of the major histopathological anomalies which can be observed by histopathological investigation after the treatment of different pesticides. Cattaneo *et al.* [44] documented disruption in the connections of hepatocytes, disruption of the cellular membrane, and vacuolated cytosol in the hepatic tissue of *Rhamdia quelen*, following exposure to 2,4-D herbicide. Experiments conducted by Norhan *et al.* [45] on paraquat-induced histopathological changes in

liver tissues of *Anabas testudineus*. Treated exhibited many alterations like necrosis, and cell degeneration following a 96-hour exposure to this pesticide. Paraquat exposure at 15.0 mg/L resulted in hemorrhage, necrosis, hydropic degeneration, and pyknosis. The study by Velmurugan *et al.* [46] was done to investigate the toxicity of cypermethrin on the histology of the liver of *Anabas testudineus*. The study revealed that exposure to this pesticide caused several histological changes like pycnotic nucleus, dilatation of sinusoids, hypertrophy of liver cells, necrosis, granular degeneration and congestion. Hassan *et al.* [37] noticed various histopathological changes in the liver of dimethoate-exposed tilapia fish like congestion of the central vein, vacuolar degeneration of the liver cells, dilatation and congestion of sinusoid, aggregation of inflammatory cells, necrosis and hemorrhage. Shah and Praveen [18] researched pesticide-polluted Ganga River. Liver tissues of the fish *Rita rita* collected from the Narora site showed various necrotic changes in hepatocytes and distorted arterial walls. Natraj *et al.*, [47] observed pyknosis in the nucleus, vacuolation, nuclear degradation and cellular edema on the liver tissue of freshwater fish, *Labeo rohita* exposed to profenofos. These studies indicate that pesticide damage to the liver leads to the accumulation of various waste materials which can make fish sick.

Gonads

The tiny diameters of the impacted cells make it challenging to examine some insecticide-induced histopathological alterations in the testes under light microscopy. The research was done by Marutirao [48] to study the histopathological alterations after dimethoate exposure on ovarian tissue of *Puntius ticto*. Following fatal exposure, the ovary displayed notable alterations. Ovarian follicles were partially disrupted, and vacuolation was observed in the cytoplasm of germinal cells. There was an injury to the interfollicular connective tissue. The normal layout of ovarian follicles was lost. There was evidence of injury to the yolk vesicles of developing oocytes as well as necrosis and fibrosis in the connective tissue. Biju *et al.*, [49] conducted research to study exposure-dependent changes in the ovary of Freshwater Fish, *Oreochromis niloticus* after treatment with Malathion. Various alterations like reduced size of mature oocytes, degradation of tissue cells, destruction of follicular epithelium, fractured ova, necrosis, and degradation of the ovarian structure were seen. Ezenwosu *et al.* [50] investigated the harmful effects of lambda-cyhalothrin on the histo-architecture of gonads (testes and ovaries) of *Clarias gariepinus*. Testes of the treated animals showed some damaging alterations like clusters of necrotic spermatogenic cells exhibiting nuclear pyknosis and cytoplasmic swellings. Various changes like degenerative matured flabby and vacuolated oocytes and nuclear pyknosis were seen in the ovaries. A study aimed to assess mancozeb's acute toxicity on the testis of zebrafish (*Danio rerio*) was performed by Gürol *et al.* [51]. Spermatogenic cell degeneration, seminiferous tubule disorganizations, fibrosis, hemorrhage, vacuolization, spermatocyte hypertrophy, edema, reduced spermatogenic cell clusters and sperms, and pyknotic and karyolytic nuclei were all brought on by mancozeb. These findings show that mancozeb might stop zebra fish from reproducing and lower their fertilization ratio. Numerous histological alterations were seen in the

ovary of female gangetic fish *Mystus cavasius* by Uddin *et al.* [52] after exposure to cypermethrin. With increasing cypermethrin concentration and exposure period, wrinkle oocyte, cytoplasmic clumping, atretic follicle, degraded granulose layer, distorted oocyte wall, increased inter follicular space, adhesion, cyst, and necrosis were seen. Pesticides can cause severe damage to fish reproductive organs which can halt the development, maturation, and sexual differentiation of fetuses in fish.

Conclusion

To summarize, the analysis of the available research indicates that exposure to pesticides triggers antioxidant defenses and detoxification pathways by causing the activation of antioxidant enzymes. However, the use of pesticides, whether they were acute or long-term, changed hematological, biochemical, and immunological parameters in the fish. Histopathological studies revealed that pesticides have dangerous effects on the liver, kidney, intestine, gills and gonads which lead to tissue degeneration, necrosis, degeneration of cells, bleeding in some tissues, vacuolization and many more harmful effects which can lead to mortality in fish. Pesticides have harmful effects on gonadal activity and the development stages of fish which can lead to juvenile mortality. Pesticide effects on behavior include irregular movements, skin irritation, bleeding from gills, backward swimming, excessive mucus secretion and lack of orientation. Furthermore, these pesticides accumulate in the food chain and go to higher tropic levels which include humans through bio-magnification which results in serious and long-term effects. Studies have indicated that the use of pesticides in aquatic habitats may have negative consequences for fish immunity and mangroves, which could worsen the ecological impact by making fish more susceptible to disease. The present review has accumulated valuable evidence indicating that human activities such as use of large quantities of chemical pesticides has harmful effects on numerous sectors such as aquaculture and fisheries. These changes may affect the survival or life of fish in water bodies. Hence, we need to implement alternatives for these toxic substances (pesticides) like organic farming, Integrated Pest Management (IPM), biological control techniques and genetic modification techniques in crops.

Disclaimer (Artificial intelligence)

Option 1:

Author(s) hereby declare that NO generative AI technologies such as Large Language Models (ChatGPT, COPILOT, etc) and text-to-image generators have been used during writing or editing of manuscripts.

We hereby declare that no generative AI technologies are used and no text to image generators has been used during the writing of this review article it is purely based upon the knowledge of pervious research conducted by researchers.

Option 2:

Author(s) hereby declare that generative AI technologies such as Large Language Models, etc have been used during writing or editing of manuscripts. This explanation will include the name, version, model, and source of the generative AI technology and as well as all input prompts provided to the generative AI technology

Details of the AI usage are given below:

- 1.
- 2.
- 3.

References

1. Tharmavaram M, Pandey G, Bhatt P, Prajapati P, Rawtani D, Sooraj KP, Ranjan M. Chitosan functionalized Halloysite Nanotubes as a receptive surface for laccase and copper to perform degradation of chlorpyrifos in aqueous environment. *International Journal of Biological Macromolecules*. 2021;191:1046-1055. <https://doi.org/10.1016/j.ijbiomac.2021.09.098>
2. Saroop S, Tamchos S. Impact of pesticide application: Positive and negative side. *Pesticides in a Changing Environment*. 2024 Jan 1:155-78. <https://doi.org/10.1016/B978-0-323-99427-9.00006-9>
3. Ghafarifarsani H., Fazle Rohani M., Raeeszadeh M., Ahani S., Yousefi M., Talebi M., Sazzad Hossain M.. Pesticides and heavy metal toxicity in fish and possible remediation – a review. *Annals of Animal Science*. 2024;0(0) <https://doi.org/10.2478/aoas-2024-0012>
4. Somlyai I, Berta C, Nagy SA, Dévai G, Ács É, Szabó LJ, Nagy J, Grigorszky I. Heterogeneity and anthropogenic impacts on a small lowland stream. *Water*. 2019 Sep 26;11(10):2002. DOI:[10.3390/w11102002](https://doi.org/10.3390/w11102002)
5. Arjmandi R, Tavakol M, Shayeghi M. Determination of organophosphorus insecticide residues in the rice paddies. *International journal of environmental science & technology*. 2010;7:175-182. DOI:[10.1007/BF03326129](https://doi.org/10.1007/BF03326129)
6. Tang FH, Lenzen M, McBratney A, Maggi F. Risk of pesticide pollution at the global scale. *Nature geoscience*. 2021;14(4):206-210. DOI:[10.1038/s41561-021-00712-5](https://doi.org/10.1038/s41561-021-00712-5)

7. Wang N, Wang Y, Sun A, Zhang Z, Shi X. Accumulation and elimination properties and comparative toxicity of fluxapyroxad in juvenile and adult large yellow croaker (*Larimichthys crocea*). *Science of The Total Environment*. 2024 Feb 20;912:168979.
8. Lu Z, Gan J, Cui X, Delgado-Moreno L, Lin K. Understanding the bioavailability of pyrethroids in the aquatic environment using chemical approaches. *Environment international*. 2019;129:194-207 <https://doi.org/10.1016/j.envint.2019.05.035>
9. Wang, J. Q., Hussain, R., Ghaffar, A., Afzal, G., Saad, A. Q., Ahmad, N., Nazir, U., Ahmad, H. I., Hussain, T., & Khan, A. (2022). Clinicohematological, Mutagenic, and Oxidative Stress Induced by Pendimethalin in Freshwater Fish Bighead Carp (*Hypophthalmichthys nobilis*). *Oxidative medicine and cellular longevity*, 2022, 2093822. <https://doi.org/10.1155/2022/2093822>.
10. Perez MH, Wallace WG. Differences in prey capture in grass shrimp, *Palaemonetes pugio*, collected along an environmental impact gradient. *Archives of Environmental Contamination and Toxicology*. 2004;46:81-90. DOI: [10.1007/s00244-002-0249-9](https://doi.org/10.1007/s00244-002-0249-9)
11. Baatrup E. Measuring complex behavior patterns in fish—effects of endocrine disruptors on the guppy reproductive behavior. *Human and Ecological Risk Assessment*. 2009;15(1):53-62. DOI: [10.1080/10807030802615097](https://doi.org/10.1080/10807030802615097).
12. Elayi M, Williams S. Effect of Agricultural Pesticide, Cypermethrin on Changes in Behavioural and Protein profile of larvivorous fish *Aplocheilichthys lineatus*. *International Journal of Ecology and Environmental Sciences*. 2024. <https://doi.org/10.55863/ijees.2024.0286>
13. Yalsuyi AM, Vajargah MF, Hajimoradloo A, Galangash MM, Prokić MD, Faggio C. Evaluation of behavioral changes and tissue damages in common carp (*Cyprinus carpio*) after exposure to the herbicide glyphosate. *Veterinary Sciences*. 2021;8(10):218. <https://doi.org/10.3390/vetsci8100218>.
14. de Oliveira MR, Profeta IV, Saraiva Raimondi Lopes JV, Costa RM, Matos e Chaib VR, Domingues AG, Beirão MV, Santos Rubio KT, Martucci ME, Eskinazi-Sant'Anna EM, de Azevedo CS. Effects of the fungicide carbendazim on the behaviour of the zebrafish *Danio rerio* (Cypriniformes, Cyprinidae). *acta ethologica*. 2024 Feb 16:1-1. <https://doi.org/10.17632/6dmxvjjr66.1>.
15. Kumar R, Kumari R, Mishra BK. Behavioural and morphological changes induced in the freshwater fish, *Clarias batrachus* exposed to chlorpyrifos 50%+ cypermethrin 5% EC. *Journal of Entomology and Zoology Studies*. 2020; 8(5): 1742-1745. DOI: [10.1016/S0045-6535\(03\)00106-1](https://doi.org/10.1016/S0045-6535(03)00106-1).
16. Khan S, Qayoom I, Balkhi MH, Abubakr A, Rashid S, Alsaffar RM, Rehman MU. Behavioural incongruities in juvenile *Cyprinus carpio* exposed to organophosphate compounds. *Heliyon*. 2022 Nov 1;8(11). <https://doi.org/10.1016/j.heliyon.2022.e11227>
17. Banaee, M. (2023). Toxicological Interaction Effects of Herbicides and the Environmental Pollutants on Aquatic Organisms. *IntechOpen*. doi: [10.5772/intechopen.105843](https://doi.org/10.5772/intechopen.105843).

18. Shah ZU, Parveen S. Oxidative, biochemical and histopathological alterations in fishes from pesticide contaminated river Ganga, India. *Scientific Reports*. 2022 Mar 7;12(1):3628. DOI: [10.1038/s41598-022-07506-8](https://doi.org/10.1038/s41598-022-07506-8)
19. Abd El Megid A, Abd Al Fatah ME, El Asely A, El Senosi Y, Moustafa MM, Dawood MA. Impact of pyrethroids and organochlorine pesticides residue on IGF-1 and CYP1A genes expression and muscle protein patterns of cultured Mugil capito. *Ecotoxicology and environmental safety*. 2020;188:109876. DOI: [10.1016/j.ecoenv.2019.109876](https://doi.org/10.1016/j.ecoenv.2019.109876).
20. Meng S, Chen X, Song C, Fan L, Qiu L, Zheng Y, Chen J, Xu P. Effect of Chronic Exposure to Pesticide Methomyl on Antioxidant Defense System in Testis of Tilapia (*Oreochromis niloticus*) and Its Recovery Pattern. *Applied Sciences*. 2021; 11(8):3332. <https://doi.org/10.3390/app11083332>
21. El-Houseiny W, Anter RGA, Arisha AH, Mansour AT, Safhi FA, Alwutayd KM, Elshopakey GE, Abd El-Hakim YM, Mohamed EMM. Growth Retardation, Oxidative Stress, Immunosuppression, and Inflammatory Disturbances Induced by Herbicide Exposure of Catfish, *Clarias gariepinus*, and the Alleviation Effect of Dietary Wormwood, *Artemisia cina*. *Fishes*. 2023; 8(6):297. <https://doi.org/10.3390/fishes8060297>
22. Silva SB, Gregório KP, de Freitas RM, Destro AL, Salaro AL, Zuanon JA, Gonçalves RV, Freitas MB. EXPOSURE TO THE HERBICIDE ATRAZINE INDUCES OXIDATIVE IMBALANCE, MORPHOLOGICAL DAMAGE AND DECREASED SURVIVAL IN JUVENILE FISH. *Bioscience Journal*. 2023;39. <https://doi.org/10.14393/BJ-v39n0a2023-65784>.
23. Ndlovu R, Basopo N. Pesticide-Induced Alterations of Esterase and Antioxidant Enzymes of Aquatic Organisms *Oreochromis mossambicus* and *Xenopus laevis*. *Advances in Biological Chemistry*. 2022;12(6):292-305. DOI: [10.4236/abc.2022.126023](https://doi.org/10.4236/abc.2022.126023).
24. Osiona E, Ezugworie TT. Comparative evaluation of antioxidant enzymes, lipid peroxidation, nitric oxide, and non-microsomal oxidases in *Galatea paradoxa* exposed to varying concentrations of 'uproot' a glyphosate-based herbicide. *Egyptian Journal of Aquatic Biology and Fisheries*. 2022;26(3):213-228. DOI: [10.21608/EJABF.2022.239713](https://doi.org/10.21608/EJABF.2022.239713)
25. Faria M, Bedrossiantz J, Ramírez JR, Mayol M, García GH, Bellot M, Prats E, Garcia-Reyero N, Gómez-Canela C, Gómez-Oliván LM, Raldúa D. Glyphosate targets fish monoaminergic systems leading to oxidative stress and anxiety. *Environment international*. 2021;146:106253. <https://doi.org/10.1016/j.envint.2020.106253>.
26. Barathinivas A, Ramya S, Neethirajan K, Jayakumararaj R, Pothiraj C, Balaji P, Faggio C. Ecotoxicological effects of pesticides on hematological parameters and oxidative enzymes in freshwater Catfish, *Mystus keeltingi*. *Sustainability*. 2022;14(15):9529. <https://doi.org/10.3390/su14159529>.

27. Tokriya RK, Billore K. HEMATOLOGICAL CHANGES INDUCED BY IMIDACLOPRID IN *CLARIAS BATRACHUS* (MAGUR). Int. J. Adv. Res. 2024;. 12(01), 546-555. <http://dx.doi.org/10.21474/IJAR01/18153>
28. Das BK, Nayak KK, Kumar V. Alteration of haematological and biochemical biomarkers after sub-lethal chronic malathion (Elathion®) intoxication in freshwater fish, Labeorohita (Hamilton, 1822). Comparative Biochemistry and Physiology Part C: Toxicology & Pharmacology. 2024;277:109844. <https://doi.org/10.1016/j.cbpc.2024.109844>.
29. El-Bouhy ZM, Mohamed FA, Elashhab MW, El-Houseiny W. Toxicity bioassay and sub-lethal effects of profenofos-based insecticide on behavior, biochemical, hematological, and histopathological responses in Grass carp (*Ctenopharyngodonidella*). Ecotoxicology. 2023;32(2):196-210. <https://doi.org/10.1007/s10646-023-02628-9>.
30. Amaeze NH, Komolafe BO, Salako AF, Akagha KK, Briggs TM, Olatinwo OO, Femi MA. Comparative assessment of the acute toxicity, haematological and genotoxic effects of ten commonly used pesticides on the African Catfish, *Clarias gariepinus* Burchell 1822. Heliyon. 2020;6(8). <https://doi.org/10.1016/j.heliyon.2020.e04768>.
31. Mrong CE, Islam MR, Kole K, Neepa NN, Alam MJ, Haque MR, Rahman UO, Mostakim GM. Malathion-Induced Hematotoxicity and Its Recovery Pattern in *Barbonymus gonionotus*. Journal of Toxicology. 2021;2021(1):9417380. <https://doi.org/10.1155/2021/9417380>
32. Majumder R, Kaviraj A. Histopathological alterations of gills, liver and kidney of freshwater fish, *Oreochromis niloticus*, exposed to Cypermethrin. Journal of Aquatic Biology & Fisheries. 2022;10(1):1-5.
33. Arslan H, Özdemir S, Altun S. Cypermethrin toxication leads to histopathological lesions and induces inflammation and apoptosis in common carp (*Cyprinus carpio* L.). Chemosphere. 2017;180:491-499. DOI: [10.1016/j.chemosphere.2017.04.057](https://doi.org/10.1016/j.chemosphere.2017.04.057)
34. Ghayyur S, Khan MF, Tabassum S, Ahmad MS, Sajid M, Badshah K, Khan MA, Ghayyur S, Khan NA, Ahmad B, Qamer S. A comparative study on the effects of selected pesticides on hemato-biochemistry and tissue histology of freshwater fish *Cirrhinus mrigala* (Hamilton, 1822). Saudi Journal of Biological Sciences. 2021;28(1):603-11. DOI: [10.1016/j.sjbs.2020.10.049](https://doi.org/10.1016/j.sjbs.2020.10.049).
35. Verma J, Sharma S, Thakur DR. Impact Assessment of Cypermethrin (A Pyrethroid) Induced Chronic Toxicity on Vitals of Adult *Cyprinus carpio* L. UTTAR PRADESH JOURNAL OF ZOOLOGY. 2023;44(23):46-51. <https://doi.org/10.56557/upjz/2023/v44i233762>.
36. Vali S, Majidiyan N, Azadikhah D, Varcheh M, Tresnakova N, Faggio C. Effects of Diazinon on the survival, blood parameters, gills, and liver of grass carp (*Ctenopharyngodonidella Valenciennes, 1844; Teleostei: Cyprinidae*). Water. 2022;14(9):1357. DOI: [10.3390/w14091357](https://doi.org/10.3390/w14091357).

37. HASSAN SS, ALI MF, IDRIS SK, Khairy M. Histopathological and biochemical studies on the acute toxicity of Dimethoate on Nile tilapia Fish. *Assiut Veterinary Medical Journal*. 2024;70(180):187-202.
<https://doi.org/10.21608/avmj.2023.232748.1183>.
38. Américo-Pinheiro JH, Machado AA, da Cruz C, Aguiar MM, Ferreira LF, Torres NH, Machado-Neto JG. Histological changes in targeted organs of Nile tilapia (*Oreochromis niloticus*) exposed to sublethal concentrations of the pesticide carbofuran. *Water, Air, & Soil Pollution*. 2020;231(5):228.DOI:[10.1007/s11270-020-04628-5](https://doi.org/10.1007/s11270-020-04628-5).
39. Sharmin S, Islam MT, Sadat MA, Jannat R, Alam MR, Shahjahan M. Sumithion induced structural erythrocyte alteration and damage to the liver and kidney of Nile tilapia. *Environ Sci Pollut Res Int*. 2021;28(27):36695-36706. DOI:[10.1007/s11356-021-13263-4](https://doi.org/10.1007/s11356-021-13263-4)
40. Yuen BB, Wong CK, Woo NY, Au DW. Induction and recovery of morphofunctional changes in the intestine of juvenile carnivorous fish (*Epinephelus coioides*) upon exposure to foodborne benzo [a] pyrene. *Aquatic toxicology*. 2007;82(3):181-94.DOI:
[10.1016/j.aquatox.2007.02.010](https://doi.org/10.1016/j.aquatox.2007.02.010).
41. Chand GB, Verma P, Singh P, Prasad S. Butachlor induced serum biochemical anomalies correlated with histopathological changes in intestinal tissue of *Clarias batrachus*(LINN.): in-vivo study. *UTTAR PRADESH JOURNAL OF ZOOLOGY*. 2021;42(8):18-28.
42. Bhattacharjee D, Das S. Intestinal histopathology as a biomarker for lindane toxicity in teleost fish, *Channa punctata*. *Global Journal of Biology Agriculture and Health Sciences*. 2015;4(3):16-18.
43. Fang B, Li JW, Zhang M, Ren FZ, Pang GF. Chronic chlorpyrifos exposure elicits diet-specific effects on metabolism and the gut microbiome in rats. *Food and chemical toxicology*. 2018;111:144-152.. <https://doi.org/10.1016/j.fct.2017.11.001>
44. Cattaneo R, Loro VL, Spanevello R, Silveira FA, Luz L, Miron DS, Fonseca MB, Moraes BS, Clasen B. Metabolic and histological parameters of silver catfish (*Rhamdia quelen*) exposed to commercial formulation of 2, 4-dichlorophenoxyacetic acid (2, 4-D) herbicide. *Pesticide Biochemistry and Physiology*. 2008;92(3):133-137.
<http://dx.doi.org/10.1016/j.pestbp.2008.07.004>.
45. Norhan NA, Zakariah MI, Karim NU, Daud HM, Melad AA, Yusoff NA, Hassan MA. Paraquat-induced histopathological changes on the gills, kidney and liver tissues of *Anabas testudineus* (bloch 1792). *J Sustain Sci Manag*. 2022;17:165-174.
<https://doi.org/10.46754/jssm.2022.08.010>.
46. Velmurugan B, Satar EI, Yolcu M, Uysal E. Effects of Cypermethrin on Serum Biochemistry and Liver Histopathology of *Anabas testudineus*. *Journal of Chemical Health Risks*. 2024;14(1). <https://doi.org/10.22034/jchr.2023.1948154.1479>.
47. Nataraj B, Hemalatha D, Rangasamy B, Maharajan K, Ramesh M. Hepatic oxidative stress, genotoxicity and histopathological alteration in fresh water fish *Labeorohita*

- exposed to organophosphorus pesticide profenofos. *Biocatalysis and Agricultural Biotechnology*. 2017;12:185-190. <http://dx.doi.org/10.1016/j.bcab.2017.09.006>.
48. Marutirao GR. Histopathological changes in the ovary of freshwater fish *Puntius ticto* (Ham) under dimethoate toxicity. *The Bioscan*. 2013;8(3):989-992.
49. Biju A, Remya Devi GS, Sreejai R. Histopathological Impact of Organophosphorus Pesticide, Malathion on the Ovary of Freshwater Fish *Tilapia niloticus* (Linnaeus, 1758). *Journal of Aquatic Biology & Fisheries*. 2020;8:97-100.
50. Ezenwosu SU, Nnamonu EI, Odo GE, Ikele BC, Ani OC. Evaluation of lambda-cyhalothrin oxidative stress and gonad histoarchitecture toxicity potency in *Clarias gariepinus*. *The journal of basic and applied zoology*. 2021;82:1-1. <https://doi.org/10.1186/s41936-020-00201-y>.
51. Gürol MA, Arman S, Yön ND. Effects of mancozeb on the testicular histology of the zebrafish (*Danio rerio*). In *Annales de Limnologie-International Journal of Limnology* 2020 (Vol. 56, p. 10). EDP Sciences. <http://dx.doi.org/10.1051/limn/2020009>.
52. Uddin MH, Ali MH, Sumon KA, Shahjahan M, Rashid H. Effects of pyrethroid pesticide cypermethrin on the gonad and hemato-biochemical parameters of female gangeticmystus (*Mystuscavasius*). *Aquaculture Studies*. 2022;22(3). DOI : [10.4194/AQUAST819](https://doi.org/10.4194/AQUAST819).