

A case report on Cerebral Gliomatosis: Challenges in delayed diagnosis and management

Abstract:

Aim : The aim of this study is to reveal the difficulties in delayed diagnosis and management of the Cerebral Gliomatosis : a rare primary infiltrative neoplasia of the brain.

Presentation of the case : It's about 9 years old girl with no specific symptoms like headaches with balance disorder and speech disorder that last for more than 2 months.

The paraclinical exams of the brain (MRI,spectrometry and stereotactic biopsy) can put the diagnosis.

Discussion :

Cerebral Gliomatosis (CG) is a rare primary infiltrative neoplasia of the brain characterized by diffuse glial proliferation affecting at least both cerebral lobes . The difficulties to diagnosis this pathology and to manage it like in the case of that young girl is because there's no specific symptoms and to the delayed diagnosis to . In fact the clinical signs are unspecific and highly variable and depending on the areas of the brain affected, the patient's age and the rate of tumor growth.

Conclusion :

The difficult diagnosis of the Cerebral Gliomatosis is based on a combination of morphological and histological criteria.

Spectroscopic imaging is of diagnostic and prognostic interest.

Keywords : Cerebral Gliomatosis,diagnosis,management,pediatric neurooncology.

Introduction:

Gliomatosis cerebri (GC) is a very rare primary brain tumour, characterized by diffuse and extensive infiltration of neoplasia global cells in more than two contiguous cerebral lobes. Characteristically, it can cross the midline and affect both hemispheres, more frequently affecting the brain but also the brainstem and spinal cord.

In 2016, the WHO histological classification of brain tumors no longer considers Gliomatosis cerebri (GC) as a distinct pathological identity. GC is a group of clinical and radiological signs (based on MRI findings) and histological examination of the tumor is performed to confirm the glial nature of the tumor.

The case report :

This is a 9-year-old girl presenting with headache and balance disorders for 1 month.

Clinical examination revealed phasic disorders, decreased muscle strength, normal osteoarticular reflexes, cerebellar syndrome and bilateral papilledema.

MRI showed diffuse T1-hypointense and T2-hyperintense subcortical areas involving cerebral and cerebellar white matter, the splenium, corpus callosum and basal ganglia, with no circumscribed mass and no enhancement after gadolinium injection.

Spectrometry showed a moderately increased choline/creatin ratio, a lower NAA/Cr ratio and a choline/NAA ratio >2.5, as well as increased creatine and myoinositol.

Stereotactic biopsy allowed the diagnosis of astrocytic cerebral Gliomatosis.

Discussion:

GC is rare diffuse disease of the nervous system currently defined in the WHO classification as an infiltrating high-grade glial lesion involving at least two lobes of the brain.

In 2015, Goerge et al. reviewed the literature over a 15-year period and described 88 GC patients aged from 4 months to 21 years with a mean age of 11.7 years and a male preponderance with a sex ratio of 1.7. There are no specific signs, but the most frequently observed symptoms are: seizures, headaches, memory loss, personality disorders, vision problems, loss of balance, fatigue, muscle weakness, sensory disorders, personality disorders and intracranial hypertension...Focal neurological signs may appear secondarily.

At present, the difficult diagnosis is based on a combination of morphological and histological criteria [1].

On nuclear magnetic resonance, the morphological criteria are as follows:

- Diffuse tumor infiltration reaching more than two cerebral lobes, with infratentorial or even medullary extension.
- The basal ganglia, corpus callosum, thalamus, hypothalamus and brainstem may be involved.

Histology reveals oligodendrocytic and/or astrocytic glial proliferation, generally without specificity, with WHO grade varying between grade II, III or IV [2]. Spectroscopic imaging provides additional support for the diagnosis of GC [3,4].

The main spectral changes described in the context of GC concern the following metabolites [3]:

- N-Acetyl Aspartate (NAA): a marker of neuronal integrity is decreased in GC.
- Creatine (Cr): reflecting the energy metabolism of normal brain tissue, is less diminished in GC than in low-grade gliomas (GBG).
- Choline (Cho): linked to membrane activity, is higher in GBG than in GC.
- Myoinositol (Ino): marker of glial activation is increased in GC and GBG but not in glial tumors.

The study of spectrometry data proves to be relevant in determining several ratios of the different metabolites observed.

In our case, for example, the Cho/NAA ratio was increased, while the NAA/Cr ratio was reduced, suggesting a tumoral origin [3,5].

Furthermore, according to the literature, the significant elevation of Cho/NAA ratios (>2.5) would be in favour of a high histological grade of GC [5].

Levier et al [6] recently retrospectively studied 15 cases of patients managed for cerebral Gliomatosis. Spectroscopic study of Gliomatosis revealed a higher peak in creatine and myoinositol for astrocytic infiltrations compared with oligodendroglial infiltrations ($p < 0.01$).

At present, there is no standard treatment for GC, the disease progresses rapidly and most patients succumb to it within the first few months or even years of diagnosis. Various treatment strategies such as surgery, radiotherapy or chemotherapy have so far proved ineffective.[7,8]

Conclusion:

Cerebral gliomatosis is a rare form of glial tumor with an insidious onset. Its late diagnosis and inoperability pose a major prognostic problem.

So far, no therapeutic protocol appears to be effective. Resonance spectrometry is a valuable adjunct to diagnosis and prognosis.

Ethical Approval:

As per international standards or university standards written ethical approval has been collected and preserved by the author(s).

Consent

As per international standards, parental written consent has been collected and preserved by the author(s).

Disclaimer (Artificial intelligence)

Option 1:

Author(s) hereby declare that NO generative AI technologies such as Large Language Models (ChatGPT, COPILOT, etc) and text-to-image generators have been used during writing or editing of manuscripts.

Option 2:

Author(s) hereby declare that generative AI technologies such as Large Language Models, etc have been used during writing or editing of manuscripts. This explanation will include the name, version, model, and source of the generative AI technology and as well as all input prompts provided to the generative AI technology

Details of the AI usage are given below:

- 1.
- 2.
- 3.

Bibliography :

[1] Goerge E, Settler A, Connors S and Greenfield JP, Pediatric Gliomatosis Cerebri: A review of 15 years . **J. Child Neurol (2016)31. 378-387.**

[2]Lantos PL, Bruner JM, Gliomatosis Cerebri In Kleihues.

Pathology and genetics Tumors of the Nervous System. **The International Agency for Research on Cancer Lyon 1997,65-66.**

[3]Peretti Viton P, Brunel H, Chinot O et al. Histological and MR correlations in Gliomatosis Cerebri. **Journal of neurooncology 2002,59.249-59.**

[4]Galanaus D, Chinot O, Nicoli F et al, Use of proton magnetic resonance spectroscopy of the brain to differentiate gliomatosis Cerebri from low-grade Gliomatosis. **J Neurosurg 2003,98,269-76.**

[5] Saraf-lavi E, Bowen BC, Pattany PM,Proton MR spectroscopy of gliomatosis cerebri: case report of elevated myoinositol with normal choline levels. **AJNR 2003. 24,94651.**

[6]Bendzus M,Warmuth , Klein R et Al. MR spectroscopy in Gliomatosis Cerebri .MR spectroscopy in Gliomatosis Cerebri. **A. JNR 2000, 21,375-80.**

[7] Levin N , Linetsky E, Siegal T, Gliomatosis Cerebri: Proton ME spectroscopy (¹H-MRS) features, **Neurology 2004, 62 (suppl 5) A470.**

[8] Gliomatose cérébrale envahissant la substance grise chezl'enfant: une entité distincte? Étude multicentrique de 14 cas .
Neurochirurgie 57, septembre 2011,266,s4-6.

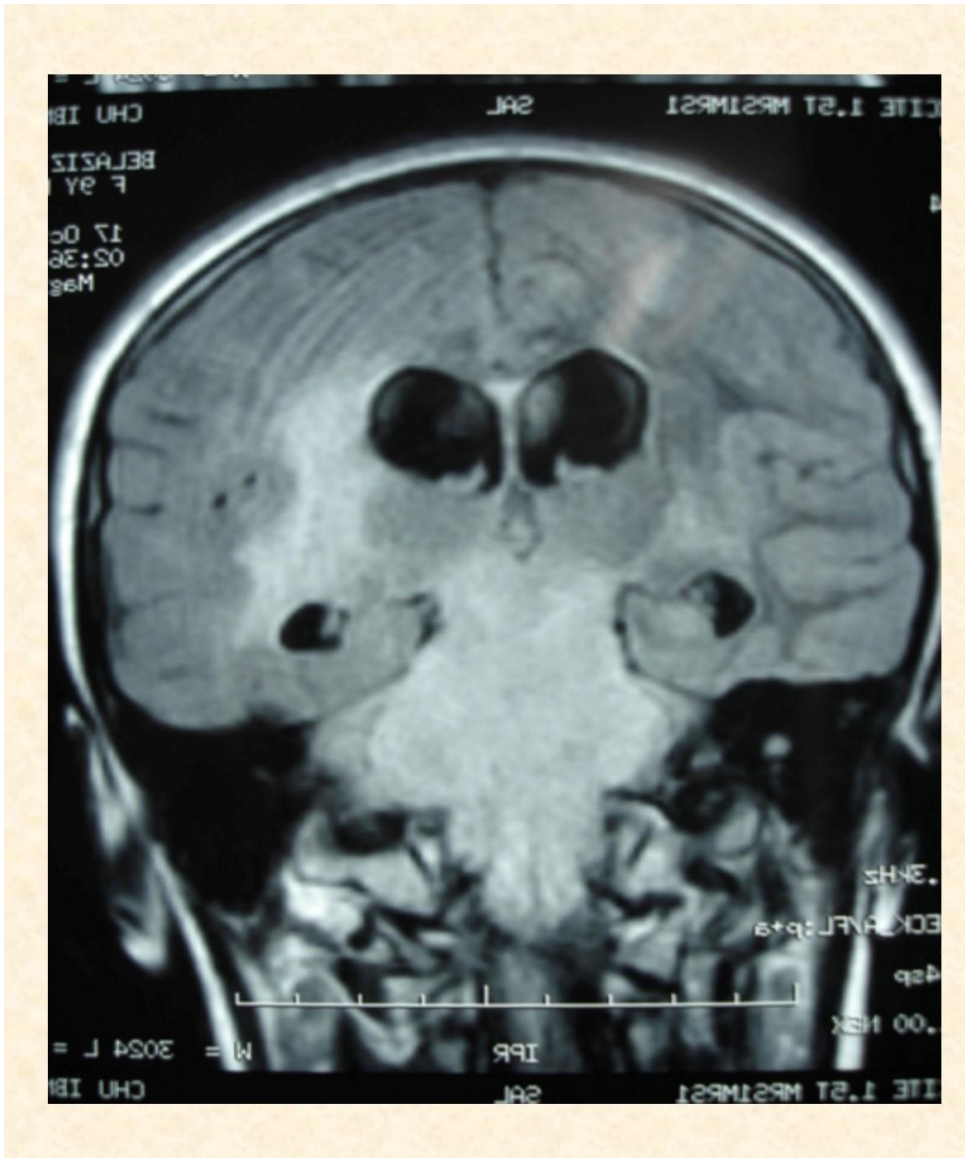


Fig 1. Cerebral Gliomatosis

Fig 2. Scan report

