

A HIDDEN TREASURE TROVE: THE CASE OF PERSISTENT PRIMARIES

ABSTRACT –

Background

Hamartomas are benign, abnormal growths composed of tissues normally found in the affected area. Unlike tumors, they do not have the capacity for uncontrolled growth or metastasis. While uncommon in the oral cavity, they can occur and present unique diagnostic challenges

Case presentation

A 12-year-old female patient reported to the department of oral medicine and radiology with a chief complaint of over-retained deciduous teeth in upper front region of jaw. Accidentally, on radiographical investigation a hamartomatous tooth-like radio-opacity was discovered in the anterior maxilla, which was hidden without any clinical signs and symptoms.

Conclusion

Compound odontomas classified as hamartomatous lesion. They are developmental anomalies and are found only during radiographic examinations. They can cause complications such as tooth impactions, malocclusion and may cause craniofacial abnormalities. Thus early identification of odontomas results in more manageable and cost-effective treatment options, as well as a better prognosis.

Keywords: Hamartomas, Maxillary Anterior Region, Tooth-Like Growth

INTRODUCTION –

“The term hamartoma is derived from the Greek word “hamartia” referring to a defect or an error. It was originally coined by Albrecht in 1904 to denote developmental tumour-like malformations. It can be defined as a non-neoplastic, unifocal/multifocal, developmental malformation, comprising a mixture of cytologically normal mature cells and tissues which are indigenous to the anatomic location, showing disorganized architectural pattern with predominance of one of its components. According to Reichart and Philipsen and the World Health Organization (WHO) 2005, compound and complex odontomas are hamartomatous lesions. They have a relative frequency of 4.2–73.8% and 5–30%, respectively. Associated syndromes include Gardner's and Hermann's syndromes”.⁽¹⁾

Odontomas are typically tiny, solitary, or numerous radio-opaque lesions. Historically, odontomas were categorized as benign tumours and further classified as complex or compound based on their morphology. They frequently interfere with the eruption of teeth.⁽²⁾

“At the beginning of their discovery, odontomas were considered true tumors. But very quickly, this appellation disappeared to be replaced by the notion of hamartomas malformations as they develop from odontogenic epithelium and ectomesenchyme components, with the capacity of forming enamel, dentin, and cementum”.⁽³⁾

“An early detection of odontoma is more likely an accidental radiological finding, hence the need for routine radiographic analysis should be emphasized. Early diagnosis of odontomas in primary dentition is crucial in order to prevent later complications, such as impaction or failure of eruption of teeth”.⁽⁴⁾

CASE REPORT –

This case report presents a 12-year-old female patient with over retained 62,63 with unerupted succedaneous tooth, along with radiographic accidental finding of a tooth like structure which after surgical excision diagnosed as a compound odontoma.

CASE DESCRIPTION –

A 12-year-old girl reported to the department of Oral Medicine and Radiology with a chief complaint of milk tooth that has not fallen in upper left front region of jaw. Her medical history was non-contributory. There was no history of trauma to her orofacial region. There was no family history of unerupted teeth or hypodontia.

Intraoral examination revealed total 28 teeth, with over retained 62,63. On Inspection a solitary dome shaped intraoral bulge felt on left maxillary arch involving attached gingiva and alveolar mucosa extending mediolaterally from mesial aspect of 62 to distal aspect of 24 and superoinferiorly from alveolar mucosa to attached gingiva of approximately 1.5 x 2cm in size with a color like rest of gingiva. On palpation It was non tender, firm in consistency, with smooth surface, non-compressible, non-fluctuant, non-reducible, non-pulsatile [Figure 1].

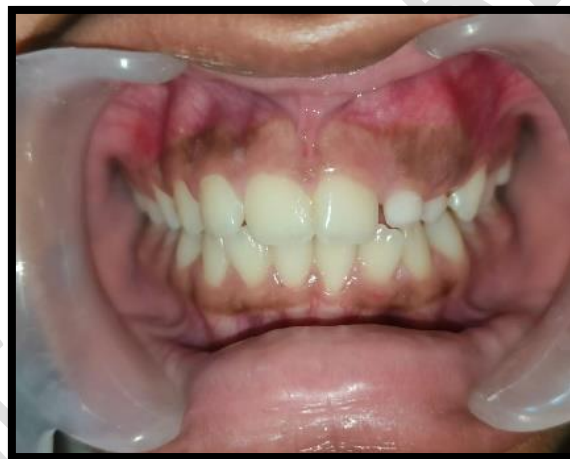

Figure 1. Over Retained left maxillary lateral incisor and canine with solitary bulge seen on attached gingiva w.r.t. 62 and 63

CBCT reports revealed [Figure 2(a-d)] Overretained 62,63. Presence of multiple small radiopaque structures resembling teeth in maxillary anterior region at apical level of overretained 62,63 surrounded by thin radiolucent line of size (1.2x1x1.7 cm) suggestive of benign odontogenic tumor D/D compound odontoma. A Vertically impacted 22. Its Crown is placed at apical level of 21 on palatal aspect and a single slender root of 10 mm placed obliquely is in close approximation of floor of nasal fossa (4-c). A Vertically impacted 23, its crown is placed above the benign odontogenic tumor

and a single slender root of 13 mm is in close approximation of medial wall of maxillary sinus (4-a)

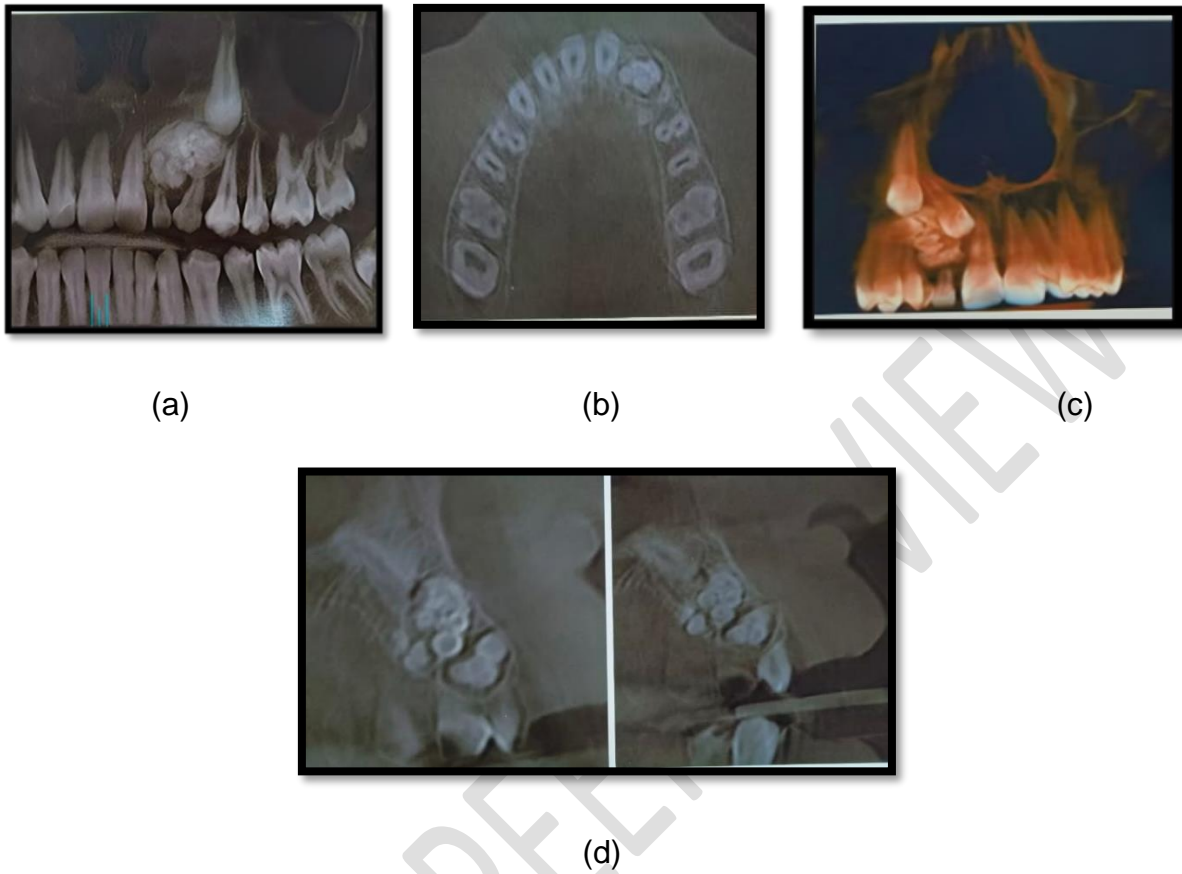


Figure 2 (a-d) . CBCT report showing Multiple small radiopaque structures resembling teeth

Surgery was performed to remove the lesion. A total of 15 small teeth like structures [Figure 3] which were in different developing stages were removed after reflection of full thickness mucoperiosteal triangular and closure done with 3-0 vicryl sutures after extraction of 62 and 63 [Figure 4] .

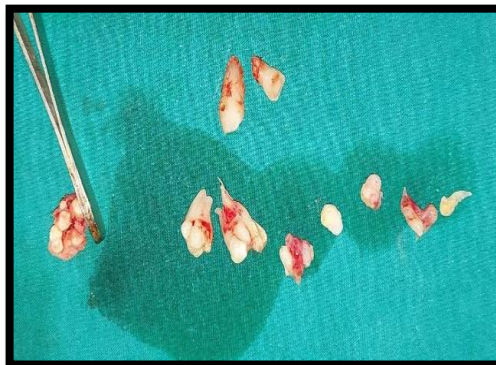


Figure 3. Multiple teeth like structures after surgical excision.

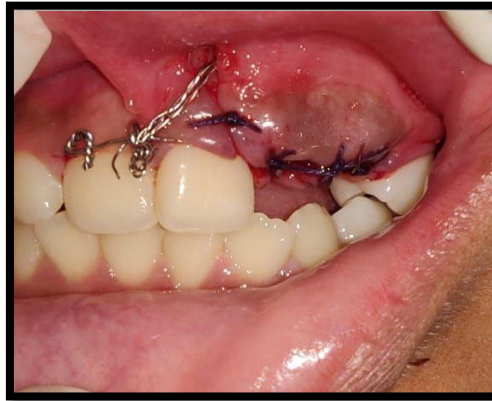

Figure 4. Closure done with 3-0 vicryl sutures after extraction of 62 and 63

Orthodontic management was done after surgical removal of lesion.[Figure 5 and 6]

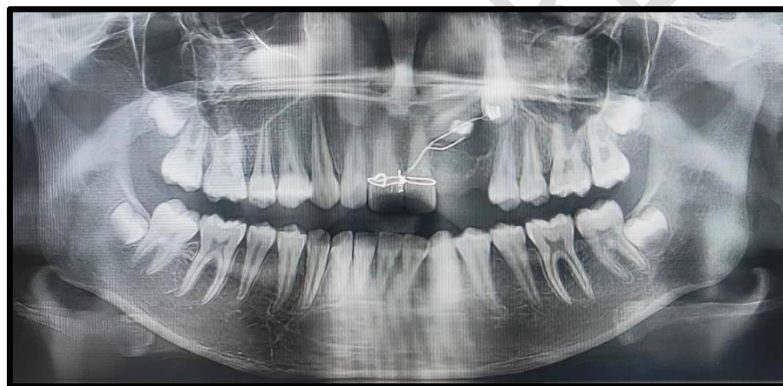

Figure 5

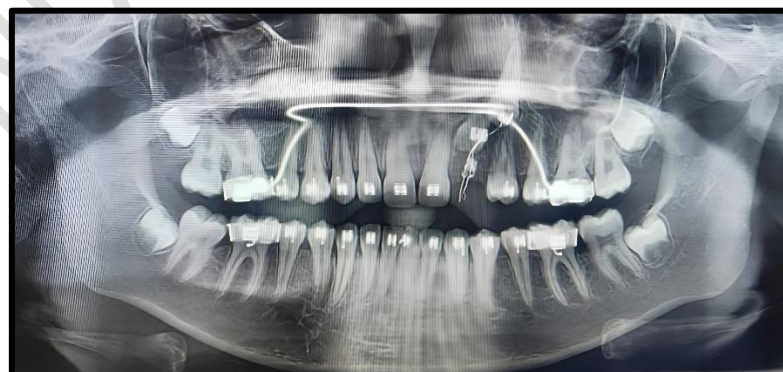

Figure 6

DISCUSSION –

“Hamartomas are tumorlike malformations characterized by the presence of a cellular proliferation that is native to the part but that manifests growth cessation without potential for further growth. Hemangioma (both solitary and when found in association with other developmental anomalies in the various angiomatosis syndromes), lymphangioma, glomus tumor, nevi, granular cell tumor of the tongue and granular cell epulis, neuromas of the type III multiple endocrine neoplasia (MEN III) syndrome, fibrous dysplasia of bone, cherubism, various odontomas, some odontogenic tumors, and (possibly) the melanotic neuroectodermal tumor of infancy are all examples of hamartomatous development in the oral region. To a greater or lesser extent, these lesions all possess the characteristics of hamartomas”.⁽⁵⁾

“The odontoma is a benign tumor hamartomatous growth containing all the various component tissues of teeth”⁽⁶⁾.

“Odontomas are the most prevalent odontogenic tumors of the jaws in an interval of 35%–76%, characterized by their non-aggressive character. Their discovery is usually accidental during routine radiological examinations given their asymptomatic evolution in most cases”.⁽⁷⁾

“Odontomas are relatively common, asymptomatic odontogenic hamartomatous malformations. The most common clinical presentation for an odontoma is the association with impacted or retained primary teeth”⁽⁸⁾.

“Broadly, odontomes are classified into compound and complex types, with compound odontomes further classified into denticular, particulate and denticuloparticulate types”.⁽⁹⁾

According to the World Health Organization (WHO) classification, odontomes can be divided into three groups:

- 1) Complex odontome: when the calcified dental tissues are simply arranged in an irregular mass bearing no morphologic similarity to rudimentary teeth.
- 2) Compound odontome: composed of all odontogenic tissues in an orderly pattern, which result in many teeth-like structures, but without morphological resemblance to normal teeth.

- 3) “Ameloblastic fibro-odontome: consists of varying amounts of calcified dental tissue and dental papilla-like tissue, the later component resembling an ameloblastic fibroma. The ameloblastic fibro-odontome is considered as an immature precursor of complex odontoma”.⁽¹⁰⁾

“The odontoma seems to result from a budding of extra odontogenic epithelial cells from the dental lamina. This cluster of cells forms a large mass of tooth tissue that may be deposited in an abnormal arrangement but consists of normal enamel, dentin, cementum, and pulp”.⁽¹¹⁾

“Compound odontomas contain calcified structures that grossly and radiographically resemble poorly formed and often small teeth in which enamel, dentin, and cementum can be distinguished”.⁽⁵⁾

“The mean age of detection on an average is 14.8 years, with the prevalent age being the second decade of life. There is a slight predilection for the occurrence in males (59%) as compared with females (41%). The compound odontome is known to occur more commonly in the maxilla (67%) than the mandible (33%), with a marked predilection for the anterior maxillary region (61%)” [8].

On the radiographical examination, The borders of odontomas are well defined, with a smooth but irregular periphery. These lesions have a cortical border. The contents of these lesions are heterogeneously radiopaque. Compound odontomas have a number of variably sized toothlike structures or denticles that have the appearance of deformed teeth. In some cases, enamel, dentin, and pulp spaces can be visualized, thereby contributing to the heterogeneous appearance.⁽⁷⁾ “The radiographic findings of odontomas depend on their stage of development and degree of mineralization. The first stage is characterized by radiolucency due to the lack of calcification. Partial calcification is observed in the intermediate stage, while in the third stage, the lesion usually appears as radiopaque masses surrounded by radiolucent areas corresponding to the connective tissue histologically”.⁽¹³⁾

“Rarely, an odontoma may erupt into the oral cavity. Odontomas are generally small; however, they may occasionally grow large, resulting in bone expansion. Usually, odontomas can be confidently subclassified based on the radiographic appearance alone. Although they are commonly asymptomatic, clinical indicators of odontoma may

include retention of deciduous teeth, noneruption of permanent teeth, pain, expansion of the cortical bone and tooth displacement”⁽¹⁴⁾

Odontomas are removed by simple excision. They do not recur and are not locally invasive.

CONCLUSION –

Odontomas cannot be diagnosed using visual or physical procedures. It must be done in conjunction with radiographic and histological examinations. All paediatric patients with delayed eruption, missing teeth, or temporary tooth displacement, independent of trauma history, should have a thorough visual, manual, and radiographic examination. Early identification of odontomas results in more manageable and cost-effective treatment options, as well as a better prognosis.

CONSENT –

Written consent was obtained from the mother for the agreed dental treatment and the use of her records or photographs for publication purpose.

ETHICAL APPROVAL –

As per international standards or university standards written ethical approval has been collected and preserved by the author(s).

Disclaimer (Artificial intelligence)

Option 1: NO

Author(s) hereby declare that NO generative AI technologies such as Large Language Models (ChatGPT, COPILOT, etc) and text-to-image generators have been used during writing or editing of manuscripts.

Option 2:

Author(s) hereby declare that generative AI technologies such as Large Language Models, etc have been used during writing or editing of manuscripts. This explanation will include the name, version, model, and source of the generative AI technology and as well as all input prompts provided to the generative AI technology

Details of the AI usage are given below:

- 1.
- 2.
- 3.

REFERENCES –

- 1) Patil, Shankargouda & Rao, RoopaS & Majumdar, Barnali. (2015). Hamartomas of the oral cavity. *Journal of International Society of Preventive and Community Dentistry*. 5. 10.4103/2231-0762.164789.
- 2) Nguyen DK, Van Huynh D. Clinical and radiological characteristics of odontomas: A retrospective study of 90 cases. *Imaging Sci Dent*. 2023 Jun;53(2):117-126. doi: 10.5624/isd.20220184. Epub 2023 Mar 24. PMID: 37405206; PMCID: PMC10315233.
- 3) Hidalgo-Sánchez O, Leco-Berrocal MI, Martínez-González JM. Metaanalysis of the epidemiology and clinical manifestations of odontomas. *Med Oral Patol Oral Cir Bucal*. 2008; 13(11): E730-E734.
- 4) Isola, Gaetano DDS, PhD*; Cicciù, Marco DDS, PhD†; Fiorillo, Luca DDS*; Matarese, Giovanni DDS, MD*. Association Between Odontoma and Impacted Teeth. *Journal of Craniofacial Surgery* 28(3):p 755-758, May 2017. | DOI: 10.1097/SCS.00000000000003433
- 5) Lester_William_Burket,_Martin_S._Greenberg,_Micha 10th ed . Benign tumours of oral cavity. P. 137-193.
- 6) Wood NK, Goaz PW, Lehnert J. Mixed radiolucent-radiopaque lesions associated with teeth. In: Wood NK, Goaz PW, editors. *Differential diagnosis of oral and maxillofacial lesions*. Singapore: Harcourt Brace & Company Asia Pvt Ltd; 1998. p. 415-432
- 7) Khalifa C, Omami M, Garma M, Slim A, Sioud S, Selmi J. Compound-complex odontoma: A rare case report. *Clin Case Rep*. 2022 Apr 4;10(4):e05658. doi: 10.1002/ccr3.5658. PMID: 35387291; PMCID: PMC8978784.
- 8) Rana V, Srivastava N, Kaushik N, Sharma V, Panthri P, Niranjana MM. Compound Odontome: A Case Report. *Int J Clin Pediatr Dent*. 2019 Jan-Feb;12(1):64-67. doi: 10.5005/jp-journals-10005-1575. PMID: 31496576; PMCID: PMC6710944.
- 9) Marappa Sathyamoorthy SK, Chakrika H, Dhinakaran M CBCT-guided management of compound odontoma *BMJ Case Reports CP* 2021;14:e244457.

- 10) Tomizawa M, Otsuka Y, et al. Clinical observations of odontomas in Japanese children: 39 cases including one recurrent case. *Int J Paediatr Dent* 2005;15:37–43. DOI: 10.1111/j.1365-263X.2005.00607.x
- 11) Wood NK, Goaz PW, Lehnert J. Mixed radiolucent-radiopaque lesions associated with teeth. In: Wood NK, Goaz PW, editors. *Differential diagnosis of oral and maxillofacial lesions*. Singapore: Harcourt Brace & Company Asia Pvt Ltd; 1998. p. 415-432
- 12) Shafer WG, Hine MK, et al. Cysts and tumours of the jaws. *A Textbook of Oral Pathology*, 4th edn. Philadelphia, PA, USA: WB Saunders, 1997; pp. 308–311.
- 13) Areal-Lopez L, Silvestre DF, et al. Compound odontoma erupting in the mouth: Four years follow-up of a clinical case. *J Oral Path* 1992;21:285–288. DOI: 10.1111/j.1600-0714.1992.tb01012.x
- 14) Gedik R, Müftüoğlu S. Compound Odontoma: Differential Diagnosis and Review of the Literature. *West Indian Med J*. 2014 Dec;63(7):793-5. doi: 10.7727/wimj.2013.272. Epub 2014 Aug 26. PMID: 25867569; PMCID: PMC4668987.