

# Cervical bronchogenic cyst causing inspiratory stridor

---

## Abstract

### Introduction

Bronchogenic cyst is a rare congenital pulmonary malformation, which is a consequence of abnormal budding of the foregut. 85% of bronchogenic cysts are found in the mediastinum. However, unusual locations such as neck, pericardium or abdomen have been reported. We present a case of a bronchogenic cyst at the cervical region extending to the superior mediastinum.

### Case report

A 2-month old baby girl presented to the hospital at day 13 of life with profound noisy breathing. There was an inspiratory stridor and mild subcostal and intercostal recession on examination. Chest Xray revealed hyper-inflated lungs. Nasopharyngolaryngoscopy revealed redundant arytenoid tissue which prolapsed into the airway during inspiration and provisional diagnosis was laryngomalacia. A Computed tomography of thorax revealed a homogenous hypodense mass located on the left of trachea at the superior mediastinum compressing the trachea and displacing it to the right. Cystic mass was excised and histopathological examination interpreted as bronchogenic cyst.

### Discussion

Children with bronchogenic cyst can present with breathlessness, cough, wheeze or stridor while 20% of them are asymptomatic. Computed tomography provides information regarding the location of the mass and degree of upper airway narrowing. Complete surgical excision is the standard management even in asymptomatic patients in order to prevent complications and avoid malignant transformation.

### Conclusion

Patients who do not respond to conventional treatment for wheezing or stridor, require further investigations to confirm the diagnosis. Multidisciplinary discussion should be carried out to decide the best timing and approach of surgery in order to achieve the best outcome.

*Keywords: bronchogenic cyst, wheezing, stridor, laryngomalacia*

## INTRODUCTION

Bronchogenic cyst is a rare congenital pulmonary malformation with the prevalence of 1 in 42,000 to 1 in 68,000. Bronchogenic cyst is a consequence of abnormal budding of the foregut. Its location varies depending on the embryological stage of development affected. Maier classified the cyst as paratracheal, carinal, para-esophageal, hilar, and miscellaneous. 85% of bronchogenic cysts are reported to be found in the mediastinum. However, unusual locations such as neck, pericardium or abdomen have been reported. We present a rare case of a bronchogenic cyst at the cervical region extending to the superior mediastinum.

## CASE REPORT

We report a 2-month old baby girl, presented to the hospital at day 13 of life with profound noisy breathing since day 7 of life. On physical examination, there was an inspiratory stridor and mild subcostal and intercostal recession. There was no mass palpable over the neck and other system examination was unremarkable. Chest Xray (CXR) revealed hyper-inflated lungs. She was co-managed initially by the paediatrics and ENT team. After a bedside flexible nasopharyngolaryngoscopy (FNLPS) was performed revealing redundant arytenoid tissue which prolapsed into the airway during inspiration, a provisional diagnosis of laryngomalacia was made. However, child deteriorated further requiring an Examination under anaesthesia, bronchoscopy and supraglottoplasty. Intraoperatively, it was noted that the aryepiglottic fold were tight bilaterally with pooling of secretion at supraglottic region. A supraglottoplasty was performed by releasing tort aryepiglottic fold bilaterally. In view of multiple episodes of desaturations after surgery, a repeated bronchoscopy was performed, which revealed tracheobronchomalacia with left main bronchus collapsed suspecting external compression. A HRCT of thorax were performed revealing a homogenous hypodense non-enhancing mass measuring 2.3cmx2.9cmx3.1cm located on the left of the trachea at the superior mediastinum, causing compression to the trachea and displacement of the trachea to the right. Differential diagnosis at this point of time was bronchogenic cyst, esophageal duplication cyst and lymphatic malformation. (Fig 2).

Child was subsequently referred to our Paediatric Surgical Team. Upon our examination, there was no neck mass palpable. After reviewing the images and a multidisciplinary team discussion, we then proceeded with an excision of the superior mediastinal mass. Patient was initially put in the right lateral decubitus position with neck hyperextended. Left transverse cervical incision made and left sternocleidomastoid muscle (SCM) was retracted posteriorly exposing the cystic mass. It was a thin-walled cystic mass which was located medial to left SCM, in between trachea and oesophagus, measuring 3cmx3cm. It was ruptured during mobilisation and thick mucoid fluid was drained out. The cystic mass was opened up to identify the posterior wall and subsequently excised completely. (Fig 3) There was no immediate post-operative complication. Child was successfully discharged three weeks post-operatively with home CPAP and Ryle tube feeding in view of the severe laryngotracheobronchomalacia and oesophageal dysmotility. This child was reviewed in our clinic two months after surgery. Her requirement for CPAP at home has been reduced with longer rest time. ENT team had performed another FNLPS for her and showed that bilateral false folds were normal with mobile and symmetrical vocal cords. Final histological analysis revealed fibrocollagenous cyst wall tissue lined with stratified columnar epithelium. The wall displayed presence of cartilage and seromucinous glands. Features were in keeping with bronchogenic cyst.

## DISCUSSION

Around 20% of children with bronchogenic cyst are asymptomatic, while others may have symptoms such as shortness of breath, cough, wheeze or stridor depending on the size and location of the cystic mass. Symptoms can be due to compression on surrounding structures, infection, haemorrhage, fistula formation, malignant transformation and superior vena caval syndrome. In our patient, the location of the cyst in between the trachea and oesophagus, brought on an early presentation of inspiratory stridor at day 7 of life which worsened over the time of admission. Any presentation of stridor in an infant not responding to treatment should be extensively worked up to rule out other causes such as external compression. In our patient, the CXR did reveal a slight deviation of the trachea which should have raised a suspicion of an external compression necessitating a CT scan. Other signs include well-defined homogenous density and compression effect-like atelectasis or emphysema. CT scan of neck and thorax provides useful information regarding the location of the mass and degree of upper airway narrowing. It can also delineate the relationship of the cystic mass with its surrounding structures. The cyst usually has a homogeneous appearance. However, it can have an attenuation of up to 120 Hounsfield units which is attributed to its protein and calcium content or to infectious complications. On MRI, the fluid inside the cyst can have low or high intensity on T1 images and bright intensity on T2 images. (1)

Cystic mass can be excised via sternotomy, thoracotomy, thoracoscopy, transbronchial or percutaneous aspiration, mediastinoscopy or cervical incision. It depends on the size and location of the mass. Cervical approach has been reported by Thaller which also required limited resection of trachea and oesophagus due to difficult dissection of bronchogenic cyst. (2) Complete surgical excision is the standard management for bronchogenic cyst even in asymptomatic patients in order to prevent complications and avoid malignant transformation of the cystic mass. The risk of malignant transformation in adult bronchogenic cyst was reported as less than 0.7%, however only a few well-documented cases in paediatric group (3,4) The definitive diagnosis can only be confirmed by histopathological examination following surgery. Histopathological findings of a typical bronchogenic cyst include ciliated columnar epithelium with underlying fibrous connective walls. Presence of cartilage is important for diagnosis of bronchogenic cyst. Smooth muscle and seromucous glands may also present. (5)

Bronchogenic cyst can also be associated with tracheobronchomalacia in which the affected bronchus lacking rigidity because of insufficient cartilages or extrinsic compression, which had happened in our patient. There is a reported case of bronchogenic cyst in neonate which experienced a complete resolution of tracheobronchomalacia after surgical excision. (6) There were also cases with residual tracheobronchomalacia present after surgery. Although this patient is showing improvement in recovery, we will continue to follow up her for a longer period of time to review her general condition.

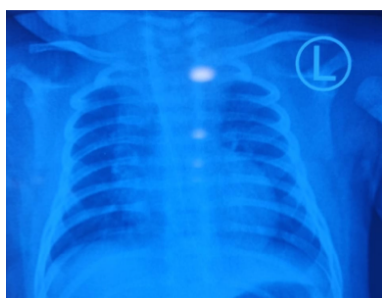

Figure 1. Chest Xray showed hyper- inflated lungs.

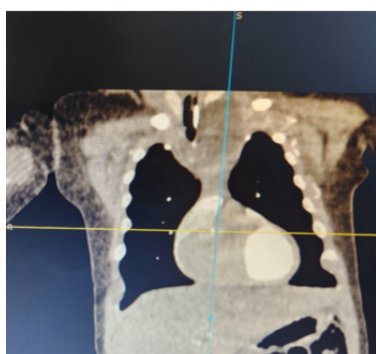


Figure 2 Coronal view of HRCT of thorax showed homogenous mass on the left of trachea causing compression of trachea and displacement of trachea to the right.

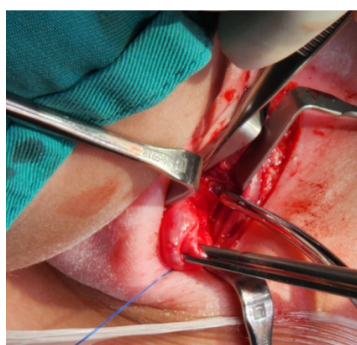


Figure 3. Cystic mass at the cervical region. Child in right lateral decubitus position with neck hyperextended.

## CONCLUSION

Patients who do not respond to conventional treatment for wheezing or stridor, require further investigations to confirm the diagnosis. Surgical excision is indicated for bronchogenic cyst even they are asymptomatic to prevent the complications and potential risk of malignant transformation. Multidisciplinary discussion should be carried out to decide the best timing and approach of surgery in order to achieve the best outcome.

## REFERENCE

1. Intramural Bronchogenic Cysts in the Pediatric Population, Sharif Almatrafi, Cureus. 2020 Feb; 12(2): e7111.
2. Neonatal respiratory distress syndrome revealing a cervical bronchogenic cyst: a case report , Penelope Thaller, BMC Pediatrics (2015) 15:72
3. Mediastinal Bronchogenic Cysts Resection in Adults: Results of Vats and Thoracotomy Procedures, El Hassan Kabiri, Portuguese Journal Of Cardiac Thoracic and Vascular Surgery, 2022 Oct 5;29(3):35-39.
4. Surgical Management and radiological Characteristics of Bronchogenic Cysts, Hon-Chi Suen, The Society of Thoracic Surgeons 1993
5. Pediatric bronchogenic cysts in the head and neck region: A study of 10 surgical cases and a review of the literature, Wei Chen, Front Pediatr. 2022;10:1030692.
6. Stridor secondary to a bronchogenic cyst in a neonate, Rowley S Busino, Ear Nose Throat J 2011 Nov;90(11):E8-10.