

Case report

Case report of a 12-year-old girl with Clear Cells Hidradenoma

Abstract:

Hidradenoma is an uncommon skin tumor, representing 1% of all skin tumors, that originates from the duct of sweat gland and remains exceptional in children. Our case report describes the case of a 12-year-old girl patient with a mass on the anterior aspect of the right forearm for two years. The ultrasound examination did not reveal any abnormalities. Histopathological examination was performed and revealed monomorphic, clear, and rich in glycogen cell clusters with glandular cavities and anastomosing digitations, suggesting hidradenoma. Surgical excision had been done with a safety margin of 1 cm with a good evolution over a 12-month period. The authors propose a literature review based on this clinical observation.

Key words: hidradenoma, child, girl. skin tumor, cell hidradenoma

Introduction:

Hidradenoma is an uncommon skin tumor, representing 1% of all skin tumors [1-2]. Clear cell hidradenoma is a rare adnexal tumor, exceptional in children, of eccrine origin, located mainly on the trunk. Its prognosis is conditioned by the risk of frequent local and distant recurrences. We report a new observation of a hidradenoma with an exceptional location on the forearm.

Case Presentation:

A 12-year-old girl presented 2 years ago with a mass of the anterior aspect of the middle third of the right forearm. The evolution was marked 3 months before his admission by ulceration with abundant bleeding on contact and a rapid increase in size.

Examination revealed an ulcerated mass on the anterior aspect of the middle third of the right forearm, bleeding on contact, measuring 4*3 cm (figure 1), with no other concomitant lesions, particularly no axillary adenopathy. Biopsy was in favour of a clear cell hidradenoma.

Surgical resection was performed with a safety margin of 1 cm, removing the dermis, hypodermis, and superficial fascia (Figures 2-3).

The immunohistochemical study confirmed a benign clear cell hidradenoma (Figure 4).

After 6 years of follow-up, the evolution was good with no local or distant recurrence.

Discussion:

Mayer was the first to describe the hidradenoma as a distinct clinical entity [3]. It is a benign adnexal neoplasm of uncertain origin. The eccrine origin is the most likely. However, some studies point to an apocrine derivation. Recently, hidradenoma has been classified into two groups; those with eccrine differentiation (poroid hidradenoma) and those with apocrine differentiation (clear cell hidradenoma) [3]. Clear cell hidradenomas are by far the most common subtype and represent 95% of all cases [4-5] and 1% of primary skin tumors. The gender ratio of men to women is 1 to 2 [1-2].

The fact that oestrogen receptors are sometimes found in benign nodular hidradenomas and the female predominance suggest a possible role for these hormones in the development of these tumors [4]. The average age is between 30 and 40 years, and children are exceptionally affected. No risk factors have been identified [4].

The hidradenoma usually presents as a solitary, asymptomatic, well-circumscribed, slowly growing mass composed of lobulated, cystic, or pedunculated lesions that reside in the upper or middle dermis but sometimes extend deeply into the subcutaneous tissue. They range in size from 0.5 to 3 cm and are often found on the head, face, and upper limbs [6-7-8]. The colour of the skin above is variable.

The lesion may ulcerate, producing a clear or hemorrhagic fluid [2], as in our case, where negligence led to a 4 cm mass which subsequently ulcerated. In two of the larger series [3-9], the hidradenoma was located in the trunk in more than half of the cases, and in the cervico-facial region in 25%. [9]

Indeed, clear cell hidradenomas rarely occur in the limbs. The most common tumors found in the limbs are fibromatosis, giant cell tumors of the tendon sheaths, and lipomas [3].

The histopathological diagnosis is difficult, due to the varied clinical signs and the variable prevalence of the different components: solid, cystic, tubular lumen, clear cells, and spindle cells, explaining the many histological varieties. The clear cell form remains the most common. There are several variants of clear cell hidradenoma, including the benign form, the locally aggressive tumor with tissue invasion, and the malignant tumor with metastatic potential, which is mainly lymphophilic and remains rare [4].

The distinction between benign and malignant hidradenoma is quite difficult, hence the interest in immunohistochemistry. MKi67 is used to define the aggressivity of the tumor by percentage. The epithelial nature and adnexal differentiation are confirmed by other markers (keratin / EMA / CEA / S100 protein / Vimentin) [5].

Because of the high recurrence rate, surgical resection should be complete with wide safety margins, as malignant transformation may be present in other areas of the lesion [9]. In addition, hidradenoma has a recurrence rate of approximately 12% if not completely excised [10], especially in lesions with irregular peripheral margins [11].

Clinical surveillance should be regular, justified by the hypothesis of a possible benign extension to the lymph nodes.

Although most cases of hidradenocarcinoma occur de novo, it can also appear in pre-existing hidradenoma, and this potential for transformation requires clear surgical margins [12-13-14] for which there is no clear consensus.

Conclusion:

Hidradenoma is an uncommon adnexal tumor, without being extremely frequent. Immunohistochemistry remains the only examination that can differentiate benign from malignant forms due to the clinical and pathological difficulties. Surgical resection is the rule because of the risk of malignant transformation.

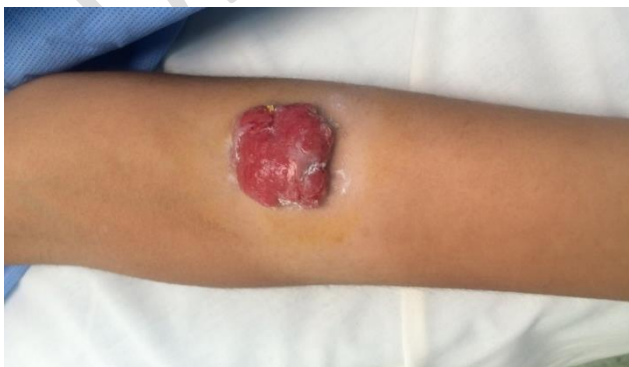

Figure 1: clinical appearance of the tumor

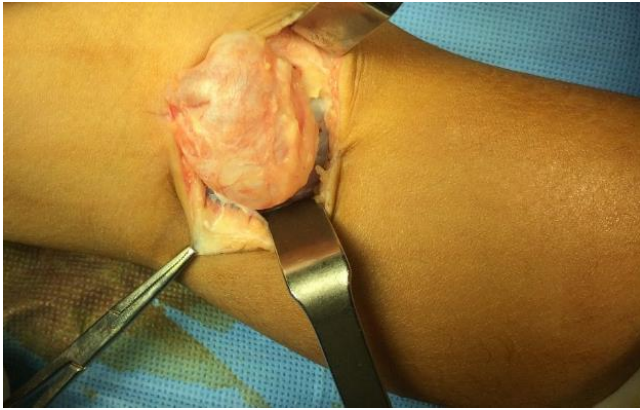

Figure 2: intraoperative appearance

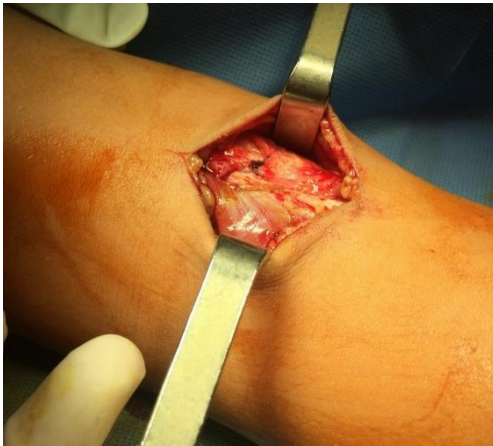


Figure 3: appearance after resection of the tumor removing dermis, hypodermis and superficial aponeurosis

Ethical Approval:

As per international standards or university standards written ethical approval has been collected and preserved by the author(s).

Consent

As per international standards or university standards, patient(s) written consent has been collected and preserved by the author(s).

Disclaimer (Artificial intelligence)

Option 1:

Author(s) hereby declare that NO generative AI technologies such as Large Language Models (ChatGPT, COPILOT, etc) and text-to-image generators have been used during writing or editing of manuscripts.

Option 2:

Author(s) hereby declare that generative AI technologies such as Large Language Models, etc have been used during writing or editing of manuscripts. This explanation will include the name, version, model, and source of the generative AI technology and as well as all input prompts provided to the generative AI technology

Details of the AI usage are given below:

- 1.
- 2.
- 3.

Références :

- 1- Schweitzer WJ, Goldin HM, Bronson DM, Brody PE. Ulcerated tumor on the scalp. Clear-cell hidradenoma. Arch Dermatol 1989 ;125 :985-6.
- 2- Reza Yaghoobi Clear cell hidradenoma in a young boy lear cell hidradenoma in a young boy Indian J Dermatol Venereol Leprol|September-October 2007| Vol 73|Issue 5
- 3- Gianotti R, Alessi E. Clear cell hidradenoma associated with the Folliculo - Sebaceous - Apocrine unit : Histologic study of five cases. Am J Dermatopathol 1997 ;19 :351-7.
- 4- Faulhaber D, Worle B, Trautner B, Sander CA. Clear cell hidradenoma in a young girl. Am Acad Dermatol 2000 ;42 :693- 5.
- 5- Ozawa T, Fujiwara M, Nose K, Muraoka M. Clear cell hidradenoma of the Forearm in a young boy. Pedia Dermatol 2005 ;22 :450-2.
- 6- Nandeesh B.N., Rajalakshmi T. : A study of histopathologic spectrum of nodular hidradenoma. Am J Dermatopathol 2012 ; 34 : pp. 461-470.
- 7- Isabel Park a, *, Esther Lee a, Stephanie Barak b, Punam G. Thakkar a
A rare case of Hidradenoma of the lower lip American Journal of Otolaryngology–Head and Neck Medicine and Surgery 42 (2021) 103108
- 8- Ultrasonographic and pathologic findings of recurred clear cell hydradenoma Dong-ho Ha Dong-A University Medical Center, Seo-gu, Busan, South Korea
- 9- Schweitzer WJ, Goldin HM, Bronson DM, Brody PE. Ulcerated tumor on the scalp. Clear-cell hidradenoma. Arch Dermatol 1989 ;125 :985-6.
- 10- Patterson J W, Wick M R. Neoplasms and pseudoneoplastic proliferations of the sweat glands. In : Silverberg SG, Sobin LH, eds. AFIP Atlas of tumor pathology. Non-melanocytic tumors of the skin. Washington, DC : Armed Forces Institute of Pathology, 2006137–199.

- 11- Crowson A N, Magro C M, Mihm M C. Malignant adnexal neoplasms. *Mod Pathol* 2006;19(Suppl 2) S93–126.
- 12- Obaidat NA, Alsaad KO, Ghazarian D. Skin adnexal neoplasms—part 2 : an approach to tumours of cutaneous sweat glands. *J Clin Pathol* 2007 ;60(2) :145–59. <https://doi.org/10.1136/jcp.2006.041608>
- 13- A Toulemonde A., Croue A., Rodien P., Verret J.L. : Hidradénome nodulaire malin et hidradénomes nodulaires multiples chez un malade hypogonadique. *Ann Dermatol Venerol* 2006 ; 133 : pp. 1005-1008.
- 14- N. Gouiaa, K. Abbas, I. Fakhfekh, L. Ayadi, I. Bahri, C. Chaari, S. Ellouze, I. Chtourou, S. Makni et T. Sellami-Boudawara. Hidradénocarcinome développé sur un hidradénome préexistant. *Annales de Dermatologie et de Vénérologie*, 2008-10-01, Volume 135, Numéro 10, Pages 714-715
- 15 Dele, E. Imasogie, and T. Azeke Akhator. 2018. “Case Series of Cutaneous Adnexal Tumours; A Voice to the Existing Literatures, a Tertiary Hospital Experience in South-South Nigeria”. *Journal of Advances in Medicine and Medical Research* 26 (6):1-8. <https://doi.org/10.9734/JAMMR/2018/40650>.
- 16 Ohi, Y., Umekita, Y., Rai, Y., Kukita, T., Sagara, Y., Sagara, Y., ... & Yoshida, H. (2007). Clear cell hidradenoma of the breast: a case report with review of the literature. *Breast Cancer*, 14, 307-311.
- 17 Ohnishi, T., & Watanabe, S. (1997). Histogenesis of clear cell hidradenoma: immunohistochemical study of keratin expression. *Journal of cutaneous pathology*, 24(1), 30-36.