

Case report
Chronic Myeloid Leukemia with pleural effusion: A Rare Case Report of 45-year-old Women

Abstract:

Chronic myeloid leukemia has the highest prevalence rate among all the oncological cases around the globe. It possesses a very significant risk to the public in various forms. About 1 person in 526 will get CML in their lifetime. Nowadays, it's very challenging for the patients to understand the proper symptoms of these diseases. However, chronic myeloid leukemia with pleural effusion is very rare and poorly understood. In this case report, we present 45-year-old women with the diagnosis of chronic myeloid leukemia with bilateral pleural effusion.

Key words: Myeloid leukemia, Case report, oncology

Introduction:

One of the rarest kinds of bone marrow carcinoma is chronic myeloid leukemia. This particular form of blood cancer starts in the myeloid cells, or stem cells, found in the bone marrow. Excess myeloblasts in the bone marrow and blood are indicative of this slow-growing malignancy. Chronic myeloid leukemia is also called chronic myelogenous leukemia and chronic granulocytic leukemia. It mainly affects the old adults, and it very rarely occurs in the children, despite the fact that it can occur at any age.^{1,2-3} Many people with chronic myeloid leukemia can have a normal life span due to the advancement in the medications. This chronic myeloid leukemia is relatively common amongst the people around. The annual incidence rate of chronic myeloid leukemia in India is reported to be 0.8 to 0.22 per 100,000 population. The epidemiology varied across age groups, with an increased incidence of older individuals.⁴ A very long time is required for chronic myeloid leukemia to get worse. Many people learn that they have CML after routine blood test results. The symptoms affecting chronic myeloid leukemia are fatigue or weakness, shortness of breath (dyspnea), fever, night sweats, unexplained weight loss, abdominal swelling or discomfort, and always feeling full stomach. One of the worst outcomes could be

CML with pleural effusion, which is still less understood among the medical fraternity. But the report suggests that dasatinib may have an effective result on CML, but its use can also be associated with pleural effusion, which can range from mild to moderate.⁵

Case report:

A 45-year-old female was admitted in the Max Healthcare hospital in the oncology department on February 1st, 2023, with a chief complaint of hair fall, skin infection, dry cough, epigastric pain, and vomiting. where she is diagnosed as chronic myeloid leukemia with bilateral pleural effusion.

Clinical findings:

On examination, the patient was found conscious with skin rashes in the entire body. The vital sign recorded was Weight: 47 kg, Height: 147 cm. BMI: 21.75 BP: 100/70 Temperature: 98°F Pulse: 86/min Respiration: 22/min SpO₂: 99%. Furthermore, the patient also had a complaint of repeated diarrhea.

Diagnostic assessment:

All the relevant emergency investigations were done on the arrival of the patient. The blood test report showed CBC 10.9/12.8/162. creatinine 0.63, uric acid level 4.4 OT/PT-42/34, TB/DB-0.5/0.16, TSH 1.2, chest x-ray revealed bilateral pleural effusion. The HB level of the patient was 8.2, packed cell volume is 27.6, and the RBC count as seen was 2.8. Above all, after further investigation, it was also seen that the patient was going through bilateral grade-I medical renal disease. Minimal ascites, right-sided minimal pleural effusion, and cholelithiasis were also observed. After the HRCT thorax investigation was done, it was observed that the right lower lobe shows segmental collapse, bilateral diffuse perihilar ground glass opacities with smooth interlobular septal thickening, and bilateral moderate pleural effusion with extension along the oblique fissure. Calcified right hilar, lower right paratracheal lymph nodes noted.

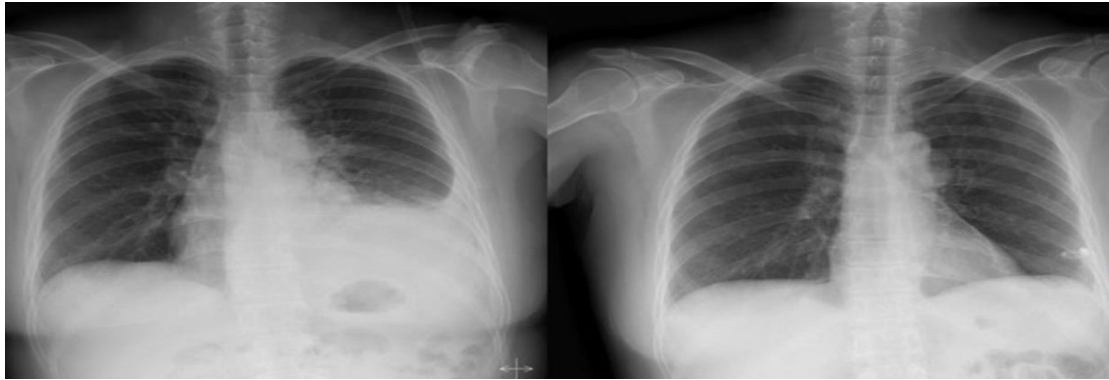


Fig 1: Chest PA showing the amount of Bilateral pleural effusion with pigtail catheter insertion site

Therapeutic intervention:

The patient was prescribed Tab Dasatinib (Invista) 50 mg OD X 3 months, Tab Shelcal 500 mg OD X 3 months, Cap D-Rise 60k once a month, Tab Rosuvas 10 mg OD (HS) X 3 months, and Tab Vertin 8 mg SOS for vertigo. Furthermore, the patient was also undergoing pigtail drainage (Dasatinib-induced?).

Discussion:

Chronic myeloid leukemia is a very slow-progressing blood and bone marrow disease that mainly takes place during middle age and is very rare in children. In these too many blood stem cells transform into a type of WBC, which is known as the granulocytes. These abnormal granulocytes do not have the capability to form healthy white blood cells. These white blood cells can also be termed leukemic cells. The Philadelphia chromosome, which means change in gene mutation, is very common among the chronic myeloid leukemia patients. This mainly results in bone marrow making a protein called tyrosine kinase that causes too many stem cells to become wbc (granulocytes or blasts).⁴ The physical examination, history collection, complete blood count with differential, blood chemical testing, bone marrow aspiration, and biopsy are the diagnostic procedures performed to analyze the blood and bone marrow. Some other tests are there that can be done on the samples of the blood or bone marrow tissues that are removed. They are called the cytogenic analysis, FISH (Fluorescence in situ hybridization), and reverse transcription polymerase chain reaction test (RT-PCR). The factors that can affect the prognosis (chance of recovery) are the patient's age, the phase of CML, and the number of blasts in the blood or bone marrow. There are some different phases of chronic myeloid leukemia; they are most probably the chronic phase, the accelerated phase, and the blastic phase. Chronic phase is something where less than 10 percent of the cells in the blood and bone

marrow are the blast cells. Standard treatment mainly works in these. Next comes the accelerated phase, during which 10–19% of the bone marrow and blood cells are blast cells. Visibility of the symptoms starts at this stage.⁶ and last phase is the blastic phase, in which at least 20% of the cells in bone marrow or blood are blast cells. During these stages, the blast cells begin to spread to the body's other organs. The primary treatment for chronic myeloid leukemia is targeted therapy, which involves the use of medications⁷ or other substances that target particular cancer cells while causing the least amount of damage to healthy cells. Tyrosine kinase inhibitors are the medications that are typically used to treat this condition (TKIs). Next is immunotherapy, high-dose chemotherapy combined with a stem cell transplant, donor lymphocyte infusion (DLI), and chemotherapy, which is a very successful treatment for chronic myeloid leukemia. DLI is a post-stem cell transplantation therapy choice. In these, healthy lymphocytes from the donor of the stem cell transplant are infused into your bloodstream. The remaining cancer cells are killed by these donor lymphocytes. Splenectomy is also could be beneficial in some cases where surgically the spleen will be removed. The treatment protocol depends on which phase the patient is in.^{1,4-6} pleural effusion is common in some types of cancer, but CML with pleural effusion is considered a very poor outcome indicator, and there is no proper treatment protocol to counter the problem. However, the symptoms can be managed by thoracentesis and chemotherapy for underlying CML and pleurodesis.⁸

Conclusion:

In conclusion, CML with pleural effusion is a very rare condition that might affect the patient's physical and mental wellbeing drastically. Further research is important to unfold the mystery about the presented condition. Awareness among the cytopathologist, oncologist, and oncosurgeon about the condition is very important to diagnose the disease correctly along with the pleural fluid interpretation to avoid false reports. In addition to this, a multidisciplinary healthcare approach should be taken along with medical treatment for optimal care.

Consent: As per international or university standards, the patient's written consent has been collected and preserved by the author(s).

Ethical approval: Ethical approval was obtained from the institutional ethical committee and the hospital ethical committee.

Reference:

1. Chronic myelogenous leukemia - Symptoms and causes - Mayo Clinic [Internet]. Mayo Clinic. 2023. Available from: <https://www.mayoclinic.org/diseases-conditions/chronic-myelogenous-leukemia/symptoms-causes/syc-20352417>
2. Professional CCM. Chronic Myeloid Leukemia (CML) [Internet]. Cleveland Clinic. Available from: <https://my.clevelandclinic.org/health/diseases/21845-chronic-myelogenous-leukemia-cml>
3. NCI Dictionary of Cancer Terms [Internet]. Cancer.gov. Available from: <https://www.cancer.gov/publications/dictionaries/cancer-terms/def/chronic-myeloid-leukemia>
4. Chronic Myelogenous Leukemia Treatment [Internet]. Cancer.gov. 2023. Available from: <https://www.cancer.gov/types/leukemia/patient/cml-treatment-pdq>
5. Cortes JE, Jimenez CA, Mauro MJ, Geyer A, Pinilla-Ibarz J, Smith BD. Pleural Effusion in Dasatinib-Treated Patients With Chronic Myeloid Leukemia in Chronic Phase: Identification and Management. *Clinical Lymphoma Myeloma & Leukemia* [Internet]. 2017 Feb 1;17(2):78–82. Available from: <https://doi.org/10.1016/j.clml.2016.09.012>
6. Sawyers CL. Chronic myeloid leukemia. *N Engl J Med*. 1999 Apr 29;340(17):1330-40. doi: 10.1056/NEJM199904293401706. PMID: 10219069.
7. Elias Jabbour, Hagop Kantarjian. Chronic myeloid leukemia: 2018 update on diagnosis, therapy and monitoring, *American journal of haematology therapy and monitoring*. 2018;93(3):442-459.
8. Nuwal P, Dixit R, Dargar P, George J. Pleural effusion as the initial manifestation of chronic myeloid leukemia: Report of a case with clinical and cytologic correlation. *Journal of Cytology* [Internet]. 2012 Jan 1;29(2):152. Available from: <https://doi.org/10.4103/0970-9371.97165>