

Tomographic comparison of changes in the nasopharynx after treatment with MARPE and self-ligating appliances

ABSTRACT

Objective: The objective of this study was to compare the sagittal area, minimum axial area and volume of the nasopharynx after treatment with MARPE and self-ligating appliances.

Material and Methods: The sample consisted of documentation and initial and final CT scans of 37 patients with Class I malocclusion treated without extraction, divided into 2 groups: Group 1 (Self-ligating): 21 patients, mean age of 19.55 years (s.d.=1.31), 11 men and 10 women, with moderate dental crowding, presence of maxillary atresia and treated with self-ligating fixed appliance Damon 3MX. Group 2 (MARPE): 16 patients, with mean age of 24.92 years (s.d.=7.60), 11 women and 5 men, presence of maxillary atresia and posterior crossbite and treated with mini-implant anchored rapid maxillary expansion (MARPE). The Dolphin Imaging 3D software was used to assess nasopharyngeal changes using CT scans before and after treatment with MARPE and after leveling with self-ligating appliances. Intergroup comparison was performed using the independent t-test.

Results: The MARPE group showed a statistically greater increase in all nasopharyngeal measurements, ie, sagittal area, minimum axial area and volume, with treatment, than the self-ligating group.

Conclusion: Miniscrew-supported rapid maxillary expansion (MARPE) achieved better results with greater increase in all nasopharyngeal measurements than self-ligating appliances.

Keywords: *Orthodontic Anchorage Procedures. Airway Management. Cone Beam Computed Tomography. Fixed Orthodontic Appliances.*

1. INTRODUCTION

The miniscrew assisted rapid palatal expansion (MARPE) was developed to treat young adult patients with maxillary discrepancy, minimizing the need for surgically assisted rapid maxillary expansion. According to Lombardo et al.[1] the expansion obtained with MARPE causes minimal damage to the teeth and periodontium, correcting transverse deficiencies. Furthermore, as mini-implants are anchored in bone, the force exerted by the device results in skeletal movement[1].

In an attempt to correct maxillary atresia with compensatory orthodontics, self-ligating appliances are an accessible option for orthodontists. According to Lima et al.[2] the Damon self-ligating system results in an increase in the dimensions of the maxillary arch, mandibular intercanine and interpremolar distances when compared to conventional appliances.

Some authors claim that MARPE can improve airflow in the nasal cavity, leading to an improvement in respiratory function due to the increase in volume

of the upper airways[3-7], With the use of self-ligating appliances, there appears to be no significant increase in the upper airways[8, 9].

According to Calil et al.[10] MARPE produced more skeletal effects, and the self-ligating appliances more dental effects.[10] Furthermore, MARPE is effective and efficient in increasing the airways dimensions increasing the nasal cavity and nasopharyngeal volume[11]. Both skeletal and dental maxillary expansion are efficient in increasing airway volume[11].

Since there is no comparison between the changes of nasopharyngeal measurements after treatment with self-ligating appliances and the MARPE appliance, this study aimed to compare the sagittal area, minimum axial area and nasopharynx volume after treatment with MARPE and self-ligating appliances.

2. MATERIAL AND METHODS

2.1. Material

This study was approved by the Human Research Ethics Committee of Ingá University Center UNINGÁ (protocol n. 51486321.4.0000.5220).

The sample calculation was based on an alpha significance level of 5% and a beta of 20% to detect a minimum difference of 5500mm³ with mean standard deviation of 5408.15mm³ for the nasopharynx volume.[12] Therefore, the sample calculation resulted in the need for at least 16 patients in each group.

This retrospective research was composed of patients previously treated at the Instituto de OdontologiaAvanzada, Assunción, Paraguay and Bauru Dental School, University of São Paulo, Bauru, Brazil.

The following inclusion criteria were used: patients with Class I malocclusion, no prior orthodontic treatment, presence of all erupted teeth up to first molars, healthy periodontium, and minimum age of 16 years.

The sample consisted of initial and final cone beam computed tomography (CBCT) scans of 37 patients divided into 2 groups:

Group 1 (Self-ligating): 21 patients (11 male; 10 female) with mean age of 19.55 years (s.d.=1.31), with moderate dental crowding, presence of maxillary atresia requiring transverse maxillary increase and treated with self-ligating fixed appliance (Damon 3MX,Ormco, Orange, USA). This sample was obtained from the archives of the Bauru Dental School, University of São Paulo, Bauru, Brazil. The archwire sequence for alignment and leveling of teeth was followed: 0.014", 0.014"x0.025", and 0.016"x0.025" Copper NiTi (Ormco, Orange, USA). Finally, 0.019"x0.025" stainless steel archwires were installed. Alignment time was 6 months on average. Patients were evaluated at the beginning of treatment (T1) and the end of the alignment and levelling stage (T2), when the 0.019"x0.025" stainless steel archwires were in place for one month.

Group 2 (MARPE): 16 patients (5 male; 11 female), with mean age of 24.92 years (s.d.=7.60), with maxillary atresia and posterior crossbite, treated with miniscrews assisted rapid palatal expansion (MARPE). This sample was obtained from the archives of the Instituto de OdontologiaAvanzada, Assunción, Paraguay. The patients underwent maxillary disjunction with the MARPE device (PecLab, Belo Horizonte, Brazil), model SL, supported on four MARPE titanium

mini-implants, with bands on the first molars. The activation protocol was ¼-turn in the morning and ¼-turn at night until a relationship was obtained in which the palatal cusps of the maxillary first molars touched the buccal cusps of the mandibular first molars. No other orthodontic treatment was performed. Suture rupture was confirmed clinically by evaluating the opening of the maxillary interincisor diastema. Only patients with successful in opening the midpalatal suture was included. The device was maintained for 4 months after the end of expansion. Patients were evaluated at the beginning of treatment (T1) and right after the removal of the expander (T2).

2.2. Methods

To evaluate changes in the nasopharynx, CBCT scans were performed before treatment (T1) and after alignment and leveling in the self-ligating group and immediately after the removal of the expansion appliance in the MARPE group (T2).

In group 1, patients underwent CBCT scans with the i-Cat Cone Beam 3-D Dental Imaging System (USA), with the following image acquisition protocol: amperage of 36.12mA, 120kV, field of view (FOV) of 13cm (including the entire face), exposure time was 40 seconds, generating a voxel of 0.25x0.25x0.25mm.

In group 2, CBCT scans were performed using the Orthophos SL 2D/3D device (Sirona Dental Systems GmbH, Germany) with the following image acquisition protocol: FOV of 8cm Ø x 5.5cm height (maxilla) and voxel of 0.08mm.

The images were saved and imported in DICOM (Digital Imaging and Communications in Medicine) format and were measured using Dolphin Imaging 3D software (Chatsworth, USA), version 11.95 Premium.

Initially, the head position was standardized, using as a reference in the frontal view, the plane that passes through the lowest point of the infraorbital foramina, in the lateral view and also in the axial direction, the plane that passes through the Anterior Nasal Spine (ANS) and Posterior Nasal Spine (PNS).[10]

2.2.1. Analysis of the upper airway (nasopharynx)

Due to the fact that, in the MARPE group, the CBCT scans included only the maxilla, the oropharynx could not be evaluated.

The nasopharynx was measured using a tool from the Dolphin Imaging 11.95 Premium program (Chatsworth, USA) appropriate for evaluating the upper airways[9]. A plane transverse to the sagittal plane passing through in the PNS and the lower medial border of the first cervical vertebra divides the pharyngeal airway into two segments: nasopharynx (upper) and oropharynx (lower)[9].

The limits of the nasopharynx, or upper airway, were 2 lines: the upper line was established by a point on the posterior edge of the nasal spine (PNS) and the midpoint of the curvature between the upper and lower surfaces of the basilar portion of the occipital bone (Ba). The lower line was established by a medial point in the anterior region of the first cervical vertebra (CV1m) to a point on the anterior wall of the nasopharynx, parallel to the nasal floor (Na) (Figure 1).

Once the portion of the airway of interest was defined, the Dolphin 3D airway analysis tool was used to measure the nasopharynx. This program allowed airway selection by defining a threshold range of computed tomography units that characterized the sectioned airspace. As the air space has a lower computed tomography value than the denser surrounding soft tissues, it was possible to delimit the same region to perform the measurements. Then, using the sinus/airway analysis option, points were marked in the selected region and the volume option was updated and the software shows the volume, sagittal area and minimum axial area of the nasopharynx (Figure 1).

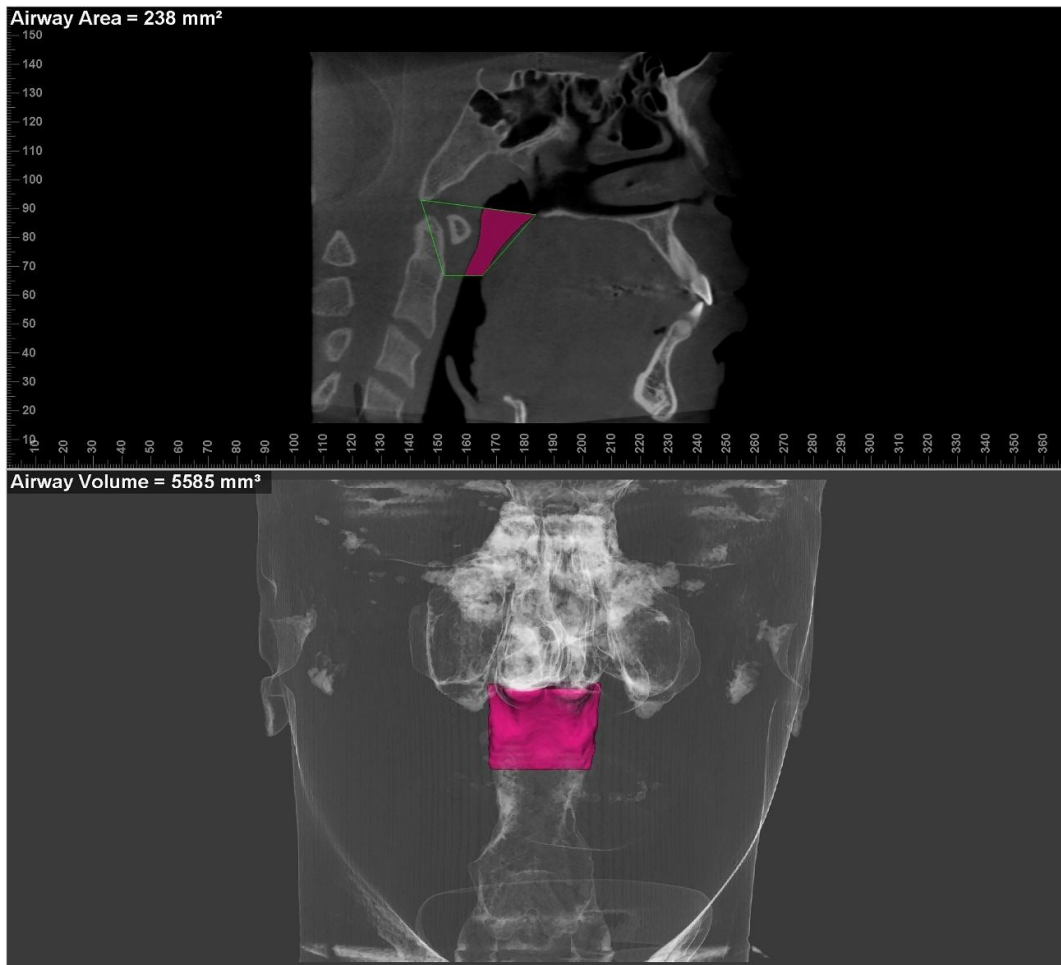


Figure 1. Nasopharynx measurement.

2.2.2. Error study

To calculate the error of the method, the initial and final CBCT scans of 12 patients were evaluated. The first and second measurements were performed with a month interval. Dahlberg's formula was used to evaluate the casual errors[13], and the systematic errors were evaluated by dependent t test[14].

2.2.3. Statistical analysis

The normality of the data normality was confirmed by the Shapiro-Wilk test. Intragroup comparisons were performed by the dependent t test. Intergroup comparisons at T1 and T2 stages and changes with treatment were performed using the independent t test.

The tests were performed with Statistica software (version 12.0, Statsoft, Tulsa, USA). Data were considered significant at $P < 0.05$.

3. RESULTS

There was no significant systematic error, and the largest casual error was 52.41 mm^3 , which is considered within acceptable limits.[15]

The self-ligating group was significantly younger than MARPE group (Table 1). There was compatibility of sex distribution between the groups (Table 1).

Table 1. Results of the intergroup compatibility of age and sex distribution.

Variables	Self-ligating (N=21)	MARPE (N=16)	P
	Mean (s.d.)	Mean (s.d.)	
Age (years)	19.55 (1.31)	24.92 (7.60)	0.003* ^T
Sex			$X^2 = 1.65$
Males	11	5	DF=1
Females	10	11	$p = 0.198^{\alpha}$

* Statistically significant for $P < 0.05$

^T independent t test; ^α chi-square test

The comparison between the initial and final stages of the self-ligating group showed no significant changes in the measurements of the nasopharynx with the treatment performed (Table 2). In MARPE group, there was a statistically significant increase in the sagittal area and nasopharyngeal volume with treatment (Table 2).

There was compatibility between the groups in nasopharyngeal measurements in the initial stage, and the measurements were also similar between the groups in the final stage (Table 3). With treatment, the MARPE group showed a statistically significant increase in all nasopharyngeal measurements, i.e., sagittal area, minimum axial area and volume when compared to the self-ligating group (Table 3).

Table 2. Results of the intragroup comparison of the initial and final stages of nasopharyngeal measurements (dependent t-test).

Variables	Initial		Final		P
	Mean	s.d.	Mean	s.d.	
Self-ligating (n=21)					
Sagital area (mm ²)	233.13	111.45	270.02	106.82	0.140
Minimum axial area (mm ²)	78.21	62.13	83.22	71.65	0.405
Volume (mm ³)	6943.63	4789.23	7532.81	5489.17	0.356
MARPE (n=16)					
Sagital area (mm ²)	229.71	107.88	304.83	95.22	0.045*
Minimum axial area (mm ²)	75.91	59.12	104.37	45.01	0.136
Volume (mm ³)	6723.15	4678.92	9995.61	4002.33	0.042*

* Statistically significant for $P < 0.05$

Table 3. Results of intergroup comparison of the initial (T1) and final (T2) stages and treatment changes (T2-T1) of nasopharyngeal measurements (independent t-tests).

Variables	Self-ligating (N=21)		MARPE (N=16)		P
	Mean	s.d.	Mean	s.d.	
Initial stage (T1)					
Sagital area (mm ²)	233.13	111.45	229.71	107.88	0.926
Minimum axial area (mm ²)	78.21	62.13	75.91	59.12	0.910
Volume (mm ³)	6943.63	4789.23	6723.15	4678.92	0.889
Final stage (T2)					
Sagital area (mm ²)	270.02	106.82	304.83	95.22	0.311
Minimum axial area (mm ²)	83.22	71.65	104.37	45.01	0.308
Volume (mm ³)	7532.81	5489.17	9995.61	4002.33	0.139
Treatment changes (T2-T1)					
Sagital area (mm ²)	36.89	17.44	75.12	26.74	0.000*
Minimum axial area (mm ²)	5.01	3.07	28.46	12.56	0.000*
Volume (mm ³)	589.18	400.92	3272.46	2531.16	0.000*

* Statistically significant for $P < 0.05$

4. DISCUSSION

In this study, the sagittal area, minimum axial area and volume of the nasopharynx were evaluated using CBCT scans. CBCT was chosen due to the high quality images, with little distortion and high resolution[16]. Therefore, it is important that groups were comparable, to avoid the influence of other factors.

There was a statistically significant difference in the age of the groups, where self-ligating group was younger than MARPE group (Table 1); however, the majority of patients were young adults. Lagravère et al.[17] reported that in adulthood, there is little bone growth in the transverse dimension. Furthermore, the groups were evaluated for a short period of time: the self-ligating group was evaluated for 6 months and the MARPE group was evaluated immediately after expansion (average of 4 months). These differences in initial age and in the time between the first and second CBCT scans probably did not influence the results. In the self-ligating group, patients had a minimum age of 18 years and a maximum of 20 years and in the MARPE group, a minimum age of 17 years and a maximum of 32 years. And it was observed that there are no significant growth changes in maxillary width in women after 15 years of age and in men after 18 years[18, 19]. Although the self-ligating group is statistically younger, which would tend to favor better results for this group, the results were statistically significant higher for the MARPE group in relation to all nasopharyngeal measurements.

In the present study, patients which did not show opening of the midpalatal suture after treatment with MARPE were excluded[20]. The advanced degree of bone maturation of this suture can occur even in young adult patients, justifying the failure in some cases[21]. However, failure can also come from the zygomatic-maxillary complex and the circummaxillary sutures[22]. To avoid this, it is necessary to create a complete treatment plan with CBCT scans[19, 20, 23].

The groups performed the CBCT scans with different voxels (0.25mm and 0.08mm for self-ligating and MARPE, respectively), but this did not compromise the reliability of the results[24]. It is known that the smaller the voxel, the sharper the CBCT images, however, the 0.25mm voxel (self-ligating group) presented sufficient sharpness for measurements of the nasopharynx. According to a previous study, tomographic measurements proved to have similar reproducibility, even with images of different voxel sizes[25].

The measurements were made only in the nasopharynx, because the MARPE sample had CBCT scans only from the maxilla, which did not allow the measurement of the oropharynx.

There was no statistically significant increase in the nasopharynx after leveling with self-ligating appliances (Table 2), corroborating previous studies[8, 12]. In the study by Vieira et al.[12], the Damon System produced a significant transverse increase in the posterior region of the maxillary and mandibular arches with differences in dental inclinations, however, there was no significant difference in the upper airways[12]. Besides, rapid maxillary expansion with Hyrax followed by fixed appliances produced more dimensional changes in the upper airway than the Damon system[8].

The results found show an increase in the nasopharynx and improvement in the upper airway with MARPE treatment, which may favor an increase in airflow[26-29], also enabling improvement in tongue posture and

favorable pharyngeal adaptations, contributing to improvement in Obstructive Sleep Apnea Syndrome (OSAS)[30-32].

With the expansion of the MARPE group, there was a statistically significant increase in the nasopharyngeal sagittal area and volume (Table 2), corroborating previous studies[3, 33, 34].

Abdalla et al.[16] reported that, at pretreatment, patients with younger skeletal age had a greater prediction of airway changes during treatment and had a greater increase in airway volume[4, 5, 35, 36].

Furthermore, the nasopharynx volume measured in the MARPE group was from 6,723.15 mm³ to 9,995.61 mm³ (Table 3). Yi et al.[36] reported a statistically significant increase in nasopharyngeal volume of 8.48% in the MARPE group. Kim et al.[4] noted a statistically significant increase in the volume of the nasal cavities and the volume of the nasopharynx after MARPE[4, 36].

Therefore, treatment with MARPE resulted in a greater increase in the nasopharynx than leveling and alignment with self-ligating brackets. There are no known studies comparing these treatment modalities. However, several studies show an increase in upper airway after MARPE[4, 5, 11, 36] and some studies have shown that there were not significant changes in the upper airway with self-ligating appliances[8, 12].

Both self-ligating and MARPE appliances have transverse expansive effects[10]. However, since MARPE promotes a greater skeletal effect than treatment with self-ligating appliances[10], a greater increase in airways was already expected with the use of MARPE when compared to the self-ligating appliance, as demonstrated by the results of the present study.

5. CONCLUSION

MARPE treatment obtained better results with greater increase in all nasopharyngeal measurements than self-ligating appliances.

CONSENT

Not applicable.

ETHICAL APPROVAL

All authors hereby declare that all experiments have been examined and approved by the appropriate ethics committee and have therefore been performed in accordance with the ethics standards laid down in the 1964 Declaration of Helsinki.

REFERENCES

- [1] Lombardo L, Carlucci A, Maino BG *et al.* Class III malocclusion and bilateral cross-bite in an adult patient treated with miniscrew-assisted rapid palatal expander and aligners. *Angle Orthod.* 2018;88(5),649-64.
- [2] Lima NCJ, Falcão ICMCF, Freitas KMS *et al.* Comparison of changes in dental arch dimensions in cases treated with conventional appliances and self-ligating Damon system. *Open Dent J.* 2018;12(1)
- [3] Kavand G, Lagravere M, Kula K, Stewart K, Ghoneima A. Retrospective CBCT analysis of airway volume changes after bone-borne vs tooth-borne rapid maxillary expansion. *Angle Orthod.* 2019;89(4),566-74.
- [4] Kim SY, Park YC, Lee KJ *et al.* Assessment of changes in the nasal airway after nonsurgical miniscrew-assisted rapid maxillary expansion in young adults. *Angle Orthod.* 2018;88(4),435-41.
- [5] Li Q, Tang H, Liu X *et al.* Comparison of dimensions and volume of upper airway before and after mini-implant assisted rapid maxillary expansion. *Angle Orthod.* 2020;90(3),432-41.
- [6] Smith T, Ghoneima A, Stewart K *et al.* Three-dimensional computed tomography analysis of airway volume changes after rapid maxillary expansion. *Am J Orthod Dentofacial Orthop.* 2012;141(5),618-26.
- [7] Zeng J, Gao X. A prospective CBCT study of upper airway changes after rapid maxillary expansion. *Int J Pediatr Otorhinolaryngol.* 2013;77(11),1805-10.
- [8] Gianoni-Capenakas S, Flores-Mir C, Vich ML, Pacheco-Pereira CJAJoO, Orthopedics D. Oropharyngeal 3-dimensional changes after maxillary expansion with 2 different orthodontic approaches. 2021;159(3),352-9.
- [9] Vieira MCSS. Avaliação tridimensional das alterações nas vias aéreas superiores associadas a dois tipos de aparelhos expansores maxilares. Londrina: Universidade Norte do Paraná; 2019.
- [10] Calil RC, Ramirez CMM, Otazu A *et al.* Maxillary dental and skeletal effects after treatment with self-ligating appliance and miniscrew-assisted rapid maxillary expansion. 2021;159(2),e93-e101.
- [11] Mirhashemi A, Arab S, Bahrami R. Miniscrew-Assisted Palatal Expansion and Airway Volume Changes; A Systematic Review. *Iranian J Orthod.* 2021;16(1),1-6.
- [12] Vieira BdS. Cone-beam computed tomography evaluation of upper airway, dental arches dimensions and buccolingual inclination through of cases treated with Damon System: Universidade de São Paulo; 2017.
- [13] Dahlberg GJSmf, students. b. Statistical methods for medical and biological students. 1940;
- [14] Houston WJAjoo. The analysis of errors in orthodontic measurements. 1983;83(5),382-90.
- [15] Iwasaki T, Saitoh I, Takemoto Y *et al.* Tongue posture improvement and pharyngeal airway enlargement as secondary effects of rapid maxillary expansion: a cone-beam computed tomography study. *Am J Orthod Dentofacial Orthop.* 2013;143(2),235-45.
- [16] Abdalla Y, Brown L, Sonnesen L. Effects of rapid maxillary expansion on upper airway volume: A three-dimensional cone-beam computed tomography study. *Angle Orthod.* 2019;89(6),917-23.
- [17] Lagravère MO, Carey J, Heo G, Toogood RW, Major PW. Transverse, vertical, and anteroposterior changes from bone-anchored maxillary expansion vs traditional rapid maxillary expansion: a randomized clinical trial. *Am J Orthod Dentofacial Orthop.* 2010;137(3),304. e1-. e12.

- [18] Edwards CB, Marshall SD, Qian F *et al.* Longitudinal study of facial skeletal growth completion in 3 dimensions. *American Journal of Orthodontics and Dentofacial Orthopedics.* 2007;132(6),762-8.
- [19] Hwang S, Noh Y, Choi YJ *et al.* Dentofacial transverse development in Koreans according to skeletal maturation: A cross-sectional study. *The Korean Journal of Orthodontics.* 2018;48(1),39-47.
- [20] Park JJ, Park Y-C, Lee K-J *et al.* Skeletal and dentoalveolar changes after miniscrew-assisted rapid palatal expansion in young adults: A cone-beam computed tomography study. *The Korean Journal of Orthodontics.* 2017;47(2),77-86.
- [21] Angelieri F, Cevidanes LHS, Franchi L *et al.* Midpalatal suture maturation: classification method for individual assessment before rapid maxillary expansion. *Am J Orthod Dentofacial Orthop.* 2013;144(5),759-69.
- [22] Cantarella D, Dominguez-Mompell R, Moschik C *et al.* Midfacial changes in the coronal plane induced by microimplant-supported skeletal expander, studied with cone-beam computed tomography images. *American Journal of Orthodontics and Dentofacial Orthopedics.* 2018;154(3),337-45.
- [23] Mah JK, Danforth RA, Bumann A, Hatcher D. Radiation absorbed in maxillofacial imaging with a new dental computed tomography device. *Oral Surgery, Oral Medicine, Oral Pathology, Oral Radiology, and Endodontology.* 2003;96(4),508-13.
- [24] Costa AL, Barbosa BV, Perez-Gomes JP *et al.* Influence of voxel size on the accuracy of linear measurements of the condyle in images of cone beam computed tomography: A pilot study. *J Clin Exp Dent.* 2018;10(9),e876-e82.
- [25] Menezes CC, Janson G, da Silveira Massaro C, Cambiaghi L, Garib DG. Precision, reproducibility, and accuracy of bone crest level measurements of CBCT cross sections using different resolutions. *Angle Orthod.* 2016;86(4),535-42.
- [26] De Felipe NLO, Da Silveira AC, Viana G *et al.* Relationship between rapid maxillary expansion and nasal cavity size and airway resistance: short-and long-term effects. *Am J Orthod Dentofacial Orthop.* 2008;134(3),370-82.
- [27] Enoki C, Valera FCP, Lessa FCR *et al.* Effect of rapid maxillary expansion on the dimension of the nasal cavity and on nasal air resistance. *Int J Pediatr Otorhinolaryngol.* 2006;70(7),1225-30.
- [28] Iwasaki T, Saitoh I, Takemoto Y *et al.* Improvement of nasal airway ventilation after rapid maxillary expansion evaluated with computational fluid dynamics. *Am J Orthod Dentofacial Orthop.* 2012;141(3),269-78.
- [29] Zeng B, Ng AT, Qian J *et al.* Influence of nasal resistance on oral appliance treatment outcome in obstructive sleep apnea. *J Sleep.* 2008;31(4),543-7.
- [30] Iwasaki T, Yoon A, Guilleminault C, Yamasaki Y, Liu SY. How does distraction osteogenesis maxillary expansion (DOME) reduce severity of obstructive sleep apnea? *J Sleep Breathing.* 2020;24,287-96.
- [31] Pirelli P, Saponara M, Guilleminault C. Rapid maxillary expansion in children with obstructive sleep apnea syndrome. *Sleep and Breathing.* 2004;27(4),761-6.
- [32] Vinha PP, Faria AC, Xavier SP, Christino M, de Mello-Filho FV. Enlargement of the pharynx resulting from surgically assisted rapid maxillary expansion. *J Oral Maxillofac Surg.* 2016;74(2),369-79.

[33] Bazargani F, Magnuson A, Ludwig BJEJoO. Effects on nasal airflow and resistance using two different RME appliances: a randomized controlled trial. 2018;40(3),281-4.

[34] Mehta S, Wang D, Kuo C-L *et al.* Long-term effects of mini-screw–assisted rapid palatal expansion on airway: A three-dimensional cone-beam computed tomography study. 2021;91(2),195-205.

[35] Shetty A, Ratti S, Nakra P *et al.* Evaluation of Soft Tissue and Airway Changes in Individuals Treated with Mini-Implant Assisted Rapid Palatal Expansion (MARPE). 2022;32

[36] Yi F, Liu S, Lei L *et al.* Changes of the upper airway and bone in microimplant-assisted rapid palatal expansion: A cone-beam computed tomography (CBCT) study. 2020;28(2),271-83.

UNDER PEER REVIEW