

Vitamin-resistant rickets type 2 Hereditary Disorder : About a new case

1. Abstract:

The aim : the aim of the study is to resume the difficulties to diagnosis and to manage a rare type of rickets the vitamin-resistant type II.

Introduction :

Rickets is a disease of the skeleton of growing children due to a defect in bone mineralization.

Much rarer is vitamin-resistant rickets secondary to genetic or acquired abnormalities of phosphocalcic metabolism. Pseudo-deficiency rickets type II is a vitamin-resistant rickets due to an abnormality of the vitamin D receptor.

Report case : This is a 3 years old boy of consanguineous parents, with totally alopecia who presented an inability to walk and stand. The paraclinical signs (radiological and biological) also the character genetic mutation put the diagnosis of vitamin-resistant rickets type II.

Discussion :

Vitamin-resistant ricket type II is a rare disease, the alopecia and the normal level of plasma 25 OH vitamin D is very suggestive of the diagnosis. The management of the disease is very difficult and requires a long term multidisciplinary approach.

Conclusion :

Target gene therapy and genetic counselling offer hope of cure for children who do not respond to long-term high-dose replacement therapy.

Keywords : vitamin-resistant ricket type II, alopecia, hypocalcemia, mutation genetic.

2. Introduction :

Rickets is a disease of the skeleton of growing children due to a defect in bone mineralization. The most common cause is vitamin D deficiency corresponding to deficiency rickets, the best treatment of which is systematic prevention.

A rare type of the disease is the vitamin-resistant rickets secondary to genetic abnormalities of the phosphocalcic metabolism.

In this context, we report the observation of a new case of vitamin-resistant rickets type II, through which we recall all the specific clinical and paraclinical signs (radiological and biological), the characteristic genetic mutation but also the difficulty of the therapeutic management of the disease.

3. Case report :

This is a 3-year-old boy of 1st degree consanguineous parents, 4th sibling of 4, birth weight 2Kg who presents with total alopecia also affecting the eyebrows with a manifest height-weight delay greater than > -2 SDS with a weight of 10 Kg and a height of 75 cm and a PC of 45cm,

He presents a facial dysmorphism with prominent frontal bosses.

The examination of the limbs finds epiphyseal knots at the wrists, a genu valgum deformity of the lower limbs with sternal protrusion and diffuse bone pain.

The initially acquired gait was waddling and difficult to maintain then subsequently the child presented an inability to walk and stand.

The child also has no delay in higher functions on the contrary a particularly alert child with a very developed language and easy contact.

Biologically, hypocalcemia at 70 mg/l was found, alkaline phosphatase at 2299U/l, hypophosphatemia at 23 mg/l, 25,OH vitamin D dosage at 21ng/ml, 1,25 OH vitamin D dosage was very high at 177pg/ml and hyperparathyroidism at 400 pg/ml.

The alkaline phosphatase dosage was at 2299UI/l and blood creatinine at 5 mg/l , urea at 0,16g/l. And finally the urinary calcium was at 30 mg/l and urinary phosphorus at 701mg/l .

Radiologically ,X-rays of the skeleton and thorax revealed diffuse bone demineralization with a striated and condensed appearance of the distal metaphyses of the long bones, pathological fractures at the level of the diaphyses of the right and left ulna, a champagne cork appearance of the chondrocostal junctions.

The molecular study carried out revealed the presence of a new deleterious mutation at the level of the VDR gene classified as pathogenic gene compatible with the diagnosis. Vitamin-resistant rickets type II due to anomaly of the VDR gene is of autosomal recessive transmission. Molecular analysis by targeted Sanger sequencing can be offered to parents to confirm that they are carriers of the mutation and to provide genetic counseling.

The patient was put on: - high dose calcitriol (alpha to 1ug) 5 tabs/day
-high dose oral calcium (2 cam 2 doses per day)
-vitamin D 25000 IU / 15 days
-phosphoneuros 50 drops/day

The child did not respond to the treatment carried out at high doses despite regular monitoring and adequate intake of his treatment, he presented in fact many complications including pathological fractures at the wrists and pelvis but also episodes of wheezing dyspnea and a severe drop in serum calcium to 60 mg/l requiring boluses of injectable calcium, renal ultrasound found an appearance of nephrocalcinosis type1.

4.Discussion :

Vitamin-resistant rickets is one of the common cause of calcipenic rickets where there is inactivating mutation of vitamin D receptor.

Vitamin-resistant rickets to 1,25OH (D2)type II has a clinical particularity, the frequent association of early and diffuse alopecia which has a great diagnostic value. These patients usually presents with rachitisme changes over hans and feet with low calcium, low to normal phosphate, raised iPTH and alkaline phosphatase.

Biologically, the normal or even high level of plasma 25 OH vitamin D allows vitamin D deficiency to be excluded. [1,2,3]

At the same time, the observation of a very high plasma level of 1,25 (OH) D2 indicates peripheral resistance to 1,25 (OH) D2.[1]

Treatment uses 1 alpha hydroxyl derivatives of vitamin D and calcium.

Despite the context of resistance, a trial of treatment with 1 alpha hydroxyl derivative of vitamin D must be undertaken systematically.

Due to a lack of partial receptivity, the use of high doses of 1 alpha OHD3 or 1,25 OH D2, D3 10 to 20 ug/day is sometimes effective; sometimes resistance is total even when using extremely high doses of several tens of ug/day.

Treatment with calcium either orally or parenterally is necessary in order to increase passive intestinal absorption of calcium, which is normally order to increase passive intestinal absorption of calcium normally very low, oral treatment requires high doses of calcium (3 to 4g of calcium element divided into 4 or 5 doses per day) which can lead to a slow correction of rickets.[4,5,6]

Most often, the treatment remains difficult and the response remains variable and requires high doses of supplementation (1alpha and calcium) exposing the child to the risks of renal complications (nephrocalcinosis), hypercalciuria and hypercalcemia but also those related to the disease especially pathological fractures .[7,8]

This shows the interest of multidisciplinary management and regular monitoring (physical examinations, biochemical analyses, standard radiographs and renal ultrasounds) in this disease.[8,9,10]

Targeted gene therapy in this disease remains promising in the therapeutic management of difficult cases.

5. Conclusion:

Vitamin-resistant rickets type 2 has autosomal recessive transmission due to a mutation of the genes coding for vitamin D receptors. Alopecia is described very frequently and is often indicative of the disease. Treatment is based on high-dose, long-term supplementation; gene therapy remains a promising therapeutic option in the future.

Ethical Approval

As per international standards or university standards written ethical approval has been collected and preserved by the author(s).

Consent

As per international standards, parental written consent has been collected and preserved by the author(s).

Disclaimer (Artificial intelligence)

Option 1:

Author(s) hereby declare that NO generative AI technologies such as Large Language Models (ChatGPT, COPILOT, etc) and text-to-image generators have been used during writing or editing of manuscripts.

Option 2:

Author(s) hereby declare that generative AI technologies such as Large Language Models, etc have been used during writing or editing of manuscripts. This explanation will include the name, version, model, and source of the generative AI technology and as well as all input prompts provided to the generative AI technology

Details of the AI usage are given below:

- 1.
- 2.
- 3.

6. References :

- [1]. Vitamin-resistant rickets in children about 4 cases Kamal El Yansli Thesis n 145/13.
- [2]. Vitamin-resistant rickets with metabolic disorder of vitamin D action. Garbedian M, Mallet E, Linglat A, Lenhardt A. Medicines Sciences Publications (Lavoisier) 2nd edition 2011, 108118.
- [3]. Vitamin deficiency and rickets screening and treatment, practical aspects for clinicians. Elsa Gonzalez Nguyen Tang, Paloma Parvex, Alexandra Goischle. Rev Med Suisse 2019. 15, 384-9.
- [4]. Vitamin-resistant rickets type 2 about 2 observations. Simonin G, Chabrol B, Moulene O, Bollini G, Strouc.S, Mattei.J.F, Giraud.F. Revue Pediatie 1992, vol 47, Num12, p817-20.
- [5]. Vitamin-resistant rickets type 2: a rare cause of alopecia in children. R. Chaabouni, E. Bahloul, I. Chabchoub. Annales de Dermatologie et de Venereologie 145(12) S205-2018.

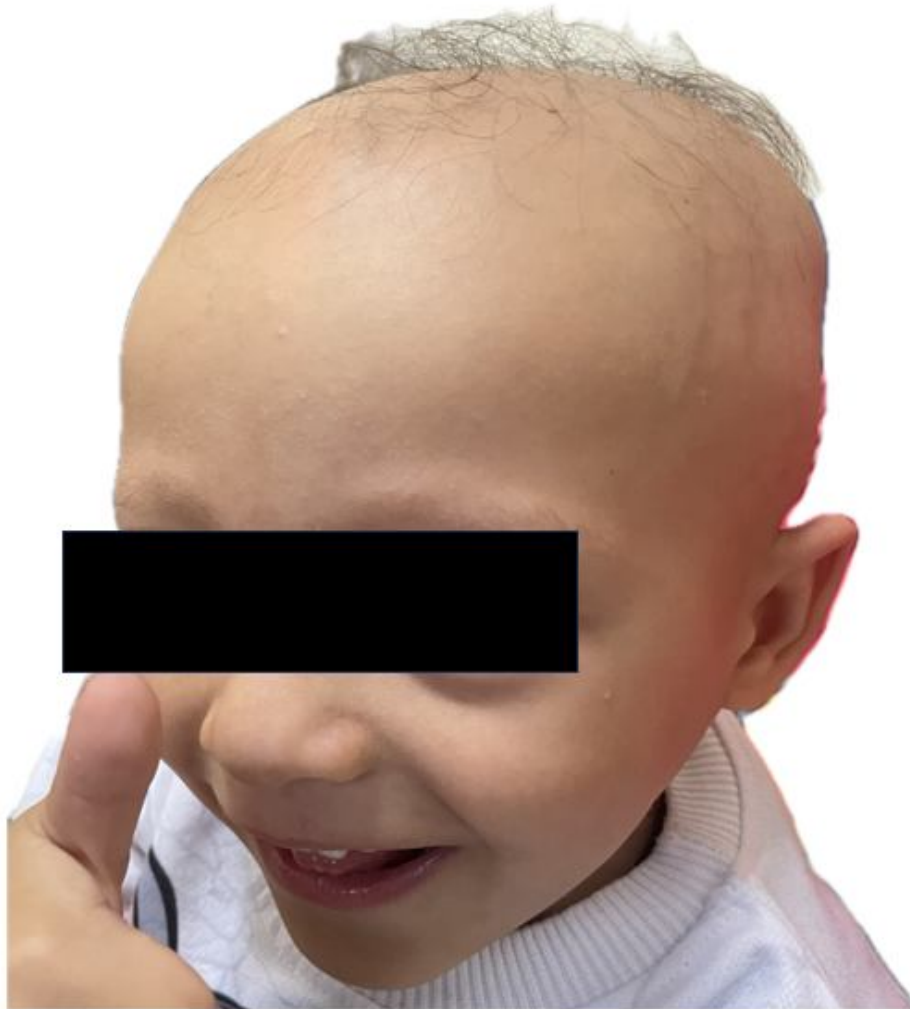[6].Rickets.I.Gargouri,I.El Aoud,Y.Hentati.JIM
Sfax N October 24 16,1-9.

[7]. Orthopedic aspects of vitamin-resistant rickets.F.Benkhatar,C Thamar-Noel,D.Bensahel.Pediatrics review
(Paris) 23-443 ,1987.

[8].Hypocalcemia and bone deformities in a case of vitamin-resistant rickets.B Roland-Gosselin,O Basmaison,
B.Rauchin,A-L Leclerc,N.Tourda Bouchain,P.Cochat.archives of pediatrics 20(7) 800-802-2013.

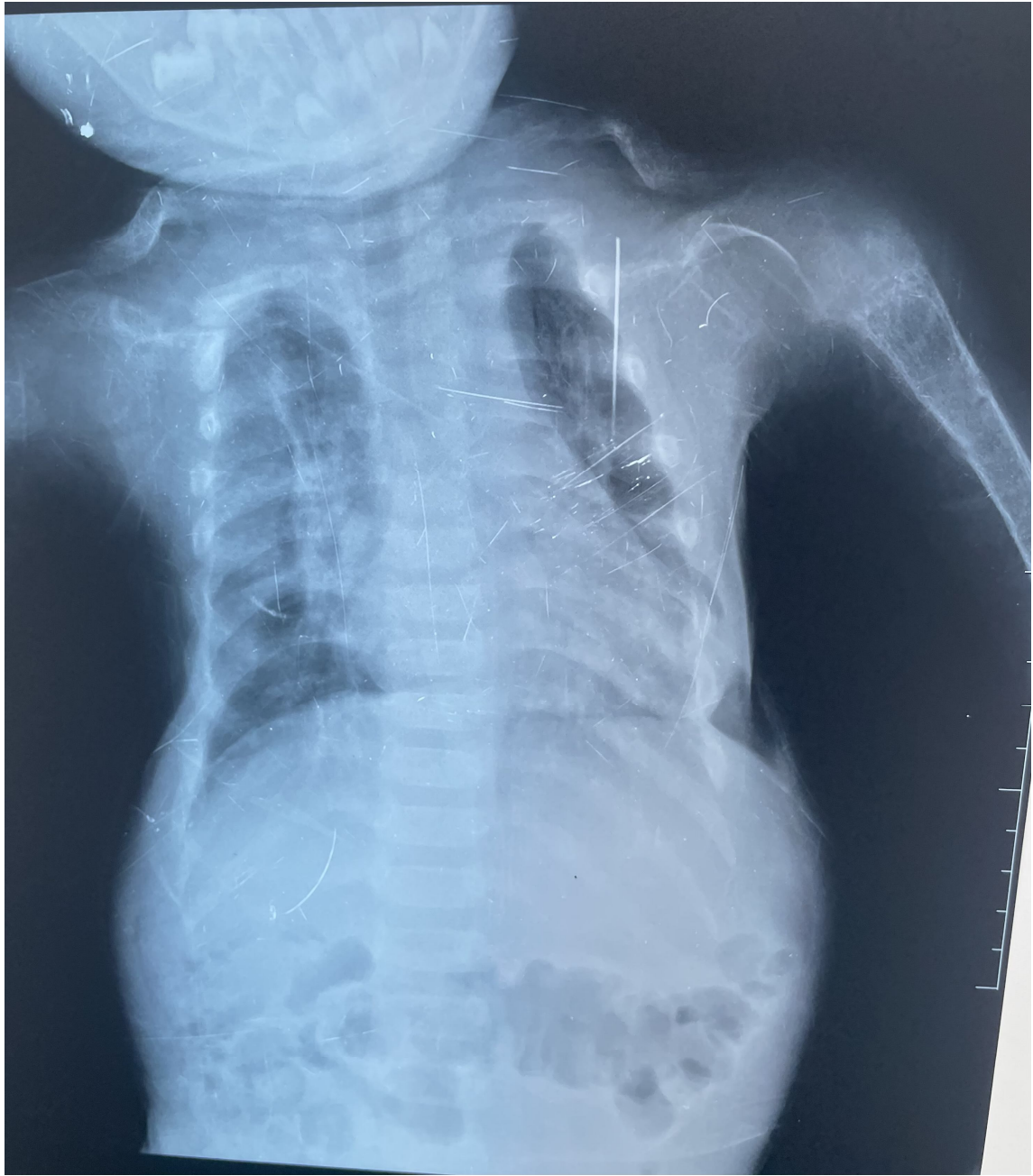
[9]. Vitamin D in pediatrics . Michel Vidailhel,E.Mallet. Medical press 42(10)1383-1390(2013).

[10].Familial form of vitamin-resistant rickets in children.S.Briki,S.Ben Berek,S.Halioui. Rhumatism review
10(73)1153-1154,

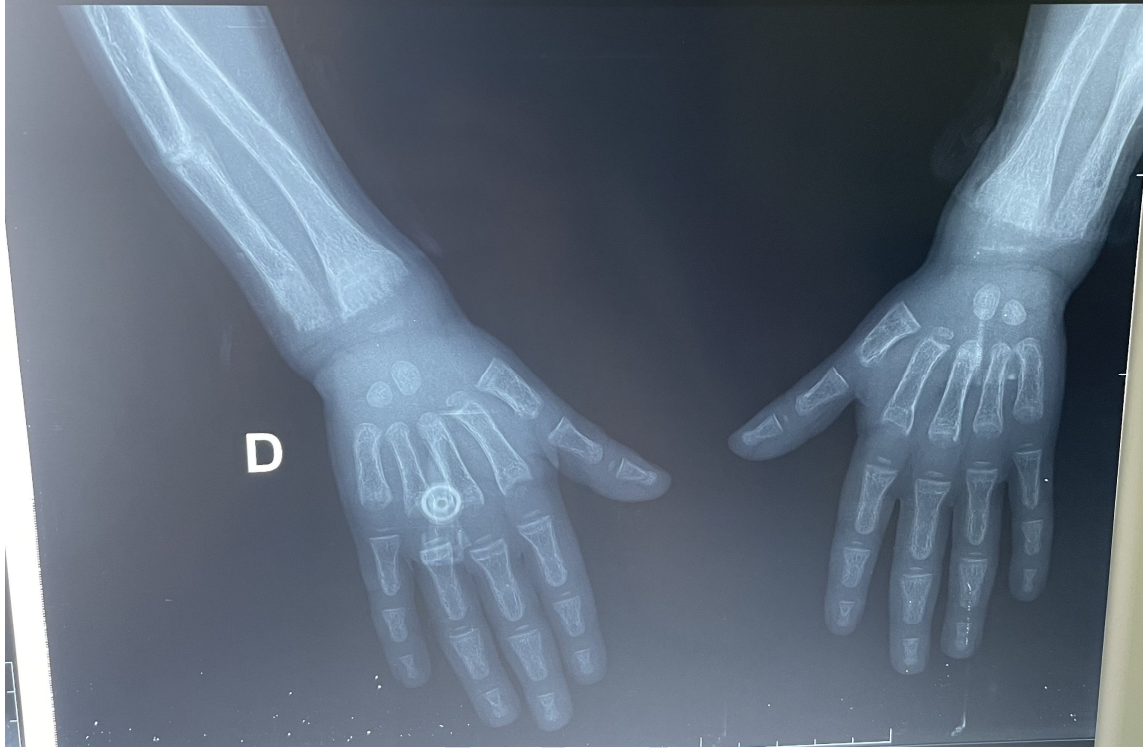

Photography 1 :Subtotal alopecia clinical sign characteristic of vitamin resistant rickets type II

UNDER PEER REVIEW

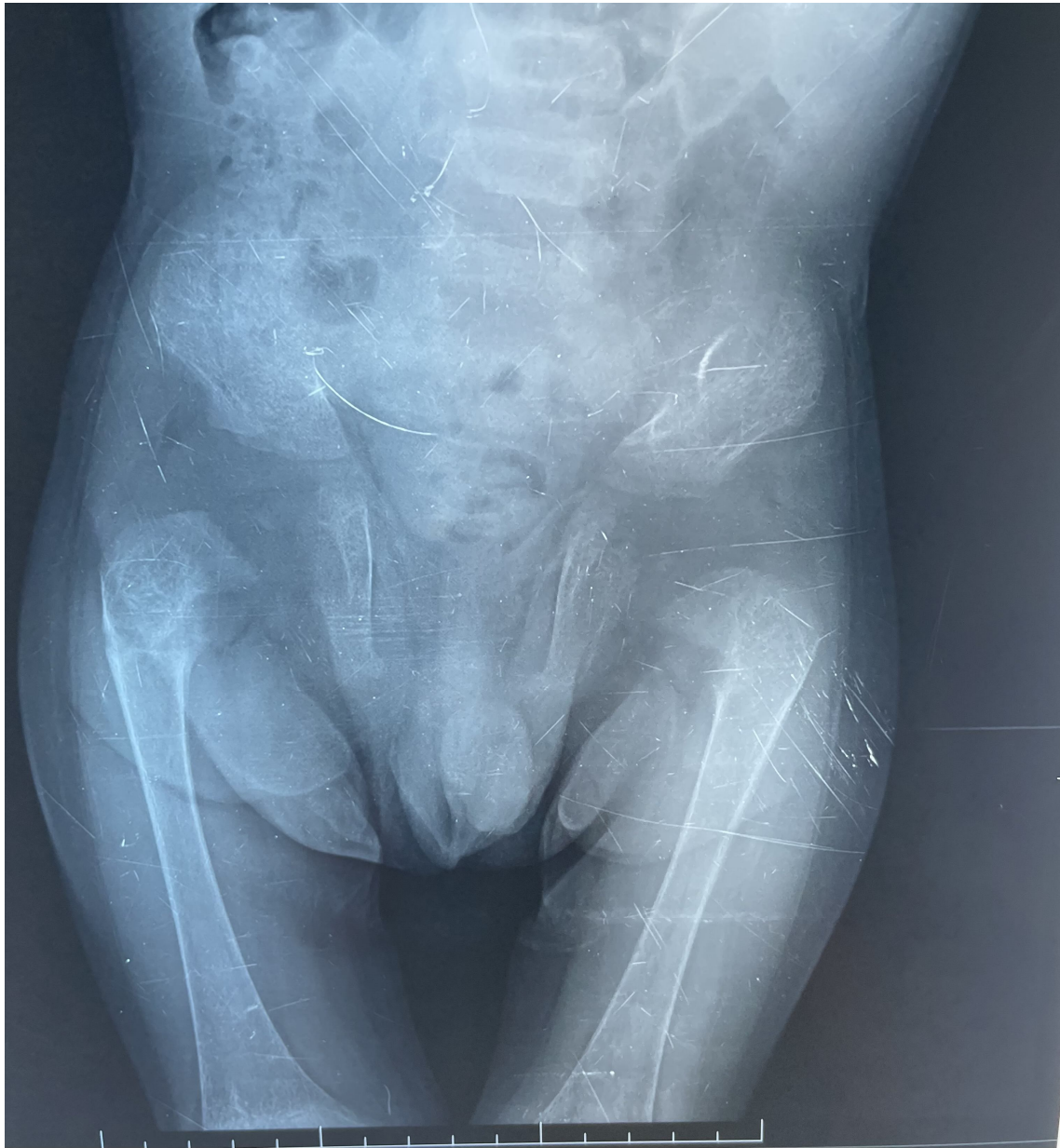

Picture 1



Picture 2

UNDER PELL



Picture 3

Pictures 1.2.3 : Standard radiographs diffuse demineralization, visible pathological fractures, cup-shaped appearance of the metaphyses and delayed appearance of ossification points, champagne cork appearance on the chest X-ray.