

Review Article

Elizabethkingiameningoseptica: A Rare Cause of Infection in Neonates

Abstract

Elizabethkingiameningoseptica is known to cause nosocomial infection, particularly among preterm neonates, causing high rates of mortality and significant neurological morbidity amid survivors. The disease presents several challenges in diagnosis and management due to its rarity and multidrug resistance. With the increasing incidence of preterm births in Middle East; and consequently, prolonged NICU admissions and hospital acquired infections, it is essential for the physicians to have knowledge on diagnostic and therapeutic strategies about an organism that could possibly affect such infants and cause devastating outcomes. Our study's primary objective is to give neonatologists a comprehensive overview of *E.meningoseptica* with its presenting features, risk factors, diagnostic modalities, management protocols and complications. We conducted a literature search on *E.meningoseptica* infection in neonates, and included a total of 19 reports of this disease, published between 2018-2023 in our study. The cases we reviewed consisted of both preterm and term neonates showing various presentations of the infection with the most common being meningitis. Rapid diagnosis through blood and CSF cultures or utilizing automated systems, together with the initiation of appropriate combination antibiotic therapy is indispensable. In addition, practicing rigorous infection control policies, and having a high index of suspicion when dealing with cases of neonatal sepsis and/ or meningitis is the cornerstone of management.

Keywords

neonates, neonatal sepsis, preterm, meningitis, multidrug resistant

Introduction

Infections caused by gram negative bacteria are reported to be a huge burden in the neonatal intensive care units, being extremely challenging to control due to their nosocomial origin and tendency to colonize human skin and mucous membranes.^[1] *Elizabethkingiameningoseptica* is one of such rare opportunistic gram-negative organisms causing healthcare associated infections among neonates and immunocompromised patients. The organism was first discovered by Elizabeth O. King in 1959 while she was conducting a research study to explore an unknown organism causing meningitis among the pediatric age group.^[2] The bacterium has been shown to most commonly spread via hands of healthcare workers, thus implementing good infection control policies is the key to its prevention.^[1]

It is known to cause early onset sepsis or meningitis in the neonates.^[3] World over, the most common organisms that cause meningitis and or sepsis in neonates are documented to be group B *Streptococcus*, followed by *Escherichia coli* and *Listeria monocytogenes*.^[4,5] Although an infrequent cause of meningitis, *E.meningoseptica* has been reported to have an estimated mortality rate of 57%; in addition it causes severe neurological sequelae among survivor babies with rates of hydrocephalus reaching as high as 69%.^[6,7] According to Mahmoud ElHalik et al.,2018, the incidence rate of sepsis in a tertiary hospital in Dubai, UAE was estimated to be 2.4% during 0-28 days of birth and 4.5% during 0-90 days in their 12-year retrospective study. The incidence of meningitis was reported to be 0.22%. The overall mortality observed was 17.3%. In addition, the results of the study showed that gram negative infections were the leading cause of sepsis among babies weighing less than 1.5kg.^[8]

E.meningoseptica is known to commonly affect preterm and low birth weight infants and, a study conducted in 2020 by Taha Z et al., showed an increased incidence of preterm and low birth weight babies in the Middle East.^[9] Considering the lack of available literature on *E.meningoseptica*, it often goes misdiagnosed particularly in rural areas with limited resources.^[3,10] Furthermore, the organism is known to be multidrug resistant posing further challenges in its management.^[1,11,12] Newer studies have shown fluoroquinolones to be a promising treatment for *E.meningoseptica*.^[3,6,10,11,13,14] Early diagnosis followed by appropriate and timely administration of both empiric and definitive antimicrobial therapy is the key to decrease mortality and morbidity.

Discussion

In this study we utilized the PubMed and Google Scholar electronic databases to select pertinent scientific studies published between 2018 and 2023. A total of 395 articles were obtained initially when predefined keywords such as “*Elizabethkingiameningoseptica*” and “neonate” or “neonatal” were used. After further screening and exclusion of duplicates and abstracts, a total of 19 full-text, open access case studies which met our inclusion criteria were included in the literature review (See Fig.1).^[1,3,6,7,10-24]

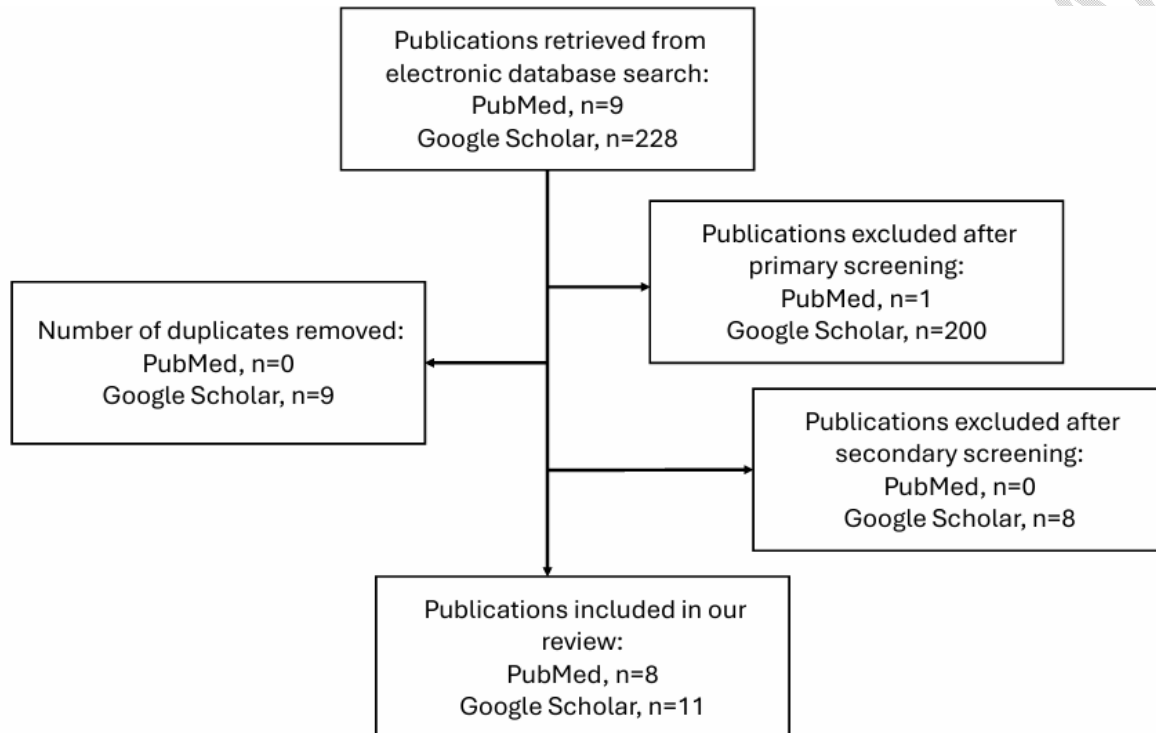


Figure 1: Flow chart summarizing the article selection process.

Organism and pathogenesis

Elizabethkingiameningoseptica was initially identified in the year 1959 by Elizabeth O. King,^[2] at the Centers for Disease Control in Atlanta, Georgia, USA, when it was placed under genus *Flavobacterium*. Later in the year 1994 it was shifted to the genus *Chryseobacterium* and finally classified under *Elizabethkingia* in 2005 after the phylogenetic analysis of its 16s rRNA.^[11,15] The bacterium is a gram negative, rod shaped, non-motile, aerobe, which is positive for catalase, oxidase, urease and does not ferment glucose.^[10] It produces indole by splitting tryptophan.^[11] It is known to grow well on chocolate and blood agar at 37-degree Celsius and gives rise to smooth, pale colonies in 24 hours.^[6,7,13,15]

Though several theories have been proposed, the exact pathogenesis by which *E.meningoseptica* causes disease is poorly understood. It is known to attach to the surface of various medical devices through its ability to form biofilm. The organism has been found to possess several virulence factors namely protease, catalase, peroxidase, acetyltransferase, capsular polysaccharide, lipooligosaccharide and heat shock proteins.^[11] Person to person transmission is reported to be uncommon. It has a low level of pathogenicity, as a result colonization and sepsis only develop in patients with an impaired immunity.^[1] **Since the transplacental transfer of most immunoglobulins required to fight infections occurs after 32 weeks of gestation, preterm infants are at a higher risk of being infected with *E.meningoseptica*.**^[10]

Risk Factors

The most important risk factor for transmission of the infection has been reported to be through the hands of healthcare workers due to lack of proper hand hygiene.^[1] Patient related risk factors include prolonged hospital stay, premature birth, prolonged vacuum-assisted delivery, immunocompromised health status, presence of indwelling catheters, feeding tubes and invasive devices.^[10,16,17] Other hospital environment related risk factors include hospital surfaces, water supply, saline solutions, syringes, incubators, and beds.^[17,18]

Clinical features

Infection with *E.meningoseptica* most often manifests as meningitis, bacteremia and hospital acquired pneumonia. Other less common presentations include skin, eye and soft tissue infections, endocarditis, catheter-associated, gastrointestinal, and biliary tract infections.^[1,17]

Preterm and low birth weight infants were the most affected.^[10,17,19] In a retrospective study conducted by Goel S et al., the majority of neonates who developed the infection were reported to be preterm with a median gestational age of 31 weeks and average birth weight 1.25 kg.^[19]

The most common presenting features involved pyrexia, psychomotor agitation, poor feeding, listlessness and hypoactivity.^[1,3,6,10,11,13-18,20-22] Few infants also developed seizures;^[3,7,14,16,17,20,23] and Joshi P et.al. reported a case where the neonate progressed to refractory status epilepticus.^[23] Goel and associates described the mean duration of symptom onset to be seven days after birth with most frequent presentations being lethargy (100%), apnea (85%), seizures (71%) and feeding difficulty (42%).^[19]

Frequently reported findings on examination were respiratory distress, reduced level of consciousness, bulging tense fontanelles, hypertonia with opisthotonus and abnormal primitive reflexes.^[1,3,6,10,11,13-18,20-22] In one of the cases the baby was referred already with complications of

hydrocephalus.^[13] An erythematous rash over the abdomen associated with episodes of fever was recorded by Masrani KM and associates.^[12] Rakesh K et al., reported a rare presentation of neonatal purpura fulminans with disseminated intravascular coagulation (DIC) caused by infection with *E.meningoseptica* in a preterm infant delivered at 31 weeks gestation, weighing 1.48kg who developed widespread purpura, pulmonary hemorrhage and eventually shock.^[24]

Investigations

E.meningoseptica being a rare organism creates significant challenges in its diagnosis which necessitated the authors to use various laboratory testing modalities to reach a definitive diagnosis based on initial presentation and progression of disease in the neonates. Initial investigations performed on admission included basic blood tests that involved; FBC which most commonly revealed findings of leukocytosis,^[1,6,14,17,23] neutrophilia,^[1,6,10,14] and thrombocytopenia;^[3,15,11,17,24] while thrombocytosis was reported in two cases^[6,20] and anemia noted in three neonates.^[6,14,15] The workup also showed elevated levels of inflammatory markers.^[3,6,7,10,15,17,20,22,23,18] A raised D-dimer,^[6,24] and deranged coagulation profile was recorded in a few neonates.^[15,24] Chest X-ray was done in three cases and showed bilateral infiltrates and a ground glass appearance,^[1] pulmonary opacities,^[14] and findings suggestive of bronchopneumonia.^[17]

Blood cultures were obtained in many cases and showed growth of the organism, indicating a positive result.^[1,10,12-14,16-18,20-22,24] Urine culture and cultures from vascular catheter, tracheal aspirate,^[1] umbilicus,^[22] endotracheal tube,^[18] and bronchoalveolar lavage^[17] were positive in few cases indicating the nosocomial origin of the infection.

CSF analysis was performed by most authors, which revealed a turbid appearance, leukocytosis with neutrophilia, low glucose and high protein content, all findings suggestive of meningoencephalitis.^[3,6,7,10,12-23] CSF culture was positive for the organism in several cases;^[1,12,13,16-18,20-22] but Favas K et al., reported a negative culture result.^[14]

Although broth microdilution has been suggested as a better method for sensitivity testing over disc diffusion and VITEK-2 automated system due to their inaccuracy,^[15,23] several authors performed these diagnostic tests. The VITEK 2 automated system was utilized for isolating *Elizabethkingiameningoseptica* in blood and CSF samples as well as for its sensitivity testing.^[6,7,11-13,19,21,23] A few authors conducted additional susceptibility testing using the Kirby–Bauer disc diffusion method.^[7,13,19] Since the Clinical and Laboratory Standards Institute (CLSI) has not proposed guidelines for antibiotic sensitivity testing of *E.meningoseptica*, Patro P and associates used breakpoints of non-Enterobacteriaceae and *Staphylococcus aureus* as interpretive

criteria.^[7]Goel S et al., and Murthy NS et al., used BacT/ALERT automated system for detection of the organism in blood and CSF samples.^[11,19]

Few authors performed imaging studies during the process of diagnosis. Cranial ultrasound findings were unremarkable in two infants,^[6,10] showed prominent bilateral ventricles in one case,^[15] while cerebral edema was noted in one of the neonate's,^[16] Joshi P et al., carried out an MRI of the brain which revealed ventriculitis and hydrocephalus.^[23]

Molecular methods for the diagnosis of *Elizabethkingiameningoseptica* are available and include DNA hybridization, pulsed-field gel electrophoresis, polymerase chain reaction (PCR) and gene sequencing (the most frequently used ones being 16S rRNA and RNA polymerase β -subunit (*rpoB*) gene sequencing methods). Though these techniques help in highly specific identification of the organism, its strain and as well as its resistance but their use is limited only to laboratories equipped with advanced technologies.^[25,26]

Treatment

Due to lack of available literature regarding effective empiric and definitive antibiotic therapy, the rarity of the organism and its multi drug resistant nature, infection with *Elizabethkingiameningoseptica* is associated with a poor clinical outcome.^[1,11,12] Though the organism being a gram-negative bacillus has documented resistance towards antibiotics reserved for treatment of gram-negative infections (beta-lactams, aminoglycosides, tetracyclines), it has shown susceptibility to antimicrobials directed against gram positive organisms (rifampicin, vancomycin, quinolones); thus, resulting in an inappropriate use of antibiotics.^[15,21,23] Moreover, the organism has no universally accepted CLSI guidelines for performing and interpreting the sensitivity results;^[7,11,12,23] in addition use of different methods for its diagnosis generates variation in the results, thus posing further challenges in its diagnosis and management.^[15,21]

In our review the most administered empiric antibiotic combinations were ampicillin and gentamicin,^[6,10,12,20] followed by cefotaxime and amikacin,^[3,7,23] and meropenem with amikacin.^[1,19] Celik K et al., and Patro P et al., used piperacillin-tazobactam in their empiric regimen with other antimicrobials.^[1,7] A few authors also combined vancomycin in empiric therapy.^[1,13,17,22] Whole genome sequencing of the organism shows that it possesses two beta lactamases, an extended spectrum beta lactamase (ESBL) and another class B carbapenem-hydrolyzing metallo-lactamase that contributes towards its resistance to beta lactam and carbapenem antibiotics respectively.^[1,11-13] In the studies we reviewed, definitive antibiotic therapy was administered to the sick neonates either as a single agent or as combination therapy after obtaining the results of culture and sensitivity tests.

The most frequently administered antibiotic included vancomycin.^[3,6,7,10,15,17,19,23,24] Celik K et al., Petrovic V et al., Demirbakan H et al., and Govindaraju G et al., had utilized vancomycin in the empiric therapy and continued it after sensitivity results.^[1,13,17,22] In reference to previous literature, Joshi P et al., and Jain M et al., administered vancomycin intraventricularly for a duration of three to four weeks via an external ventricular drain.^[18,23] Although several studies in the past had suggested the use of vancomycin in the treatment of infections with *E.meningoseptica*, recent literature claims it to have a high minimum inhibitory concentration (MIC \geq 16 μ g/mL) thus making it less potent.^[6,7,10] In contrary to the above-mentioned reports against vancomycin reaching low concentration in CSF, Hashmi AW et al., 2023 have reported the antibiotic to have excellent CSF penetration in meningitis and moreover recommend it as a drug of choice in empirical therapy for patients with suspected meningitis specifically against multi-drug resistant organisms.^[3] Previous studies advise combination therapy of vancomycin with either ciprofloxacin, linezolid, or rifampicin instead of monotherapy for effective and successful treatment of *E.meningoseptica* infections due to drug resistance.^[3,12]

Arbune M et al., and Favas K et al., administered piperacillin/tazobactam to the infants according to results of the sensitivity test.^[6,14] Celik K et al., and Patro P et al., utilized the antibiotic as empiric and continued it as definitive treatment since it was in line with the antibiotic susceptibility test.^[1,7] Few authors discontinued piperacillin/tazobactam during the course of treatment as the infants showed no significant improvement despite culture results showing susceptibility to the drug.^[10,12,18,21] A number of studies have reported piperacillin/tazobactam to be efficacious, but it is found to achieve a lower concentration in the CSF in contrast to quinolones;^[3,6] which is in accordance with the findings of our review as many authors reported it to be ineffective. Several authors used drugs belonging to the family of fluoroquinolones, ciprofloxacin was more widely administered,^[1,3,10-12,15,17,22,23] followed by levofloxacin.^[10,16,17,20-22,24] Recent literature suggests use of new agents from quinolone class of antibiotics to have shown scope in treatment of *E.meningoseptica* infections.^[13] The fluoroquinolone class of antibiotics are found to be lipophilic in nature; as a consequence, cross the blood brain barrier more effectively; in addition, they have a uniform volume distribution and therefore are not affected in conditions of sepsis.^[6,11,14] Recent studies have proposed their successful use in treatment of *E.meningoseptica* due to their better pharmacokinetics as opposed to other hydrophilic antibiotic agents.^[10,14] Rifampicin was another antibiotic used by several authors for treatment of *E.meningoseptica* infection.^[6,7,10,12,14,15,17,19,23] The antibiotic has been shown to have excellent susceptibility and in

addition has been found to successfully cure persistent infection.^[10] Other antibiotics less commonly administered as definitive therapy included cefoperazone-sulbactam,^[1,12,19] meropenem,^[13,18,21] colistin,^[13,16] tigecycline,^[16,23] trimethoprim-sulfamethoxazole,^[22] chloramphenicol,^[7] linezolid,^[16] and ceftazidime.^[16] Several publications have recorded more than half of *E.meningoseptica* isolates to show a high susceptibility towards piperacillin-tazobactam, trimethoprim-sulfamethoxazole and ciprofloxacin.^[7] While several in-vitro studies have shown efficacy of administering combination therapy of vancomycin and rifampin in meningitis caused by *E.meningoseptica* in neonates; reports have also advised against combining vancomycin and meropenem as they have been found to be antagonistic to each other.^[13]

In addition to antibiotics, few authors reported using additional intensive care therapies such as supplemental oxygen and or mechanical ventilation,^[3,6,7,12,14,21] infusion of intravenous hydrocortisone,^[6,21] fluid and electrolyte replacement,^[3,6,7,14] inotropic support,^[7,12,14,16,17] albumin therapy and diuretics.^[6,14] Rakesh K et al., administered fresh frozen plasma, granulocyte colony stimulating factor and platelet transfusion to the neonate diagnosed with purpura fulminans.^[24] Infants found to have seizures were administered anti-epileptic agents including midazolam, phenobarbital and levetiracetam.^[3,14,16] Goel S et al., reported performing cranial ultrasound regularly on infants in whom ventricular dilatation was seen; and neonates with progressive increase in ventricular size were commenced on oral decompressive therapy with acetazolamide. Babies in whom the above measures failed were referred for ventriculo-peritoneal shunt insertion.^[19] Several neonates required ventriculo-peritoneal shunt insertion during the course of treatment.^[12,13,18,22,23] Overall, Patro P and associates have recommended considering infection with *E.meningoseptica* as a differential especially in neonates that have risk factors along with rapid diagnosis and appropriate and timely administration of antibiotics for longer duration of time (approximately three to four weeks) as essential elements in managing such rare infections.^[7]

Complications

E.meningoseptica has been reported to cause severe neurological morbidity among survivor infants including delayed achievement of developmental milestones, hydrocephalus, hearing impairment and brain abscess.^[15] Cranial ultrasound scan and MRI brain were done in most neonates during their NICU stay and before discharge. Most common findings reported were ventriculomegaly and hydrocephalus;^[6,7,12-16,18,20,22,23] ischemic injury and cerebral infarcts,^[11,15,16,23] and intraventricular hemorrhage.^[13,15,16]

Of the infants who survived, most of them required referral to neurosurgery division for CSF drainage and placement of ventriculo-peritoneal shunt. [6,12-14,18,20-23] Several babies were put on neuropsychiatric monitoring and early intervention programs as a follow up to assess for complications. [6,12,14,16,18,20-22]

A retrospective study by Goel S et al., observed the mortality and outcome after infection with *E.meningoseptica* in seven neonates. The overall mortality rate was estimated to be around 28.5%. The study showed that two neonates (28.5%) suffered no neurological morbidity and were developmentally appropriate for age on follow up and five neonates (71.4%) were reported to have developed a communicating hydrocephalus. Out of the five neonates who developed hydrocephalus, two patients succumbed to death, while the remaining three (60%) were found to have developmental delay. [19] Dziuban EJ et al., conducted a comprehensive review of *E.meningoseptica* cases in pediatric patients between 1944- 2017 and the study revealed that infection in neonates showed the highest mortality and morbidity with development of hydrocephalus in 30.4% of the recovered infants and hearing impairment observed in 6.5% of the cases. [3,27]

Prevention

Implementation of stringent infection control measures in the neonatal intensive care units is crucial to reduce incidence of infection with *Elizabethkingiameningoseptica*. Educating the hospital staff about the importance of hand hygiene, use of alcoholic hand rubs and strict contact precautions is an essential measure to prevent an outbreak. [10] Water sources and medical equipment have been found to be reservoirs for the organism thus many studies recommend execution of strict disinfection and sterilization policies. [6,10,19]

Conclusion

In our review, we studied 19 cases of *Elizabethkingiameningoseptica* infection occurring in the neonatal age group, which have been reported over the last five years. We recorded the risk factors, most common clinical presentations, diagnostic modalities, treatment, and prevention strategies. We

found that the organism particularly affected preterm babies and those with a low birth weight. Infection with the bacterium commonly presented as meningitis in the affected neonates with the most frequently noted signs and symptoms being fever, lethargy, apnea, seizures and poor feeding. Despite the fact that *E.meningoseptica* is a rare cause of nosocomial infection, it is imperative to address the infection caused by this pathogen due to the resultant adverse sequelae and high mortality rate. Preferred diagnostic modalities as utilized by several authors include blood and CSF cultures and broth microdilution was found to be a better method for sensitivity testing. The organism is also known to be highly resistant to most antibiotic agents posing further obstacles in its treatment. According to several studies, antibiotics such as rifampicin, vancomycin and fluoroquinolones that are targeted against gram positive pathogens can be used in the treatment of *E.meningoseptica* infection. Further research is needed for in-depth understanding of the organism's pathogenesis with incorporation of this understanding in development of more sensitive and specific diagnostic modalities accompanied by effective antibiotics may aid in early recognition and management of this condition thus, significantly reducing the mortality and morbidity. Therefore, in addition to following appropriate infection control measures, having a high index of suspicion in infants with risk factors and commencing prompt empiric therapy is the fundamental principle to management of such rare infections.

Disclaimer (Artificial intelligence)

The authors of this study hereby declare that NO generative AI technologies such as Large Language Models (ChatGPT, COPILOT, etc) and text-to-image generators have been used during writing or editing of manuscripts.

References:

1. Celik K, Terek D, Olukman O, Gulfidan G, Calkavur S, Devrim I, Arslanoglu S: Colonization and infection with a rare microorganism in a neonatal intensive care unit: three

- preterm infants with Elizabethkingiameningoseptica. Arch Argent Pediatr. 2019, 117:e631-4. [10.5546/aap.2019.eng.e631](https://doi.org/10.5546/aap.2019.eng.e631)
2. King EO: Studies on a group of previously unclassified bacteria associated with meningitis in infants. Am J Clin Pathol. 1959, 31:241-7. [10.1093/ajcp/31.3.241](https://doi.org/10.1093/ajcp/31.3.241)
 3. Hashmi AW, Ahmad M, Israr MM, Fajar IE, Adnan F: Multi-drug-resistant Elizabethkingiameningoseptica: a rare cause of late-onset sepsis in a preterm neonate. Cureus. 2023, 15:e34361. [10.7759/cureus.34361](https://doi.org/10.7759/cureus.34361)
 4. Simonsen KA, Anderson-Berry AL, Delair SF, Davies HD: 2014. Early-onset neonatal sepsis. Clin Microbiol Rev. 2014, 27:21–47. [10.1128/CMR.00031-13](https://doi.org/10.1128/CMR.00031-13)
 5. Bundy LM, Rajnik M, Noor A: Neonatal Meningitis. StatPearls, Treasure Island, FL; 2023 <https://www.ncbi.nlm.nih.gov/books/NBK532264/>
 6. Arbune M, Fotea S, Nechita A, Stefanescu V: Emerging infection with Elizabethkingiameningoseptica in neonate. a case report. J Crit Care Med (Targu Mures). 2018, 4:96-100. [10.2478/jccm-2018-0013](https://doi.org/10.2478/jccm-2018-0013)
 7. Patro P, Das P, Padhi P: Intrinsically resistant bacteria as looming disaster: a rare case report of Elizabethkingiameningoseptica meningitis in a neonate. J Lab Physicians. 2021, 13:70-3. [10.1055/s-0041-1724234](https://doi.org/10.1055/s-0041-1724234)
 8. Elhalik M, Habibullah J, El-Atawi K, Abdelsamad A: Epidemiology of sepsis in NICU; a 12 years study from Dubai, U.A.E. J Pediatr Neonatal Care. 2018, 8:84–8. [10.15406/jpnc.2018.08.00315](https://doi.org/10.15406/jpnc.2018.08.00315)
 9. Taha Z, Ali Hassan A, Wikkeling-Scott L, Papandreou D: Factors associated with preterm birth and low birth weight in Abu Dhabi, the United Arab Emirates. Int J Environ Res Public Health. 2020, 17:1382. [10.3390/ijerph17041382](https://doi.org/10.3390/ijerph17041382)
 10. Almatari K, Alhabsi R, Al-Rashdi M, Hamad Alnil Y: Elizabethkingiameningoseptica infection in neonates: two case reports from the eastern region of Oman. Oman Med J. 2022, 37:e416. [10.5001/omj.2022.21](https://doi.org/10.5001/omj.2022.21)
 11. Murthy NS, Shivappa SG, Tejashree A, Karthik KMVS, Deepashree R: Neonatal meningitis with septicemia by Elizabethkingiameningoseptica : a case report. J Lab Physicians. 2022, 14:362-4. [10.1055/s-0042-1742635](https://doi.org/10.1055/s-0042-1742635)
 12. Masrani KM, Salunke PP, Ahmed J, Kabra NS: Elizabethkingiameningoseptica-an emerging cause of neonatal meningitis. Perinatol. 2019, 19:139-42. <https://static1.squarespace.com/static/59f2d244cf81e03e96b107ea/t/5d008a19015d4500015112a3/1560316444383/Elizabethkingia+meningoseptica.pdf>
 13. Demirbakan H, Koçer İ, Sarıkabadayı YU: A case of Elizabethkingiameningoseptica in the neonatal intensive care unit. J Pediatr Emerg Intensive Care Med. 2022, 9:199-202. [10.4274/cayd.galenos.2021.80774](https://doi.org/10.4274/cayd.galenos.2021.80774)
 14. Favas K, Bindu A: Elizabethkingiameningoseptica –An emerging infection: a case report. Indian J Case Health. 2021, 8:305-7. [10.32677/ijch.v8i8.2991](https://doi.org/10.32677/ijch.v8i8.2991)

15. Barnawi AI, Kordy FN, Almuwallad OK, Kassarah KA: Early neonatal sepsis and meningitis caused by Elizabethkingiameningoseptica in Saudi Arabia. Saudi Med J. 2020, 41:753-6. [10.15537/smj.2020.7.25720](https://doi.org/10.15537/smj.2020.7.25720)
16. Malwade S, Nayak M, Gangadharan A, Agarkhedkar SR: Fulminant late-onset sepsis due to Elizabethkingiameningoseptica in term newborns. J Clin Neonatol. 2022, 11:182-6. [10.4103/jcn.jcn_8_22](https://doi.org/10.4103/jcn.jcn_8_22)
17. Govindaraju G, Rajaiah B, Ramakrishnan S: Elizabethkingiameningoseptica infection in neonates: a threat and clinical challenge. Infect Dis Trop Med. 2021, 7: e756. [10.32113/idtm_20219_756](https://doi.org/10.32113/idtm_20219_756)
18. Jain M, Jain P, AP Mehta, Sidana P: Use of intraventricular vancomycin in neonatal meningitis due to Elizabethkingillameningoseptica. Pediatr Neonatol. 2020, 5:000148. [10.23880/pnboa-16000148](https://doi.org/10.23880/pnboa-16000148)
19. Goel S, Jhajra SD, Nangia S, Kumar A, Nanda D: Neonatal meningitis secondary to Elizabethkingiameningoseptica infection. J Glob Infect Dis. 2023, 15:23-7. [10.4103/jgid.jgid_111_22](https://doi.org/10.4103/jgid.jgid_111_22)
20. Wijaya FA, Gustawan IW, Utama IMGDL, Sukmawati M, Kardana IM, Artana IWD, Putra PJ: A rare case of Elizabethkingiameningoseptica infection in a neonate. Intisari Sains Medis. 2023, 14:785-9. [10.15562/ism.v14i2.1783](https://doi.org/10.15562/ism.v14i2.1783)
21. Davis S, Biju RA, Sanal G: Elizabethkingiameningoseptica infection in a neonate: case report. Indian J Phar Pract. 2021, 14:311-3. [10.5530/ijopp.14.4.64](https://doi.org/10.5530/ijopp.14.4.64)
22. Petrovic V, Rozek-Mitrovic T: Late-onset neonatal sepsis due to Elizabethkingiameningoseptica. Prev Ped. 2023, 9:82-5. <https://prevped.preventivnapedijatrija.rs/index.php/casopis/article/view/46>
23. Joshi P, Shah B, Joshi V, Kumar A, Singhal T: Treatment of Elizabethkingiameningoseptica neonatal meningitis with combination systemic and intraventricular therapy. Indian J Pediatr. 2019, 86:379–81. [10.1007/s12098-019-02875-x](https://doi.org/10.1007/s12098-019-02875-x)
24. Rakesh K, Kartikeswar, GAP, Parikh T: Neonatal purpura fulminans by an unusual pathogen: Elizabethkingiameningoseptica. Indian Pediatr Case Rep. 2022, 2:245-8. [10.4103/ipcares.ipcares_133_22](https://doi.org/10.4103/ipcares.ipcares_133_22) <https://journals.lww.com/ipcr/pages/articleviewer.aspx?year=2022&issue=02040&article=00013&type=Fulltext>
25. Khan ID, Lall M, Sen S, Ninawe SM, Chandola P: Multiresistant Elizabethkingiameningoseptica infections in tertiary care. Med J Armed Forces India. 2015, 71:282-6. [10.1016/j.mjafi.2014.02.002](https://doi.org/10.1016/j.mjafi.2014.02.002)
26. Lin JN, Lai CH, Yang CH, Huang YH. Elizabethkingia Infections in Humans: From Genomics to Clinics. Microorganisms. 2019, 7:295. [10.3390/microorganisms7090295](https://doi.org/10.3390/microorganisms7090295)
27. Dziuban EJ, Franks JL, So M, Peacock G, Blaney DD: [Elizabethkingia in children: a comprehensive review of symptomatic cases reported from 1944 to 2017](https://doi.org/10.1093/cid/cix1052). Clin Infect Dis. 2018, 67:144-9. [10.1093/cid/cix1052](https://doi.org/10.1093/cid/cix1052)