

## Case report

# Abdominal Wall Abscess Due to Perforation of Sigmoid Colon in Presence of Diverticulosis: A Case Report with MDCT and Ultrasonography Findings

---

### ABSTRACT

**Study design:** Case Report

**Aims:** Perforated sigmoid diverticulosis with abscess formation is a serious complication of diverticular disease, creating additional diagnostic and treatment challenges. In this case report, a 40 year old male patient experienced an uncommon occurrence of sigmoid diverticulosis perforation with abscess formation. The condition is associated with significant morbidity and mortality. Patients typically present with symptoms such as acute abdominal pain, fever, and signs of localised or generalised peritonitis. Diagnosing the condition early is essential and involves using a combination of imaging methods like computed tomography (CT) scans, lab tests, and clinical examination. These assessments can help assess the extent of the perforation and identify any abscesses that may be associated with it. The recurrence of the disease often corresponds to associated complications. The primary treatment consists of antibiotic therapy, abscess drainage, and surgical procedures in severe cases. Surgical options, which depend on the patient's clinical condition and the severity of the disease, range from laparoscopic lavage and drainage to sigmoid colectomy with or without a colostomy. Prophylactic sigmoid resection is recommended as the mainstay of treatment. Additional clinical studies are necessary to improve treatment protocols and outcomes for this complex surgical procedure.

*Keywords:* Sigmoid diverticulosis, surgical emergency, perforated diverticulitis, diverticular disease

### 1. INTRODUCTION

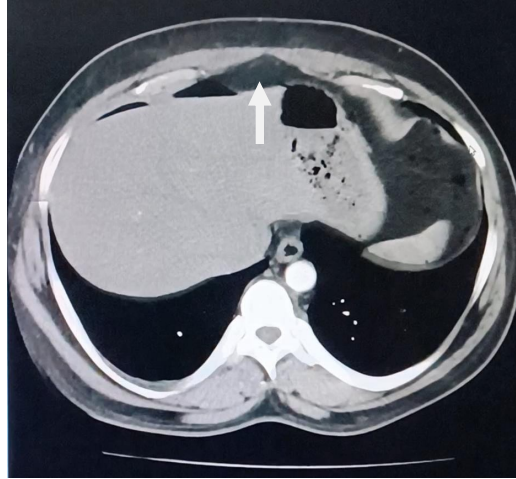
In western countries, diverticular disease is typically observed in elderly adults and primarily affects the left side of the colon [1]. Diverticular disease is believed to have a complex pathophysiology that involves environmental and genetic factors in addition to the commonly recognised aetiology that includes structural changes in the colon, abnormal motility, dietary fibre deficit, and vitamin D deficiency [1]. The risk factors for acute diverticulitis are associated with obesity, nonsteroidal anti-inflammatory drugs (NSAIDs), aspirin, and changes in lifestyle [1]. Diverticulosis is becoming more common in younger populations, according to recent studies [1]. In the young male population, obesity has also been found to

be strongly linked to diverticular complications [1]. By receiving early diagnosis and prompt medical care, uncomplicated diverticulitis can be prevented from developing into complicated diverticulitis. A peridiverticular abscess, a perforation with peritonitis, a fistulation into adjacent viscera, and luminal narrowing due to inflammation or stricture formation producing obstruction are the factors that lead to complicated diverticulitis [2]. Symptoms of diverticulitis include an acute abdomen due to perforation and peritonitis, or it might cause mild abdominal pain [1]. The clinical severity of the disease varies considerably [1]. The gold standard for diagnosing acute diverticulitis is an abdominal CT scan with oral and intravenous contrast, which has high sensitivity and specificity [1]. Because of major advancements in parenteral nutrition, antibiotic treatment, critical care medicine, interventional radiology, and CT diagnostic accuracy, the management of colonic diverticulitis has evolved in recent decades towards a more nonoperative approach [3]. The best and most recommended technique for identifying and providing interventional guidance for the drainage of abdominal and pelvic abscesses is CT-guided percutaneous drainage [3]. Also, emergency laparoscopic sigmoidectomy is a safe and practical treatment option for complicated diverticulitis patients, offering several benefits like reduced rates of conversion, reintervention, morbidity, and death, quicker recovery times, and increased rates of stoma reversal [3]. While favourable results with laparoscopic resection have been observed, general peritonitis is often regarded as a contraindication for laparoscopic surgery, particularly in cases where it is faecal [3]. Open or laparoscopic resectional treatment may be performed with or without a defunctioning loop ileostomy, depending on the patient's age, comorbidities, and clinical state, as well as the quality of colonic tissue and intraoperative findings [3].

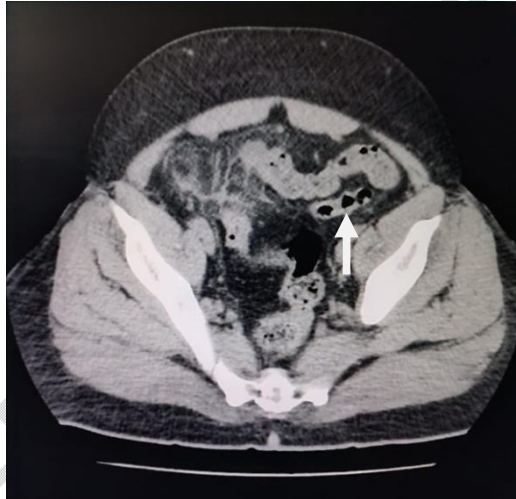
## 2. PRESENTATION OF CASE

A 40-year-old male patient presented to the emergency room with complaints of intense abdominal pain and fever. He did not have any known co-morbidities and was at higher risk due to obesity and smoking. The patient was experiencing fever, constipation, and intermittent lower abdominal pain in the right iliac fossa over the past month. During the assessment, the patient appeared conscious, coherent, and oriented to the time, place, and person on examination. The patient was found to have tachycardia, a fever of 38.3 °C (101.1 °F), and a blood pressure of 130/80 mmHg. Both oxygen saturation and respiration were found to be normal. A cardiac examination revealed regular heart sounds, while a respiratory assessment indicated a central trachea and the absence of breath sounds in the bilateral infra-axillary region. Examination of the abdomen showed tenderness and guarding in the lower right quadrant, as well as slight tenderness in the suprapubic area.

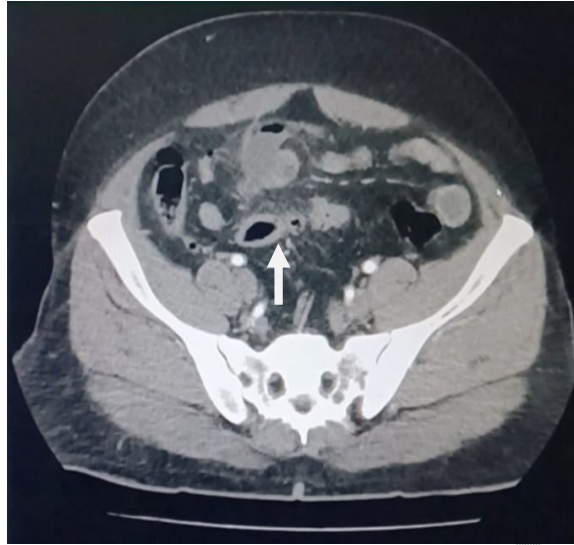Results from the laboratory investigations revealed an increase in neutrophils. Ultrasonography of the abdomen indicated the presence of a clearly defined hypoechoic area measuring approximately 15cc in the right iliac fossa region. The appendix was not visible, and a grade 1 fatty liver was observed. Multiple small diverticula in the ileal loops and sigmoid colon were discovered during an abdomen and pelvic contrast-enhanced computed tomography (CECT) scan. It also revealed a 4.8 x 3.2 cm collection of air fluid, small air pockets in the hypogastric area close to a mid-ileal loop, and surrounding mesenteric fat stranding. There was also a small umbilical hernia and a mild pneumoperitoneum in the upper abdomen. A thick collection of pus, suggestive of an abscess is seen surrounding the sigmoid colon (figure 3). Other investigations performed upon admission were reported within normal limits.



**FIGURE 1: Contrast enhanced computed tomography (CECT) of the abdomen and pelvis demonstrated pneumoperitoneum due to diverticular perforation.**



**FIGURE 2: Contrast enhanced computed tomography (CECT) of the abdomen and pelvis demonstrated multiple pouches of the diverticula.**



**FIGURE 3: Contrast enhanced computed tomography (CECT) of the abdomen and pelvis showing thick walled collection surrounding the sigmoid colon.**

Based on clinical presentation and radiological findings, the patient was preoperatively diagnosed with ileal diverticular perforation and abscess formation. The patient **was** been treated with antibiotic therapy and surgical interventions. Exploratory laparotomy with drainage of the abscess and peritoneal lavage under general anaesthesia were performed. Multiple sigmoid diverticula with a small sigmoid perforation were observed during the surgical procedure, in addition to pus in the peritoneal cavity and faecal contamination. An extensive washout was carried out, the abscess was drained, and the perforation was closed via primary closure. The process was well tolerated by the patient, and pus was collected for culture, confirming the presence of the organism *Escherichia coli*. A post-operative final diagnosis of sigmoid diverticular perforation was made. Following the surgery, the patient received intravenous fluids, antibiotics, analgesics, and appropriate wound care. Regular monitoring included a complete blood count, C-reactive protein, imaging studies, and other routine tests. On the sixth day after the surgery, the patient experienced persistent fever spikes and abdominal pain that did not improve with initial antibiotic treatment. An abdominal ultrasound revealed mild inflammatory changes at the suture site. Subsequently, a contrast-enhanced computed tomography (CECT) scan of the abdomen and pelvis indicated mild dilatation of the ileal loops and inter-bowel fluid collection in the left lower abdomen. Additionally, blood and urine cultures and wound swabs were obtained for further investigation. The patient was shifted to higher antibiotics, such as injection meropenem and injection amikacin, based on culture and sensitivity reports. The patient became afebrile on the ninth post-operative day and had a stable recovery.

### 3. DISCUSSION

Inflammation of the colonic diverticulum is known as acute diverticulitis, which can include perforation or microperforation [4]. Localised diverticular inflammation is known as uncomplicated diverticulitis, while diverticular inflammation linked to an abscess, phlegmon, fistula, obstruction, haemorrhage, or perforation is known as complicated diverticulitis [4]. Diverticulitis is said to develop in 10% to 25% of patients with diverticulosis over time, according to historical reports [5]. Diverticular disease has been thought to be primarily caused by a low-fibre diet, either exogenously or environmentally [5]. Smoking, the use of

steroids and non-steroidal anti-inflammatory drugs, and obesity are other environmental variables linked to diverticulitis [5]. In conclusion, extrinsic environmental, dietary, and constitutional/genetic variables may all have a role in the formation of diverticula [5]. The pathophysiology of diverticular disease appears to have several components and is yet to be fully understood [5]. Diverticula development is linked to chronic constipation, which can result in elevated intraluminal pressure, hypertrophy of the colonic muscles, and mucosal and submucosal herniation at the entry sites of the penetrating blood vessels [5]. While diverticulitis is thought to arise from trauma and blockage of the diverticulum, followed by ischaemia, microperforation, and infection, these theories are long-standing but not scientifically proven [6]. The most widely used imaging test, computed tomography (CT), can help determine the diagnosis, scope, and severity of the illness and, in some cases, rule out complications such as abscesses [4]. When diverticula associated with inflammatory symptoms of the colonic wall and pericolonic fat are found on CT, the diagnosis of acute diverticulitis is confirmed after other pathologic disorders are ruled out [7].

When the mucosal defence barrier is breached, the typical intestinal flora in the colon can infect the abdominal cavity, leading to intra-abdominal infections [8]. When the pericolonic tissues fail to stop the inflammatory process from spreading, abscesses develop [9]. An accumulation of these liquefied remains, enzymes, and cellular debris from either an infected or non-infectious cause is known as an abdominal abscess [8]. Primary abdominal wall abscesses are exceedingly rare; most arise as a result of malignant tumours, inflammatory diseases, and surgical site infections [10]. An abscess in the abdomen could be caused by the organisms such as candida, bacteroides, Neisseria, chlamydia, and escherichia coli [8]. In up to 10 percent of patients, peridiverticular abscesses may progress to develop fistulas between the colon and surrounding tissues [9]. Large diverticular abscesses have been observed to a greater risk of recurrence [11].

Intravenous antibiotics should be used to treat abscesses that are less than 3 cm [12]. If there is a clinical deterioration, the abscess should be evaluated again [12]. For abscesses measuring 3 cm or more, imaging-guided percutaneous drainage is advised, along with surgical consultation if necessary [12]. Surgical intervention is necessary in order to address bowel perforation [12]. While the main indication for emergency surgery is perforated diverticulitis [13], compared to open colectomy, laparoscopic surgery has a shorter length of stay, fewer complications, and reduced in-hospital mortality [1]. However, a large retrospective study found that the morbidity and mortality following emergency laparoscopic sigmoid resection for purulent peritonitis and diverticular perforation are similar to those following elective sigmoidectomy, including the rate of leakage [13]. Therefore, patients with recurrent diverticulitis should make an individual decision on whether to proceed with surgery depending on their lifestyle, comorbidities, and preferences [4]. Increased dietary fibre consumption, exercise, quitting smoking, and weight loss are among the interventions used to prevent the recurrence of diverticulitis [4].

#### 4. CONCLUSION

Perforated sigmoid diverticulosis with abscess formation represents a formidable clinical challenge requiring prompt recognition and decisive management. A multidisciplinary approach to treating the disease is crucial, as this study has demonstrated the complex nature of this ailment. In this report, we present the case of a 40-year-old male patient with sigmoid diverticulosis who presented with sudden-onset severe abdominal pain and fever. Other risk factors were ruled out, although the patient had the related risk factors of obesity, smoking, and a diet high in animal fat. It was necessary to diagnose and treat this problem as soon as possible. After a diagnosis, the course of treatment should be modified for each

patient, taking into consideration variables such as comorbidities, hemodynamic stability, the presence of an abscess, and the degree of perforation. In addition to percutaneous abscess drainage, which can relieve symptoms and promote the healing process, antibiotic medication is essential for managing infection. If there are big abscesses, severe peritonitis, or hemodynamic instability, surgery **may** be required. The patient's clinical state and the surgeon's experience should be taken into consideration while selecting a surgical technique, be it laparoscopic or open. Perforated sigmoid diverticulosis with abscess formation continues to be associated with significant morbidity and death, even with advancements in diagnostic and treatment techniques. For early diagnosis and prevention of complications, constant efforts are required to optimise surgical procedures and establish treatment plans.

### **Ethical Approval:**

As per international standards or university standards written ethical approval has been collected and preserved by the author(s).

### **Consent**

As per international standards or university standards, patient(s) written consent has been collected and preserved by the author(s).

### **Disclaimer (Artificial intelligence)**

Author(s) hereby declare that generative AI technologies such as Large Language Models, etc have been used during writing or editing of manuscripts. This explanation will include the name, version, model, and source of the generative AI technology and as well as all input prompts provided to the generative AI technology

Details of the AI usage are given below:

1. ChatGPT version 3.5 was used in editing the abstract, case description and conclusion part of paper only for better rephrasing of the paragraph. We have not used AI anywhere else.

### **REFERENCES**

1. Kamal MU, Baiomi A, Balar B. Acute diverticulitis: a rare cause of abdominal pain. *Gastroenterology Research*. 2019 Aug;12(4):203.
2. Boulos PB. Complicated diverticulosis. *Best Practice & Research Clinical Gastroenterology*. 2002 Aug 1;16(4):649-62.
3. Lambrichts DP, Birindelli A, Tonini V, Cirocchi R, Cervellera M, Lange JF, et.al. The multidisciplinary management of acute complicated diverticulitis. *Inflammatory intestinal diseases*. 2018 Feb 16;3(2):80-90.

4. Wilkins T, Embry K, George R. Diagnosis and management of acute diverticulitis. *American family physician*. 2013 May 1;87(9):612-20.
5. Hanna MH, Kaiser AM. Update on the management of sigmoid diverticulitis. *World journal of gastroenterology*. 2021 Mar 3;27(9):760.  
DOI: [10.3748/wjg.v27.i9.760](https://doi.org/10.3748/wjg.v27.i9.760)
6. Strate LL, Morris AM. Epidemiology, pathophysiology, and treatment of diverticulitis. *Gastroenterology*. 2019 Apr 1;156(5):1282-98.  
DOI: <https://doi.org/10.1053/j.gastro.2018.12.033>
7. Sessa B, Galluzzo M, Ianniello S, Pinto A, Trinci M, Miele V. Acute perforated diverticulitis: assessment with multidetector computed tomography. In *Seminars in Ultrasound, CT and MRI*. 2016 Feb 1;37(1):37-48. WB Saunders.  
DOI: <https://doi.org/10.1053/j.sult.2015.10.003>
8. Mehta NY, Lotfollahzadeh S, Copelin IE. Abdominal abscess. *StatPearls [Internet]*. 2018
9. Salzman H, Lillie D. Diverticular disease: diagnosis and treatment. *American family physician*. 2005 Oct 1;72(7):1229-34.
10. Shiihara M, Sudo Y, Matsushita N, Osugi H, Inoue T. Recurrent Primary Abdominal Wall Abscess: A Case Report and Review of the Literature. *Cureus*. 2023 Jun;15(6).  
DOI: [10.7759/cureus.41069](https://doi.org/10.7759/cureus.41069)
11. Coakley KM, Davis BR, Kasten KR. Complicated diverticular disease. *Clinics in Colon and Rectal Surgery*. 2021 Mar;34(02):096-103.  
DOI: [10.1055/s-0040-1716701](https://doi.org/10.1055/s-0040-1716701)
12. Bailey J, Dattani S, Jennings A. Diverticular disease: rapid evidence review. *American family physician*. 2022 Aug;106(2):150-6.
13. Nascimbeni R, Amato A, Cirocchi R, Serventi A, Laghi A, Bellini M, et.al. Management of perforated diverticulitis with generalized peritonitis. A multidisciplinary review and position paper. *Techniques in Coloproctology*. 2021 Feb;25:153-65.  
DOI: <https://doi.org/10.1007/s10151-020-02346-y>