

CASE REPORT

RADIOLOGICAL DIAGNOSIS OF EXTRAUTERINE GESTATION USING COMPUTED TOMOGRAPHY AND ULTRASONOGRAPHY. A CASE REPORT IN A SPECIALIST HOSPITAL **IN PORT HARCOURT**, Nigeria

ABSTRACT: Abdominal gestation is an infrequent form of ectopic gestation, noticed in 1:10,000 to 1:30,000 pregnancies and accounting for up to 1.4% of all ectopic gestations. It is classified as primary or secondary based on site of fertilization. Still, when it does occur, it goes on unnoticed until term because the pregnancy can appear normal during clinical checkup. Progressive abdominal gestation is connected with high death rate for both mother and the baby at 1-20% and 40-95% **respectively.**

Our case study is a 36-years-old woman Gravida 3 Para 2+0(1 Alive) at 16 weeks 6 days Gestation age(GA) who presented to the Radiology department for an abdominopelvic ultrasound scan investigation on account of mild-moderate abdominal pain and amenorrhea. The abdominal ultrasound shows an inactive fetus with positive spalding sign in the abdomen. The placenta is

attached to the omentum, the uterus is empty. Other abdominal organs are within normal. Biparietal diameter (BPD) measures 35.60mm with a GA of 16 weeks 6 days, a correlating NCECT scan was done.

The importance of this case report is to highlight the role of imaging in the diagnosis of abdominal pregnancy in developing countries. Ultrasound alone cannot be relied on to make the diagnosis, so other imaging modality should be employed based on the presence of fetal cardiac activity. In this case non-contrast enhanced computed tomography(NCECT) was done which cleared all the doubt. In addition to highlighting the role of imaging in diagnosis, the aim is also to report this study as it has not been reported in our environment.

Keywords: Extrauterine gestation, Ultrasonography, Computed tomography, Case report.

INTRODUCTION:

Abdominal gestation is an infrequent form of ectopic gestation, noticed in 1:10,000 to 1:30,000 pregnancies and accounting for up to 1.4% of all ectopic gestations. May be classified as primary or secondary based on site of fertilization.¹ Often missed in routine antenatal care. Still, when it does occur, it may go on unnoticed until term since the pregnancy can look normal during clinical checkup. Maternal death rate is projected between 0.5-18% while perinatal death is could be as high as 40-95%.² A lot of the cases that advances to term are typically asymptomatic and diagnosis is made after unsuccessful induction of labour or during laparotomy. For indicative abdominal

pregnancy, studies have shown that the clinical appearance hinge on the gestational age.^{2,3} Progressive abdominal pregnancy can be detected during elective caesarean section.⁴ Quite a few cases of fetal survival have been reported despite its rarity.⁵ Progressive abdominal gestation is connected with high death rate for both mother and the baby at 1-20% and 40-95% respectively. Since there are no specific clinical signs and symptoms for abdominal pregnancy henceforth making diagnosis tough.⁶ Earlier studies revealed that most third trimester pregnancies are secondary abdominal pregnancies.⁷

It is worthy of note to mention some of the short comings of the imaging modalities. Ultrasonography is highly operator dependent and also the patient habitus could be a limiting factor if obese. Computed tomography is a 3-dimensional imaging modality but uses ionizing radiation, its expensive and non-availability of this machine in most centers are the noticeable disadvantages. Magnetic resonance imaging is safe but it's very expensive and time consuming. Also, availability and affordability by patient are the pitfalls associated with this imaging modality.

This case report helps to highlight the tremendous role of minimum of two imaging modalities in the prompt diagnosis of extrauterine gestation either primary or secondary forms. Owing to its unique appearance, case reports are still imperative to improve diagnosis and management of progressive abdominal pregnancy.

AIM/OBJECTIVE: To report the rarity of this form of ectopic pregnancy in our setting as well as further contribute on the already existing knowledge of the priceless use of computed tomography and ultrasonography in confirming the diagnosis of this infrequent condition.

CASE REPORT

Our case study is a 36-years-old woman Gravida 3 Para 2+0(1 Alive) at 16 weeks 6 days Gestation age (GA) who presented to the Radiology department for an abdominopelvic ultrasound scan investigation on account of mild-moderate abdominal pain and amenorrhea. The abdominal ultrasound shows an inactive fetus with positive Spalding sign in the abdomen. The placenta is attached to the omentum, the uterus is empty. Other abdominal organs are within normal. Biparietal diameter (BPD) measures 35.60mm with a GA of 16 weeks 6 days, a correlating NCECT scan was done and the following findings was noted (seen images).

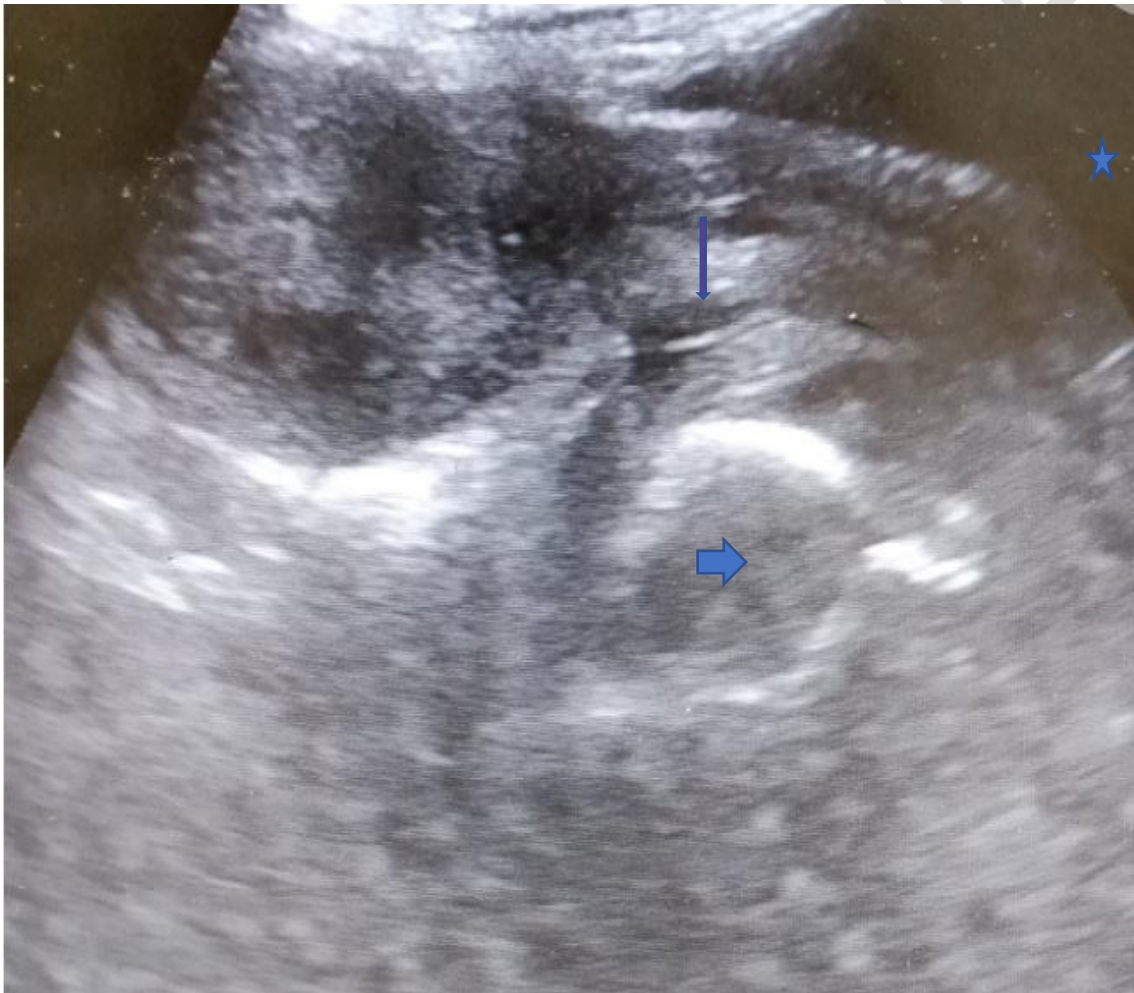


Figure 1. B-mode image of the lower abdomen/pelvic showing the urinary bladder(blue star), empty stretched anteverted uterus(slimmed purple arrow) and fetal skull with positive Spalding

sign seen(thick short blue arrow). The finding is in keeping with extrauterine gestation at about 16weeks.

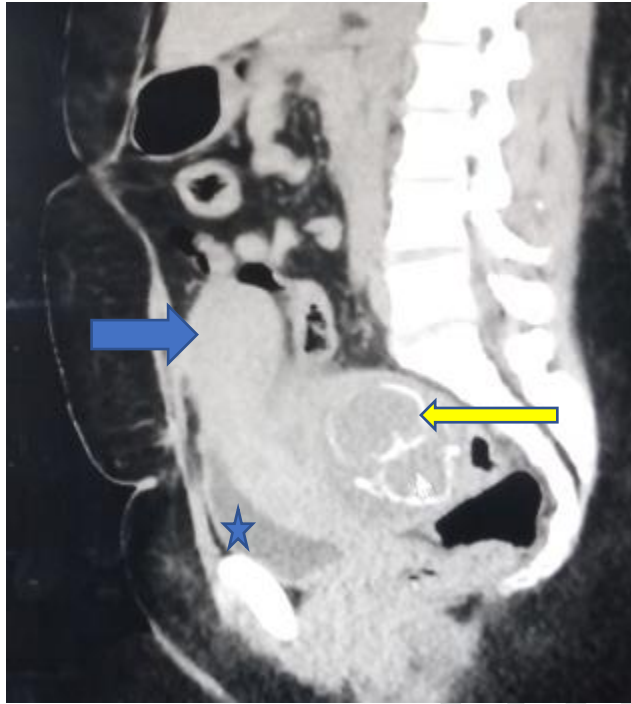


Figure 2. Sagittal reformat non contrast enhanced ct scan of the abdominopelvic region showing the empty stretched anteverted uterus(blue arrow), fetal skeleton /bony frame(slimmed long yellow arrow) and urinary bladder(blue star).

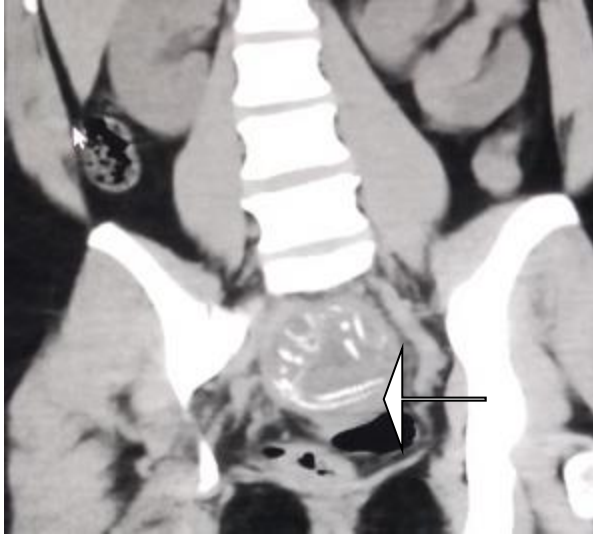


Figure 3. Coronal reformat non contrast enhanced ct scan of the abdominopelvic showing the spine of the fetus(slimmed body arrow).

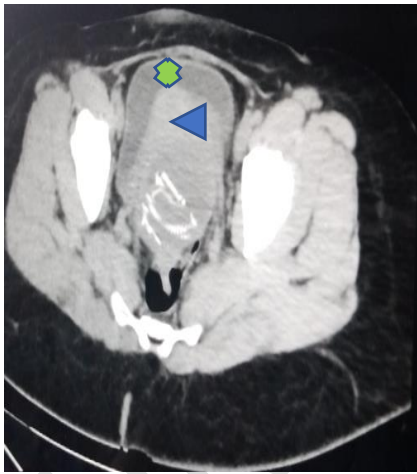

Fig. 4a. Showing the uterus (blue arrow head), urinary bladder (green x-arrow).

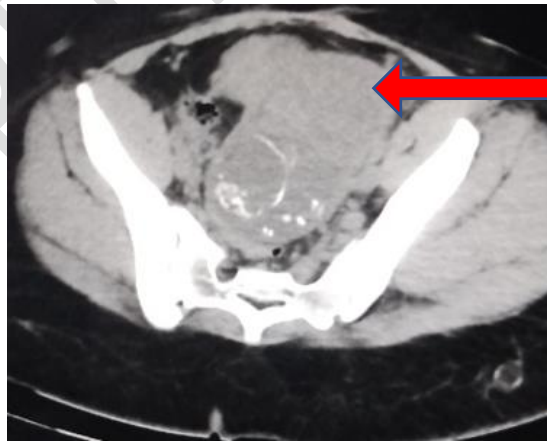


Fig. 4b Showing the placenta (long slimmed red arrow).

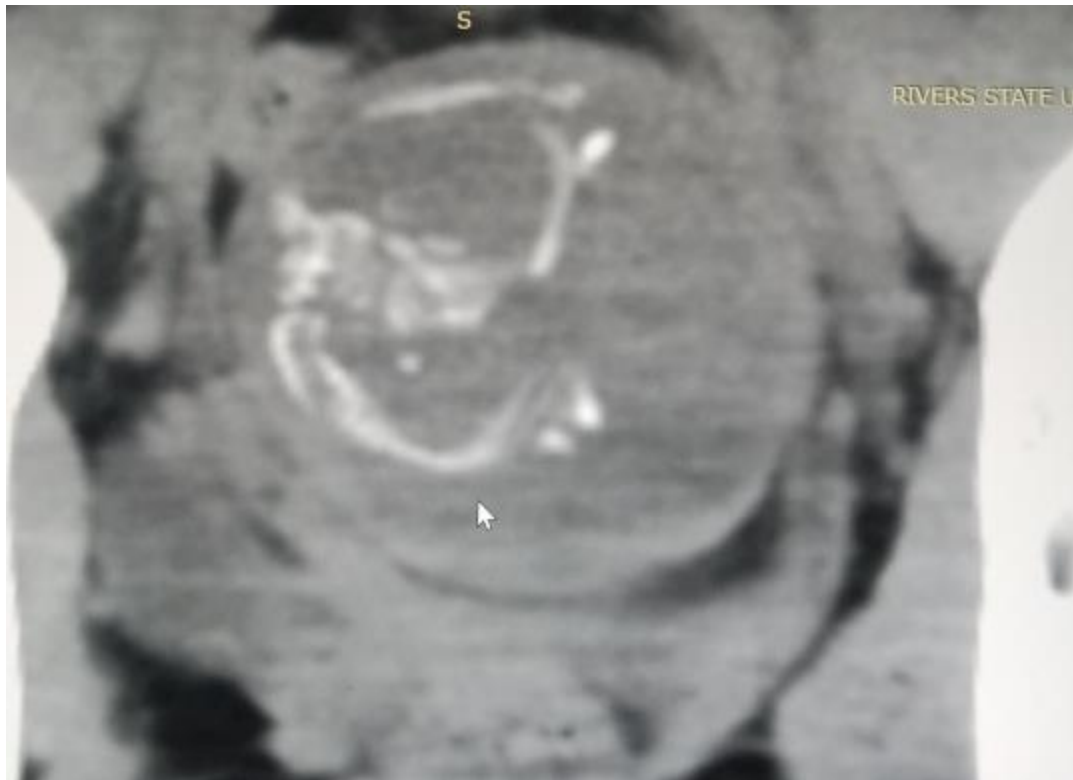

Figure 5. Close up view of the coronal reformat non contrast enhancing ct scan of the abdominopelvic region with emphasis on the fetus showing the skeletal frame.

DISCUSSION

Its worthy of note that abdominal gestation is a rare variety of extrauterine gestation. Good clinical acumen alongside imaging is required for diagnosis. In this case reports both ultrasonography and NCECT scan were employed.

A case report of abdominal pregnancy was documented by Agbon-Ojeme G et al at Igbinedion University Teaching Hospital, 19 years old female with 16 weeks GA(Para0+1), which was missed on ultrasound. Placenta was attached to the omentum. Exploratory laparotomy reviewed extrauterine fetus that was not viable. In contrast, to our case report ultrasonography picked it

up/showed it and we further correlated with NCECT scan. This difference maybe due to availability of multiple imaging modalities/seasoned Radiologist in our institution. Patient had exploratory laparotomy done which further confirmed the diagnosis of a non-viable extrauterine gestation.

Contrary to our case report, Akunaeziri et al documented a case report of a 27-years old woman, Para 2, who delivered a live fetus at 34 weeks by exploratory laparotomy after diagnosis was made via ultrasonography at presentation at 32 weeks GA. Placenta was attached to uterine fundus. This is a rare presentation of extrauterine gestation. Our case report detected the extrauterine pregnancy but there is no cardiac activity at presentation.

Surprisingly, a case of term abdominal pregnancy has been reported. Mengistu et al published a case of a 32-year-old woman, Para 2 at 40 weeks gestation with signs of increasing continuous abdominal pain of four months periods. An abdominal ultrasound was carried out, establishing the diagnosis of abdominal gestation/pregnancy. A live baby was delivered through laparotomy. However, abdominal pregnancy presents with life threatening condition as hemorrhage. This contradicts our current case report in which fetal demise had occurred at the time of examination at 16 weeks GA.

Chen Y et al reviewed 17 cases of abdominal pregnancy over a period of 32 years/ from 1989 to 2021. They found an occurrence of 0.19% of all ectopic pregnancy/gestations; the average age of women was 34 years. Twelve of the 17 cases were misdiagnosed as tubal pregnancies, bringing to light, the fact that a high index of suspicion is imperative. Our case report has proven that multiple imaging modalities can be used when in doubt, in this case the NECT scan was used since fetal activity was not detected on ultrasound.

Magnetic resonance imaging (MRI) is another imaging modality of extreme value due to its non-ionizing radiation and excellent soft tissue imaging advantage. The only pitfall is that, not all center has this imaging modality and those who have find it difficult to maintain. However, in this index case report MRI was not employed.

CONCLUSION: This case report has shown that radiological investigations are pivotal in the management of suspicious ectopic pregnancy. In which ultrasonography, computed tomography(CT) can be used to confirm the diagnosis. Also, magnetic resonance imaging (MRI) is of extreme value due to its non-ionizing radiation and excellent soft tissue imaging advantage. The only pitfall is that, not all center has this imaging modality and those who have find it difficult to maintain.

Ethical Approval:

As per international standards or university standards written ethical approval has been collected and preserved by the author(s).

Consent

As per international standards or university standards, patient(s) written consent has been collected and preserved by the author(s).

Disclaimer (Artificial intelligence)

Option 1:

Author(s) hereby declare that NO generative AI technologies such as Large Language Models (ChatGPT, COPILOT, etc) and text-to-image generators have been used during writing or editing of manuscripts.

Option 2:

Author(s) hereby declare that generative AI technologies such as Large Language Models, etc have been used during writing or editing of manuscripts. This explanation will include the name, version, model, and source of the generative AI technology and as well as all input prompts provided to the generative AI technology

Details of the AI usage are given below:

- 1.
- 2.
- 3.

REFERENCES

1. Haliu FG, Yihunie GT, Essa AA, Kindle Tsega W. Advanced abdominal pregnancy, with live fetus and severe preeclampsia, Case report. BMC Preg Childbirth. 2017;17(1):243. Pubmed | Google Scholar.
2. Cotter AM, Jacques EG, Izquierdo LA. Extended field of view sonography: a useful tool in the diagnosis and management of abdominal pregnancy. J Clin Ultrasound 2004;32(4):207-10. Pubmed | Google Scholar
3. Okafor I, Nwogu-Ikojo E, Obi S. Pregnancy after of pregnant uterus. J Obstet Gynaecol .2011;31(5):371-4. Pubmed | Google Scholar
4. Matovelo D, Ng`walida N Haemoperitoneum in advanced abdominal pregnancy with a live baby: a case report. BMC Res Notes.2014;7(1):106. Pubmed | Google Scholar

5. Meseci E, Guzel Y, Zemheri E, Eser SK, Ozkanli S, Kumru P. a 34-week ovarian pregnancy: case report and review of the literature . J Turkish german gynaecol ass. 2013;14(4):246-9. Pubmed | Google Scholar
6. Haung K, Song l, Wang BL, Gao Z, Menzg Y, Lu Y. Advanced abdominal pregnancy: an increasingly challenging clinical concerns for obstetricians. Int J Clin Experimental Pathol. 2014; 7(9):5461. Pubmed | Google Scholar.
6. Sahara Shurie, John Ogot, Philippe Poli, Edwin Were. Diagnosis of abdominal pregnancy still a challenge in low resource settings: a case report on advanced abdominal pregnancy at a tertiary facility in western Kenya. Pan African Med J; 2018;31:239. doi:10.1164/pamj.2018.31.239.17766
7. Agbon-Ojeme G, Benebo AS, Otumagie F, Sule Z, Unuigbe JA. A Review of the Changing Proportions of Unusual Ectopic Pregnancy Sites: Clinic-Pathological correlates. T J Obstet Gynaecol.2023;41(2):70-6.
8. Akunaeziri AU, Alao AI, Olatunji-Olubunmi OA, et al. Advanced abdominal pregnancy in a tertiary health centre. Trop j Obstet Gynaecol. 2021; 38(1):106-110.
9. Mengistu, Getachew A, Adefrism. Term abdominal pregnancy: a case report J Med Case Reports 2015; 9: 168-170.
10. Chen Y, Peng P, Li C, Teng L, et al Abdominal pregnancy: a case report and review of 17 cases. Arch Gynaecol Obstet. 2023;307(1):263-274.

UNDER PEER REVIEW