

Complex central odontogenic fibroma: A literature update on a clinical case

Abstract

Central odontogenic ossifying odontogenic fibroma is a low-incidence tumor produced by connective tissue surrounding the dental organs. It was first described in 1967 by the Swedish pathologist Christer Lindahl. In 2017, the World Health Organization classified it within the benign odontogenic ectomesenchymal tumors with or without inclusion of odontogenic epithelium. It has been associated with an alteration in chromosome 2, in the short arm region (2p16). The most commonly identified chromosomal abnormality is the translocation t(2;11) (q31;p13) involving chromosomes 2 and 11. A 52-year-old female patient was referred from a private consultation for presenting an asymptomatic depression in the right premaxillary region. She had no significant medical history relevant to her current condition. Physical examination revealed a melanocytic lesion on the right cheek with irregular borders and a café-au-lait color, measuring 1 cm in diameter. Intraoral examination revealed a mesial rotation of tooth 11. A cavity is observed in the mucosa of the palatal rugae in the radicular direction of tooth 12, with a bluish-white coloration, normothermic, with a depression measuring approximately 4x6x2 mm

Keywords: Central odontogenic fibroma, enucleation, Maxilla

Introduction

The central odontogenic ossifying fibroma is a low-incidence tumor produced by connective tissue surrounding the dental organs¹. It was first described in 1967 by the Swedish pathologist Christer Lindahl and later by DrPind Borg, Walldromen, and Eversole². In the literature, it can be found under the eponyms: ameloblastic fibroma and odontogenic fibroma^{3,4}.

Classification

In 2017, The World Health Organization (WHO) classified this lesion within the benign odontogenic ectomesenchymal tumors, with or without inclusion of odontogenic epithelium. It determined that the primary risk factor is the fourth decade of life, with a preference for the maxilla in the region of the incisors and first molars, in a 7:1 ratio favoring females⁵.

Clinical characteristics

It is a benign lesion located within the oral cavity, which can lead to facial asymmetry. Depending on its location, two variants can be found: the first is called peripheral or extraosseous and the second is known as central or intraosseous. The latter is more frequently found in the mandible, with a frequency of 6.5:1 compared to the maxilla. Within the oral cavity, an increase in volume can be observed in the cortical bone with changes in coloration and mobility of the affected dental organs. However, the literature review has shown clinical cases where no morphological or structural changes were present, making this lesion a radiographic finding¹.

Genes

It has been primarily associated with an alteration in chromosome 2, specifically in the short arm region of chromosome 2 (2p16). The most commonly identified chromosomal anomaly in central odontogenic fibroma is the translocation t(2;11)(q31;p13), which involves chromosome 2 and chromosome 11⁶⁻⁸.

Diagnosis

In the absence of supporting laboratory studies, the correct diagnosis is based on clinical and imaging features. Radiographic studies typically reveal a well-defined, circumscribed

radiolucent lesion with irregular borders, which can be unilocular or multilocular, surrounded by a sclerotic halo. In some cases, it may present as a mixed radiological lesion with a ground-glass appearance. It can be associated with expansion of the cortical bone and displacement or even severe resorption of the roots of adjacent teeth. Additionally, **Computed tomography(CT)** scans provide a three-dimensional projection of a well-defined, radiolucent lesion with bone expansion, with units ranging from 194 to 436 HU⁹⁻¹¹.

Differential Diagnosis

Due to its radiographic characteristics, various pathologies that share similar features should be considered, such as desmoplastic fibroma, apical granuloma, lateral periodontal cyst, follicular cyst, calcifying epithelial odontogenic tumor, fibromyxoma, fibrous dysplasia, fibrosarcoma, central giant cell granuloma, calcifying odontogenic fibroma, and ameloblastoma¹⁰⁻¹³. Lafuente BS et al. compared the clinical and radiographic features of odontogenic fibroma with those of desmoplastic fibroma, both intraosseous¹⁰.

Histopathology

Microscopically, fibrous tissue with calcified deposits of dentinoid material may be present, which is subdivided into two main variants: the simple type, which contains a sparse cellular component with dispersed collagen fibers, with or without the presence of inactive odontogenic tissue; and the complex type, which includes cellular connective tissue and mature fibroblasts, with islands and strands of odontogenic epithelium, along with the presence of calcifications of dentin material and granular cells^{5,10}.

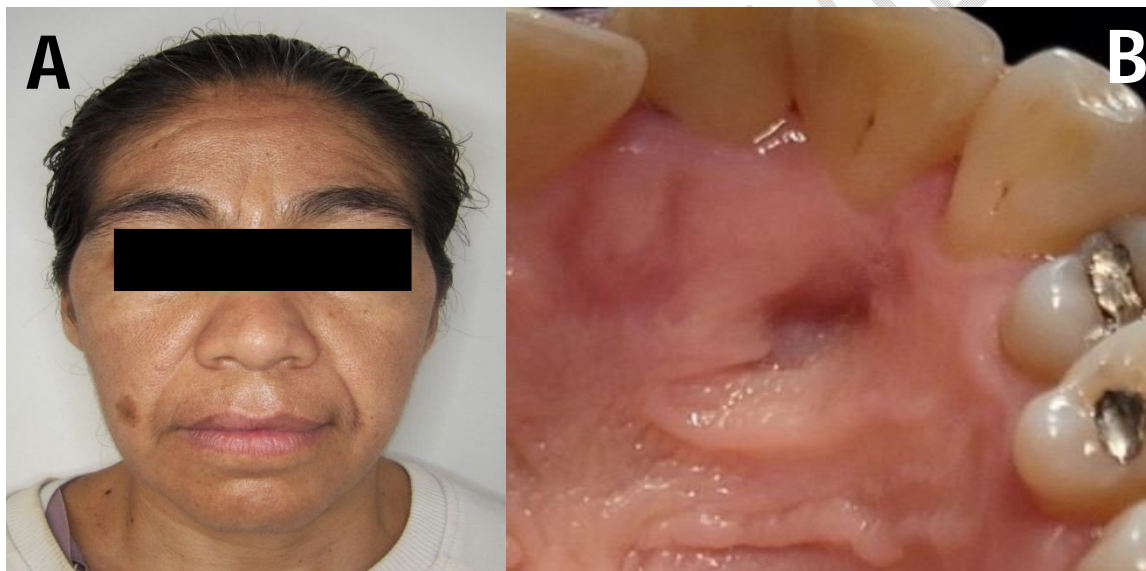Treatment

The surgeon can choose between two possible treatments. The first involves performing an enucleation and curettage of the surgical bed, while the second consists of surgical resection. The correct choice will be based on the extent of the lesion and its clinical characteristics¹.

Case presentation

A 52-year-old female patient was referred from a private consultation for presenting an asymptomatic depression in the right premaxillary region. She had no significant medical history relevant to her current condition. Physical examination revealed a melanocytic lesion on the right cheek with irregular borders and a café-au-lait color, measuring 1 cm in diameter. Intraoral examination revealed a mesial rotation of tooth 11, the presence of multiple caries, crowding in the anterior mandible, dental restorations, and a false anodontia of teeth 46, 45, and 36.

A cavity is observed in the mucosa of the palatal rugae in the radicular direction of tooth 12, with a bluish-white coloration, normothermic, with a depression measuring



approximately 4x6x2 mm (Figure 1)

Figure 1: A) a coffee-au-lait macule can be seen on the right cheek with undefined edges, with color changes. B) depression is present in the right premaxilla with red-blue color changes.

Radiographically, there is a halo that presents a radiopaque coloration in the mesial part, while the apical area distally shows a radiolucent lesion with undefined borders and progressive root destruction of dental organ 11. The CT scan reveals a cavity in the premaxillary region measuring 9.2x8.8x13.5 mm and a density of -110 to 158 HU (Figure 2). Laboratory tests were requested, obtaining the following values: hemoglobin,

hematocrit, platelets, lymphocytes, PT, and PTT. A surgical time was scheduled to remove the involved dental organ, enucleate the pathological tissue, and send it for biopsy.

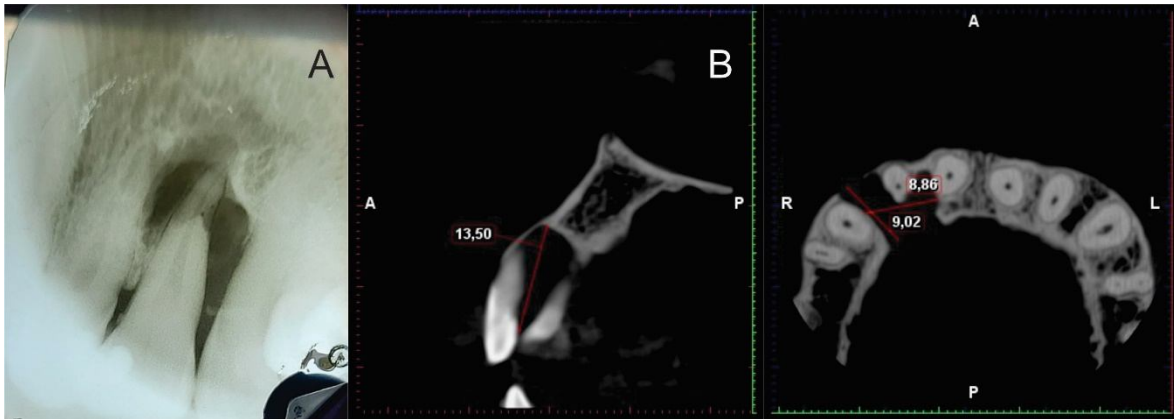


Figure 2: A) Periapical radiograph involving dental organs 11, 12 and 21. Where a radiolucent lesion with irregular edges and partial resorption of the root of the upper right central incisor is seen. B) A CT scan shows a lesion that compromises the cortical walls of the right premaxilla.

Report macroscopic examination revealing the presence of six irregularly shaped fragments, with dimensions ranging from 0.3x0.2x0.2 cm to 1x0.8x0.4 cm. They have a rough surface and a light brown color, with a soft consistency. In addition, a dental piece measuring 2.2x0.8x0.6 cm, yellow in color and hard in consistency, is received. In the root region, an area of erosion measuring 0.5 cm is observed. (Figure 3A). The histopathological results microscopic examination describes a moderately cellular fibroblastic proliferation with collagen fibers arranged compactly, with some loose areas, giving a fibrous to fibromyxoid appearance. These alternate with scattered groups of inactive odontogenic epithelial cells arranged in cords and small nests. These cells have moderate eosinophilic cytoplasm and small nuclei with smooth contours and fine granular chromatin. In some fragments, (Figure 3B), surface epithelium corresponding to stratified squamous epithelium with sequential maturation is observed, (Figure 3B) where a focal area of erosion is noted with moderate chronic inflammatory infiltrate extending into the underlying connective tissue.

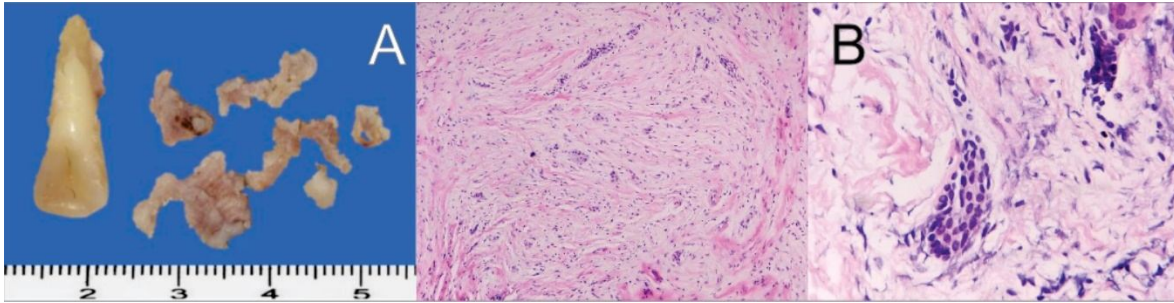


Figure 3: A) Macroscopic tissue sent for biopsy, which includes dental organ 11 and remains of the capsular tissue. B) microscopic image that describes a moderate fibroblastic proliferation with cells with collagen fibers.

Discussion

The literature review shows that central odontogenic fibroma is a rare lesion with undefined behavior. Authors such as Romero JG et al.¹ and Lafuente BS et al.¹⁰ mention the presence of expansion of the cortical bone without changes in coloration.

The treatment focused on the preservation of the adjacent structures. Considering the specific characteristics of the lesion, enucleation was performed without compromising the integrity of the dental organs and maxilla.

Rodrigues DF, et al In 2011, and Aldana H, et al.determined that central odontogenic tumor is extremely rare in the oral cavity, representing 0.1% of all odontogenic tumors. Being that currently the pathology and its behavior are not very clear and therefore it is not established whether it is a hamartoma or a neoplasia^{14,15}.

Conclusion

Central odontogenic fibroma is a low-incidence lesion that, due to its nature, may be considered a radiographic finding in the absence of signs and symptoms.

The interdisciplinary work between the various areas of dentistry allows us to provide timely treatment to patients by radiographically identifying abnormal images that compromise bone and dental structures.

Ethical Approval:

As per international standards or university standards written ethical approval has been collected and preserved by the author(s).

Consent

As per international standards or university standards, patient(s) written consent has been collected and preserved by the author(s).

Disclaimer (Artificial intelligence)

Option 1:

Author(s) hereby declare that NO generative AI technologies such as Large Language Models (ChatGPT, COPILOT, etc) and text-to-image generators have been used during writing or editing of manuscripts.

References

1. Romero JG, Téliz-Meneses MA, Reynaldos-Del Pozos JA, González-De Santiago MA, Pimentel-Madrigal EY, Aldape-Barrios BC, Ramírez TA. Central odontogenic fibroma: Report of two cases. ADM Journal. 2016;73(1):33-38.
2. Shafer WG, Levy BM. Textbook of Oral Pathology. (4th ed.). Mexico: Interamericano Publishing. 1988.
3. Linard AR, Carvalho-De Bezerra PG, Lucas NA, De Oliveira-Neto PJ, Sávio-De Souza EA. Ameloblastic Fibroma: Clinical considerations, Clinical case. Acta Odontol. Venez. 2009;47(4):256-264.

4. Calero-Escobar JA, Rodríguez-Paz ML. Odontogenic fibroma. *Gastrohnp Journal*. 2013;15(2):518-523.

5. Thompson L. World Health Organization Classification of Tumors: Pathology and Genetics of Head and Neck Tumors. *Ear, Nose, Throat Journal*. 2006, February; 85(2):74. PMID: 16579185.

6. Philip SJ, Eversole LR, Wysocki GP. *Contemporary Oral and Maxillofacial Pathology*. (2nd ed.). Spain: Elsevier. 2008.

7. Rajendran A, Sivapathasundharam B. *Shafer's Textbook of Oral Pathology*. (7th ed.). Spain: Elsevier. 2012.

8. Neville BW, Damm DD, Allen CM, Bouquot JE. *Oral and Maxillofacial Pathology*. (11th ed.). Spain: Elsevier. 2008.

9. Dellán A, Villarroel DM, Hernández AA. Application of Hounsfield units in computed tomography as a diagnostic tool for intraosseous lesions of the maxillomandibular complex: A diagnostic clinical study. *RevOdontol. Univ. Cid. Sao Paulo*. 2015;27(2):100-111.

10. Lafuente BS, Aytés BL, Escoda CG. Central odontogenic fibroma: Literature review and presentation of a new case. *Medicina Oral SL*. 1999;4(2):422-434.

11. González HJ, Moret GY. Cementifying and ossifying odontogenic fibroma associated with retained teeth: A case report. *ActaOdontol. Venez*. 2000;38(1):44-46.

12. Muñoz TC, Reyes OP, Álvarez NC, Venegas RB. Central odontogenic fibroma, WHO type: Case report and literature review. *SpanishJournal of Oral and MaxillofacialSurgery*. 2010;32(4):159-164.

13. Babkina TM, Shekera OG, Storozhchuk YO, Telukha KI, Nozhenko OA, Fesenko II, Zaritska VI, Snisarevskyi PP. Gigantic dentigerous cysts associated with the ectopic/impacted upper third molars: computed tomography analysis of nasolacrimal duct and osteomeatal complex obstructions and review of literature. *J Diagn Treat Oral MaxillofacPathol* 2020;4(5):79–94.

<https://doi.org/10.23999/j.dtomp.2020.5.1>

14. Aldana H, Orozco M, Ordoñez L, Estrada CI, Mosquera C. Trabecular juvenile ossifying fibroma management by virtual surgical planning, piezoelectric surgery, and simultaneous patient specific implant (PSI) reconstruction. *J Diagn Treat Oral MaxillofacPathol* 2020;4(2):39–48. <https://doi.org/10.23999/j.dtomp.2020.2.6>

15. Rodrigues DF, De Moraes M, Capistrano NA, Da Casta-Miguel MC, Dantas-Da Silveira EJ. Central odontogenic fibroma. *Annals of diagnosticpathology*. 2011;15(6):481-484.

UNDER PEER REVIEW