

ANESTHESIA CARE FOR A POLYTRAUMATIZED ELEVEN YEARS OLD CHILD WITH THORACO-ABDOMINAL IMPALEMENT TRAUMA

Abstract :

The present study explores anesthesia care for a polytraumatized eleven years old child with thoraco-abdominal impalement trauma. The anesthetist plays an important role in trauma management. We present the case of an 11-year-old boy who had thoraco-abdominal exploration for impalement injury. Children are at increased risk of peri-operative cardio-respiratory deterioration due to their unique physiological reserve. Post-operative care for polytrauma patient in the intensive care unit as for the index patient aimed at maintaining hemodynamic and metabolic stability via continued fluid resuscitation, and correction of metabolic derangements, mechanical ventilatory strategies and adequate monitoring. Adequate resuscitation, maintenance of hemodynamic stability, judicious selection and use of anesthetic agents and post surgical critical care play important role in ensuring the desired successful outcome.

Keywords: anesthesia, fluid resuscitation, metabolic derangements, morbidity

INTRODUCTION

Trauma is the third commonest cause of morbidity and mortality across all age groups¹. Trauma remains a source of concern globally. This is due to the associated morbidity and mortality for the victim as well as the burden placed on the already stretched resources of the healthcare system.

A coordinated multidisciplinary approach to patient management, improvements in early resuscitative care, as well as evolution of advances in anesthetic practice has ensured better outcome for trauma victims.²

The anesthetist plays an important role in trauma management. This encompasses emergency resuscitation and optimization of the patient in readiness for surgery, provision of safe anesthetic care during surgery, post operative care to ensure smooth post operative recovery, further management in the intensive care unit/high dependency unit and even in chronic pain management thereafter^{1,2}.

CASE REPORT

We present the case of an 11-year-old boy who had thoraco-abdominal exploration for impalement injury. Patient was said to have climbed up a mango tree from which he fell onto a sharp roof edge

with the wood on the rooftop piercing the upper anterior abdominal wall, the diaphragm and the left pleural cavity. There was evisceration of the bowels but no bleeding from craniofacial orifices.

At our emergency room, he had a quick primary survey and resuscitation. Examination revealed a conscious child in severe painful distress, pale, with pulse rate of 133 per minute, respiratory rate of 33 cycles per minute and SPO₂ of between 88-90%. American Society of Anesthesiologist IV_E was assigned to him by the anesthetist and his parents were counseled for surgery (left thoracotomy and laparotomy) to remove the foreign body. Written informed high-risk consent was obtained. Baseline investigations conducted and two units of blood were grouped and cross matched for the surgery.

At the theatre, baseline vital signs were; pulse rate of 133 beats per minute, respiratory rate of 40 cycles per minute, an improved SPO₂ of 95-96% following administration of supplemental oxygen and blood pressure of 120/63mmHg. Additional intravenous access was secured on both forearms. Anesthesia was induced using 60mg of ketamine; laryngoscopy was facilitated with 35mg of suxamethonium and patient had intubation with a size 6.0 cuffed endotracheal tube. He was then ventilated to normocarbia before surgery commenced.

An episode of cardiac arrest 15 minutes into the procedure necessitated temporary suspension of surgery for advanced cardiac life support. Following stabilization, he was re-positioned for the left thoracotomy and thereafter abdominal exploration and repairs.

Surgery lasted for 6 hours during which anesthesia was maintained with aliquots of intravenous ketamine and isoflurane at 0.5% dial in 100% oxygen, muscle paralysis with Pancuronium and analgesia with Tramadol and Diclofenac. Intra-operative vital signs were systolic blood pressure 120-135mmHg, diastolic blood pressure 55- 60mmHg, pulse rate of 120-130 beats per minute.

Intra-operative surgical findings were as follows: viable eviscerated bowels extruded via a jagged anterior abdominal wall with a 30 cm piece of wood penetrating through it, the stomach, left hemi-diaphragm, left hemi-thorax and left lower lung, fracture of the 1st and 2nd ribs, debris of tiny shreds of wood splinters, freshly eaten meal within the pleural and abdominal cavities, and multiple gastric perforations. Repair of the disrupted organs was done and both cavities were extensively lavaged with normal saline. A closed thoracostomy tube and abdominal drain were sited at the end of the procedure. Estimated blood loss was 1.5L and patient received two units of blood intra-operatively.

Patient was transferred to the intensive care unit for mechanical ventilation. With stable vital signs, he was extubated 24 hours later following withdrawal of sedation and assessment of readiness for weaning off mechanical ventilation and extubation. However, patient remained admitted in the intensive care unit. Abdominal drain and chest tube were removed on the 6th and 9th post operative days respectively and graded oral sips were well tolerated. He was discharged from the intensive care unit to the pediatric surgical ward on the 12th post operative day. He was managed for post

traumatic chest infection following transfer to the ward and had a good recovery. Subsequently, he was successfully discharged home on 30th post operative day.

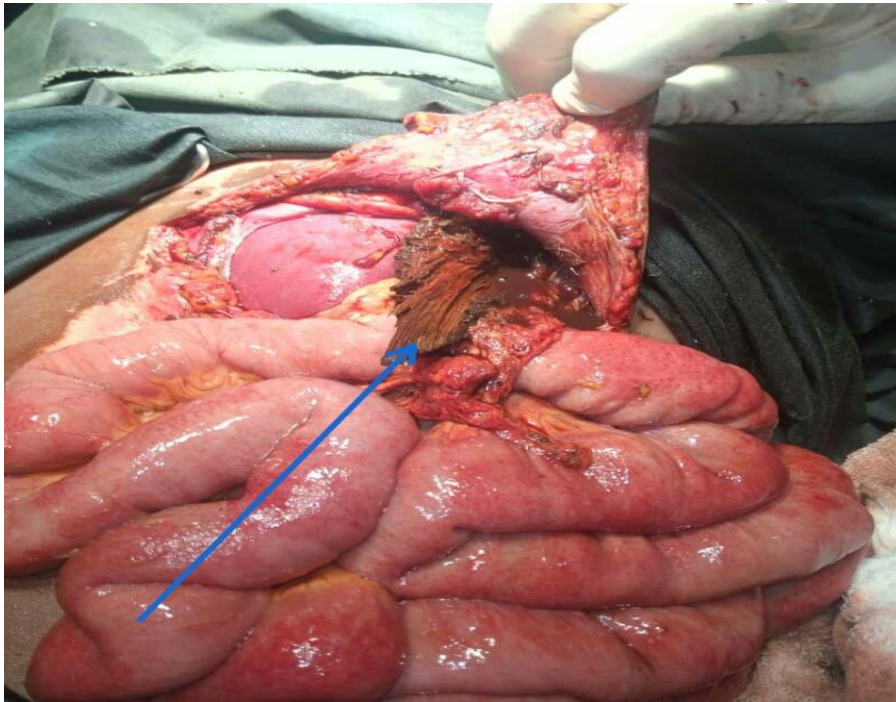


FIGURE 1: ARROW SHOWS SPLINTERS OF WOOD PROTRUDING FROM VISCERA

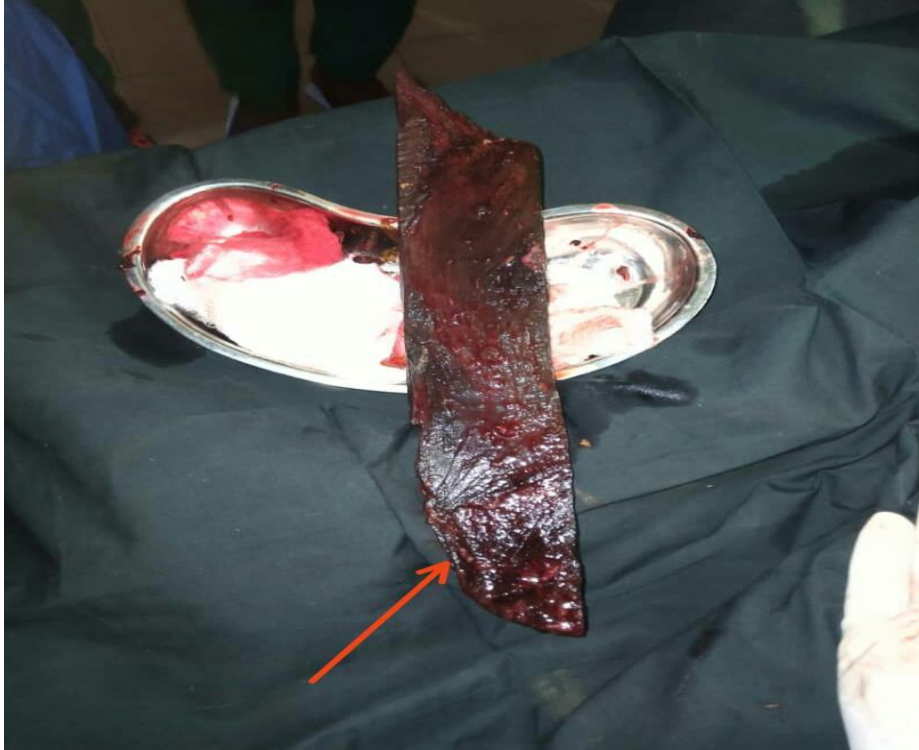

FIGURE 2: ARROW SHOWS THE PIECE OF WOOD THAT PIERCED ABDOMINAL WALL AND VISCERA

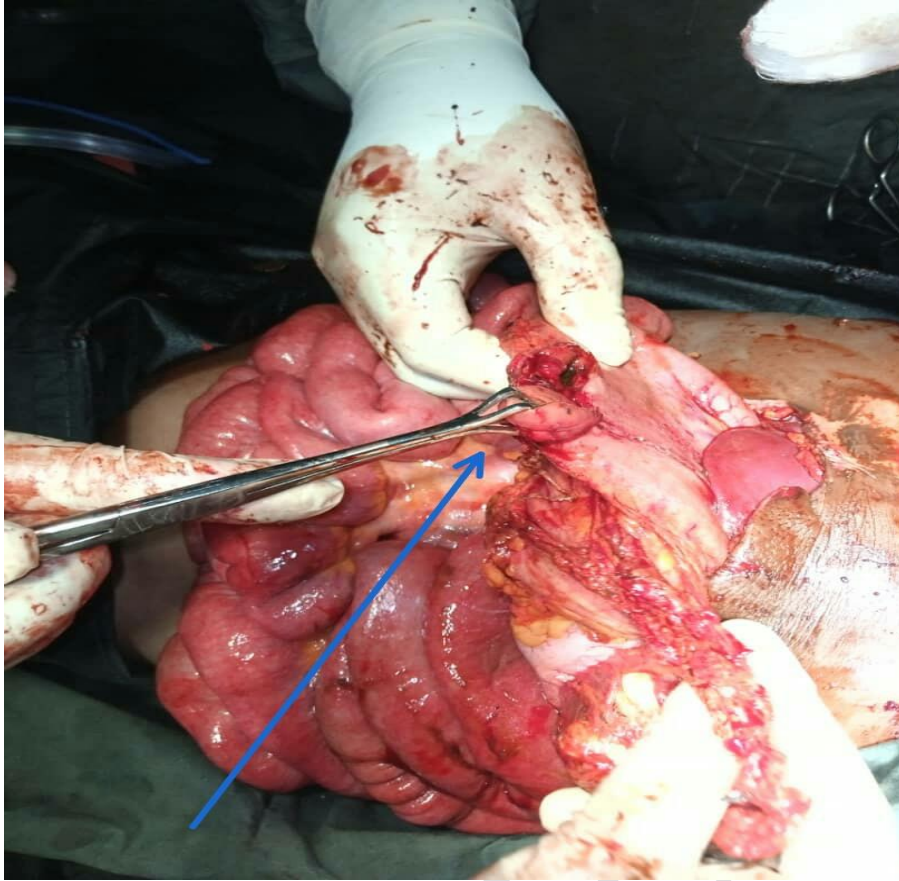


FIGURE 3: ARROW SHOWS A SECTION OF VISCERA REPAIR DURING SURGERY

DISCUSSION

Children are at increased risk of peri-operative cardio-respiratory deterioration due to their unique physiological reserve³. This vulnerability could be exaggerated during anesthesia, thus vigilance of the anesthetist can never be overemphasized^{3,4}. Anesthesia management for polytrauma pediatric patients requires careful planning, preparation, vigilance and prompt intervention in the event of an untoward incidence³⁻⁵. The induction agent of choice in trauma patients is largely dependent on the hemodynamic stability of the patient⁶. Ketamine is preferred in hemodynamically unstable patients. This is due to its inherent hemodynamic, analgesic and sedative properties thus minimizing the need for anesthetic poly pharmacy^{7,8}. Other intravenous agents that may be used include etomidate propofol, and adjuncts such as midazolam, depending on patient's hemodynamic state. The use of ketamine in the index patient was predicated on the patient's unstable hemodynamic state, thus ensuring that there was no further depression of the already compromised cardiovascular system of the patient and minimizing the need for anesthetic poly pharmacy. Also, administration of aliquots of ketamine at intervals for maintenance of anesthesia and analgesia further helped maintain sympathetic tone and blood supply to organs.

Furthermore, pre warming of the operating room as well as the use of warm intravenous and irrigation fluids is important in aiding thermoregulation by minimizing hypothermia⁹. For patients with thoracic and abdominal cavities exposed to operating room temperature as in the index case, impaired core thermoregulation may arise with undesirable sequelae, both intra-operatively and post-operatively, such as prolonged drug metabolism and delayed emergence from anesthesia. Therefore use of pre warmed fluids for the index patient was ensured throughout the duration of the surgery as well as a warm ambient operating room.^{9,10}

Patient monitoring during surgery and vigilance to changes in vital signs, including urine output, are integral components of intra-operative anesthesia care; more so in the index patients, whose polytraumatized state can predispose him to fluctuations in hemodynamic state. Assessment of procedural blood loss, compatible blood transfusion and judicious fluid therapy as done for the index patient are very vital components of peri-operative fluid management.

Post operative care for polytrauma patient in the intensive care unit as for the index patient aimed at maintaining hemodynamic and metabolic stability via continued fluid resuscitation, and correction of metabolic derangements, mechanical ventilatory strategies and adequate monitoring^{2, 11}. Furthermore, other post operative strategies such as maintaining normal glycemic state via glucose containing fluids, early enteral nutrition and blood glucose level monitoring, avoidance of hypothermia via continued use of warm blankets, warm fluids and fluid warmer, ensuring normoxemia, normocarbia via supplemental oxygen, and normal blood pressure for age, adequate analgesia, use of antibiotics to mitigate surgical site infection and sepsis as well as plans and strategies to wean patient off ventilatory support early were done to ensure successful outcome².

CONCLUSION

Anesthetic care for polytraumatized patient presents a daunting challenge. Adequate resuscitation, maintenance of hemodynamic stability, judicious selection and use of anesthetic agents and post surgical critical care play important role in ensuring the desired successful outcome.

REFERENCES

1. Aboseif E.M. Role of anaesthesiologists in the management of trauma patients: Updates. *Ain Shams J Anaesthesiol.* 2016;9:153–158.
2. Dattatri R, Jain VK, Iyengar KP, Vaishya R, Garg R. Anaesthetic considerations in polytrauma patients. *J Clin Orthop Trauma.* 2021;12(1):50-57.
3. Saikia D, Mahanta B. Cardiovascular and respiratory physiology in children. *Indian J Anaesth.* 2019;63(9):690-697

4. Bhananker SM, Ramamoorthy C, Geiduschek JM. Anesthesia-related cardiac arrest in children: Update from the pediatric perioperative cardiac arrest registry. *Anesth Analg.* 2007;105:344–50.
5. Tay CL, Tan GM, Ng SB. Critical incidents in paediatric anaesthesia: An audit of 10000 anaesthetics in Singapore. *Paediatr Anaesth.* 2001;11:711–8
6. Sikorski, R.A., Koerner, A.K., Fouche-Weber, L.Y. et al. Choice of General Anesthetics for Trauma Patients. *Curr Anesthesiol.* 2014; 225–232 ()
7. Morgan MM, Perina DG, Acquisto NM, Fallat ME, Gallagher JM, Brown KM, Ho J, Burnett A, Laird J, Rowe D, Gestring ML. Ketamine Use in Prehospital and Hospital Treatment of the Acute Trauma Patient: A Joint Position Statement. *Prehosp Emerg Care.* 2021;25(4):588-59
8. Karlow N, Schlaepfer CH, Stoll CRT, Doering M, Carpenter CR, Colditz GA, Motov S, Miller J, Schwarz ES. A Systematic Review and Meta-analysis of Ketamine as an Alternative to Opioids for Acute Pain in the Emergency Department. *Acad Emerg Med.* 2018;25(10):1086-1097
9. Campbell G, Alderson P, Smith AF, Warrtig S. Warming of intravenous and irrigation fluids for preventing inadvertent perioperative hypothermia. *Cochrane Database Syst Rev.* 2015(4). doi:10.1002/14651858.CD009891.pub2
10. Oshvandi K, Shiri FH, Fazel MR, Safari M, Ravari A. The effect of pre-warmed intravenous fluids on prevention of intraoperative hypothermia in cesarean section. *Iran J Nurs Midwifery Res.* 2014;19(1):64-69.
11. Serpa Neto A., Cardoso S.O., Manetta J.A. Association between use of lung-protective ventilation with lower tidal volumes and clinical outcomes among patients without acute respiratory distress syndrome: a meta-analysis. *J Am Med Assoc.* 2012;308(16):1651–1659