

Case report

Presentation and management outcome of anterior fontanelle Dermoid cyst: review of 6 cases

Abstract

Aim

The aim of study is highlight the presentation of anterior fontanelle Dermoid cyst which is relatively uncommon condition, and our ability to excised the cysts in our resource poor environment.

Presentation of cases

A retrospective study of all the consecutive patients managed by pediatric surgery unit over 6 years was done and the results was analysed and documented.

A total of 6 patients was managed over a period of 5years including 4 boys and 2 girls. The age ranges between 6month to 5year. (five years)

Discussion

Dermoid cysts are inclusion cyst mostly seen in the midline.^{1,2} They occur in head and neck or the trunk. It is a benign, slowly growing lesion, dermoid cysts are thought to arise during the third and fifth week of embryogenesis from displacement of germ cells during the formation of the neural tube.

All of the patients had excision under general anesthesia. The intra operative finding is a global, cystic swelling containing amber to yellow color jelly fluid.

All the patients were operated as day case surgery and were discharged home about 4 to 6hours after recovery from anesthesia. All the patients did well postoperatively, only 1patient had surgical site infection which was treated with antibiotics and wound dressing.(one patient ,six hours)

Conclusion

Dermoid cyst is an uncommon congenital cyst mostly diagnosed during infancy, following excision recurrence is uncommon

UNDER PEER REVIEW

INTRODUCTION

Dermoid cysts are inclusion cyst mostly seen in the midline.^{1,2} They occur in head and neck or the trunk. It is a benign, slowly growing lesion, dermoid cysts are thought to arise during the third and fifth week of embryogenesis from displacement of germ cells during the formation of the neural tube, the cyst is thought to be formed from defects in the separation of neuroectoderm, resulting in sequestration of ectodermal remnants.^{3,4}

The incidence rates of scalp dermoid cysts range from 15 to 22% c.^{5,6} scalp dermoid involving the anterior fontanelle is rare.⁷ It is a congenital lesion hence mostly present at birth or notice few month after birth, with a swelling that is slowly increasing in size.^{8,9}

CASES PRESENTATION

Between January 2017 to December 2021 six (6) **schildren (children)** were managed by pediatric surgery unit, comprises **4boys** and 2 girls (fig. 1). The age ranges between **6mont** to 5years. The commonest complain at presentation is scalp swelling which is painless slowly increasing in size (FIG 2). Only one patient has fever at presentation which was treated with anti-malarial and paracetamol before the surgery, **2patients** also had anemia with packed cell volume of less than 30% and were optimized with hematinic before the surgery.

All of the patients had excision under general anesthesia. The intra operative finding is a global, cystic swelling containing amber to yellow color jelly fluid (FIG 3B). All the patients were operated as day case surgery and were discharged home about **4 to 6hours** after recovery from anesthesia. All the patients did well postoperatively, only **1patient** had surgical site infection which was treated with antibiotics and wound dressing. None of the patients had recurrence throughout the follow up period, though the last patient was followed up for only 6month before the end of the study period.

Discussion

Dermoid cyst are subcutaneous sacs lined with a stratified squamous epithelium consists of semi-solid inspissated yellow material. ^{4(?)}The contents of the cyst are commonly hair and hair follicle, sebaceous glands, rarely presence of sweat gland is also reported in the literature. ⁵ (?)This is confirmed histologically in most of our pathologic samples. (are these sample of refrence)

The common symptoms at presentation in our patients is painless scalp swelling around the anterior fontanelle which is slowly increasing in size, this is similar to most of documented findings in other studies worldwide. ⁷ usually there are no constitutional symptoms except infected or in the present of trauma which is consistent with the features we found among our patients only 1patient had fever. ^{8,9} They are usually round cystic masses that are non-tender, the affected children are otherwise healthy.

The diagnosis is usually clinical from history and examination, however some investigations may be done to confirm the presence of a cystic mass at the anterior fontanelle or presence of intracranial extension of the cyst, these includes high resolution ultrasound, scalp computer tomography (CT) or scalp Magnetic resonance imaging (MRI). ^{8,9,10}

All of our patients had subcutaneous ultrasound studies which showed a cystic swelling around the anterior fontanelle.

The most widely used method of treatment is surgical excision, and recurrence after excision is said to be very low. All of the patients in our study had surgical excision under general anesthesia and none of them had recurrence due period of the follow up. ^{10, 11}

Conclusion

Dermoid cyst is a congenital cyst mostly diagnosed during infancy, following excision recurrence is uncommon

References

1. Asra Tanwir, Noor Malik, Gohar Javed, Romana Idrees. Dermoid cyst with no intracranial extension: A case report and literature review. 28-Feb-2019;10:25.
2. Peter JC, Sinclair-Smith C, de-Villiers JC Midline dermal sinuses and cysts and their relationship to the central nervous system. *Eur J PediatrSurg* 1991;1:73-9
3. Agrawal A, Santhi V, Reddy V. Subgaleal dermoid cyst of the anterior fontanelle in a child. *Egypt J RadiolNucl Med.* 2015. 46: 1171-4
4. Iwamuro Y, Shirahata M, Jito J, Tokime T, Hosotani K, Tokuriku Y. A case report of a scalp dermoid cyst containing watery-clear fluid. *No ShinkeiGeka.* 2002. 30: 211-4.
5. Peter JC, Sinclair-Smith C, de-Villiers JC Midline dermal sinuses and cysts and their relationship to the central nervous system. *Eur J PediatrSurg* 1991;1:73-9
6. Tan EC, Takagi T. Congenital inclusion cysts over the anterior fontanelle in Japanese children. A study of five cases. *Childs NervSyst* 1993;9:81-3.
7. Makhija D, Sisodiya N, Shah H, Waghmare M. Cystic congenital scalp inclusion dermoid: A case report. *Dev Period Med.* 2016. 20: 287-8
8. Kumar S, Singh M, Agarwal P. Giant congenital dermoid cyst of scalp. *J Cran Max Dis.* 2014. 3: 147-9.
9. Udina C, Calligaris L, Berti I, Cattaruzzi E, Barbi E. Inclusion cyst of anterior fontanelle. *Arch Dis Child.* 2020;105:95
10. de Aquino HB, de Miranda CC, de Britto Filho CA, Carelli EF, Borges G. Congenital dermoid inclusion cyst over the anterior fontanel: report of three cases. *ArqNeuropsiquiatr.* 2003;61:448–452
11. Ramnarayan R, Mariappan M. Dermoid Cysts of the Anterior Fontanel in Adults. *J Neurosci Rural Pract.* 2018; 9: 448–449.

FIGURES

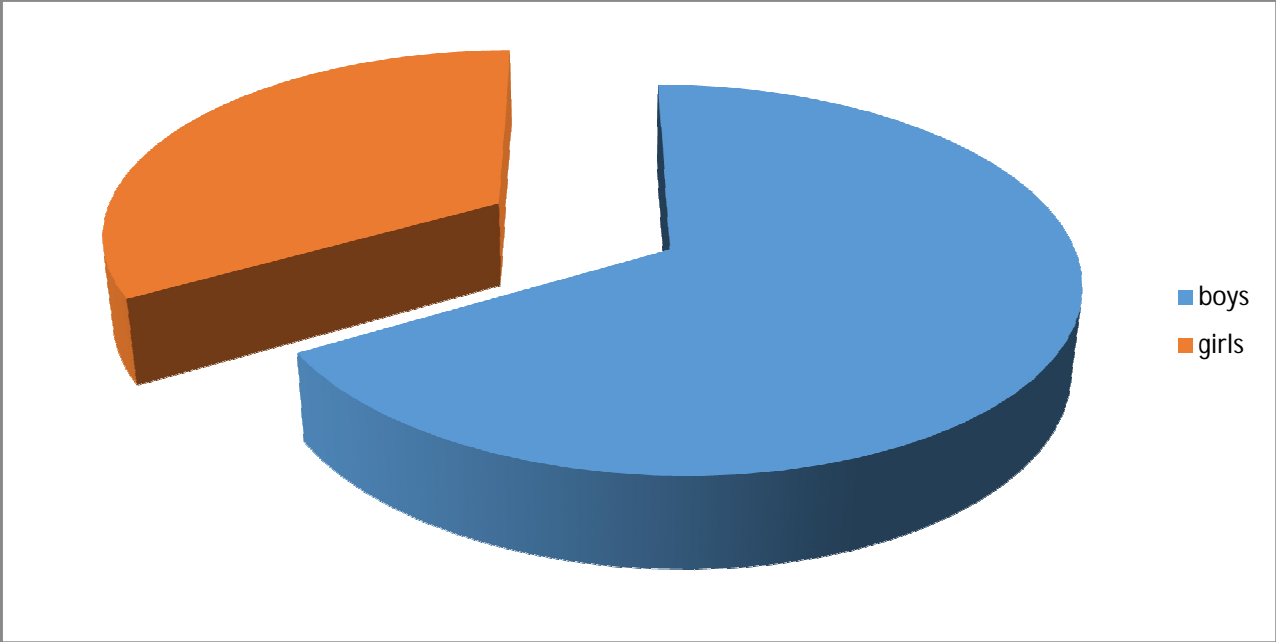


FIG. 1 pie chart showing sex distribution

UNDER PEER REVIEW

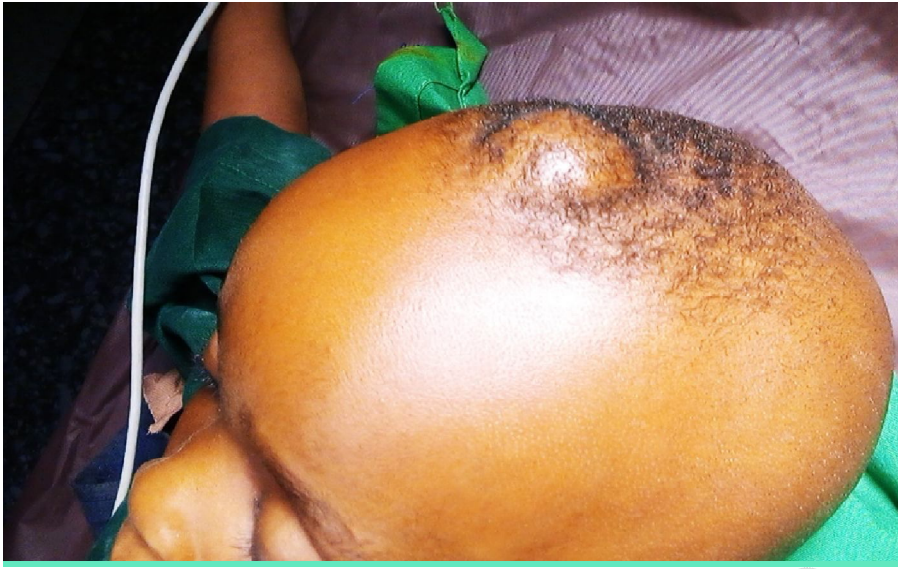

FIG. 2. Pre- operative picture

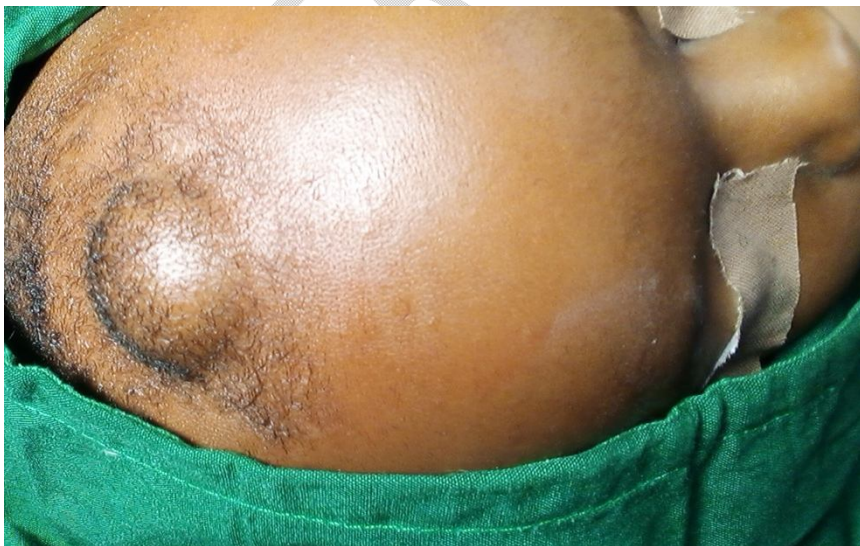

FIG. 3 A. intra – operative picture (before incision)

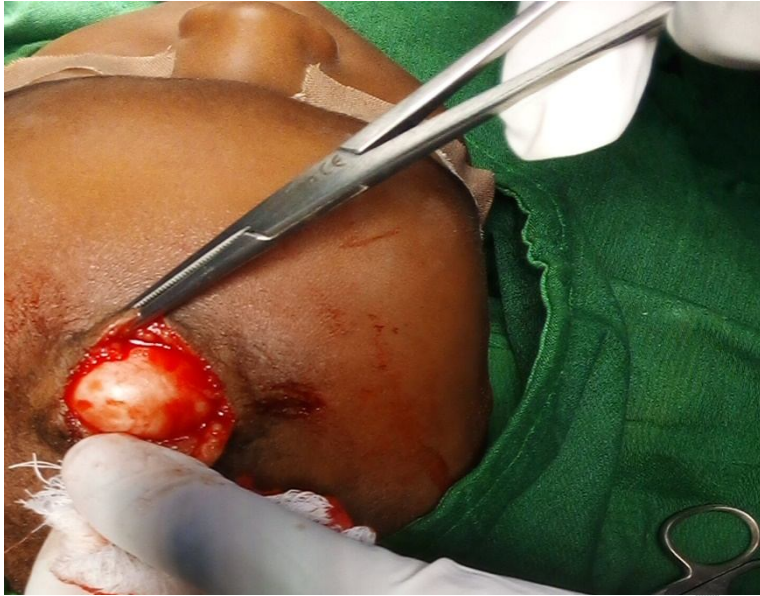

Fig.3B. intra – operative picture

UNDER PEER REVIEW