

## Salmonella Paratyphoid Induced Hemophagocytic Lymphohistiocytosis, its Presentation, Treatment and it'sLiterature Review.

### **ABSTRACT:**

**Background:**Haemophagocytic lymphohistiocytosis (HLH) is a rare and life-threatening syndrome characterized by an excessive inflammatory response. Limited data exist on adult HLH.

**Introduction:** Hemophagocytic lymphohistiocytosis (HLH) is a condition in which immune hyperactivation and deregulation causes hemophagocytosis and organ disorder due to activated histiocytes and macrophages. Symptoms include fever, splenomegaly, abdominal distension and hepatomegaly.

**Methodology and our case report:**We report the case of a forty year old man who presented to our Hospital with fever and loose stools and upon investigation had a pancytopenia with hypertriglyceridemia, hepatosplenomegaly, these clinical and laboratory findings raised suspicion of HLH secondary to typhoid fever. The patient was treated with immunosuppression (dexamethasone) and antibiotics and showed remarkable recovery. Hemophagocytic lymphohistiocytosis should be suspected in patients with tropical infections like enteric fever, tuberculosis, malaria, dengue, etc. that worsen despite appropriate treatment, as late diagnosis is associated with greater mortality. In this national, retrospective cohort study, we analysed data from the Pub Med database collected between October 1, 2006 and December 31, 2023 in making of this literature review.

**Results and conclusion:** Typhoid fever caused by the bacterium salmonella typhi and paratyphi is a serious febrile illness and is more common in the developing countries As a first line intervention, treating the etiology of HLH would be an efficient way to restrict the disease's progression. We report a rare and unique case of secondary HLH due to typhoid fever, this complication is often missed and a prompt diagnosis is essential for the treatment of this fatal disease.It can be primary (familial) or secondary (acquired).Clinically diagnoses can be difficult because of similarities in signs and symptoms with other illnesses as it generally presents with fever, loose stools, and decreased appetite and on Investigation one can expect pan or bi cytopenias, hepatosplenomegaly, hypertriglyceridemia, hypofibrinogenemia. Timely diagnosis of HLH makes it very treatable in majority of cases.

**KEY WORDS:**Typhoid fever, HLH, Hemophagocytic lymphohistiocytosis, secondary HLH, Salmonella typhi.

### **Introduction:**

Typhoid fever is a life-threatening infection caused by the bacterium Salmonella enterica serotype typhi (Salmonella Typhi)<sup>1</sup>. It is an invasive bacterial disease, which mainly affects children, has a feco-oral transmission and is associated with bloodstream infection which causes a high burden of disease in Africa and Asia (James E. Meiring, 2023) because of poor sanitation and unavailability of clean drinking water in these countries. Symptoms include prolonged fever, fatigue, headache, nausea, abdominal pain, and diarrhea<sup>2</sup>. It is mainly treated with antibiotics but resistance is common.Hemophagocytic lymphohistiocytosis (HLH) can occur secondary to infection with salmonella typhi<sup>3</sup>.

HLH is a rare condition in which the immune system abnormally overreacts and attacks the body characterized by many hematologic changes and organ disorders<sup>4</sup>. It can be primary (familial) or secondary (acquired). Familial HLH is caused by genetic mutations inherited in a homozygous or compound heterozygous pattern, resulting in disruptive mutations that fully eliminate the function of cytotoxic T cells and NK cells (Hanny Al-Samkari 1, 2017)<sup>5</sup>. Some of the genetic mutations causing HLH have been identified such as PRF1 (perforin gene mutation), CD27, STX11 (syntaxin), STXB2 but the frequency of these mutations varies with different ethnicities. Secondary HLH on the other hand is an acquired condition which one develops after an abnormal immune response it can be caused by Epstein-Bar virus (EBV), bacterial, viral or fungal infections, in autoimmune conditions, rheumatologic diseases and malignancies (non-Hodgkin's lymphoma)<sup>6</sup>.

Clinical presentation is generally a febrile illness associated with multiple organs involvement "i.e.," fever, rash (erythroderma), hepatosplenomegaly, lymphadenopathy, edema, bleeding manifestations, icterus, liver dysfunction and neurological symptoms such as seizures, altered mentation, ataxia and posterior reversible encephalopathy syndrome (PRES) like picture especially in case of FHLH (Siddaiahgari, 2016)<sup>7</sup>.

Investigations done are include a complete blood count to check for bi\pan cytopenias, Liver function and coagulation profile, important biochemistry markers for HLH are ferritin, fibrinogen, triglycerides, bone marrow examination for hemophagocytosis, genetic and HLA testing in cases of a positive family history. The HLH 2004 criteria (and the more recent Modified HLH 2009 criteria) can be used to arrive at a diagnosis and start early treatment<sup>8</sup>.

Treatment is directed at reducing Inflammation and immunosuppression Dexamethasone alone controls the disease significantly in many secondary HLH. Broad-spectrum antibiotics as per culture report and clinical need are to be administered either orally or parentally based on severity of the infection (Kodan, Chakrapani, Shetty, Pavan, & Bhat, 2014)<sup>9</sup>. cyclosporine A, methotrexate and prednisolone may also be used but treatment may vary depending on the cause, age group, severity of symptoms<sup>10</sup>

### **Case presentation:**

A 40 years old , male who is a resident of Islamabad Pakistan and a project manager by profession with no food and drug allergy and no known Co-morbidities was in a usual state of health eighteen days back when he suddenly developed fever demonstrated to be 39C/102F , intermittent in nature and relived by taking Paracetamol and brufen, it was associated with rigor and chills and settled after 5 days the fever then recurred one week back sudden in onset, intermittent in nature, with rigor and chills. The patient also had loose stools 10 days back up to three episodes per day with no blood and mucous, associated with nausea and vomiting; they were aggravated with taking meals and no specific reliving factors. The patient also complains of a dry cough for the past 10 days and decreased oral intake.

Past medical history was not significant; he had no significant drug history except for the paracetamol and brufen he was taking for the fever, no positive family history for hypertension, diabetes malignancies or a recent TB or other infection. He is a non-smoker non-alcoholic with no other addiction.

On a systemic review his CNS, CVS, genitourinary, locomotor and endocrine systems were intact with no significant positive findings. He only had loose stools on GIT inquiry a dry cough on respiratory inquiry.

All his baselines were normal with a pulse of 80 beats\min, temperature 37C, and blood pressure of 100\60mmHg, respiratory rate of 20\min, weight 75Kgs, and oxygen saturation of 96%.

On general physical examination patient is conscious and well oriented, pale looking lying comfortably on his bed. No noted clubbing, koilonychias, bucharad or heberden nodes, osslers nodes.Cappillary refill was slow of about 4secs.There was no palmer erythema,dupytren contracture.No radio-radial delay or water hammer pulse was noted. No palpable axillary or cervical lymph nodes. Face was normal with no ptosis, swelling. Conjunctiva was pale, no jaundice noticed on sclera. Patient had a good oral hygiene.All of the systemic examination was performed which was normal with no significant positive findings.

### Investigations:

A complete blood count was done which showed a reduced white blood cell count of 1670\UL, red blood cell count 3.52m\UL and platelets of 73000\UL which indicates a pancytopenia. His hemoglobin was also reduced: 10.7g\dl (table 1).

Dengue, malaria which are endemic in the country were ruled out.Hepititis A,E and C were also ruled out.HIV AG\AB combo was also non-reactive.(table 2)

In suspicion of secondary HLH due to salmonella paratyphi a fibrinogen and triglyceride test was also performed which showed a normal fibrinogen count of (323.90) and a slightly raised triglyceride of 195mg\dl(table 3). Patient's serum LDH was markedly raised: 756U\L (table 3)

A urine routine examination was also performed which showed blood and proteins to be positive (+++).ketone (+) and urobilinogen (++). (Table 4).

**Table 1: The base line investigations:**

Complete blood count 23-OCT-23		
Category	Result	Reference ranges
WBC Total	1,670	(4000/UL -11000/UL)
RBC, Total	3.52	M(4.5 - 6.5)m/UL F(3.8 - 5.8)m/UL
Hemoglobin	10.7	M(13.0-18.0)g/dL F(11.6-16.5)g/dL
HCT	29.6	M(40 - 54)% F(38 - 47)%
MCV	84.1	(80 - 90)FL
MCH	30.4	(27 - 32)pg.
MCHC	36.1	(33 - 38)g/dL
Platelet Count	73,000	(150,000-400,000)/UL
Neutrophils	72	(40 - 75)%
Lymphocytes	20	(20 - 45)%
Monocytes	8	(2 - 10)%
Eosinophils		
Basophils		
RDW	11.9	11.5-13.6

**Table 2: The virology profile:**

category	result	reference
HIV Ag / Abs Combo	Non-Reactive	Non-Reactive 0.90 S/Co Borderline 0.90-0.99 S/Co Reactive $\geq 1.0$ S/Co
Hep. E Antibody IgM	Non-Reactive	Non-Reactive
Hepatitis A Ab IgM	Non-Reactive	Reactive $\geq 1.0$ S/Co
Coomb's Test, Direct	Negative	
Hepatitis C Virus Ab	Non-Reactive	Non-Reactive 0.90 S/Co Borderline 0.90-0.99 S/Co $\geq 1.0$ S/Co
Patient S/CO	0.04	

**Table 3: The special hematologic investigations ordered:**

category	result	reference
Fibrinogen Level	323.90	(200 - 400)mg/dL
Triglycerides	195	Normal 150 mg/dL Borderline High 150-190 mg/dL High 200-499 mg/dL Very High $\geq 500$ mg/dL
Patient S/CO Value	0.482	
Patient S/CO	0.25	
Folic Acid (Serum)	5.8	3.1 - 20.5 ng/mL
Active Vitamin B12	100	25 - 165 pmol/L
L D H	758	Male:135-225 U/L, Female:135-214 U/L
Malarial Parasite	Not Seen	
Dengue IgM	Negative	
Dengue IgG	Negative	
Dengue NS1 Ag	Negative	

**Table 4: The urine Routine analysis:**

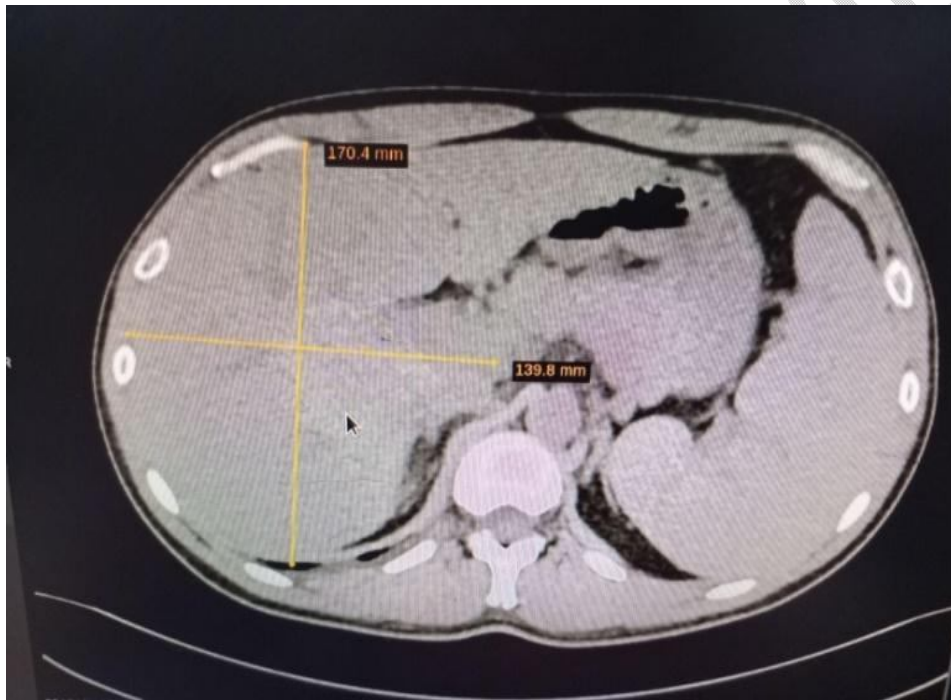
Urine routine examination		
Category	Result	Reference
Specific Gravity	1.010	1.005 - 1.025
pH	7	5 - 8
Protein	+++	Negative
Glucose	Negative	Negative
Ketone	+	Negative
Urobilinogen	++	Negative
Bilirubin	Negative	Negative
Nitrite	Negative	Negative
Blood	++++	Negative

Leukocytes	Negative	Negative
------------	----------	----------

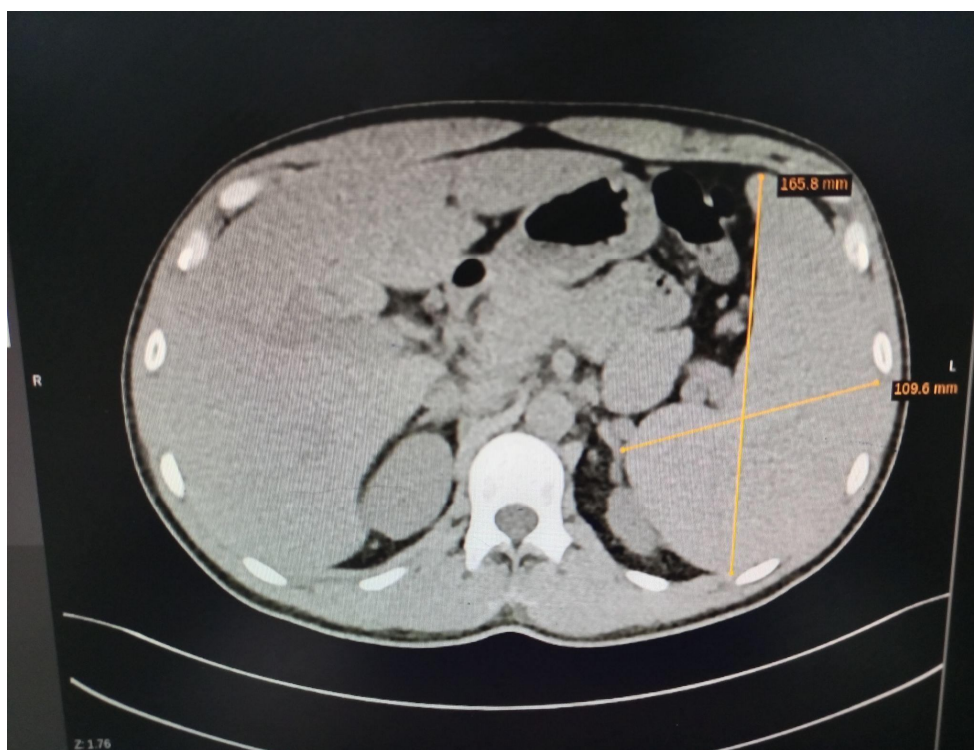
**Abbreviations:** WBCs: white blood cells; RBCs red blood cells; PTH: parathyroid hormone; mg/dL: milligram per deciliter; mmol/L: millimole per liter; pg/ml: picogram per milliliter; IU: international units; hpf: high power field.

**Abdominal CT scan:** abdominal CT scan of the patient shows a hepatosplenomegaly and small cysts on both the kidneys

**Figure 1.** [showing an abdominal CT scan with enlarged liver, and enlarged spleen due to HLH](#)



**Figure 2.** Showing an abdominal CT scan with an enlarged spleen



**Table 5. Abdominal CT scan findings:**

S. No.	Structure	Impression
01	<b>Liver</b>	Hepatomegaly with liver measuring 20 cm (normal 7-10cm). A hypo density measuring 11mm is noted in segment II of the liver with internal water attenuation likely a small liver cyst
02.	<b>Spleen</b>	Splenomegaly measuring 16cm (normal 12cm) in craniocaudal dimension. A small calculi s is also noted on the upper pole of the spleen
03.	<b>Lymph nodes and Ascites</b>	No intra-abdominal lymphadenopathy or ascites
04.	<b>Kidneys</b>	Right kidney measures 11.2 cm and left kidney

		measures 10.2 cm in maximum bipolar dimension. A cyst measuring 8 mm at the interpolar region of the right kidney and sub capsular cyst measuring 11 mm at lower pole of left kidney
--	--	--

**Abdominal Ultrasound:**An abdominal ultrasound also showed an enlarged liver measuring 170 mm (normal 137mm) in cranio caudal dimension and an enlarged spleen with a splenic span of 164 mm.No wall thickening in the gallbladder was noted. All other viscera were normal.

**Table 6.Treatment:**Received by the patient in both inpatient and at home setting;

S. No.	Name of a drug	Route of administration	Dosage	Duration
1	Dexamethasone	IV	20 mg	Once a day for 3 days
2	Inj. Vitamin K	IV	10 mg	OD
3	Inj. Ceftriaxone	IV	1 g	OD
4	Syp. Duphalac	PO	2 TSF	TDS
5	Inf. Ringer's lactate solution	IV	500 ml	BD
<b>Home Treatment:</b>				
6	Tab. Motilium (antiemetic)	PO	1 Tab	TDS
7	Syp. Ulsanic (antitussive)	PO	2 TSF	BD
8	Tab. Cefixime	PO	250 mg	BD

**Abbreviation:***Inj, Injection; Syp syrup, Inf. infusion, Tab., tablet, IV, Intravenous, PO, per oral; TSF, teaspoon, OD, once daily, TDS, thrice daily, BD, twice daily.*

### Literature Review of previously reported *S paratyphi* associated HLH:

On reviewing some of the literature on HLH secondary to *Salmonella typhi* a number of case reports were found with most of the patients being from a pediatric age group a few other age groups were also reported<sup>11</sup>.

.A case in which a 4 year old girl reported to a tertiary care hospital in Karachi with high-grade fever, frequent loose stools, and bleeding from the lips and gums. Investigations showed pancytopenia, hyperferritinemia, hypofibrinogenemia, and hypertriglyceridemia whereas the bone marrow biopsy revealed hemophagocytosis with trilineage suppression. Blood cultures grew *Salmonella typhi*. After ruling out other possibilities, the diagnosis of HLH was made as per the HLH-2004 diagnostic criteria. The patient responded well to culture-sensitive antibiotics and supportive treatment. (Awais Abbas, 2018)<sup>11</sup>.

A case in Bali of a 38-year-old male was admitted with complaints of persistent intermittent fever for three weeks. Other complaints were maculopapular rashes, epistaxis, black-colored stools, abdominal pain, nausea, vomiting, fatigue, and decreased appetite. On physical examination, he was pale; with a temperature was 39.5C, a dry tongue with petechial spots at the root of the tongue, and some maculopapular rash of the entire body. There was splenomegaly. Laboratory investigations showed pancytopenia. IgM salmonella typhi was positive<sup>12</sup>. A liver function test revealed transaminitis. Additional laboratory tests showed hypertriglyceridemia, hyperferritinemia and hypernatremia. USG's abdomen showed splenomegaly. Patient possibility of secondary HLH was considered and investigated, diagnosed and treated accordingly (Suputra, 2019)<sup>13</sup>.

A 23-year-old male from Mumbai, India with a fever and abdominal pain due to typhoid. He continued to have a high-spiking fever and developed dyspnea, requiring oxygen therapy despite being treated with appropriate antibiotics<sup>14</sup>. Laboratory evaluation revealed cytopenias and deranged liver function tests, and abdominal imaging revealed hepatosplenomegaly<sup>15</sup>. These clinical and laboratory findings raised suspicion of HLH secondary to typhoid fever. Further investigations were suggestive of hyperferritinemia and hypofibrinogenemia, and bone marrow aspirates showed hemophagocytes. The patient was treated with immunosuppression (dexamethasone) and antibiotics and showed remarkable recovery (Shekhar Shekhar1 Rahul Radhakrishnan, 2023)<sup>16</sup>

### **Brief epidemiology and pathophysiology of HLH**

Defining the true incidence is an impossible task as HLH is a condition that some consider a faith-based diagnosis, making the phenotype of the provider as important as the patient to identify and report "HLH" versus other conditions characterized by inflammation (Leticia Castillo 1, 2009).It affects both genders though slight male predisposition is seen in adolescents (Claireaux, 1952)<sup>17</sup>

In the normal physiological context, granule-mediated cytotoxic function of natural killer (NK) cells and CTLs is required for clearance of viral infection as well as regulation and termination of the inflammatory response. Thus, defects in NK cell and CTL granule-mediated cytotoxicity result in ineffective clearance of infection and defective suppression of antigen presentation, leading to persistent antigen exposure and prolonged cytotoxic T-cell activation (Jennifer E. Lykens, 2012).An overwhelming T-cell activation can lead to a marked elevation of cytokines such as IFN-gamma, tumor necrosis factor alpha, IL-6, IL8, IL-10, IL-12, IL-18, and macrophage colony-stimulating factor. IFN-gamma has a critical role in macrophage activation in HLH. Tumor necrosis factor can cause hypertryglyceredemia and hypofibrinogenemia<sup>18</sup>.

### **Discussion:**

HLH is a rare condition in which the immune system abnormally overreacts and attacks the body characterized by many hematologic changes and organ disorders. It can be primary (familial) or secondary (acquired). Familial form is because of genetic mutations and might have a positive family history, while the acquired form is usually secondary to infections which can be bacterial, viral or fungal.

In developing countries, typhoid fever continues to be a major source of fever due to the Salmonella typhi or paratyphi bacteria. The severity of the condition can vary from a simple febrile sickness to sepsis and complications like hemophagocytic lymphohistiocytosis (HLH), which affects multiple organs (Christian S Marchello, 2020)<sup>19</sup>.

The exact pathogenesis of secondary HLH has yet to be understood but it is an inflammatory condition characterized by an overwhelming T-cell activation leading to a marked elevation of cytokines such as IFN-gamma, tumor necrosis factor alpha, IL-6, IL8, IL-10, IL-12, IL-18, and macrophage colony-stimulating factor.

Clinically diagnoses can be difficult because of similarities in signs and symptoms with other illnesses as it generally presents with fever, loose stools, and decreased appetite and on Investigation one can expect pan or bi cytopenias, hepatosplenomegaly, hypertriglyceridemia, hypofibrinogenemia<sup>20</sup>.

HLH is usually diagnosed using both molecular and clinical criteria by Histiocyte Society's HLH-2004. Nowadays, alternative modified measures 2009 have been proposed:

**Table 7:** HLH 2004 diagnostic criteria and HLH proposed diagnostic criteria 2009.

HLH 2004 diagnostic criteria	Proposed diagnostic criteria 2009
a. Molecular diagnosis consistent with HLH. Pathologic mutations of PRF1, UNC13D or STX11 are identified.	a. Molecular diagnosis consistent with HLH or X-linked lymph proliferative syndrome (XLP).
OR	OR
b. Fulfillment of five of eight of the following criteria <ul style="list-style-type: none"> <li>• Fever</li> <li>• Splenomegaly</li> <li>• Cytopenias (affecting at least two of three lineages in the peripheral blood)</li> <li>• Hemoglobin &lt;9 g/100 ml (in infants &lt;4 weeks: hemoglobin &lt;10 g/100 ml)</li> <li>• Platelets &lt;100 ×10<sup>3</sup> /ml</li> <li>• Neutrophils &lt;1× 10<sup>3</sup> /ml</li> <li>• Hypertriglyceridemia (fasting, ≥265 mg/100 ml) and/or hypofibrinogenemia ( ≤ 150 mg/100 ml)</li> <li>• Hemophagocytosis in BM, spleen or lymph nodes</li> <li>• Low or absent NK cell activity</li> <li>• Ferritin ≥ 500 ng/ml</li> </ul>	<ul style="list-style-type: none"> <li>• b. Fulfillment of at least three of four following criteria               <ul style="list-style-type: none"> <li>• <b>Fever</b></li> <li>• <b>Splenomegaly</b></li> <li>• <b>Cytopenias (minimum 2 cell lines reduced)</b></li> <li>• Hepatitis</li> </ul> </li> <li>• c. Fulfillment of at least one of four following criteria               <ul style="list-style-type: none"> <li>• Hemophagocytosis</li> <li>• <b>↑ Ferritin</b></li> <li>• <b>↑ sIL2Rα (age based)</b></li> <li>• Absent or very decreased NK function</li> </ul> </li> <li>d. Other supportive diagnostic features               <ul style="list-style-type: none"> <li>• <b>Hypertriglyceridemia</b></li> <li>• Hypofibrinogenemia</li> <li>• Hypernatremia</li> </ul> </li> </ul>

- |  |  |
|--|--|
| <ul style="list-style-type: none"><li>• Soluble CD25 (soluble IL-2 receptor) &gt;2400 U/ml (or per local reference laboratory)</li></ul> |  |
|--|--|

The highlighted symptoms were present in our patient.

Identifying, providing supportive care and treating the underlying cause of HLH may be the most crucial intervention for patients of acquired HLH. However, severely ailing or deteriorating patients may require steroid or immunomodulatory therapy (Suputra, 2019). Broad-spectrum antibiotics as per culture report and steroid therapy is deemed the most suitable treatment option for the control of disease<sup>21</sup>.

For this patient a treatment of Dexamethasone (steroids) and third generation cephalosporins was adopted which controlled the progression of disease and corrected the pan cytopenias and fever dropped. Ringer lactate for fluid balance was given because of his diarrhea. Antiemetic and Antitussives were also given for his associated symptoms of vomiting and dry cough. Early diagnoses and prompt treatment resulted in a recovery of the patient from this treatable but fatal condition<sup>22,23</sup>.

### **Conclusion:**

Typhoid fever caused by the bacterium salmonella typhi and paratyphi is a serious febrile illness and is more common in the developing countries. As a first line intervention, treating the etiology of HLH would be an efficient way to restrict the disease's progression. We report a rare and unique case of secondary HLH due to typhoid fever, this complication is often missed and a prompt diagnosis is essential for the treatment of this fatal disease.

### **Data availability**

#### *Underlying data*

All data underlying the results are available as part of the article and no additional source data are required

### **Consent:**

Written informed consent for publication of their clinical details and/or clinical images was obtained from the patient.

### **Disclaimer (Artificial intelligence)**

#### **Option 1:**

Author(s) hereby declare that NO generative AI technologies such as Large Language Models (ChatGPT, COPILOT, etc.) and text-to-image generators have been used during the writing or editing of this manuscript. **Not used**

#### **Option 2:**

Author(s) hereby declare that generative AI technologies such as Large Language Models, etc. have been used during the writing or editing of manuscripts. This explanation will include the name, version, model, and source of the generative AI technology and as well as all input prompts provided to the generative AI technology, **Not used**

## References:

1. Awais Abbas, M. R. (2018). *Infection-associated Hemophagocytic Lymphohistiocytosis: An Unusual Clinical Masquerader*.cureus.
2. Christian S Marchello, M. B. (2020). Complications and mortality of typhoid fever: A global systematic review and meta-analysis. *journal of infection*.
3. Claireaux, J. W. (1952). Familial Haemophagocytic Reticulosis. *archives of diseases in childhood*.
4. Hanny Al-Samkari 1, N. B. (2017). Hemophagocytic Lymphohistiocytosis. *Annual review of pathology*.
5. James E. Meiring, F. K. (2023). Typhoid fever. *white rose research online*, 51.
6. Jan-Inge Henter MD, P. A. (2004). HLH-2004: Diagnostic and therapeutic guidelines for hemophagocytic lymphohistiocytosis. *pediatric blood and cancer*.
7. Jennifer E. Lykens, C. E. (2012). Perforin is a critical physiologic regulator of T-cell activation. *blood*.
8. Kodan, P., Chakrapani, M., Shetty, M., Pavan, R., & Bhat, P. (2014). Hemophagocytic lymphohistiocytosis secondary to infections. *journal of post graduate medicine*.
9. Leticia Castillo 1, J. C. (2009). Secondary hemophagocytic lymphohistiocytosis and severe sepsis/systemic inflammatory response syndrome/multiorgan dysfunction syndrome/macrophage activation syndrome share common intermediate phenotypes on a spectrum of inflammation. *pediatric critical care medicine*.
10. Shekhar Shekhar1 Rahul Radhakrishnan, a. V. (2023). *Secondary Hemophagocytic Lymphohistiocytosis Due to Typhoid Fever*.cureus.
11. Siddaiahgari, S. R. (2016). Hemophagocytic Lymphohistiocytosis: A Review. *Blood Disorders & Transfusion*.
12. Suputra, I. G. (2019). *Secondary Hemophagocytic Lymphohistiocytosis In Typhoid Fever: Case Report*. international journal of scientific advances.
13. Hemophagocytic lymphohistiocytosis mimics many common conditions: case series and review of literature. Akenroye AT, Madan N, Mohammadi F, Leider J. <http://www.eurannallergyimm.com/cont/journals-articles/466/volume-hemophagocytic-lymphohistiocytosis-mimics-many-common-1243allasp1.pdf>. Eur Ann Allergy Clin Immunol. 2017;49:31–41. [PubMed] [Google Scholar]
14. Recent advances in the diagnosis and treatment of hemophagocytic lymphohistiocytosis. Bode SF, Lehmborg K, Maul-Pavicic A, Vraetz T, Janka G, Stadt UZ, Ehl S. *Arthritis Res Ther*. 2012;14:213. [PMC free article] [PubMed] [Google Scholar]
15. Interleukin-18: biological properties and role in disease pathogenesis. Kaplanski G. *Immunol Rev*. 2018;281:138–153. [PMC free article] [PubMed] [Google Scholar]
16. Macrophage activation-like syndrome: a distinct entity leading to early death in sepsis. Karakike E, Giamarellos-Bourboulis EJ. *Front Immunol*. 2019;10:55. [PMC free article] [PubMed] [Google Scholar]
16. Adult haemophagocytic syndrome. Ramos-Casals M, Brito-Zerón P, López-Guillermo A, Khamashta MA, Bosch X. *Lancet*. 2014;383:1503–1516. [PubMed] [Google Scholar]

17. How I treat hemophagocytic lymphohistiocytosis. Jordan MB, Allen CE, Weitzman S, Filipovich AH, McClain KL. *Blood*. 2011;118:4041–4052. [PMC free article] [PubMed] [Google Scholar]
18. Highly elevated ferritin levels and the diagnosis of hemophagocytic lymphohistiocytosis. Allen CE, Yu X, Kozinetz CA, McClain KL. *Pediatr Blood Cancer*. 2008;50:1227–1235. [PubMed] [Google Scholar]
19. Diagnostic challenges of hemophagocytic lymphohistiocytosis. Otrock ZK, Daver N, Kantarjian HM, Eby CS. *Clin Lymphoma Myeloma Leuk*. 2017;17S:0–10. [PubMed] [Google Scholar]
20. Central nervous system involvement in hemophagocytic lymphohistiocytosis in adults: a retrospective analysis of 96 patients in a single center. Song Y, Pei RJ, Wang YN, Zhang J, Wang Z. *Chin Med J (Engl)* 2018;131:776–783. [PMC free article] [PubMed] [Google Scholar]
21. Hemophagocytic lymphohistiocytosis: an unusual complication in disseminated Mycobacterium tuberculosis. Padhi S, Ravichandran K, Sahoo J, Varghese RG, Basheer A. *Lung India*. 2015;32:593–601. [PMC free article] [PubMed] [Google Scholar]
22. Tuberculosis-associated hemophagocytic lymphohistiocytosis with initial presentation of fever of unknown origin in a general hospital: an analysis of 8 clinical cases. Zhang Y, Liang G, Qin H, Li Y, Zeng X. *Medicine (Baltimore)* 2017;96:0. [PMC free article] [PubMed] [Google Scholar].
- [23. Munasinghe BM, Arambepola AG, Pathirage N, Fernando UPM, Subramaniam N, Nimalan S, Gajanthan T. Haemophagocytic Lymphohistiocytosis with Leptospirosis: A Rare but Devastating Complication. Case Rep Infect Dis. 2021 Jul 8;2021:3451155. doi: 10.1155/2021/3451155. PMID: 34336315; PMCID: PMC8295509.](#)