

BIPHASIC ORTHODONTIC TREATMENT FOR SEVERE CLASS III MALOCCLUSION USING ORTHODONTIC CAMOUFLAGE: A CASE REPORT

ABSTRACT

Class III malocclusion in growing patients is one of the most challenging problems in orthodontics in terms of diagnosis, prognosis and treatment, mainly due to the unpredictability of the growth pattern in these patients. At this stage, malocclusion can be corrected in a variety of ways, depending on the degree of discrepancy and the pattern of malocclusion. Thus, the objective of this study was to demonstrate the importance of early treatment of class III malocclusion, treated using interceptor orthodontics with orthodontic and orthopedic effects associated with the use of Petit mask, conventional orthodontic appliances and premolar extraction. We conclude that early interception through orthodontic mechanics and facial orthopedics proved to be an effective treatment alternative, yielding satisfactory and stable aesthetic-functional results, along with the patient's satisfaction in utilizing orthodontic camouflage instead of undergoing orthognathic surgery.

Keywords: Orthodontics; Angle Class III malocclusion; Corrective Orthodontics.

INTRODUCTION

Class III malocclusion involves dental, skeletal or both structures and has a lower prevalence compared to other malocclusions [1,2]. Because it is a complex condition, treatment commonly involves a compensatory or orthodontic-surgical approach, although the results are not consistently predictable [3].

In growing patients, Class III malocclusion is one of the most challenging problems in orthodontics, mainly due to the unpredictability of the growth pattern. In this phase, malocclusion can be corrected in a variety of ways, depending on the degree of discrepancy and the pattern of malocclusion [4,5]. Therefore, the early approach to this type of condition has been increasingly employed since, in these cases, there is no intrinsic potential for self-correction [6].

In situations with large vertical and anteroposterior disparities in skeletal structures, the combination of orthodontic treatment with surgery can be considered the most appropriate strategy [7]. However, in certain circumstances, some patients may express a preference for less-invasive interventions. In such cases, a viable alternative is compensatory treatment through extractions, which offers satisfactory results both in occlusal and aesthetic terms, with considerable stability. This approach is particularly appropriate when there are no aesthetic concerns from the patient and the anteroposterior skeletal disparity is not significant [8,9,10].

Therefore, the objective of this study is to demonstrate the importance of early treatment of class III malocclusion, through the presentation of a pediatric patient's clinical case, treated using interceptor orthodontics with orthodontic and orthopedic effects associated with the use of the Petit mask and later with conventional orthodontic appliances and extraction of premolars in an eleven-year follow-up.

CASE REPORT

Diagnosis

A 3-year-and-9-month-old Caucasian female patient presented at a dental clinic in Vespasiano, Minas Gerais, Brazil, with a complaint of increased growth of the chin. The patient exhibited a skeletal Class III malocclusion, potentially attributed to hereditary factors, as her father demonstrated a similar facial pattern. After the initial assessment of treatment options, including consideration of the potential need for surgery at a later stage, during adolescence or adulthood, the parents chose to pursue the least invasive resolution possible through orthodontic mechanics and facial orthopedics. Clinical evaluation revealed facial asymmetry, mandibular protrusion, and lower lip protrusion, along with anterior crossbite and the absence of diastemas (Baume type II arch) and primate spaces (Figure 1).

Teleradiography of the face and panoramic radiography revealed the presence of a slightly concave facial profile associated with the dolichofacial biotype (Figure 2). Capelozza's facial analysis was performed, and the following values were obtained for the SNA, SNB and ANB angles: 79; 83 and -1 (Table 1).

The anterior position of the mandible and lower lip resulted in an increased distance from the nasal tip to the H line (13 mm), with the S-Ls and S-Li line values at 0 mm and 1 mm, indicating a concave facial profile (Table 1).

Clinical and imaging evaluation made it possible to reach the diagnosis of the patient as Angle Class III with anteroposterior maxillary deficiency (maxillary hypoplasia) and an open gonial angle with marked mandibular growth. Thus, the proposed treatment options involved the implementation of orthodontic and orthopedic mechanics, aiming for orthodontic camouflage through dental and skeletal compensations, while acknowledging the potential necessity for surgical correction of the Class III malocclusion during adolescence or adulthood.

Treatment Plan

The treatment of choice was orthodontic camouflage through dental and skeletal compensations in the initial phase. The treatment plan involved the following stages throughout the child's growth: (1) installation of a facial mask with Hyrax; (2) bonding of brackets on deciduous teeth for slow incisor protrusion; (3) installation of the lower spur; and subsequently, (4) installation of the upper fixed appliance in the permanent dentition; (5) extraction of the premolars (44/34).

Treatment Progress

Initially, the maxilla was disconnected with Hyrax, activating it with 2/4 turns in the morning and 2/4 turns in the afternoon for 20 days. Concomitantly with the disjunction, reverse traction of the maxilla was performed using the Petit face mask for a period of 20 hours a day (from 4 to 9 years) with the use of 1/2-inch medium elastic bands.

With the use of the face mask and the disjunction of the maxilla, it was observed that the upper deciduous incisors were in a top-to-top relationship. Thus, in order to optimize the treatment time, when the patient was 6 years old, brackets were bonded to these deciduous teeth and, with the Ricketts base arch mechanics, these dental elements were advanced to uncross the anterior bite. Then the brackets were removed.

After the eruption of the permanent teeth, when the patient was 10 years old, new orthodontic documentation was requested to continue the treatment. Subsequently, the device was installed in the upper arch and lower spur in order to correct atypical swallowing by tongue pressing. At 12 years of age, the extraction of the mandibular first premolars was performed to gain space, perform a lower canine retraction, and camouflage the dental malocclusion. Subsequently, the lower orthodontic appliance was installed, and the fixed treatment continued until the completion of the leveling and alignment of the teeth when the patient was 14 years old. For follow-up, radiographic exams were requested until the year 2023.

Treatment Results

At the conclusion of treatment, with the patient in the adolescent phase, she reported satisfaction with the compensatory treatment, which eliminated the need for surgery. Physical examination revealed correction of facial asymmetry achieved through the employed treatment modalities. Intraoral examination demonstrated a Class I canine relationship according to Angle, satisfactory alignment and leveling, coincident upper and lower midlines, as well as a harmonious facial profile(Figure 3).

Teleradiography of the face and panoramic radiography showed the presence of a straight facial profile associated with the mesofacial biotype (Figure 4). The final analysis of Cepelozza showed the following values of the SNA, SNB and ANB angles: 82, 81 and 0, indicating the facial pattern of normality (Table 1).

The position of the mandible and lower lip after camouflage showed a distance of 11 mm from the nasal tip to the H line, resulting in the S-Ls and S-Li line values at 5 mm and 4 mm, indicating a straight facial profile (Table 1).

The clinical and imaging evaluation made it possible to reach the final diagnosis of class I canines, achieved through orthodontic camouflage and dental/skeletal compensation.

Treatment Alternatives

It is important to mention the limitations of the approach employed in this case. By opting for dental and skeletal compensation, the final outcomes may not be ideal, potentially impacting facial aesthetics, the integrity of the teeth, and overall occlusal stability. The gold standard for the treatment of dentofacial deformities is the orthodontic-surgical pathway, utilizing orthognathic surgery to aid in the repositioning of the jaws.

Therefore, it is essential to evaluate each case individually to determine the treatment possibilities, considering the limitations, degree of severity and patient's wishes.

DISCUSSION

In the clinical case presented, considering the clinical characteristics of the patient, as well as the severity of the dentofacial discrepancy present, orthodontics alone was chosen instead of the surgical approach. Sinclair; Thomas; Proffit [11] pointed out that one of the most difficult decisions for the orthodontist and surgeon is whether the patient with borderline skeletal discrepancy can be successfully treated with orthodontics alone. The risks of surgical treatment are greater than those of a camouflage approach [12].

The multifactorial nature of mandibular prognathism expression in individuals is uncontroversial, being a result of environmental and genetic factors, as widely demonstrated in the scientific literature [13]. Although varied environmental factors contribute to mandibular growth, genetic factors play a substantial role, such as autosomal dominant inheritance, with incomplete penetrance associated with this phenotype [14]. Nevertheless,

recent studies have been able to demonstrate that the genetic components associated with the expression of mandibular prognathism are not only involved in maxillo-mandibular osteogenesis, but also with masticatory muscles, the condyle, and growth hormone [13].

On the other hand, the benefits that orthodontic interception, especially in patients with Class III malocclusion, such as the one performed in this case, can bring to patients, have long been known, reducing the total treatment time and providing better stability and functional and aesthetic results [15]. In addition, orthodontic interception that occurred in childhood has important repercussions from the point of view of the patient's psychosocial context, considering that recent studies have shown that dental malocclusions are the main causes of bullying in school-age children [16,17]. A recently published systematic review evaluated the correlation between dental malocclusion and bullying and concluded that, although the association between orthodontic treatment and better self-esteem is still controversial, the results suggest that malocclusion may indeed be related to the occurrence of bullying among children and adolescents [18]. In another study, conducted with the participation of Brazilian children aged 8 to 10 years, whose degree of severity of malocclusions was classified based on the Dental Aesthetic Index (DAI), and quality of life assessed by the CPQC8-10 questionnaire, it was observed that malocclusions, especially with the presence of pronounced overjet, had a negative impact on the quality of life of these individuals [19].

Orthodontic interception, using the camouflage technique, was the choice for this case, where the aim was to improve the positioning of the teeth and also the facial profile. Orthodontic camouflage planning must be extremely careful and well carried out [20,21,22,23]. Despite the dental benefits pursued by orthodontic mechanics, additional benefits were achieved by performing orthodontic interventions early, such as lower economic and biological costs [24].

The initial (pre-treatment) values of the Capellozza cephalometric analysis revealed the presence of a slightly concave facial profile associated with the dolichofacial biotype, with values of the SNA, SNB and ANB angles: 79°; 83rd and -1st respectively. The orthodontic technique used allowed the correction of the SNA, SNB and ANB angles for the values: 78°, 81° and -2°, revealed through the post-treatment cephalometric analysis, which indicated a normal facial pattern. The results obtained with orthodontic camouflage corroborate the findings in the literature, which demonstrate that in addition to dental improvement, camouflage also improves the facial profile [25].

It was demonstrated that orthodontic interception performed early (in the growth phase) was able to properly and adequately resolve a dentoskeletal-facial discrepancy that, in adulthood, would lead to the indication of orthognathic surgery for its correction. Interceptive orthodontics aims to stop an existing abnormality, causing the occlusion to proceed normally [26].

According to Cruz et al. [27], the orthodontist must satisfy the patient's main complaint so that the patient presents a pleasant facial aesthetic and a healthy functional and masticatory occlusion for better long-term stability of the cases. In this sense, the present treatment allowed a satisfactory and stable positioning of Class I canines through the use of orthodontic mechanics aimed at dental compensation.

Corroborating the results obtained in the management of this clinical case, a recent multicenter retrospective controlled study conducted in Brazil evaluated the short- and long-term dentoskeletal effects of early treatment for Class III malocclusion using rapid maxillary expansion and facial mask (RME/FM) followed by fixed appliances [28]. The study demonstrated that this approach was effective in improving the dentoskeletal relationships of Class III malocclusion in the short term, with these changes remaining stable in the long term, primarily due to favorable mandibular alterations. In this context, it is essential to emphasize that orthodontic compensation or camouflage techniques may be instituted in specific cases but should not be employed as a generalized practice.

Mentoplasty for chin setback was suggested to achieve a final refinement of the facial aesthetic result; however, the patient opposed the procedure, citing satisfaction after the completion of orthodontic treatment.

CONCLUSIONS

Considering the limitations of this treatment option and the specificities of this clinical case, particularly the degree of discrepancy initially presented, we conclude that early interception through orthodontic mechanics and facial orthopedics proved to be an effective treatment alternative, yielding satisfactory and stable aesthetic-functional results, along with the patient's satisfaction in utilizing orthodontic camouflage instead of undergoing orthognathic surgery.

DISCLAIMER (ARTIFICIAL INTELLIGENCE)

Author(s) hereby declare that NO generative AI technologies such as Large Language Models (ChatGPT, COPILOT, etc.) and text-to-image generators have been used during the writing or editing of this manuscript.

COMPETING INTERESTS

Authors have declared that no competing interests exist.

REFERENCES

1. Alhammadi MS., Almashraqi AA., Khadhi AH., Arishi KA., Alamir AA., Beleges EM., et al. Orthodontic camouflage versus orthodontic-orthognathic surgical treatment in borderline class III malocclusion: a systematic review. *Clin Oral Investig* 2022;26(11):6443–55. Doi: 10.1007/s00784-022-04685-6.
2. Guo L, Feng Y, Guo HG, Liu BW, Zhang Y. Consequences of orthodontic treatment in malocclusion patients: clinical and microbial effects in adults and children. *BMC Oral Health*. 2016;112:1–7.
3. Mts A., Lr S. Orthodontic camouflage as a treatment alternative for skeletal Class III. *Dental Press Journal of Orthodontics* 2021;26(4). Doi: 10.1590/2177-6709.26.4.e21bbo4.
4. Ngan P., Moon W. Evolution of Class III treatment in orthodontics. *American Journal of Orthodontics and Dentofacial Orthopedics* 2015;148(1):22–36. Doi: 10.1016/j.ajodo.2015.04.012.
5. Yu HS., Baik HS., Sung SJ., Kim KD., Cho YS. Three-dimensional finite-element analysis of maxillary protraction with and without rapid palatal expansion. *The European Journal of Orthodontics* 2007;29(2):118–25. Doi: 10.1093/ejo/cjl057.
6. Al-Mozany SA., Dalci O., Almuzian M., Gonzalez C., Tarraf NE., Ali Darendeliler M. A novel method for treatment of Class III malocclusion in growing patients. *Prog Orthod* 2017;18(1):40. Doi: 10.1186/s40510-017-0192-y.
7. Poletti L., Silvera AA., Ghislanzoni LTH. Dentoalveolar class III treatment using retromolar miniscrew anchorage. *Prog Orthod* 2013;14(1):7. Doi: 10.1186/2196-1042-14-7.
8. Zimmer B., Gaida S., Dathe H. Compensation of skeletal Class III malocclusion by isolated extraction of mandibular teeth: Part 2: Skeletal, dentoalveolar and soft tissue parameters in comparison with nonextraction Class III therapies. *J Orofac Orthop* 2016;77(2):119–28. Doi: 10.1007/s00056-016-0016-6.
9. Ruellas ACDO., Baratieri C., Roma MB., Izquierdo ADM., Boaventura L., Rodrigues CS., et al. Angle Class III malocclusion treated with mandibular first molar extractions. *American Journal of Orthodontics and Dentofacial Orthopedics* 2012;142(3):384–92. Doi: 10.1016/j.ajodo.2011.01.025.
10. De Lima E., Brum F., Mezomo M., Pasquali CE., Farret M. Orthodontic treatment of Class III malocclusion with lower extraction and anchorage with mini implants: Case report. *Journal of the World Federation of Orthodontists* 2017;6(1):28–34. Doi: 10.1016/j.ejwf.2017.02.003.
11. Proffit W. *Ortodontia Contemporânea*. 6th ed. RIO DE JANEIRO, RJ: Grupo Gen; 2022.
12. Mihalik CA., Proffit WR., Phillips C. Long-term follow-up of Class II adults treated with orthodontic camouflage: A comparison with orthognathic surgery outcomes. *American Journal of Orthodontics and Dentofacial Orthopedics* 2003;123(3):266–78. Doi: 10.1067/mod.2003.43.
13. Liu H., Wu C., Lin J., Shao J., Chen Q., Luo E. Genetic Etiology in Nonsyndromic Mandibular Prognathism. *Journal of Craniofacial Surgery* 2017;28(1):161–9. Doi: 10.1097/SCS.0000000000003287.
14. Doraczynska-Kowalik A., Nelke KH., Pawlak W., Sasiadek MM., Gerber H. Genetic Factors Involved in Mandibular Prognathism: *Journal of Craniofacial Surgery* 2017;28(5):e422–31. Doi: 10.1097/SCS.0000000000003627.
15. Richardson A. Interceptive orthodontics in general dental practice. Part I--Early interceptive treatment. *Br Dent J* 1982;152(3):85–9. Doi: 10.1038/sj.bdj.4804752.
16. Artese F. A broader look at Interceptive Orthodontics: What can we offer? *Dental Press J Orthod* 2019;24(5):7–8. Doi: 10.1590/2177-6709.24.5.007-008.edt.

17. Seehra J., Newton JT., DiBiase AT. Interceptive orthodontic treatment in bullied adolescents and its impact on self-esteem and oral-health-related quality of life. *The European Journal of Orthodontics* 2013;35(5):615–21. Doi: 10.1093/ejo/cjs051.
18. Tristão SKPC., Magno MB., Pintor AVB., Christovam IFO., Ferreira DMTP., Maia LC., et al. Is there a relationship between malocclusion and bullying? A systematic review. *Prog Orthod* 2020;21(1):26. Doi: 10.1186/s40510-020-00323-7.
19. Dutra SR., Pretti H., Martins MT., Bendo CB., Vale MP. Impact of malocclusion on the quality of life of children aged 8 to 10 years. *Dental Press J Orthod* 2018;23:46–53. Doi: 10.1590/2177-6709.23.2.046-053.oar.
20. Kai R., Umeki D., Sekiya T., Nakamura Y. Defining the location of the dental midline is critical for oral esthetics in camouflage orthodontic treatment of facial asymmetry. *American Journal of Orthodontics and Dentofacial Orthopedics* 2016;150(6):1028–38. Doi: 10.1016/j.ajodo.2015.10.035.
21. Kumari L. Non-surgical Management of Skeletal Class III Malocclusion with Bilateral Posterior Crossbite: A Case Report. *JCDR* 2016. Doi: 10.7860/JCDR/2016/19752.8962.
22. Lee G-C., Yoo J-K., Kim S-H., Moon C-H. Lip line changes in Class III facial asymmetry patients after orthodontic camouflage treatment, one-jaw surgery, and two-jaw surgery: A preliminary study. *The Angle Orthodontist* 2017;87(2):239–45. Doi: 10.2319/033016-254.1.
23. Martinez P., Bellot-Arcís C., Llamas JM., Cibrian R., Gandia JL., Paredes-Gallardo V. Orthodontic camouflage versus orthognathic surgery for class III deformity: comparative cephalometric analysis. *International Journal of Oral and Maxillofacial Surgery* 2017;46(4):490–5. Doi: 10.1016/j.ijom.2016.12.001.
24. Mendes BP., Magalhães RC., Caetano RM. Preventive and interceptative orthodontics: oral health benefits. *Research, Society and Development* 2023;12(6):e23812642236–e23812642236. Doi: 10.33448/rsd-v12i6.42236.
25. Seo Y-J., Chung K-R., Kim S-H., Nelson G. Camouflage treatment of skeletal Class III malocclusion with asymmetry using a bone-borne rapid maxillary expander. *The Angle Orthodontist* 2015;85(2):322–34. Doi: 10.2319/031314-189.1.
26. Toffol, L. D., Pavoni, C., Baccetti, T., Franchi, L., & Cozza, P. (2008). Orthopedic treatment outcomes in Class III malocclusion: a systematic review. *The Angle Orthodontist*, 78(3), 561-573.
27. Cruz KS., Janson G., Henriques JFC., Josgrilbert LF. Orthopedic-orthodontic camouflage of Class III malocclusion: a conservative approach. *Rev Clín Ortod Dent Press* 2004:61–72.
28. Rutili V., Souki BQ., Nieri M., Carlos ALFM., Pavoni C., Cozza P., et al. Long-term effects produced by early treatment of Class III malocclusion with rapid maxillary expansion and facemask followed by fixed appliances: A multicentre retro-prospective controlled study. *Orthod Craniofac Res* 2024;27(3):429–38. Doi: 10.1111/ocr.12748.

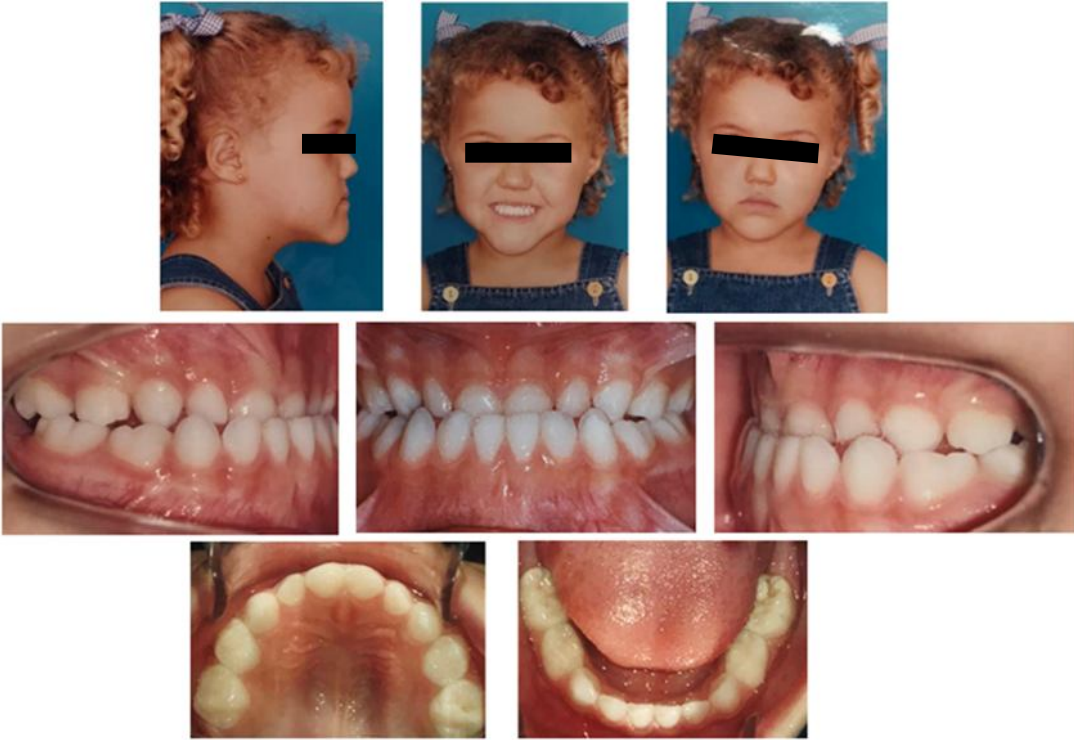

FIGURE 1. Pre-treatment facial and intraoral photographs.

UNDER PEER REVIEW

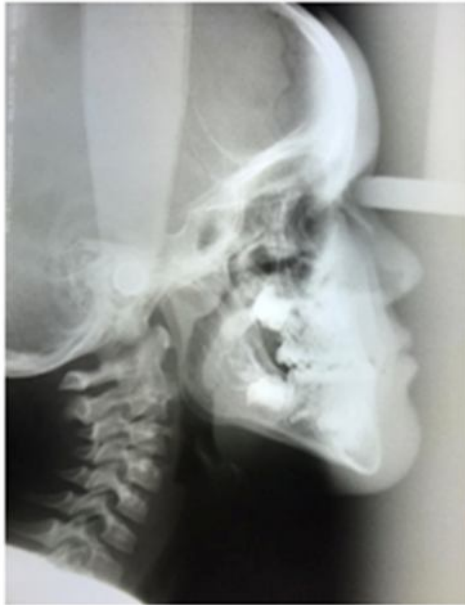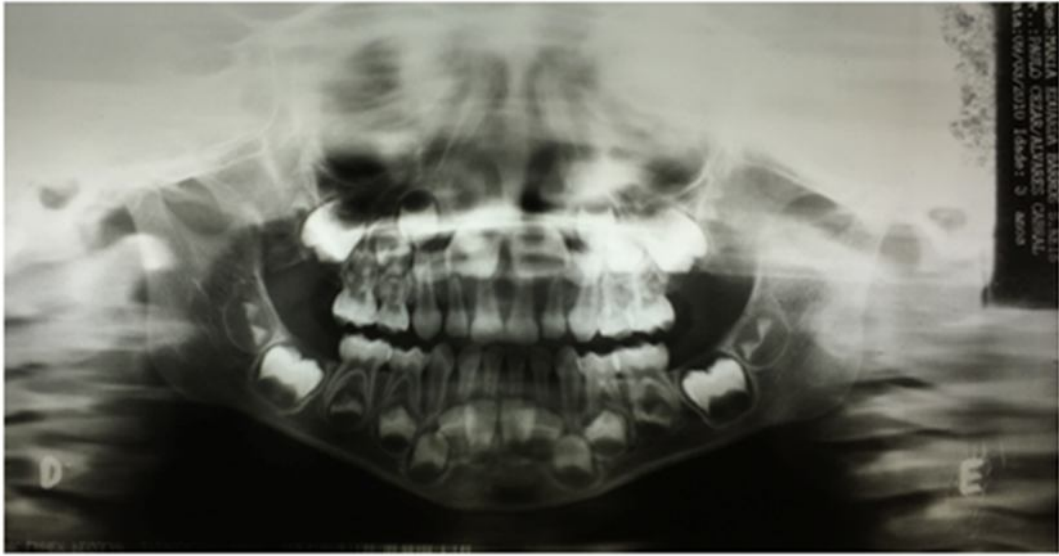


FIGURE 2.Pre-treatment panoramic and cephalometric tracing.

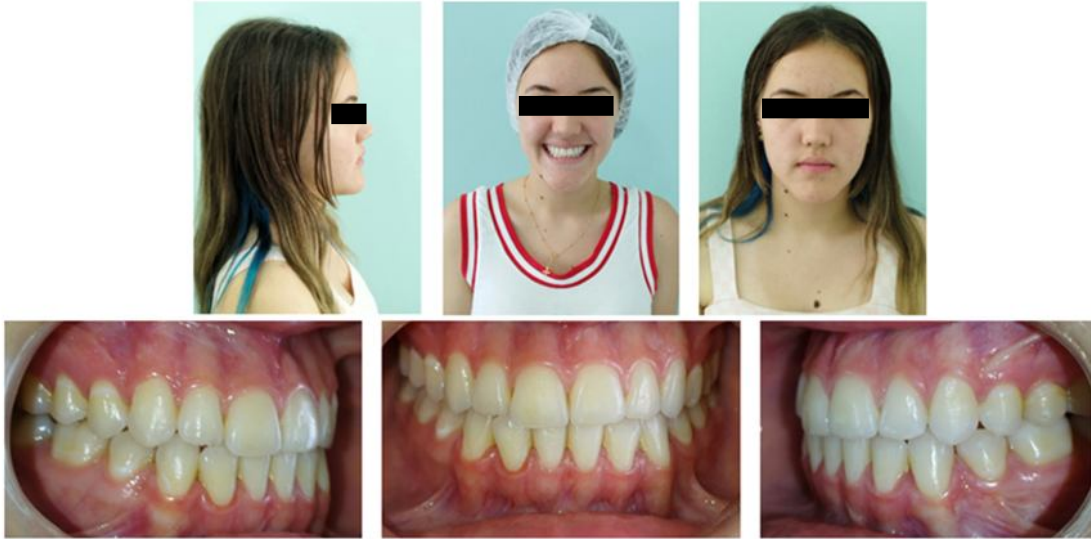

FIGURE 3. Post-treatment facial and intraoral photographs.

UNDER PEER REVIEW

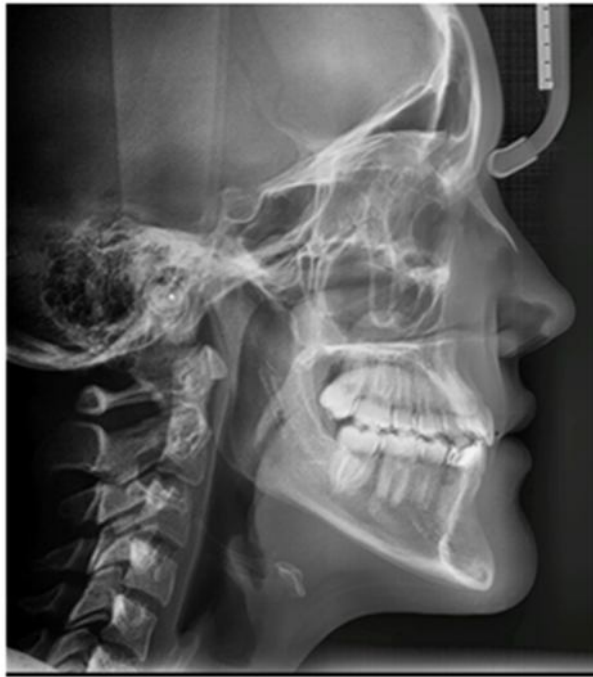
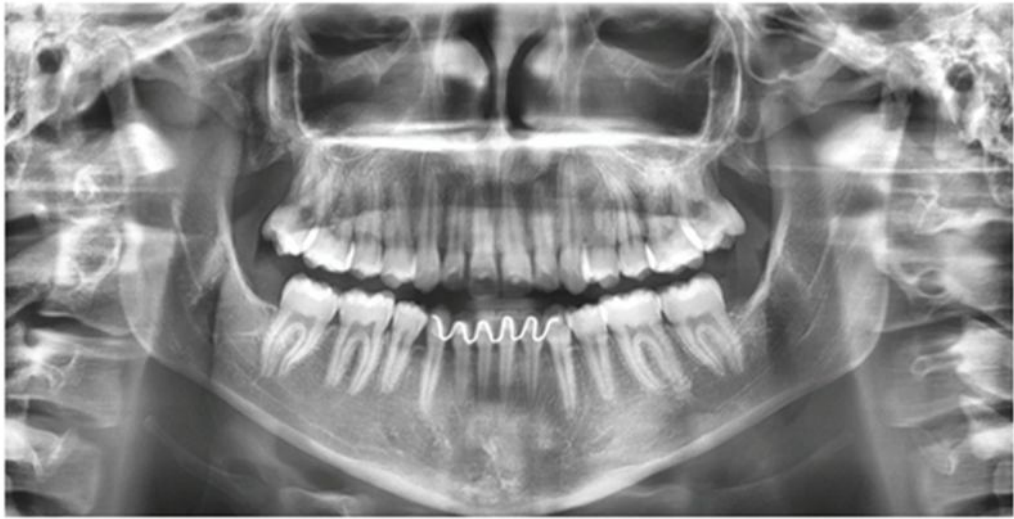
FIGURE 4. Post-treatment panoramic and cephalometric tracing.

TABLE 1. Descriptive analysis of the cephalometric variables analyzed.

CEPHALOMETRIC PARAMETERS	Initial	Final
FMA	23	25
SN. SGn	65	67
SN. GoGn	37	35
SN. Occlus	13	17
GoGn. Occlus	25	15
SNA	79	82
SNB	83	81
ANB	-1	0
SND	79	79
Facial Angle (NPog.PoOr)	94	92
Convexity angle (NA. Apog)	-6	-6
Interim Angle	133	129
I.NS	102	108
I.NA	14	33
I.NA	-1mm	6mm
IMPA	74	80
I.NB	15	18
I.NB	0mm	2mm
Nasolabial angle	87	96
H-Nose	13mm	11mm
Line S-Ls	0mm	5mm
Line S-Li	1mm	4mm