

ELEVEN-YEAR FOLLOW-UP OF CLASS III TREATMENT WITH ORTHODONTIC CAMOUFLAGE: A CASE REPORT

ABSTRACT

Class III malocclusion in growing patients is one of the most challenging problems in orthodontics in terms of diagnosis, prognosis and treatment, mainly due to the unpredictability of the growth pattern in these patients. At this stage, malocclusion can be corrected in a variety of ways, depending on the degree of discrepancy and the pattern of malocclusion. Thus, the objective of this study was to demonstrate the importance of early treatment of class III malocclusion, treated using interceptor orthodontics with orthodontic and orthopedic effects associated with the use of Petit mask, conventional orthodontic appliances and premolar extraction, in an eleven-year follow-up. We conclude that early orthodontic interception using orthodontic camouflage proved to be an effective treatment alternative, with satisfactory and stable aesthetic-functional results at the 11-year follow-up.

Keywords: Orthodontics; Angle Class III malocclusion; Corrective Orthodontics.

INTRODUCTION

Class III malocclusion involves dental, skeletal or both structures and has a lower prevalence compared to other malocclusions [1,2]. Because it is a complex condition, treatment commonly involves a compensatory or orthodontic-surgical approach, although the results are not consistently predictable [3].

In growing patients, Class III malocclusion is one of the most challenging problems in orthodontics, mainly due to the unpredictability of the growth pattern. In this phase, malocclusion can be corrected in a variety of ways, depending on the degree of discrepancy and the pattern of malocclusion [4,5]. Therefore, the early approach to this type of condition has been increasingly employed since, in these cases, there is no intrinsic potential for self-correction [6].

In situations with large vertical and anteroposterior disparities in skeletal structures, the combination of orthodontic treatment with surgery can be considered the most appropriate strategy [7]. However, in certain circumstances, some patients may express a preference for less-invasive interventions. In such cases, a viable alternative is compensatory treatment through extractions, which offers satisfactory results both in occlusal and aesthetic terms, with considerable stability. This approach is particularly appropriate when there are no aesthetic concerns from the patient and the anteroposterior skeletal disparity is not significant [8,9,10].

Therefore, the objective of this study is to demonstrate the importance of early treatment of class III malocclusion, through the presentation of a pediatric patient's clinical case, treated using interceptor orthodontics with orthodontic and orthopedic effects associated with the use of the Petit mask and later with conventional orthodontic appliances and extraction of premolars in an eleven-year follow-up.

CASE REPORT

Diagnosis

A female patient, 3 years and 9 months old, Caucasian, sought care at a dental office in the city of Vespasiano, Minas Gerais, Brazil, complaining of increased chin growth. The patient had a skeletal Class III malocclusion pattern, and previous treatment plans consisted of surgical-orthodontic approaches. However, her parents did not accept surgical treatment and opted for a second treatment plan. Facial asymmetry was observed, along with mandibular and lower lip protrusion. On the other hand, the intraoral examination revealed the absence of dental caries, the presence of an anterior crossbite with a mesial terminal plane, and the absence of diastemas (Baume arch type II) and primate space (Figure 1).

Teleradiography of the face and panoramic radiography revealed the presence of a slightly concave facial profile associated with the dolichofacial biotype (Figure 2). Capelozza's facial analysis was performed, and the following values were obtained for the SNA, SNB and ANB angles: 79; 83 and -1 (Table 1).

The anterior position of the mandible and lower lip resulted in an increased distance from the nasal tip to the H line (13 mm), with the S-Ls and S-Li line values at 0 mm and 1 mm, indicating a concave facial profile (Table 1).

Clinical and imaging evaluation made it possible to reach the diagnosis of the patient as Angle Class III with anteroposterior maxillary deficiency (maxillary hypoplasia) and an open gonial angle with marked mandibular growth. Thus, the proposed treatment options involved surgical correction of Class III malocclusion or orthodontic camouflage employing dental and skeletal compensations.

Treatment Plan

The treatment of choice was orthodontic camouflage. The treatment plan involved the following steps: (1) Installation of the face mask with Hyrax, (2) bonding of brackets on deciduous teeth for slow incisor protrusion; (3) installation of the lower spur; (4) installation of the upper fixed appliance in the permanent dentition, (5) extraction of the premolars (44/34).

Treatment Progress

Initially, the maxilla was disconnected with Hyrax, activating it with 2/4 turns in the morning and 2/4 turns in the afternoon for 20 days. Concomitantly with the disjunction, reverse traction of the maxilla was performed using the Petit face mask for a period of 20 hours a day (from 4 to 9 years) with the use of 1/2-inch medium elastic bands.

With the use of the face mask and the disjunction of the maxilla, it was observed that the upper deciduous incisors were in a top-to-top relationship. Thus, in order to optimize the treatment time, when the patient was 6 years old, brackets were bonded to these deciduous teeth and, with the Ricketts base arch mechanics, these dental elements were advanced to uncross the anterior bite. Then the brackets were removed.

After the eruption of the permanent teeth, when the patient was 10 years old, new orthodontic documentation was requested to continue the treatment. Subsequently, the device was installed in the upper arch and lower spur in order to correct atypical swallowing by tongue pressing. At 12 years of age, the extraction of the mandibular first premolars was performed to gain space, perform a lower canine retraction, and camouflage the dental malocclusion. Subsequently, the lower orthodontic appliance was installed, and the fixed treatment continued until the completion of the leveling and alignment of the teeth when the patient was 14 years old. For follow-up, radiographic exams were requested until the year 2023.

Treatment Results

At the end of the treatment, the physical examination revealed the absence of facial asymmetry. Intraoral examination revealed the absence of dental caries, canine class I, satisfactory alignment and leveling, and coincident upper and lower midlines (Figure 3).

Teleradiography of the face and panoramic radiography showed the presence of a straight facial profile associated with the mesofacial biotype (Figure 4). The final analysis of Capellozza showed the following values of the SNA, SNB and ANB angles: 82, 81 and 0, indicating the facial pattern of normality (Table 1).

The position of the mandible and lower lip after camouflage showed a distance of 11 mm from the nasal tip to the H line, resulting in the S-Ls and S-Li line values at 5 mm and 4 mm, indicating a straight facial profile (Table 1).

The clinical and imaging evaluation made it possible to reach the final diagnosis of class I canines, achieved through orthodontic camouflage and dental/skeletal compensation. Mentoplasty was suggested to achieve a better facial aesthetic result; however, the patient objected, claiming satisfaction after the orthodontic treatment was completed.

DISCUSSION

In the clinical case presented, considering the clinical characteristics of the patient, as well as the severity of the dentofacial discrepancy present, orthodontics alone was chosen instead of the surgical approach. Sinclair; Thomas; Proffit [11] pointed out that one of the most difficult decisions for the orthodontist and surgeon is whether the patient with borderline skeletal discrepancy can be successfully treated with orthodontics alone. The risks of surgical treatment are greater than those of a camouflage approach [12].

The multifactorial nature of mandibular prognathism expression in individuals is uncontroversial, being a result of environmental and genetic factors, as widely demonstrated in the scientific literature [13]. Although varied environmental factors contribute to mandibular growth, genetic factors play a substantial role, such as autosomal dominant inheritance, with incomplete penetrance associated with this phenotype [14]. Nevertheless, recent studies have been able to demonstrate that the genetic components associated with the expression of mandibular prognathism are not only involved in maxillo-mandibular osteogenesis, but also with masticatory muscles, the condyle, and growth hormone [13].

On the other hand, the benefits that orthodontic interception, especially in patients with Class III malocclusion, such as the one performed in this case, can bring to patients, have long been known, reducing the total treatment time and providing better stability and functional and aesthetic results [15]. In addition, orthodontic interception that occurred in childhood has important repercussions from the point of view of the patient's psychosocial context, considering that recent studies have shown that dental malocclusions are the main causes of bullying in school-age children [16,17]. A recently published systematic review evaluated the correlation between dental malocclusion and bullying and concluded that, although the association between orthodontic treatment and better self-esteem is still controversial, the results suggest that malocclusion may indeed be related to the occurrence of bullying among children and adolescents [18]. In another study, conducted with the participation of Brazilian children aged 8 to 10 years, whose degree of severity of malocclusions was classified based on the Dental Aesthetic Index (DAI), and quality of life assessed by the CPQC8-10 questionnaire, it was observed that malocclusions, especially with the presence of pronounced overjet, had a negative impact on the quality of life of these individuals [19].

Orthodontic interception, using the camouflage technique, was the choice for this case, where the aim was to improve the positioning of the teeth and also the facial profile. Orthodontic camouflage planning must be extremely careful and well carried out [20,21,22,23]. Despite the dental benefits pursued by orthodontic mechanics, additional benefits were achieved by performing orthodontic interventions early, such as lower economic and biological costs [24].

The initial (pre-treatment) values of the Capellozza cephalometric analysis revealed the presence of a slightly concave facial profile associated with the dolichofacial biotype, with values of the SNA, SNB and ANB angles: 79°; 83rd and -1st respectively. The orthodontic technique used allowed the correction of the SNA, SNB and ANB angles for the values: 78°, 81° and -2°, revealed through the post-treatment cephalometric analysis, which indicated a normal facial pattern. The results obtained with orthodontic camouflage corroborate the findings in the literature, which demonstrate that in addition to dental improvement, camouflage also improves the facial profile [25].

It was demonstrated that orthodontic interception performed early (in the growth phase) was able to properly and adequately resolve a dentoskeletal-facial discrepancy that, in adulthood, would lead to the indication of orthognathic surgery for its correction. Interceptive orthodontics aims to stop an existing abnormality, causing the occlusion to proceed normally [26].

According to Cruz et al. [27], the orthodontist must satisfy the patient's main complaint so that the patient presents a pleasant facial aesthetic and a healthy functional and masticatory occlusion for better long-term stability of the cases. In this sense, the present treatment allowed a satisfactory and stable positioning of Class I canines through the use of orthodontic mechanics aimed at dental compensation. To complete the treatment, she was offered to perform advancement mentoplasty, but the patient declined this treatment because she was satisfied with the aesthetic and functional results obtained.

CONCLUSIONS

Considering the limitations of this treatment option and the specificities of this clinical case, especially the degree of discrepancy initially present, we conclude that early orthodontic interception using orthodontic camouflage proved to be an effective treatment alternative, with satisfactory and stable aesthetic-functional results at the 11-year follow-up.

REFERENCES

1. Stellzig-Eisenhauer A., Lux CJ., Schuster G. Treatment decision in adult patients with Class III malocclusion: Orthodontic therapy or orthognathic surgery? *American Journal of Orthodontics and Dentofacial Orthopedics* 2002;122(1):27–37. Doi: 10.1067/mod.2002.123632.
2. Janson G., Prado De Souza JE., De Andrade Alves F., Andrade P., Nakamura A., Roberto De Freitas M., et al. Extreme dentoalveolar compensation in the treatment of Class III malocclusion. *American Journal of Orthodontics and Dentofacial Orthopedics* 2005;128(6):787–94. Doi: 10.1016/j.ajodo.2004.08.018.
3. Benyahia H, Azaroual MF, Garcia C, Hamou E, Abouqal R, Zaoui F. Treatment of class III skeletal malocclusions: orthognathic surgery or orthodontic camouflage? How to decide. *Int Ortod.* 2011; 9 (2):196–209.
4. Ngan P., Moon W. Evolution of Class III treatment in orthodontics. *American Journal of Orthodontics and Dentofacial Orthopedics* 2015;148(1):22–36. Doi: 10.1016/j.ajodo.2015.04.012.
5. Yu HS., Baik HS., Sung SJ., Kim KD., Cho YS. Three-dimensional finite-element analysis of maxillary protraction with and without rapid palatal expansion. *The European Journal of Orthodontics* 2007;29(2):118–25. Doi: 10.1093/ejo/cjl057.
6. Al-Mozany SA., Dalci O., Almuzian M., Gonzalez C., Tarraf NE., Ali Darendeliler M. A novel method for treatment of Class III malocclusion in growing patients. *Prog Orthod* 2017;18(1):40. Doi: 10.1186/s40510-017-0192-y.
7. Poletti L., Silvera AA., Ghislanzoni LTH. Dentoalveolar class III treatment using retromolar miniscrew anchorage. *Prog Orthod* 2013;14(1):7. Doi: 10.1186/2196-1042-14-7.
8. Zimmer B., Gaida S., Dathe H. Compensation of skeletal Class III malocclusion by isolated extraction of mandibular teeth: Part 2: Skeletal, dentoalveolar and soft tissue parameters in comparison with nonextraction Class III therapies. *J Orofac Orthop* 2016;77(2):119–28. Doi: 10.1007/s00056-016-0016-6.
9. Ruellas ACDO., Baratieri C., Roma MB., Izquierdo ADM., Boaventura L., Rodrigues CS., et al. Angle Class III malocclusion treated with mandibular first molar extractions. *American Journal of Orthodontics and Dentofacial Orthopedics* 2012;142(3):384–92. Doi: 10.1016/j.ajodo.2011.01.025.
10. De Lima E., Brum F., Mezomo M., Pasquali CE., Farret M. Orthodontic treatment of Class III malocclusion with lower extraction and anchorage with mini implants: Case report. *Journal of the World Federation of Orthodontists* 2017;6(1):28–34. Doi: 10.1016/j.ejwf.2017.02.003.
11. Proffit W. *Ortodontia Contemporânea*. 6th ed. RIO DE JANEIRO, RJ: Grupo Gen; 2022.
12. Mihalik CA., Proffit WR., Phillips C. Long-term follow-up of Class II adults treated with orthodontic camouflage: A comparison with orthognathic surgery outcomes. *American Journal of Orthodontics and Dentofacial Orthopedics* 2003;123(3):266–78. Doi: 10.1067/mod.2003.43.
13. Liu H., Wu C., Lin J., Shao J., Chen Q., Luo E. Genetic Etiology in Nonsyndromic Mandibular Prognathism. *Journal of Craniofacial Surgery* 2017;28(1):161–9. Doi: 10.1097/SCS.00000000000003287.
14. Doraczynska-Kowalik A., Nelke KH., Pawlak W., Sasiadek MM., Gerber H. Genetic Factors Involved in Mandibular Prognathism: *Journal of Craniofacial Surgery* 2017;28(5):e422–31. Doi: 10.1097/SCS.00000000000003627.
15. Richardson A. Interceptive orthodontics in general dental practice. Part I--Early interceptive treatment. *Br Dent J* 1982;152(3):85–9. Doi: 10.1038/sj.bdj.4804752.
16. Artese F. A broader look at Interceptive Orthodontics: What can we offer? *Dental Press J Orthod* 2019;24(5):7–8. Doi: 10.1590/2177-6709.24.5.007-008.edt.

17. Seehra J., Newton JT., DiBiase AT. Interceptive orthodontic treatment in bullied adolescents and its impact on self-esteem and oral-health-related quality of life. *The European Journal of Orthodontics* 2013;35(5):615–21. Doi: 10.1093/ejo/cjs051.
18. Tristão SKPC., Magno MB., Pintor AVB., Christovam IFO., Ferreira DMTP., Maia LC., et al. Is there a relationship between malocclusion and bullying? A systematic review. *Prog Orthod* 2020;21(1):26. Doi: 10.1186/s40510-020-00323-7.
19. Dutra SR., Pretti H., Martins MT., Bendo CB., Vale MP. Impact of malocclusion on the quality of life of children aged 8 to 10 years. *Dental Press J Orthod* 2018;23:46–53. Doi: 10.1590/2177-6709.23.2.046-053.oar.
20. Kai R., Umeki D., Sekiya T., Nakamura Y. Defining the location of the dental midline is critical for oral esthetics in camouflage orthodontic treatment of facial asymmetry. *American Journal of Orthodontics and Dentofacial Orthopedics* 2016;150(6):1028–38. Doi: 10.1016/j.ajodo.2015.10.035.
21. Kumari L. Non-surgical Management of Skeletal Class III Malocclusion with Bilateral Posterior Crossbite: A Case Report. *JCDR* 2016. Doi: 10.7860/JCDR/2016/19752.8962.
22. Lee G-C., Yoo J-K., Kim S-H., Moon C-H. Lip line changes in Class III facial asymmetry patients after orthodontic camouflage treatment, one-jaw surgery, and two-jaw surgery: A preliminary study. *The Angle Orthodontist* 2017;87(2):239–45. Doi: 10.2319/033016-254.1.
23. Martínez P., Bellot-Arcís C., Llamas JM., Cibrian R., Gandia JL., Paredes-Gallardo V. Orthodontic camouflage versus orthognathic surgery for class III deformity: comparative cephalometric analysis. *International Journal of Oral and Maxillofacial Surgery* 2017;46(4):490–5. Doi: 10.1016/j.ijom.2016.12.001.
24. Mendes BP., Magalhães RC., Caetano RM. Preventive and interceptative orthodontics: oral health benefits. *Research, Society and Development* 2023;12(6):e23812642236–e23812642236. Doi: 10.33448/rsd-v12i6.42236.
25. Seo Y-J., Chung K-R., Kim S-H., Nelson G. Camouflage treatment of skeletal Class III malocclusion with asymmetry using a bone-borne rapid maxillary expander. *The Angle Orthodontist* 2015;85(2):322–34. Doi: 10.2319/031314-189.1.
26. Mota DTV da. *Ortodontia Preventiva e Interceptativa*. 2019.
27. Cruz KS., Janson G., Henriques JFC., Josgrilbert LF. Orthopedic-orthodontic camouflage of Class III malocclusion: a conservative approach. *Rev Clín Ortod Dent Press* 2004:61–72.

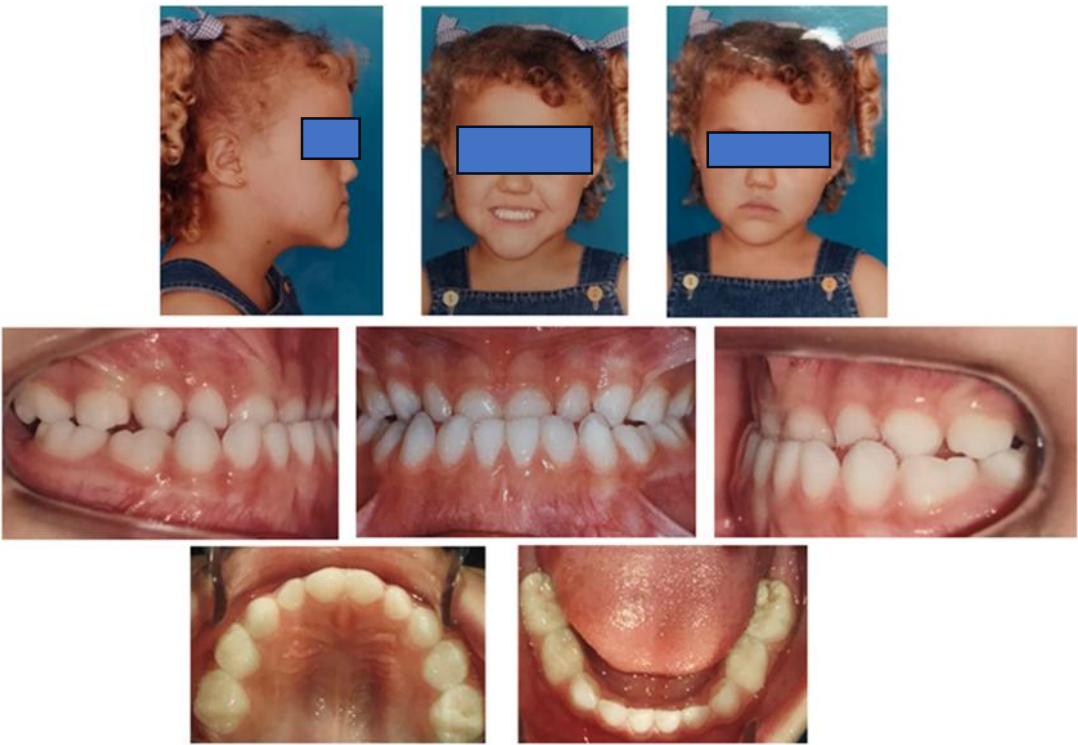

FIGURE 1. Pre-treatment facial and intraoral photographs.

UNDER PELL

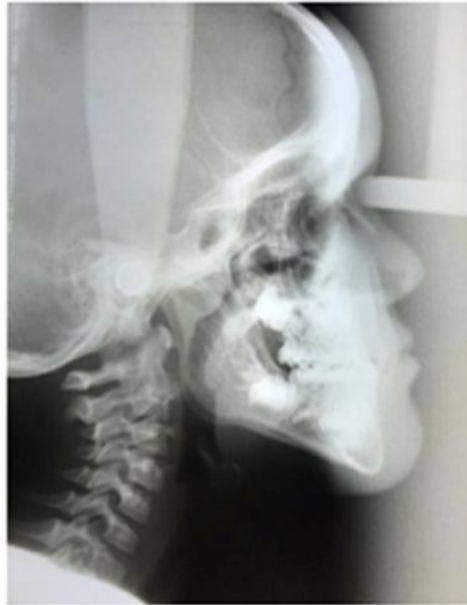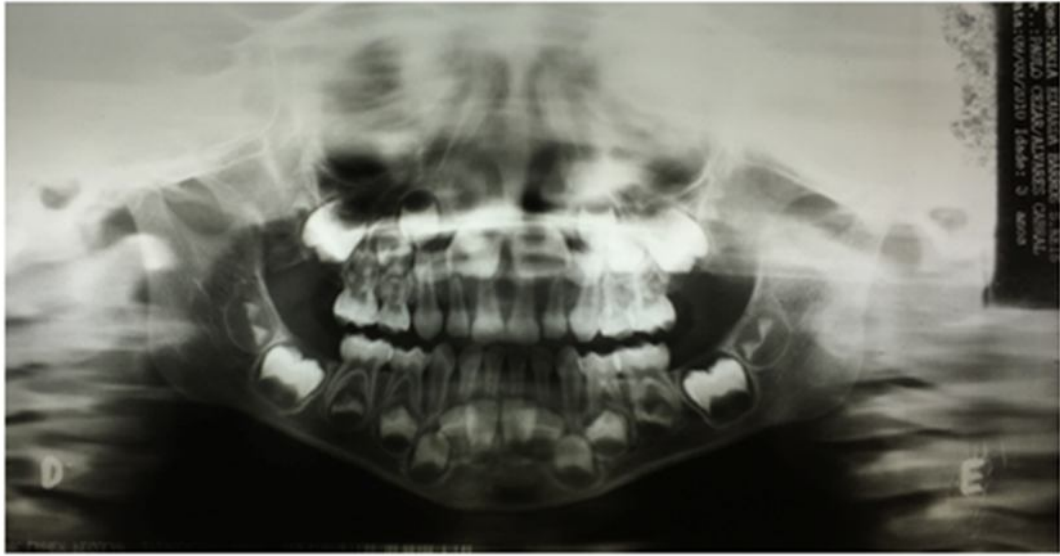


FIGURE 2.Pre-treatment panoramic and cephalometric tracing.

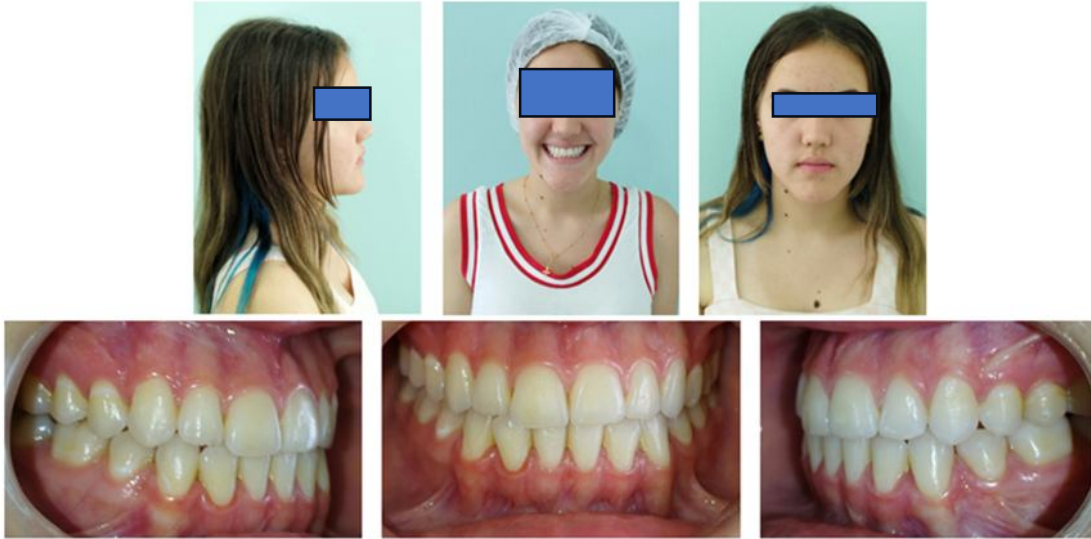

FIGURE 3. Post-treatment facial and intraoral photographs.

UNDER PEER REVIEW

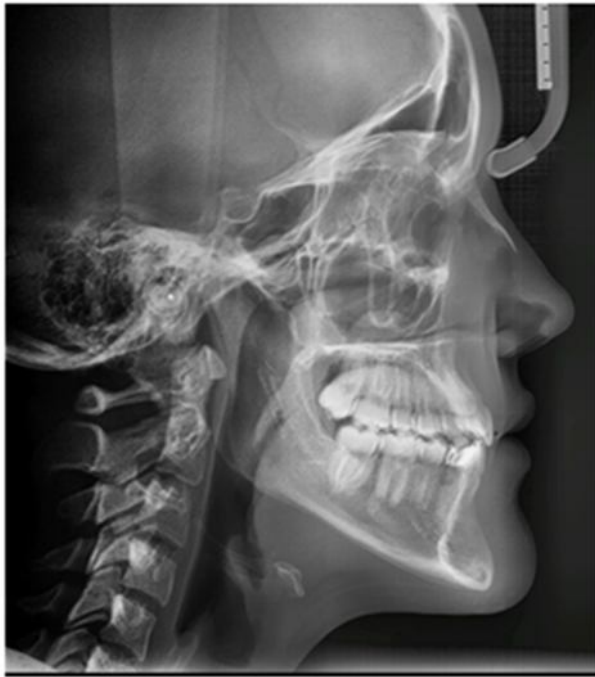
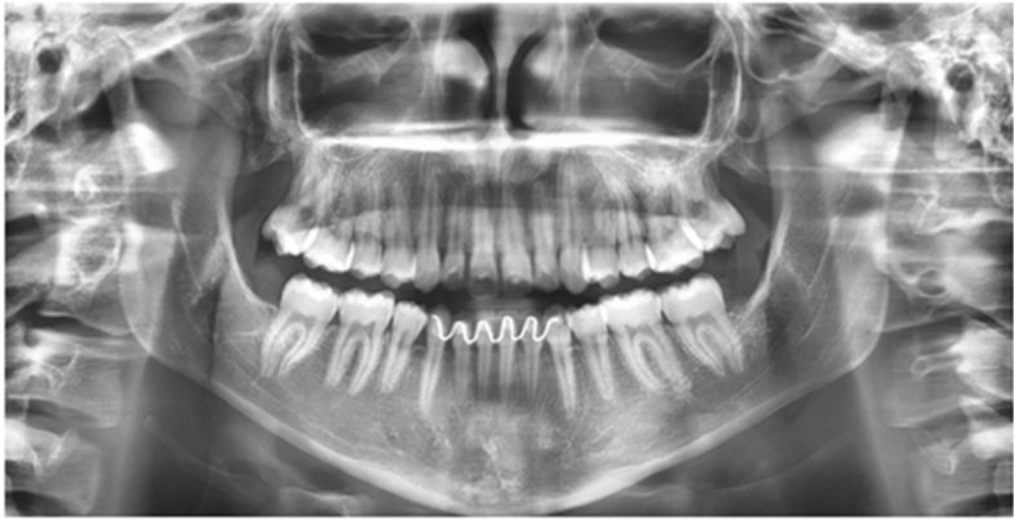
FIGURE 4. Post-treatment panoramic and cephalometric tracing.

TABLE 1. Descriptive analysis of the cephalometric variables analyzed.

CEPHALOMETRIC PARAMETERS	Initial	Final
FMA	23	25
SN. SGn	65	67
SN. GoGn	37	35
SN. Occlus	13	17
GoGn. Occlus	25	15
SNA	79	82
SNB	83	81
ANB	-1	0
SND	79	79
Facial Angle (NPog.PoOr)	94	92
Convexity angle (NA. Apog)	-6	-6
Interim Angle	133	129
I.NS	102	108
I.NA	14	33
I.NA	-1mm	6mm
IMPA	74	80
I.NB	15	18
I.NB	0mm	2mm
Nasolabial angle	87	96
H-Nose	13mm	11mm
Line S-Ls	0mm	5mm
Line S-Li	1mm	4mm