

Case report

Conservative Decompression in the Management of Odontogenic Keratocysts: case report

ABSTRACT

Aims: This study aims to assess the effectiveness of decompression as a conservative treatment for odontogenic keratocysts (OKCs), with emphasis on reducing recurrence rates, decreasing lesion size, and preserving adjacent anatomical structures. Additionally, it explores the combination of decompression with enucleation and other therapies to minimize recurrence risks.

Presentation of Case: This is a case study focusing on conservative management of OKCs using decompression, with enucleation performed when necessary.

A 15-year-old male patient with a mandibular OKC underwent decompression under local anesthesia. Preoperative radiographic evaluations were followed by aspirate puncture and placement of a thoracic drain to facilitate lesion size reduction. The patient was monitored over six months, with radiographic exams every 60 days to assess cyst shrinkage.

Discussion: The patient showed a significant reduction in lesion size following decompression, allowing for easier enucleation while preserving the bone cortex. A review of the literature supports decompression as an effective treatment; however, recurrence rates remain problematic when performed without adjunctive therapies. Combining decompression with enucleation resulted in lower recurrence rates and improved long-term outcomes.

Conclusion: Decompression is a promising conservative approach for managing OKCs, particularly when combined with enucleation and adjunctive treatments. This approach reduces lesion size and preserves critical structures, although recurrence remains a concern. Long-term follow-up and further research on recurrence mechanisms are essential to improving outcomes for patients treated with decompression for OKS.

Keywords: Odontogenic keratocyst, decompression, dental treatment.

1. INTRODUCTION

Decompression as a treatment for odontogenic keratocysts (OKCs) has been a relevant approach in managing this pathological condition. OKCs, recently reclassified as benign cystic lesions by the World Health Organization (WHO) in 2017, account for approximately 10% of lesions in the maxillofacial region, alongside other pathologies such as hamartomas, odontogenic bone cysts, and neoplasms (Vered *et al.*, 2022). The embryonic origin of OKCs is associated with remnants of the dental lamina, and their occurrence is most common in individuals aged 10 to 40, with no significant sex predilection (Jung *et al.*, 2021).

The main feature of OKCs is their aggressive behavior and high recurrence rate, attributed to factors such as the cystic epithelium's ability to grow independently and the ease with which the cyst wall separates from the adjacent connective tissue (Silva *et al.*, 2024). Clinically, most cases are asymptomatic and are discovered incidentally in routine imaging exams, such as panoramic radiographs, often presenting as a well-defined

radiolucent area and, in some cases, associated with an unerupted tooth. However, a definitive diagnosis requires clinical, radiographic, and primarily histopathological evaluation (Pogrel, 2015).

Various therapeutic approaches have been described, ranging from conservative techniques to radical surgeries. Marsupialization and simple enucleation, though common, have high recurrence rates, leading to the need for combined therapies such as peripheral ostectomy, cryotherapy, and the application of Carnoy's Solution (Chen *et al.*, 2022). In more severe cases, bone resection with a free margin is indicated, especially when there is involvement of adjacent soft tissues or rupture of the cortical bone (Ochoa *et al.*, 2023).

Surgical decompression emerges as a promising technique, allowing the creation of a communication between the cystic cavity and the oral environment, relieving internal pressure, and reducing the size of the lesion while preserving adjacent vital structures (Vallejo-Rosero *et al.*, 2020). Furthermore, decompression facilitates the total excision of the cyst by promoting the thickening of the fibrous capsule; however, its main disadvantage is the high recurrence rate, especially when performed without adjunctive treatments (Johnson *et al.*, 2013).

Histological and immunohistochemical studies on the effects of decompression in OKCs are limited, but evidence suggests that creating a large cystic communication may induce changes that increase recurrence rates, such as cellular proliferation and multiple distribution of daughter cysts in the cyst wall (Trujillo-González *et al.*, 2022). Therefore, despite its benefits in the initial reduction of lesion size and facilitation of excision, decompression requires additional care and long-term follow-up to mitigate recurrence and ensure satisfactory outcomes in the treatment of OKCs (Slusarenko da Silva *et al.*, 2019).

2. PRESENTATION OF CASE

A 15-year-old male patient with no comorbidities, ongoing medications, or allergies was initially seen at the General Surgery Clinic of the University Hospital of Western Paraná. The reason for the consultation was an increase in volume with hardened consistency upon palpation in the right mandibular body region, corresponding to the vestibular of tooth 85 (lower second deciduous molar), without spontaneous or palpation pain. Expansion of the area was noted, with preservation of the bone cortices.

Panoramic radiography revealed a radiolucent lesion in the mandibular body, involving an impacted tooth (permanent second premolar), with well-defined margins and limits. Given the presentation, the patient was referred to the UNIOESTE Dental Specialties Center for evaluation by the Oral and Maxillofacial Surgery and Trauma team.

Following clinical evaluation and imaging analysis, in conjunction with the legal guardian, an incisional biopsy and surgical decompression of the lesion were decided upon.

The procedure was performed under local anesthesia with 4% articaine and 1:100,000 epinephrine. Initially, aspirative puncture of the lesion was carried out using a 20mL syringe and hypodermic needle (40 x 1.20 mm), obtaining slightly viscous liquid with an ochre color. Subsequently, tooth 85 was extracted using forceps No. 17. Surgical access to the lesion was made through the extraction socket, with osteotomy using a 701 drill, allowing drainage of the content. Later, lateral edges of the lesion were detached using a Lucas curette, and a portion was removed for histopathological analysis using a No. 15 blade. A radiopaque thoracic drain 12Fr was placed and fixed with 4-0 nylon thread at the

center of the surgical access. The patient and his guardian were instructed to perform frequent irrigations inside the drain with 0.9% saline.

Histopathological analysis confirmed the diagnosis of odontogenic keratocyst. The patient returned for follow-up every 30 days, with new radiographic exams every 60 days for monitoring.

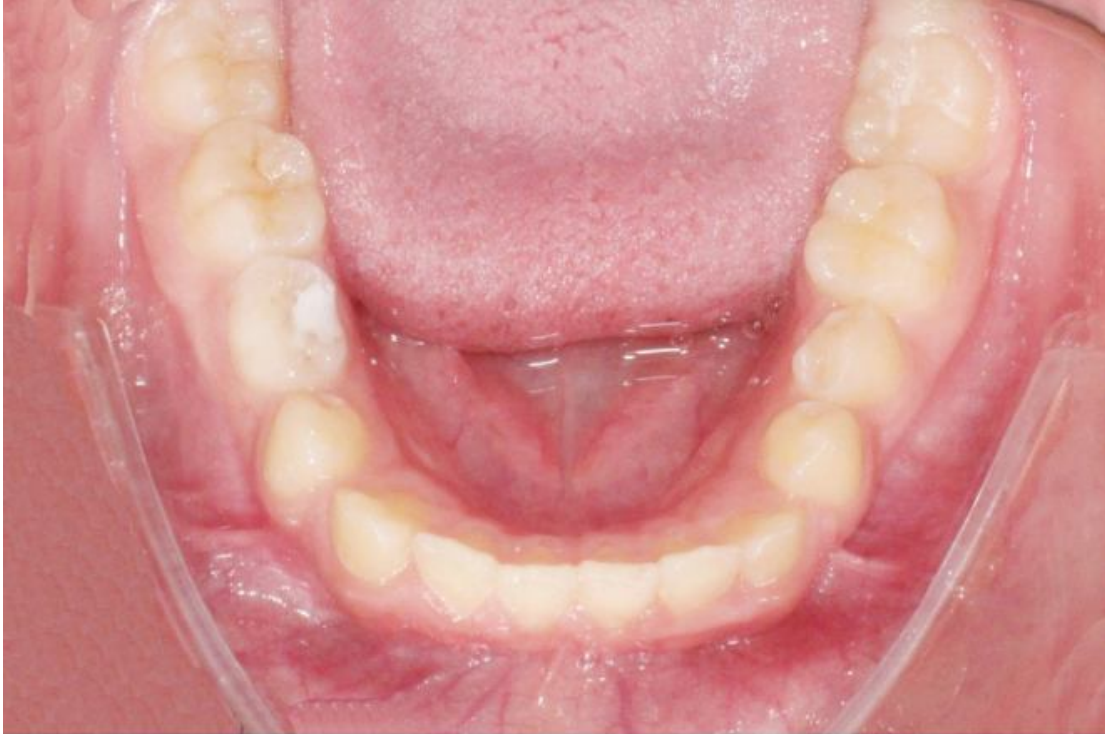

Figure 01: intraoral photos demonstrating no changes on clinical examination

UNDER

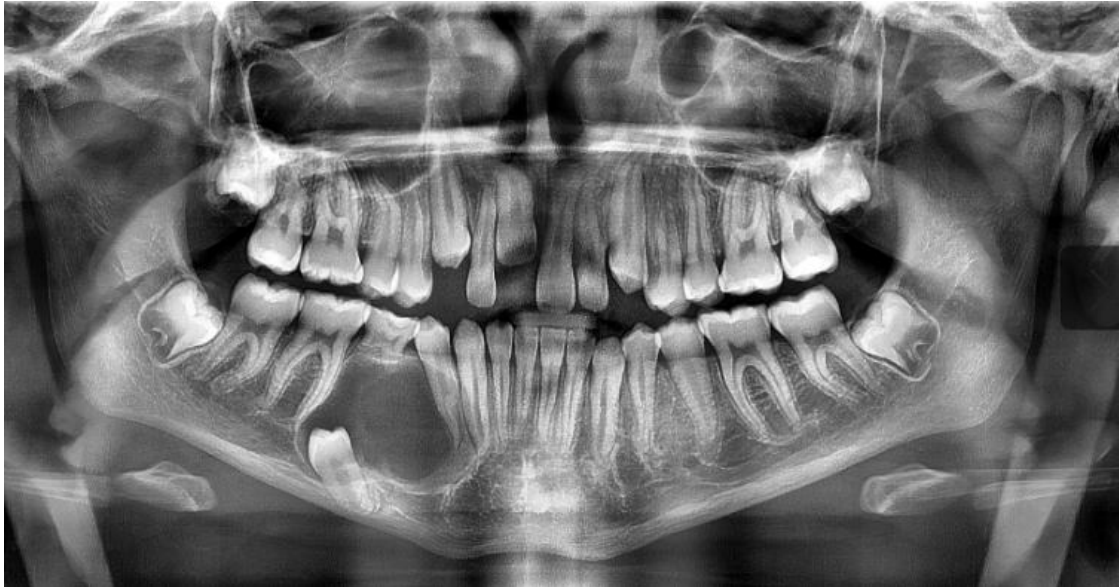

Figure 02: initial panoramic x-rays

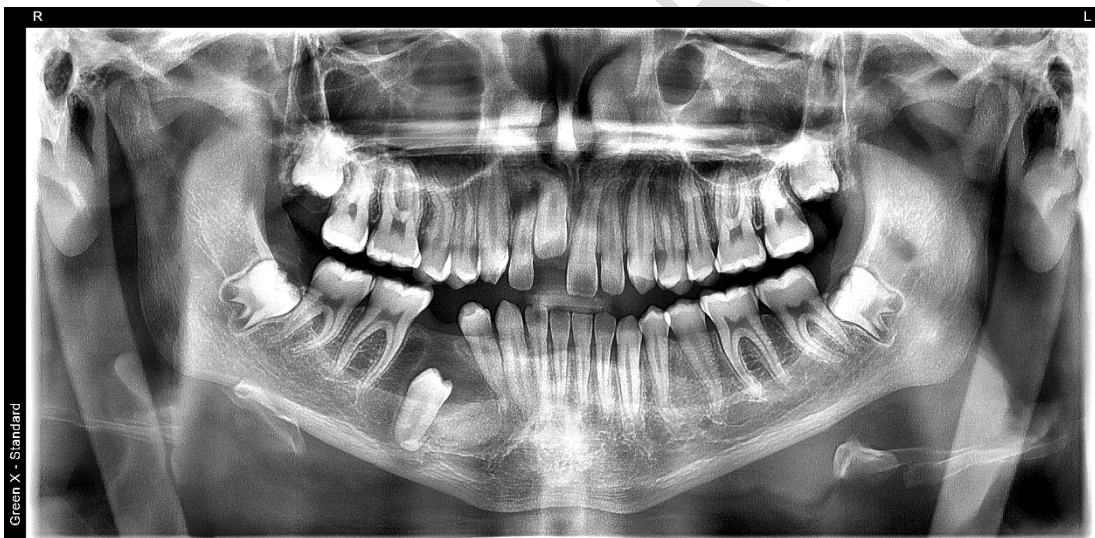

Figure 03: panoramic x-rays after 8 months, already with the decompression technique

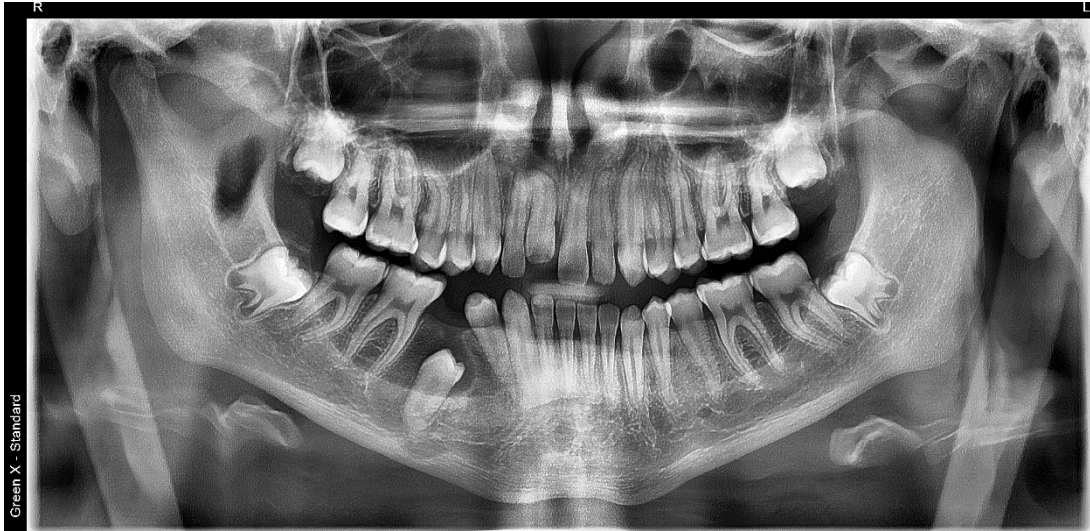


Figure 04: panoramic x-rays after 12 months

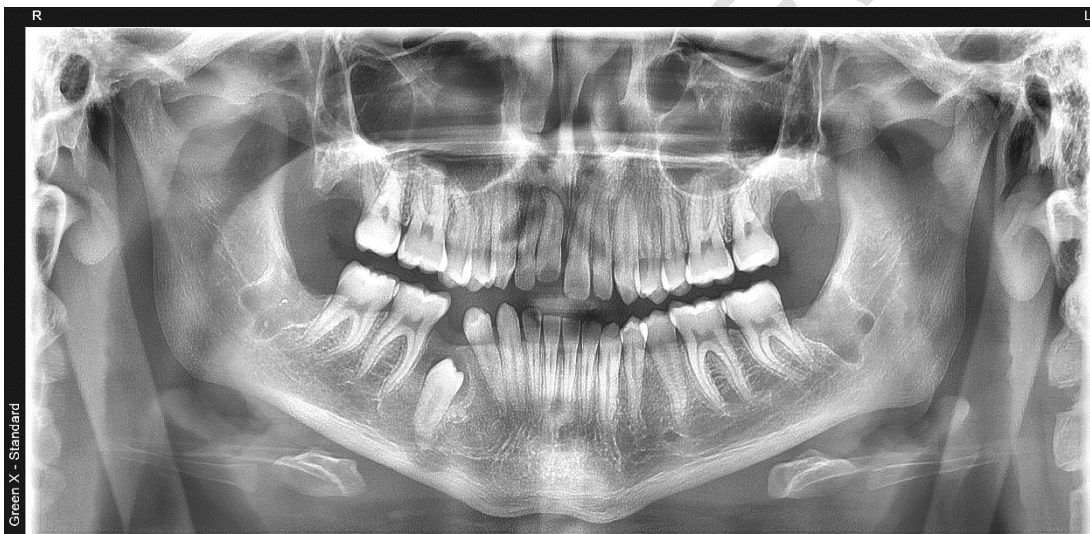

Figure 05: panoramic x-rays after 18 months

3. DISCUSSION

Initially, the odontogenic keratocyst was classified as an odontogenic tumor due to its aggressive behavior and high recurrence. However, the reclassification of OKCs as a cystic lesion by the World Health Organization (WHO) in 2017 marked a shift in the clinical and surgical approach to this pathology. The choice of treatment for OKCs typically depends on multiple factors, including the size of the lesion, its location, involvement of adjacent structures, and the risk of recurrence (Zou *et al.*, 2024).

In recent years, decompression has been promoted as a less invasive approach aimed at reducing the lesion size before a more definitive intervention, such as enucleation. This procedure involves creating a communication between the cystic cavity and the external environment, allowing for a reduction in internal pressure and the subsequent shrinking of the cyst. In countries like Brazil, where dentistry is continuously advancing and research on

minimally invasive techniques is growing, the use of decompression as an initial strategy has gained increasing popularity (Jacobs *et al.*, 2024).

Historically, decompression was considered a palliative treatment, particularly for large maxillofacial cysts and tumors, where direct surgical removal could cause significant bone defects or damage to vital structures, such as the inferior alveolar nerve. Early studies on the technique observed that decompression not only reduced the size of the lesion but also facilitated subsequent enucleation by thickening the fibrous capsule surrounding the cyst, providing greater safety for the subsequent surgical procedure (Essa, 2024).

The use of decompression as a primary method in the treatment of OKCs began to be taken more seriously after studies showed significant cystic volume reduction, along with the preservation of the integrity of nearby structures, such as teeth and the bone cortex. In Brazil, the rise in the practice of minimally invasive surgeries reflects a trend observed in dental clinics and research centers, where there is a growing pursuit of techniques that preserve function while minimizing surgical trauma (Zolfaghari *et al.*, 2024).

Decompression alters the internal physiology of the cystic cavity, leading to changes in the behavior of the cystic epithelium. Several studies suggest that by reducing intracystic pressure, decompression interferes with the mechanisms of cell proliferation in the cystic epithelium, which can result in a deceleration of cyst growth. This effect may be related to the reduction of mechanical tension that promotes cystic expansion and also to the facilitation of fibroblast recruitment to the lesion site, promoting fibrosis of the cystic capsule (Gonçalves *et al.*, 2024).

However, despite the clear benefits of decompression, there remains a high degree of controversy regarding its long-term effectiveness, especially with regard to the recurrence rate of OKCs. One hypothesis raised is that decompression may, in some cases, not be sufficient to alter the aggressive behavior of the remaining epithelium, which may continue to proliferate even after the cyst has shrunk (Desai *et al.*, 2024).

The recurrence of OKCs after decompression is one of the main clinical challenges faced by surgeons. While decompression has shown good results in terms of reducing cystic volume, its ability to prevent long-term recurrence is still questioned. Studies indicate that the modulation of the cystic epithelium induced by decompression may not be effective enough to prevent the formation of new foci of cellular proliferation. Indeed, some histological studies have revealed that the cyst wall, after decompression, can develop microcysts or "daughter" cysts, which may act as precursors for new lesions (Almeida *et al.*, 2024).

These data suggest that although decompression is a viable option to control the initial growth of the lesion and facilitate surgery, it should not be seen as a definitive treatment for all cases of OKCs. In many situations, decompression should be followed by enucleation or other complementary procedures to minimize the risk of recurrence (Nakako *et al.*, 2024).

The combination of decompression with enucleation has been widely investigated as a way to maximize the benefits of the conservative approach while minimizing the risks of recurrence. This strategy involves initially performing decompression to reduce the size of the lesion, followed by enucleation to remove the remaining cystic tissue (Jeyaraman *et al.*, 2024).

Recent studies indicate that decompression can facilitate enucleation by promoting the thickening of the fibrous capsule, making cyst removal safer and more complete.

Furthermore, combining these two techniques seems to significantly reduce the risk of recurrence compared to isolated enucleation. However, the success of this approach depends on several factors, including patient adherence to postoperative follow-up and the precise execution of surgical techniques (Liu *et al.*, 2024).

In Brazil, the use of decompression for the treatment of OKCs has been increasingly adopted in oral and maxillofacial surgery clinics. OKCs are relatively common lesions, accounting for about 10% of odontogenic cystic lesions in the maxillofacial region, making treatment choice a significant concern for dental surgeons and specialists in dentistry. Moreover, the high costs associated with more invasive approaches, such as bone resection, and the risks of surgical complications make decompression an attractive alternative for both professionals and patients (Eid *et al.*, 2024).

However, it is essential for dental surgeons to be aware of the limitations of decompression, particularly with regard to the recurrence rate and the need for long-term follow-up. The literature suggests that frequent radiographic follow-up is essential to monitor lesion evolution and identify any early signs of recurrence (Singh *et al.*, 2024).

Conservative treatment with decompression followed by enucleation emerges as a viable alternative in the management of OKCs, offering important advantages such as preserving adjacent anatomical structures and reducing surgical morbidity. However, the long-term success of this approach depends on a careful evaluation of each case, considering factors such as the size of the lesion, the biological behavior of the cyst, and the patient's ability to adhere to postoperative follow-up (Yildirimyanet *al.*, 2024).

Despite advances in decompression techniques, there is a continuous need for further research to fully understand the biological mechanisms underlying epithelial modulation induced by decompression. Moreover, the development of new therapeutic strategies, including combined therapies and the use of adjuvant pharmacological agents, may help further reduce recurrence rates and improve clinical outcomes (Zou *et al.*, 2024).

In summary, decompression offers a promising approach in the conservative management of OKCs, but it must be applied with caution and within an individualized treatment plan. Rigorous follow-up and continuous research will be essential to optimize this technique and provide better outcomes for patients suffering from this condition.

4. CONCLUSION

In conclusion, conservative treatment with decompression followed by enucleation emerges as a viable option in managing OKCs, offering advantages such as preservation of adjacent structures and lower morbidity. However, further research is needed to fully understand the mechanisms underlying epithelial modulation induced by decompression and to optimize therapeutic strategies. Long-term follow-up is essential to monitor recurrence and ensure favorable clinical outcomes for patients undergoing this type of treatment. As the understanding of OKCs and their treatment continues to evolve, integrating evidence-based approaches and individualized care will be critical in improving patient outcomes and advancing clinical practice.

CONSENT

All authors declare that 'written informed consent was obtained from the patient for publication of this case report and accompanying images.

DISCLAIMER

Author(s) hereby declares that NO generative AI technologies such as Large Language Models (ChatGPT, COPILOT, etc.) and text-to-image generators have been used during the writing or editing of this manuscript.

COMPETING INTERESTS

No conflict of interest

AUTHORS' CONTRIBUTIONS.

All authors participated, either in performing the surgical procedure or assisting in it, as well as in writing, selecting photos and reviewing the journal.

REFERENCES

1. Almeida, L. E., Loyd, D., Boettcher, D., Kraft, O., & Zammuto, S. (2024). Immunohistochemical Analysis of Dentigerous Cysts and Odontogenic Keratocysts Associated with Impacted Third Molars-A Systematic Review. *Diagnostics (Basel, Switzerland)*, 14(12), 1246.
2. Chen, P., Liu, B., Wei, B., & Yu, S. (2022). The clinicopathological features and treatments of odontogenic keratocysts. *American journal of cancer research*, 12(7), 3479–3485.
3. Desai, K. M., Tanaka, Y., Angadi, P. V., Kheur, S. M., Puranik, U., Tatsumi, A., Sekikawa, S., & Nomura, T. (2024). Characterization of stromal calcifications in odontogenic keratocyst: a multicentric study. *Odontology*, 10.1007/s10266-024-00975-5.
4. Eid, M. K., Alqhtani, N. R., Atef, A. M., & Sakka, S. (2024). Application of topical 5-Fluorouracil to reduce the recurrence of odontogenic keratocyst: A prospective study with 2-year follow-up. *Current problems in surgery*, 61(9), 101558.
5. Essa A. A. M. (2024). Downregulation of connexin 43 is crucial for basal cell alignment in ameloblastoma and odontogenic keratocyst. *The Saudi dental journal*, 36(7), 990–994.
6. Gonçalves, T. O. F., Rangel, R. M. R., Marañón-Vásquez, G. A., Soares-Silva, L., Agostini, M., Abrahão, A. C., Romañach, M. J., & Maia, L. C. (2024). Management and recurrence of the odontogenic keratocyst: an overview of systematic reviews. *Oral and maxillofacial surgery*, 10.1007/s10006-024-01277-4.
7. Jacobs, T., Patil, D., Shanti, R., & Ziccardi, V. B. (2024). Comparing 5-Fluorouracil Versus Modified Carnoy's Solution for the Treatment of Odontogenic Keratocysts: A Systematic Review and Meta-Analysis. *Journal of oral and maxillofacial surgery*

:official journal of the American Association of Oral and Maxillofacial Surgeons, S0278-2391(24)00591-3. Advance online publication.

8. Jeyaraman, P., Anbinselvam, A., & Akintoye, S. O. (2024). Differentially expressed extracellular matrix genes functionally separate ameloblastoma from odontogenic keratocyst. *BMC oral health*, 24(1), 1084.
9. Johnson, N. R., Batstone, M. D., & Savage, N. W. (2013). Management and recurrence of keratocystic odontogenic tumor: a systematic review. *Oral surgery, oral medicine, oral pathology and oral radiology*, 116(4), e271–e276.
10. Jung, H. D., Lim, J. H., Kim, H. J., Nam, W., & Cha, I. H. (2021). Appropriate follow-up period for odontogenic keratocyst: a retrospective study. *Maxillofacial plastic and reconstructive surgery*, 43(1), 16.
11. Liu, H., Zhou, N., & Huang, X. (2024). The application of wing-shaped window decompression device in the treatment of large odontogenic keratocyst: An observational study. *Medicine*, 103(36), e39601.
12. Nakako, Y., Hasegawa, K., Fujii, S., Kami, Y., Sakamoto, T., Sakamoto, M., Moriyama, M., Kurppa, K. J., Heikinheimo, K., Yoshiura, K., Kawano, S., & Kiyoshima, T. (2024). Wnt/ β -catenin-YAP axis in the pathogenesis of primary intraosseous carcinoma NOS, deriving from odontogenic keratocyst. *Pathology, research and practice*, 260, 155420.
13. Ochoa Moreira, J. A., Reinoso Quezada, S. J., & Molina-Barahona, M. (2023). Técnicas para el tratamiento del queratoquiste, revisión de la literatura y presentación de un caso [Techniques for the treatment of keratocyst, review of the literature and case report]. *Revista científica odontologica (Universidad Científica del Sur)*, 11(2), e159.
14. Pogrel M. A. (2015). The keratocystic odontogenic tumour (KCOT)--an odyssey. *International journal of oral and maxillofacial surgery*, 44(12), 1565–1568.
15. Shah, S. J., Tandon, S., Ratnani, C., Sonwani, I., & Bishal, J. (2024). Calcifying Epithelial Odontogenic Cysts of the Anterior Maxilla: Report of Two Cases. *Cureus*, 16(7), e65392.
16. Silva, V. T., de Campos, W. G., Leone, C., de Abreu Alves, F., & Lemos, C. A. (2024). Which devices can be used to decompress odontogenic cystic lesions in the oral cavity? A systematic review. *The British journal of oral & maxillofacial surgery*, S0266-4356(23)00609-5. Advance online publication.
17. Singh, H. P., Chahal, G. K., Sharma, G., & Gandhi, P. (2024). A systematic review on odontogenic cysts and tumours. *Journal of oral and maxillofacial pathology : JOMFP*, 28(2), 268–274.
18. Slusarenko da Silva, Y., Stoelinga, P. J. W., & Naclério-Homem, M. D. G. (2019). Recurrence of nonsyndromic odontogenic keratocyst after marsupialization and delayed enucleation vs. enucleation alone: a systematic review and meta-analysis. *Oral and maxillofacial surgery*, 23(1), 1–11.

19. Trujillo-González, D., Villarroel-Dorrego, M., Toro, R., Vigil, G., Pereira-Prado, V., & Bologna-Molina, R. (2022). Decompression induces inflammation but do not modify cell proliferation and apoptosis in odontogenic keratocyst. *Journal of clinical and experimental dentistry*, 14(1), e100–e106.
20. Vallejo-Rosero, K. A., Camolesi, G. V., de Sá, P. L. D., & Bernaola-Paredes, W. E. (2020). Conservative management of odontogenic keratocyst with long-term 5-year follow-up: Case report and literature review. *International journal of surgery case reports*, 66, 8–15.
21. Vered, M., & Wright, J. M. (2022). Update from the 5th Edition of the World Health Organization Classification of Head and Neck Tumors: Odontogenic and Maxillofacial Bone Tumours. *Head and neck pathology*, 16(1), 63–75.
22. Yildirimyan, N., Altay, M. A., & Özbudak, İ. H. (2024). Can CAPRIN-1 Be Responsible for the Recurrence Potential of Odontogenic Keratocysts?. *Journal of oral & maxillofacial research*, 15(2), e4.
23. Zolfaghari, R., Bijani, F., Seyedmajidi, S., & Seyedmajidi, M. (2024). Lymphangiogenesis in Odontogenic Keratocysts Compared with Dentigerous Cysts. *Journal of dentistry (Shiraz, Iran)*, 25(2), 118–124.
24. Zou, B., Ding, S. X., Ru, L., An, F. X., & Li, Y. G. (2024). Odontogenic Keratocyst in Maxillary Sinus with Ectopic Third Molar: A Case Report. *The American journal of case reports*, 25, e944543.