

Platelet-rich fibrin associated with laser biostimulation in the treatment of multiple recessions: a randomized, double-blind clinical study.

ABSTRACT

Introduction: Gingival recession can cause functional and aesthetic problems, and surgical treatment is often indicated. The use of advanced platelet-rich fibrin (A-PRF) and low-power laser therapy (LLLT) has shown considerable efficacy. **Objective:** This study evaluated the effectiveness of using A-PRF in combination with LLLT for root coverage in patients with multiple recessions. **Methodology:** This was a split-mouth, parallel-group, randomized, double-blind study. It was carried out in the dental clinics of the State University of Western Paraná (UNIOESTE), in Cascavel-PR, Brazil, between March/2022 and July/2024. 56 recessions were divided into the Control Group: coronally positioned flap using A-PRF membranes and the LASER Group: coronally positioned flap using A-PRF membranes associated with LLLT. The patients underwent root coverage periodontal surgery associated with A-PRF and on one side of the arch low-power laser was applied postoperatively in 5 sessions: immediately after surgery, 2, 4, 6, and 8 days after the surgical procedure. The patients were followed up for 0, 90, and 180 days to check clinical periodontal parameters, after which the data was subjected to parametric and non-parametric statistical tests, with a 5% significance level considered for all analyses. **Results:** In both groups, there were improvements in root coverage and keratinized tissue thickness in the periods evaluated ($p < 0.05$), but no statistical difference when comparing the groups ($p > 0.05$). **Conclusion:** Both the use of A-PRF and A-PRF combined with LLLT provided satisfactory results in covering multiple recessions, although there was no significant superiority between the two treatments.

Keywords: Platelet Rich Fibrin, Low-Intensity Light Therapy, Gingival Retraction, Oral Surgery, PRF, LLLT.

INTRODUCTION

The gingiva is made up of connective tissue and a superficial epithelial layer. It can be differentiated into three parts: free gingiva, inserted gingiva, and interdental gingiva. In various situations, the free gingiva can move in an apical direction, which is defined as gingival recession [1,2].

Gingival recession is often found in people with an excellent standard of oral hygiene, and the main causal factor is trauma, related to vigorous tooth brushing [2], as well as other factors such as alveolar bone dehiscence, high muscle insertion, and frenulum. Still, it can also be involved with poor hygiene such as plaque and calculus and periodontal disease. Other factors that can lead to recession are iatrogenic factors such as excessive restorations, and periodontal and orthodontic treatment [1].

In 2011, a classification of gingival recession based on interproximal level of insertion was described [2]: *Type 1 recession (RT1)*: recession of the vestibular tissue without loss of interproximal insertion; *Type 2 recession (RT2)*: recession of the buccal tissue associated with interproximal attachment loss less than or equal to buccal attachment loss; *Type 3 recession (RT3)*: buccal tissue recession associated with interproximal attachment loss greater than buccal attachment loss.

Gingival recession can cause negative effects, both functionally, such as increased susceptibility to root caries and dentin hypersensitivity, and aesthetically, and most of the times surgical treatment is indicated to cover the exposed root. Many treatments have been described in the literature and although the gold standard is still the use of autologous connective tissue, the use of advanced platelet-rich fibrin (A-PRF) has been shown to be just as effective, with the advantage of not needing a donor area, favoring the postoperative period for the patient [1,3]. The use of A-PRF, first implemented by Choukroun et al. in 2011, has become increasingly popular among dental surgeons, because it is a cluster of platelets, growth factors, leukocytes, and other forms of circulating cells embedded in a fibrin matrix, elements that aid healing, in addition to its proliferative effect on various types of cells [4]. These characteristics make it a healing biomaterial and it is therefore used to enhance soft tissue healing in periodontal surgery, implants, and also for intraosseous repairs and bone regeneration [5,6,7].

A-PRF is formed by collecting blood and centrifuging it. This processing separates blood components such as red blood cells that are not used, and concentrates the components used for therapy into a dense fibrin network that slowly releases growth factors, which optimizes healing properties [5,7,8]. It is a significantly simple, low-cost procedure that is easy to use and autologous in nature, which favors its clinical application [8].

Another adjuvant that has been used to increase the proliferation of mesenchymal stem cells and regulate the growth factors that participate in periodontal tissue regeneration and assist in tissue regeneration is Low-Level Laser Therapy (LLLT) [8]. The word laser stands for *light amplification of stimulated emission of radiation*, which means light amplification by stimulated emission of radiation, which, as the name implies, is a form of radiation found in the light spectrum ranging from infrared to ultraviolet, passing through the visible spectrum [9,10].

Low-intensity lasers are considered photobiomodulators and they are used for tissue repair as they can stimulate angiogenesis, regeneration, and cell growth. In addition to its anti-inflammatory and analgesic effect, promoting greater patient comfort and optimizing treatments [10,11].

After surgery, a cascade of regenerative events takes place, passing through the inflammatory, proliferative, and remodeling phases. Low-Level Laser Therapy (LLLT) on connective tissue helps the healing process, as it increases fibroblast synthesis and vascularization of the region due to neovascularization, as well as benefiting the patient with anti-inflammatory effects, controlling edema, and analgesics [11,12]. Studies have shown that the use of LLLT and A-PRF in combination has produced better results than when used individually [8,13]. For this reason, this study aims to assess whether the combination of both therapies is more effective in covering Cairo type I gingival recession than when A-PRF alone is used.

METHODOLOGY

This was a parallel randomized split-mouth prospective study, which followed CONSORT protocol that incorporates a checklist of requirements for randomised controlled trials.

To calculate the sample size, the number of patients was based on the paired T-test, with a test power of 80% and an alpha level of 0.05. These data were also based on previous studies [14, 15]. The sample size was 21 recessions. After the initial clinical periodontal examination and preparation of the patients, each received split-mouth treatment according to the proposed treatments.

For this study, 10 patients were selected (1 man and 9 women) who had multiple bilateral Cairo type 1 gingival recession in at least one arch, with recessions varying between 2 and 5 millimeters in height and between 2 and 4 millimeters in width, and were randomized by drawing lots, in which only the laser operator knew which hemiarch would receive which treatment, being randomly allocated to the Control Group (CG) and the Laser Group (LG), as shown in the flowchart (Fig 1).

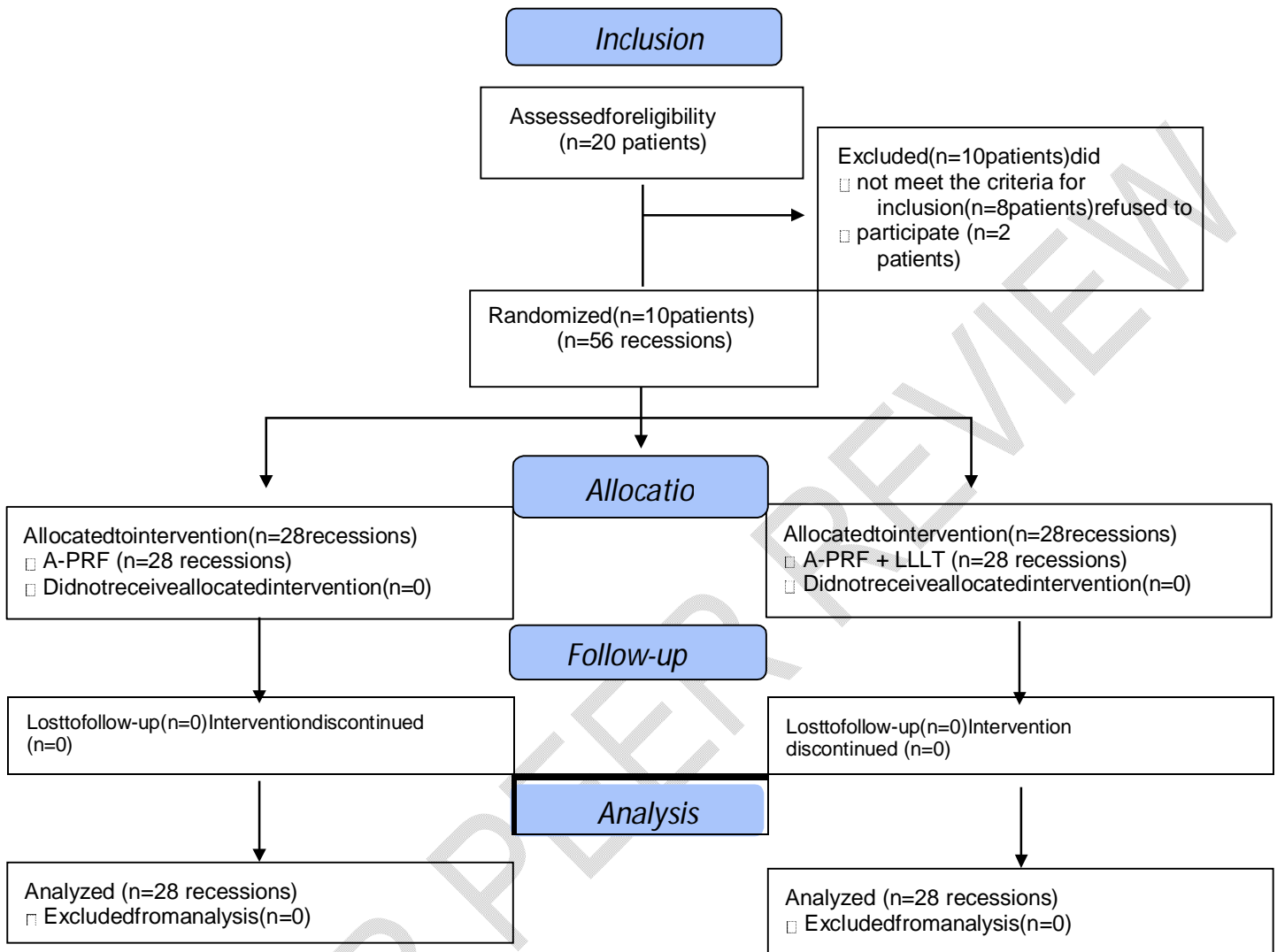


Figure 1: CONSORT 2010 flowchart.

Criteria for inclusion

Patients aged between 19 and 50 years of both sexes with bilateral multiple recessions in at least two arches and healthy teeth, with all sites showing a probing depth of less than or equal to 3mm, with a bleeding index of less than or equal to 5%, without gingival inflammation and free of caries.

Criteria for exclusion

Patients with a positive history of antibiotic therapy in the last six months and of anti-inflammatory drugs, whether steroidal or non-steroidal, in the three months prior to the study; a positive history of pregnancy during the study period; a positive history of smoking or permanent cessation of the habit within five (5) years; a positive history of any systemic problem that would contraindicate the surgical procedure; endodontic treatment or pulp pathology in the tooth involved; pathogenic occlusal interferences and previous surgery at the site. Each patient's medical history was obtained through anamnesis and all participants underwent a clinical examination.

Periodontal preparation of individuals

All patients received basic periodontal treatment and oral hygiene instruction. Periodontal treatment was carried out by a single operator with manual instrumentation under the effect of local anesthesia for patients with periodontitis using Gracey 5/6, 7/8, 11/12, and 13/14 periodontal curettes.

Clinical Periodontal Assessment

The clinical/periodontal examination was carried out initially and then 90 and 180 days after the procedure. The evaluations were carried out by a previously trained investigator who used a Willians type 23 periodontal probe to determine: Probing depth and bleeding on probing; Clinical insertion level; O'Leary Plate Index [16]; Width of the keratinized tissue; Height and width of the recession; Thickness of keratinized gingival tissue at 3 points (mesial, central, and distal);

Patients were assessed for the degree of dentin sensitivity in the region of recession using the modified U.S. Public Health Service Index consists of three scores: 0 (Alpha) - no sensitivity; 2 (Bravo) - little sensitivity; 3 (Charlie) - high sensitivity [17,18].

Surgical procedures

For the surgical procedure, the duly trained researcher performed the surgeries using the coronally positioned flap technique associated with the use of Platelet Rich Fibrin (A-PRF) membranes [19].

The protocol for obtaining A-PRF was divided into three stages [4]: Stage 1: Venipuncture and blood collection: Before the surgical procedure for root coverage began, around 50 mL of blood was venipunctured (depending on the length of the recipient bed). The puncture was carried out by a qualified professional (nurse), duly trained for this procedure. The venipuncture protocol followed the recommendations of the Ministry of Health, with a Vacuum Collection device, following the steps: Screw the needle into the adapter (cannon). Adjusting the tourniquet and choosing the vein; antiseptics of the collection site with absorbent cotton moistened in 70% alcohol or alcohol. Perform the puncture (approximately 50 mL to 80 mL). Insert the tube into the holder, pressing it as far as it will go; release the tourniquet as soon as the blood starts to flow in the tube; instruct the patient to press the punctured part with absorbent cotton, keeping the arm extended without bending it.

Stage 2: Cell separation (centrifugation): The blood was immediately taken to the centrifuge (Centrifuge LC-04P-L), in 10 mL portions. The fibrin membranes were obtained by centrifugation at 1300 rpm for 14 minutes. At the end of the centrifugation, the tubes were collected and the fibrin was not removed immediately. They were left for 30 minutes or more before being used on the surgical bed.

Stage 3: Preparing the A-PRF membranes: Using the kit for making stainless steel A-PRF membranes (Intra-Luck®), the centrifuged intermediate portion, the fibrin clot, was separated from the red cell portion and the platelet-poor plasma and placed in the stainless steel box, and the compressive lid was applied without tightening it. The weight itself (130g) is enough to compress the clot and obtain the membranes, without damaging the cellular structures present in the fibrin mesh.

Preparation of the receptor bed and insertion of the A-PRF membranes [22]

The recipient area was anesthetized with infiltrative terminal anesthesia, using the anesthetic Mepivacaine 2% with Epinephrine 1:100,000 (DFL, Rio de Janeiro, RJ, Brazil). An incision was made with a 15c blade (SOLIDOR®, Suzhou Kyuan Medical Apparatus Co. Ltd., Suzhou City, Beiqiao Town, China). The incisions were horizontal intrasulcular, at the level of the cemento-enamel junction (CEJ), mesial and distal to the teeth involved, and oblique relaxing incisions, with the epithelium of the papillae removed. A partial-thickness flap was made over the mucogingival line so that a tension-free flap was obtained. The A-PRF membranes (3 membranes at each recession site) were positioned over the recession, immediately coronary to the CEJ, and sutured

proximally with resorbable polyglycolic acid thread (BIOLINE, Anápolis, Goiás, Brazil). The flap was then repositioned and sutured over the graft with nylon 6.0 thread (SHALON São Luis M. Belos, Goiás, Brazil).

UNDER PEER REVIEW

Laser application protocol

Each patient underwent surgery in at least two hemiarcs, one of which was subjected to the photobiomodulation protocol and the other to a placebo application, to simulate the application of the laser at the site. The laser was applied by a second operator so that the study could be characterized as double-blind. There were 5 sessions: immediately after surgery, 2, 4, 6, and 8 days after the surgical procedure, making it possible to compare the surgical response without inert systemic repair bias in each patient [21]. The laser used for the study was the portable Laser Duo Optics (MMO, São Carlos, São Paulo, Brazil) which contains two wavelengths in the same device (red and infrared). The red laser was used, with a power of 100 mW, an applied energy of 3 J, and an application time of 30 seconds per point, with five points in the receiving area [13].

Control and post-operative evaluations:

The patients were assessed for a total period of 180 days, and clinical examinations were carried out at 0, 90, and 180 days [14]. During all periods, the patients received maintenance therapy, and all the criteria of the initial periodontal assessment were reassessed. After the 180-day trial period, all patients were included in a periodontal maintenance program.

Analysis Statistics:

Statistical analysis was carried out using the GraphPad Prism 8.0[®] program. All the clinical data obtained was analyzed and evaluated initially using the SHAPIRO-WILK test to check for normal distribution, followed by the ANOVA and TUKEY tests. The FRIEDMAN test was used to analyze the pain parameter. A T-test was used to compare the final means. A 5% significance level was used for all analyses.

RESULTS

A total of 56 Cairo type gingival recessions were evaluated, 28 in the control group and 28 in the laser group. There were 10 patients, 1 male and 9 females with ages ranging from 19 to 50 and a mean of 41.14 ± 10.81 years, all of whom received the two proposed treatments (A-PRF and A-PRF + LLLT) in different hemiarcs. There were 30 gingival recessions on anterior teeth (53.57%) and 28 gingival recessions on posterior teeth (46.43%). In terms of arches, 23 of the gingival recessions were located in the upper arch (41.08%) and 33 in the lower arch (58.92%). The average coverage in the A-PRF group was 55.21% and in the A-PRF+LLLT group 52.72%.

In the statistical evaluation, the data showed a significant intra-group improvement in the aspects of bleeding on probing, clinical insertion level, plaque index, the width of keratinized tissue, height, width, and thickness of the recession and sensitivity, although there was no statistically significant difference when comparing the Control and Laser groups.

Table 1: Comparative analysis of the periodontal parameters of the Control Group in the initial, 90-day, and final periods

	PRE-SURGERY	90 DAYS AFTER SURGERY	180 DAYS POST-SURGERY
MPD (MM)	2.75±0.52A	2.86±0.36A	2.78±0.20A
VPD (MM)	2.75±0.44A	2.93±0.26A	2.89±0.31A
DPD (MM)	2.71±0.53A	2.82±0.39A	2.68±0.48A
MEDIAPD(MM)	2.73±0.30A	2.86±0.16A	2.78±0.20A
PB(%)	4.90±0.48A	2.6±0.26B	2.1±0.21B
CIN(MM)	5.89±1.26A	4.61±1.17B	4.36±0.68B
PI(%)	21.36±9.67A	7.85±2.67B	7.14±2.67B
KTW(MM)	2.73±0.36A	3.25±0.33B	2.95±0.34C
RH (MM)	3.17±1.33A	1.64±1.16B	1.42±0.63B
RW(MM)	3.07±0.53A	1.50±0.88B	1.43±0.42B
GT(MM)	1.08±0.19A	1.48±0.34B	1.35±0.26B
SENS	0.42±0.79A	0.00±0.00B	0.00±0.00B

MPD: Mesial Probing Depth; VPD: Buccal Probing Depth; DPD: Distal Probing Depth; MEDIAPD: Average Probing Depth of the sites; PB: Probing Bleeding; CIN: Clinical Insertion Level; PI: Plaque Index; KTW: Keratinized Tissue Width; RH: Recession Height; RW: Recession Width; GT: Gingival Thickness; Sens: Sensitivity Index. Different letters mean that they are statistically different within each treatment group ($p < 0.05$) over the evaluation periods.

Table 2: Comparative analysis of the periodontal parameters of the Laser Group in the initial, 90-day, and final periods

	PRE-SURGERY	90 DAYS AFTER SURGERY	180 DAYS POST-SURGERY
MPD (MM)	2.93±0.47A	2.96±0.19A	2.96±0.19A
VPD (MM)	2.64±0.49A	2.89±0.31A	2.82±0.39A
DPD (MM)	2.79±0.50A	2.93±0.26A	2.93±0.26A
MEDIAPD(MM)	2.78±0.34A	2.92±0.16A	2.90±0.19A
PB(%)	2.10±0.21A	0.01±0.06B	0.10±0.15B
CIN(MM)	5.89±0.99A	4.75±1.35B	4.32±1.06B
PI(%)	21.86±9.67A	8.57±2.53B	7.14±2.67B
KTW(MM)	2.96±0.45A	3.27±0.36B	3.20±0.28B
RH (MM)	3.32±1.12A	1.64±1.28B	1.57±0.95B
RW(MM)	2.92±0.53A	1.28±0.85B	0.92±0.76B
GT(MM)	1.07±0.17A	1.51±0.34B	1.48±0.28B
SENS	0.35±0.82A	0.07±0.37AB	0.00±0.00B

MPD: Mesial Probing Depth; VPD: Buccal Probing Depth; DPD: Distal Probing Depth; MEDIAPD: Average Probing Depth of the sites; PB: Probing Bleeding; CIN: Clinical Insertion Level; PI: Plaque Index; KTW: Keratinized Tissue Width; RH: Recession Height; RW: Recession Width; GT: Gingival Thickness; Sens: Sensitivity Index. Different letters mean that they are statistically different within each treatment group ($p < 0.05$) over the evaluation periods.

Table 3: Comparative analysis of the variation (difference from 0 - 180 days) of the periodontal parameter values of the Control Group and the Laser Group

	CONTROL	LASER
MPD (MM)	-0.03±0.50A	-0.03±0.50A
VPD (MM)	-0.14±0.35A	-0.17±0.54A
DPD (MM)	0.03±0.30A	-0.14±0.52A
MEDIAPD(MM)	-0.04±0.19A	-0.11±0.51A
CIN(MM)	1.53±1.23A	1.57±0.99A
KTW(MM)	-0.22±0.36A	-0.23±0.40A
RH(MM)	1.68±1.19A	1.75±0.75A
RW(MM)	1.96±0.73A	2.00±0.94A
GT(MM)	-0.25±0.31A	-0.41±0.30A

MPD: Mesial Probing Depth; VPD: Buccal Probing Depth; DPD: Distal Probing Depth; MEDIAPD: Average Probing Depth of the sites; CIN: Clinical Insertion Level; KTW: Keratinized Tissue Width; RH: Recession Height; RW: Recession Width; GT: Gingival Thickness. Different letters mean that they are statistically different within each treatment group ($p < 0.05$) over the evaluation periods.

DISCUSSION

The use of techniques to cover areas where tissue has been lost in the oral cavity is a possibility that has been complemented over the years with the use of biomaterials. Gingival recession is a prevalent condition in the population and, for its coverage, the most commonly used substitutes are of autogenous origin, with subepithelial connective tissue grafting as the gold standard. Currently, platelet derivatives have been gaining prominence, such as advanced platelet-rich fibrin (A-PRF). This study sought to assess whether the combined use of A-PRF membrane and LLLT would bring better results for the treatment of Cairo type I recession since both treatments stimulate cell proliferation, and angiogenesis and accelerate healing [8].

A-PRF has been widely studied and is increasingly used in clinical practice for root coverage. It stands out because it is an autologous fibrin gel, rich in platelets and leukocytes, and because it interacts with growth factors (GF), which are essential for the healing process. The positive effects of A-PRF have been attributed to its various growth factors (especially PDGF, VEGF, and TGF), cytokines, glycoprotein structures, and especially the dense network of the fibrin matrix (100x larger than normal) which increases and promotes angiogenesis and matrix synthesis. A-PRF, when compared to L-PRF in immunohistochemical analysis, showed a lower density fibrin network, with cells spread more evenly in the clot, with a greater quantity of platelets and progenitor cells, as well as promoting a slower and greater release of growth factors, which can promote an improvement in tissue regeneration [22,23].

Tables 1 and 2 of this study show a statistically significant improvement in the recession pattern treated with A-PRF with or without LLLT and in both periods evaluated. This corroborates the results of other studies [6,24,25,26], which compared A-PRF to the use of connective tissue grafting, considered the gold standard, and found similar results for both groups, with the use of A-PRF implying less post-operative discomfort for patients.

However, when analyzing the results shown in Table 3, it can be seen that despite the significant improvement in Cairo type I recessions, the use of A-PRF associated with LLLT did not show significantly superior results when compared to the group using A-PRF alone. These results coincide with those obtained by Thalaimalai et al. (2020) [8], who compared both treatments for the correction of intraosseous

defects.

Low-intensity laser has numerous applications in all fields of science, making it an attractive alternative for dentistry. Laser therapy is considered non-invasive and has few side effects, producing immediate responses, such as pain reduction, and delayed responses, involving collagen biosynthesis [27]. Even today, there is not abundance literature pondering the benefits of using LLLT in the recovery process after periodontal plastic surgery. The success of periodontal plastic surgery depends mainly on patient-related issues, for example oral hygiene, traumatic toothbrushing related to the site, interdental bone level, width and depth of recession, flap thickness, and postoperative gingival margin. All these factors subsequently affect the healing of the post-operative wound, which depends on coagulation, revascularization, and maintenance of the blood supply to the surgical area. It is possible that the application of LLLT may have some immediate post-operative beneficial effects on these healing factors, accelerating wound healing, increasing the motility of human keratinocytes promoting early epithelialization, increasing fibroblast proliferation and matrix synthesis, and improving neovascularization [28].

There is a wide range of protocols for using LLLT described and their intensities can bring different results, since the response to the laser is dose-dependent, requiring the correct dose and time of application for the photobiomodulation stimulus to occur. Cells have a minimum threshold, so it is necessary to reach this threshold to start a stimulus and the maximum threshold must not be exceeded, because if an intensity greater than the ideal is emitted, bioinhibition occurs by suppressing the stimulus [13]. Studies show that doses between 3-6 J/cm² are more effective and that doses above 10 J/cm² are associated with deleterious effects [29].

This study used a power of 100 mW, an applied energy of 3 J, and an application time of 30 seconds per point, but Silva Freitas et al. (2021) [11] showed that the energy density of 4 J/cm² associated with the red wavelength of 658 nm obtained better results for the healing of skin wounds [11]. Sleem et al. (2019) [30] found no statistically significant difference in bone density or implant stability using A-PRF associated with 9 J/cm² and 830 nm LLLT. However, Ozturan et al. (2011) [28] carried out a randomized controlled clinical study using 588 nm LLLT in the coronally advanced flap technique, applying it to the test sites before and immediately after surgery and for 5 minutes daily 7 days postoperatively. The results showed that the test group had greater complete root coverage compared to the control group, and greater predictability after one year. However, corroborating the findings of Almeida et al. (2009) [31], who used 10 J/cm², the results of the present study, within its limitations such as the number of recessions evaluated, as well as the follow-up time for healing, showed that gingival recession coverage using A-PRF did not show statistically significant superiority when used in conjunction with low-intensity laser therapy. Further studies are needed to establish a photobiomodulation protocol that favors improved root coverage when associated with the use of A-PRF.

CONCLUSION

This study concludes that both the use of A-PRF and A-PRF associated with LLLT brought satisfactory results for covering Cariotypel recession, but there was no significant superiority between the two treatments.

CONSENT AND ETHICAL APPROVAL

Human Research Ethics Committee of Unioeste, under number 58903022.4.0000.0107. The study was performed in the University Clinics. All patients received the informed consent form to sign.

REFERENCES

1. Rothen SK, Silva EO, Bin LR, Nassar PO, Nassar CA. Clinical comparison of two surgical techniques in the treatment of Cairo RT2 gingival recessions associated with subepithelial connective tissue graft: randomized clinical trial. *J Adv Med Med Res* 2022;171–181. Available:<https://doi.org/10.9734/jammr/2022/v34i234851>
2. Cairo F, Nieri M, Cincinelli S, Mervelt J, Pagliaro U. The interproximal clinical attachment level to classify gingival recessions and predict root coverage outcomes: An explorative and reliability study. *J Clin Periodontol* 2011;38:661–666.
3. Neves FLS, Silveira CA, Santamaria IFM, Miguel MMV, Ferraz LFF, Casarin RCV, Sallum EA, Tatakis DN, Santamaria MP. A randomized clinical trial evaluating single maxillary gingival recession treatment with connective tissue graft and tunnel or trapezoidal flap: 2-year follow-up. *J Periodontol* 2020; 91(8): 1018-1026.
4. Choukroun J, Ghanaati S. Reduction of relative centrifugation force within injectable platelet-rich-fibrin (PRF) concentrates advances patients' own inflammatory cells, platelets and growth factors: the first introduction to the low speed centrifugation concept. *Eur J Trauma Emerg Surg* 2018; 44: 87-95.
5. Dohan Ehrenfest DM, Andial, Zumstein MA, Zhang CQ, Pinto NR, & Bielecki T. Classification of platelet concentrates (Platelet-Rich Plasma-PRP, Platelet-Rich Fibrin-PRF) for topical and infiltrative use in orthopedic and sports medicine: current consensus, clinical implications and perspectives. *Muscles Ligaments Tendons J* 2014;4(1): 3-9.
6. Hegde S, Madhurkar JG, Kashyap R, Kumar MSA, Bloor V. Comparative evaluation of vestibular incision subperiosteal tunnel access with platelet-rich fibrin and connective tissue graft in the management of multiple gingival recession defects: a randomized clinical study. *J Indian Soc Periodontol*. 2021;25:228–236.
7. Arakeeb M, Zaky AA, Harhash TA, Salem WS, El-Mofty M. Effect of Combined Application of Growth Factors and Diode Laser Bio-Stimulation on the Osseointegration of Dental Implants. *Maced J Med Sci* 2019;7(15):2520-2527.
8. Thalaimalai D, Victor DJ, Prakash P, Subramaniam S, Cholan PK. Effect of Low-Level Laser Therapy and Platelet-Rich Fibrin on the Treatment of Intra-bony Defects. *J Lasers Med Sci* 2020;11(4):456-463.
9. Neves LS, Silva CMDS, Henriques JFC, Cançado RH, Henriques RP, Janson G. Lasers in Orthodontics. *Rev. Dent. Press Ortodon. Ortop* 2005;10:149-156. *In portuguese*
10. Santos LTO, Santos LO, Guedes CDCFV. Laser Therapy in Dentistry: effects and applicability. *Scientia Generalis* 2021; 2(2): 29-46. *In portuguese*
11. da Silva Freitas KAB, Minicucci EM, de Lima TO, da Silva KAB, Menozzi BD, da Silva VFB, Popim RC. Effects of photobiomodulation (low-intensity laser) on wound healing: an integrative review. *Res Soc Develop* 2021;10(11) e362101119821-e362101119821. *In Portuguese*
12. Dharani K, Kshirsagar JT, Thangavel P. Comparative evaluation of the effectiveness of concentrated growth factor alone and in combination with diode laser application in the treatment of intrabony periodontal defects: A clinical and radiographic split-mouth study. *J Dent Res Dent Clin Dent Prospects*. 2024;18(2):143-151. doi: 10.34172/joddd.40781. Epub 2024 Jun 24. PMID: 39071208; PMCID: PMC11282198.

13. Souza Fonseca RR, Silva CP, de Senna Sastre BL, Tanaka EB, Carvalho TRB, de Oliveira PGFP, de Menezes SAF, Laurentino RV, de Oliveira RP, de Oliveira RP, Lago ADN, Almeida Machado LF. Clinical Evaluation of Bilateral Multiple Gingival Recession Treatment with Autogenous Connective Tissue Graft Associated with Low-Level Laser Therapy. *J Clin Med.* 2023; 17;12(6):2349. doi: 10.3390/jcm12062349. PMID: 36983349; PMCID: PMC10052819.
14. Nassar CA, Silva WAD da, Tonet K, Secundes MB, Nassar PO. Comparing semilunar coronally positioned flap to standard coronally positioned flap using periodontal clinical parameters. *Gen Dent.*2014;62:47–49
15. Tonet K, BombardelliCG, Bussmann LF, Secundes MB, Nassar CA, Nassar PO. Evaluation of different techniques of coverage root to health periodontal tissues. *Perionews.*2010;4:473–477. *In portuguese*
16. O'Leary TJ, Drake PB, Naylor JE. The plaque control record. *J Periodontol* 1972;43:38.
17. Bayne SC, Schmalz G. Reprinting the classic article on USPHS evaluation methods for measuring the clinical research performance of restorative materials. *Clin Oral Investing* 2005;9(4): 209-214.
18. Camilotti V, Zilly J, Busato PMR, Nassar CA, Nassar PO. Desensitizing treatments for dentin hypersensitivity: a randomized, split-mouth clinical trial. *Braz Oral Res* 2012; 26(3):263-268.
19. Spada VJ, Nassar PO, Cardoso N, Caldato KM, Pandini JH, Randon DM, Nassar CA. Root Coverage in Miller Classes I and II associated with Subepithelial Connective Tissue Graft: A comparative Clinical Trial of Two Techniques. *World J Dent* 2017; 8 (4):248-254.
20. Aroca S, Keglevich T, Barbier B, Gera I, Etienne D. Clinical Evaluation of a Modified Coronally Advanced Flap Alone or in Combination With a Platelet-Rich Fibrin Membrane for the Treatment of Adjacent Multiple Gingival Recessions: A 6-Month Study. *J Periodontol*, 2009; 80(2):244-252.
21. Brassolatti P, Bossini PS, Oliveira MC, Kido HW, Tim CR, Almeida-Lopes L, De Avó LR, Araújo-Moreira FM, Parizotto NA. Comparative effects of two different doses of low-level laser therapy on wound healing third-degree burns in rats. *Microsc Res Tech.* 2016;79(4):313-320. doi: 10.1002/jemt.22632. Epub 2016 Feb 8. PMID: 26853699.
22. Ghanaati S, Booms P, Orlowska A, Kubesch A, Lorenz J, Rutkowski J, Les C, Sader R, Kirkpatrick CJ, Choukroun J. Advanced platelet-rich fibrin: A new concept for cell-based tissue engineering by means of inflammatory cells. *J Oral Implant* 2014;40(6), 679– 689.
23. Isobe K, Watanebe T, Kawabata H, Kitamura Y, Okudera T, Okudera H, Uematsu K, Okuda K, Nakata K, Tanaka T, Kawase T. Mechanical and degradation properties of advanced platelet-rich fibrin (A-PRF), concentrated growth factors (CGF), and platelet-poor plasma-derived fibrin (PPTF). *Int J Implant Dent.* 2017; 3(1), 4–9.
24. Bin LR, Miola AEZ, Nassar PO, Vanolli R da S, Pritsch RK, Nascimento MG do, Foltz KRB, Nassar CA. Evaluation of Advanced Platelet-Rich Fibrin Associated with Zucchelli Technique in the Treatment of Cairo Type 1 Gingival Recession: Randomized Clinical Trial. *J. Adv. Med. Med. Res.* 35(7):29-43. Disponível em: <https://journaljammr.com/index.php/JAMMR/article/view/4987>
25. Carrera TMI, Machado LM, Soares MTR., Passos GP, Oliveira GJPD, Ribeiro NV, Pigossi

SC. Root coverage with platelet-rich fibrin or connective tissue graft: a split-mouth randomized trial. *Braz Oral Res* 2023;37, e084.

26. Öncü E. The Use of Platelet-Rich Fibrin Versus Subepithelial Connective Tissue Graft in Treatment of Multiple Gingival Recessions: A Randomized Clinical Trial. *Int J Periodontics Rest Dent*. 2017;37(2):265–71.
27. Nogueira JES, Gonçalves LAB, Alvarado AIS, Sousa ZS, Silveira P. Action of low-frequency laser therapy in the control of inflammatory parameters in Dentistry: Integrative review. *Rev Diálogos Acad* 2022;11: 42-45.
28. Özturan S, Durukan SA, Özcelik O, Seydaoglu G, Haytac MC. Coronally advanced flap adjunct with low-intensity laser therapy: a randomized controlled clinical pilot study. *J Clin Periodontol* 2011;38(11):1055-1062.
29. Andrade FSSD, Clark RMO, Ferreira ML. Effects of low-level laser therapy on wound healing. *Rev. Col. Bras. Cir* 2014;41:129-133.
30. Sleem, SSMEB, Zayet, MK, El-Ghareeb, TI, Saleh, HAK. Evaluation of The Bio-Stimulatory Effect of Platelet Rich Fibrin Augmented by Diode LASER Compared to Platelet Rich Fibrin Alone on Dental Implant Replacing Posterior Mandibular Teeth. Randomized Clinical Trial: Split Mouth Study. *Maced J Med Sci* 2019;7 (5), 869 -875.
31. Almeida AL, Esper LA, Sbrana MC, Ribeiro IW, Kaizer RO. Utilization of low-intensity laser during healing of free gingival grafts. *Photomed Laser Surg* 2009;27:561–564.