

# Takayasu Arteritis and its Complications: A Report on Two Rare Cases from a Tertiary Healthcare Center in Southern India

## Abstract

**Aim:** We report two cases of Takayasu arteritis that presented to our tertiary health care center, at the cardiology OP.

**Presentation:** The first case illustrates the disease's involvement of the renal arteries, which presented acutely during its early stages in a young female. The second case involves long-term neurological issues that might manifest in a confirmed case of TA.

**Discussion:** Takayasu arteritis (TA) is a rare kind of chronic granulomatous inflammatory vasculitis involving large vessels, commonly affects Asian women under the age of 40. The incidence of this disease ranges from 0.3 to 3.3 million per year, and its manifestations can range from being asymptomatic to causing catastrophic neurological impairments. They varied greatly in terms of their clinical features and age at presentation.

**Conclusion:** These cases show the wide variety of presentations of TA in the Indian population and provide insight into management of the same.

Keywords: Takayasu Arteritis, pulseless disease, systemic inflammatory disease

## Introduction :

Known more popularly as "pulseless disease," Takayasu arteritis (TA) is a systemic inflammatory disease of the medium and large arteries predominantly occurring in young Asian women. Inflammation leads to arterial wall thickening, stenosis, and thrombus formation, resulting in ischemia [1].

The most common manifestations include diminished or absent pulses associated with limb claudication, blood pressure discrepancies, and vascular bruits commonly affecting the carotid, subclavian, and abdominal vessels. Other recognized but less frequently manifesting features of the disease include hypertension, retinopathy, aortic regurgitation, and congestive cardiac failure [2].

The etiology of TA is largely unknown. One of the most commonly accepted theories suggests inflammatory granulomatous vasculitis, causing transmural fibrous thickening of the arterial walls. Elastic fiber degeneration can result in the loss of medial smooth muscle cells and the formation of aneurysms. Cell-mediated immunity assists in creating granulomas and may activate different proteases, including matrix metalloproteinase (MMP), as well as other cells that promote the development of fibrosis and chronic inflammation. B lymphocytes may produce auto-antibodies against aortic, cardiolipin, and endothelial antigens, which prolong inflammation and add to the inflammatory process. There has also been speculation on a possible connection to specific human leukocyte antigens (HLA) [3].

## Case Presentation

### Case 1:

An 18-year-old female presented to the cardiology OP with complaints of giddiness in the past week, accompanied by occasional palpitations and headaches. She took telmisartan for her hypertension, which was recently detected. Blood pressure in both arms, in the supine position from the brachial artery, read 190/110 mmHg. The radial pulse was 86/min, with a regular rhythm and normal character, having a normal vessel wall condition with no radio-radial or radio-femoral delay. Examination of all the peripheral pulses revealed no other significant abnormalities. The examination of the chest and precordial areas was clear, except for a non-specific systolic murmur. The initial workup was normal. An ECG performed was indicative of left ventricular hypertrophy (LVH). USG-Doppler imaging of bilateral renal arteries showed the main and segmental arteries exhibiting delayed peaks and parvus tardus waveforms, indicating the possibility of vasculitis. Subsequently, a CT aortogram was carried out, and the results showed circumferential smooth muscle thickening and decreased caliber of the abdominal aorta with narrowing of the celiac axis, SMA, and bilateral renal arteries at the origin with multiple abdominal wall collaterals. Thereafter, a 2D echo was performed, revealing global hypokinesia of the left ventricle with moderate LV systolic dysfunction and grade II diastolic dysfunction. Finally, angiography was done, which showed 90% stenosis of the right renal artery, 80% stenosis of the left renal artery, and 10\*7 mm stenosis of the ascending aorta. It was, hence, determined that the patient had Type V Takayasu arteritis as it involved the aorta and renal arteries. Given that the indications for revascularization were present, peripheral angioplasty of bilateral renal arteries was performed. Medical intervention in the meantime involved management of hypertension. There was no significant consultation involving other departments. The patient was subsequently discharged in stable condition.

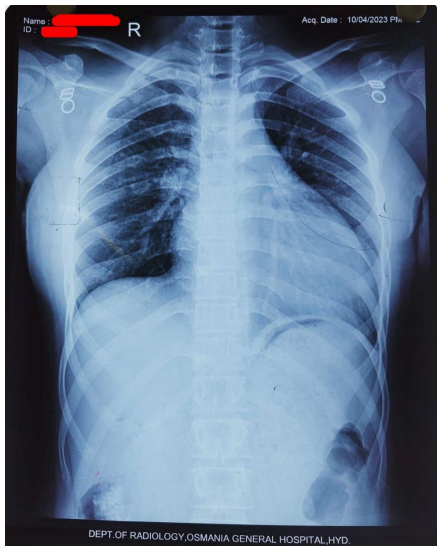


Figure 1- X-ray, PA view of chest showing Cardiomegaly in Case 1.

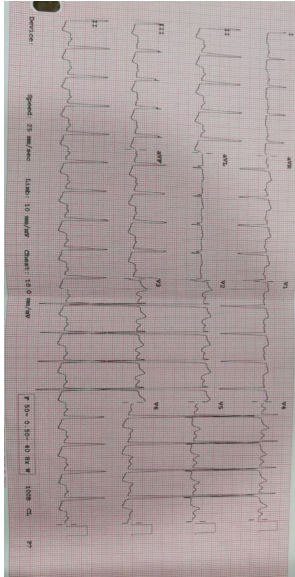


Figure 2- ECG shows left ventricular hypertrophy with strain in Case 1.

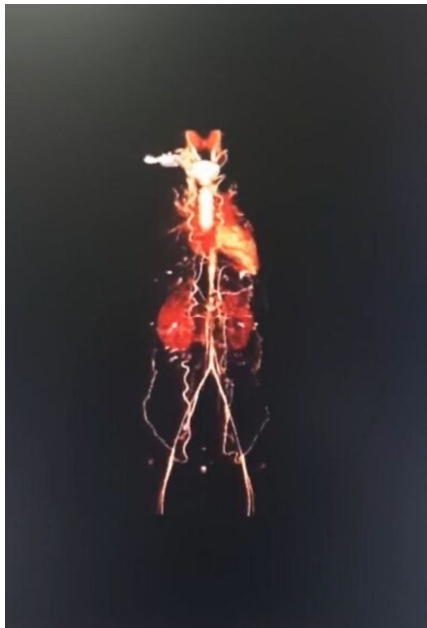


Figure 3- CECT Aortography showing circumferential smooth mural thickening of the abdominal aorta with narrowing of the celiac axis, and bilateral renal arteries at origin in Case 1.

### Case 2:

A 38-year-old female, who was a known case of Takayasu Arteritis, presented to the OP with complaints of weakness in the right upper limb and right lower limb for the last 3 months. The weakness was marked in the proximal muscles and was accompanied by a tingling sensation in the right upper and lower limbs. She had a history of similar complaints 8 years ago, where she was diagnosed as having had a cerebrovascular accident secondary to Takayasu arteritis and was relieved by taking medication. Her pulse could not be palpated bilaterally in the carotid, brachial, radial, popliteal, and dorsalis pedis arteries. Her blood pressure measured 130/80 mm Hg in both her right and left upper limbs when recorded in the supine position. On examination for power in her upper limbs, it was 4/5 in the right upper limb as compared to 5/5 in the muscles of the left upper limb. A circumduction gait was observed in her lower limbs. However, the bilateral plantar reflexes were normal. Her lab tests revealed no significant findings. Given her current history, a residual weakness from an old CVA or restroke was suspected. Doppler studies revealed bilateral homogenous thickening of the common, external, and internal carotid arteries, with a decrease in the diameter of all arteries. The left common carotid had an echogenic thrombus up to the bifurcation, and a partial thrombus was noted in the left external carotid artery as well. A parvus tardus waveform was noted in the left common carotid artery, while a reduced velocity of flow was noted in the right common carotid artery. Doppler studies of the upper limb arteries revealed decreased pulsatility. The CT brain showed hypodensity in the left cingulate gyrus, suggesting a chronic infarction. The history and imaging studies were strongly suggestive of Takayasu arteritis. The patient was managed conservatively and started on 10 mg of Apixaban orally for 1 week. Subsequently, she was discharged in a stable condition.

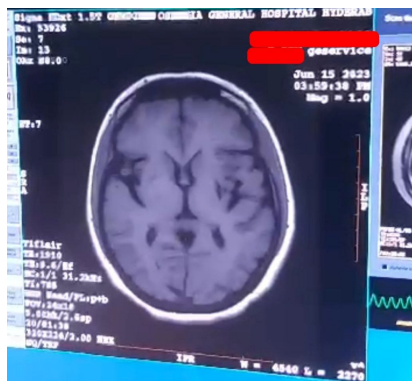


Figure 4- CT scan of the brain shows chronic infarct, seen as ill-defined hypodensity in the region of the left cingulate gyrus in Case 2.

## Discussion

Takayasu Arteritis mainly involves the aorta and its main branches with a female preponderance and age of onset being between 20-40 years of age. While the disorder may occur in adult males as well, it is at a higher age of onset when compared to females and is associated with more complications [4]. The clinical features of TA initially include nonspecific symptoms such as low-grade fever, malaise, arthralgia, unexplained weight loss and fatigue making it difficult to diagnose during the early stages of the disease. As the disease progresses, TA may cause segmental stenosis, occlusion, dilatation, or aneurysm formation in the vessel wall, eventually causing ischemic symptoms such as asymmetric, diminished or absent pulse, hypertension, renal bruit, syncope and seizures [5]. Laboratory findings frequently revealed raised ESR, CRP and hypergammaglobulinemia. Potential complications include Takayasu retinopathy aortic regurgitation, and aneurysm formation that can further deteriorate the patient's condition [6].

The pathophysiology of Takayasu arteritis (TA) remains unclear, with its etiology still unknown. Histologically, TA is marked by granulomatous vasculitis affecting medium and large arteries, leading to fibrous thickening and vascular obstructions, ultimately causing ischemia. An unidentified trigger is believed to initiate this process by inducing heat shock protein 65, which activates Major Histocompatibility Class 1 (MHC-1) on vascular cells, stimulating T lymphocytes. These cells, along with macrophages, produce pro-inflammatory cytokines and giant cells. B lymphocytes further contribute by generating auto-antibodies targeting vascular antigens. Human leukocyte antigens (HLA), particularly HLA-B52 and B39 in Japan and HLA-DR B1-1301/1302 in Mexico, have been associated with TA. A potential link with Mycobacterium tuberculosis has been proposed but lacks strong evidence, though heat shock protein-65 homology may play a role [7].

In the two cases reported by us, the first case presented with constitutional symptoms and a recent history of hypertension. Every test result was normal, but an unexpected ECG revealed LVH. Given the clinical presentation, our patient was promptly screened by a bilateral renal artery doppler, and on further probing, TA could be diagnosed when a CT aortogram was performed. Consequently, an angiogram showed significant stenosis involving bilateral renal arteries.

The incidence of renal artery stenosis in TA is 28%-75%. India and the Far East have higher rates of renal artery stenosis in TA, where the prevalence of types 3 and 4 (involving the abdominal aorta) is higher. Hypertension occurs due to excessive renin, angiotensin II, and aldosterone activity in response to reduced renal perfusion. If intervention is delayed, it may result in drug-resistant hypertension and ischemic nephropathy, which may be difficult to treat following endovascular treatments or surgery [8].

The second case, however, revealed the absence of peripheral pulses, despite a stroke-

like presentation in a known case of Takayasu arteritis with paralysis in the right upper and lower limbs. Even though it was assumed that there was residual weakening from an earlier CVA, Doppler scans of the left common carotid artery revealed that TA was the root cause. Given that TA patients are young and relatively free from atherosclerotic risk factors except hypertension and dyslipidemia, vascular inflammation may be an important risk factor for stroke [9]. According to an MRI analysis done by Hwang et al, most of the ischemic lesions were located at middle cerebral artery branches or in the internal/cortical border-zone area. The finding that large lobar, cortical border zones, and large deep infarctions were common stroke types suggests that a thromboembolic mechanism underlies stroke in TA [10].

Some conditions with overlapping symptoms that can make diagnosis challenging without thorough investigation include Giant Cell Arteritis, Behçet's disease, and infectious aortitis. Some non vasculitis-related conditions with similar presentation are Fibromuscular Dysplasia, Antiphospholipid Syndrome, and Sarcoidosis. However, they also have several other distinguishing features that can help differentiate them from Takayasu arteritis [3].

#### Management-

For clinical imaging in TA, Digital Subtraction Angiography (DSA), has long been regarded as the gold standard. However, the emergence of noninvasive diagnostic imaging such as ultrasonography, CT-Angiography (CTA), and MR-Angiography (MRA) has significantly shortened the time from onset to diagnosis.

<sup>18</sup>F-FDG PET has recently demonstrated the ability to accurately measure the extent and localize inflammation, indicating its promise as a promising imaging modality for the identification of prestenotic lesions in patients exhibiting normal CTA or MRA findings

#### Treatment-

The various modalities of therapy include glucocorticoids, cytotoxic agents such as methotrexate and azathioprine, and anti-TNF alpha antibody analogs such as infliximab and etanercept for patients refractory to conventional therapies.

Reconstructive vascular surgery and percutaneous procedures (stents, PTA) have been used to treat symptomatic vascular lesions that have not responded well to medicinal therapy. Indications for reconstructive vascular surgery in patients with TA include symptoms occurring secondary to cervico-cranial vessel stenosis, coronary artery disease, severe aortic regurgitation or stenosis, hypertension with renal artery stenosis, limb claudication, and progressive aneurysmal enlargement [5]. As our first patient experienced symptoms due to renal artery stenosis, the decision to perform angioplasty was made.

#### Conclusion

Takayasu's arteritis has a wide and non-specific range of presentation, along with an obscure etiology and pathophysiology, making it difficult to diagnose at an early stage. This leads to a worsening of the prognosis and complications necessitating the use of invasive procedures such as revascularization and bypass surgeries, in addition to medical therapies such as glucocorticoids, cytotoxic agents, and TNF- $\alpha$  inhibitors during the later stages of the disease.

Hence, it is imperative for larger organizations to conduct further research for a deeper understanding of the pathophysiology and etiology of this disease, to work up TA-

specific biomarkers that may help in early diagnosis, and to enhance strategies for long-term management of the disease and its complications.

#### Disclaimer (Artificial intelligence)

##### Option 1:

Author(s) hereby declare that NO generative AI technologies such as Large Language Models (ChatGPT, COPILOT, etc.) and text-to-image generators have been used during the writing or editing of this manuscript.

##### Option 2:

Author(s) hereby declare that generative AI technologies such as Large Language Models, etc. have been used during the writing or editing of manuscripts. This explanation will include the name, version, model, and source of the generative AI technology and as well as all input prompts provided to the generative AI technology

Details of the AI usage are given below:

- 1.
- 2.
- 3.

#### Ethical Approval:

As per international standards or university standards written ethical approval has been collected and preserved by the author(s).

### Consent

As per international standards or university standards, patient(s) written consent has been collected and preserved by the author(s).

### References

- 1) Bhandari S, Butt SRR, Ishfaq A, Attaallah MH, Ekhtor C, Halappa Nagaraj R, Mulmi A, Kamran M, Karski A, Vargas KI, Lazarevic S, Zaman MU, Lakshmi Priya Vetrivendan G, Shahzed SMI, Das A, Yadav V, Bellegarde SB, Ullah A. Pathophysiology, Diagnosis, and Management of Takayasu Arteritis: A Review of Current Advances. *Cureus*. 2023 Jul 29;15(7):e42667. doi: 10.7759/cureus.42667. PMID: 37525862; PMCID: PMC10386905.
- 2) Johnston SL, Lock RJ, Gompels MM. Takayasu arteritis: a review. *J Clin Pathol*. 2002 Jul;55(7):481-6. doi: 10.1136/jcp.55.7.481. PMID: 12101189; PMCID: PMC1769710.
- 3) Trinidad B, Surmachevska N, Lala V. Takayasu Arteritis. 2023 Aug 8. In: *StatPearls [Internet]*. Treasure Island (FL): StatPearls Publishing; 2024 Jan—. PMID: 29083666.
- 4) Virmani1, M., Ortega, L., Salman, L., Vachharajani, T., Asif, A., & Nayer, A. (2013). Takayasu's Arteritis: An Uncommon Cause of Renal Artery Stenosis and Therapeutic

Considerations. In *The Open Urology & Nephrology Journal* (Vol. 6, Issue 1, pp. 14–19). Bentham Science Publishers Ltd. <https://doi.org/10.2174/1874303x01306010014>

5) Yu H, Liu W, Zhang Y, Yan X, Li N, Ti Y, Bu P. A Case Report: An Elderly Male Patient With Takayasu Arteritis After Coronary Artery Bypass Grafting. *Front Cardiovasc Med*. 2021 Nov 23;8:766574. doi: 10.3389/fcvm.2021.766574. PMID: 34888365; PMCID: PMC8649718.

6) Guo, JiGuang MMeda; Zhang, GuoWu MD b; Tang, Dan MMeda; Zhang, JianBin MD a,\*. A case report of Takayasu arteritis with aortic dissection as initial presentation. *Medicine* 96(45):p e8610, November 2017. | DOI: 10.1097/MD.00000000000008610

7) Vaideeswar P, Deshpande JR. Pathology of Takayasu arteritis: A brief review. *Ann Pediatr Cardiol*. 2013 Jan;6(1):52-8. doi: 10.4103/0974-2069.107235. PMID: 23626437; PMCID: PMC3634248

8) Li Cavoli G, Mulè G, Vallone MG, Caputo F. Takayasu's disease effects on the kidneys: current perspectives. *Int J Nephrol Renovasc Dis*. 2018 Aug 15;11:225-233. doi: 10.2147/IJNRD.S146355. PMID: 30147353; PMCID: PMC6101009.

9) Mirouse A, Deltour S, Leclercq D, Squara P-A, Pouchelon C, Comarmond C, et al. Cerebrovascular Ischemic Events in Patients With Takayasu Arteritis [Internet]. Vol. 53, *Stroke*. Ovid Technologies (Wolters Kluwer Health) 2022; 1550–1557. Available at: <http://dx.doi.org/10.1161/STROKEAHA.121.034445>

10) Hwang J, Kim SJ, Bang OY, Chung CS, Lee KH, Kim DK, Kim GM. Ischemic stroke in Takayasu's arteritis: lesion patterns and possible mechanisms. *J Clin Neurol*. 2012 Jun;8(2):109-15. doi: 10.3988/jcn.2012.8.2.109. Epub 2012 Jun 29. PMID: 22787494; PMCID: PMC3391615.