

Case report

Floating right heart thrombus: a spectacular evolution

ABSTRACT

Introduction: Right heart thrombi are a rare entity, less well-characterized than those in the left heart, and their management is still controversial.

Case: We report the case of a 63-year-old patient who presented for pre-dialysis echocardiographic monitoring without symptoms, revealing a floating thrombus in the right atrium. Faced a therapeutic impasse, anticoagulation was initiated with a spectacular outcome.

Conclusion: There is still no clear consensus on the therapeutic strategy for right heart thrombi, underscoring the importance of considering all necessary factors before deciding on appropriate treatment.

Keywords: Thrombus; right heart; thrombolysis; thrombectomy

1. INTRODUCTION

Thrombi in the right heart are a rare entity, less well-characterized than left heart thrombi. Their incidence is around 3.1%, but they are likely underdiagnosed. They may be associated with venous thromboembolic disease or medical devices (central catheters, pacemakers) (1). Floating thrombi carry a very high risk of embolic complications, leading to pulmonary embolism (PE) or stroke, necessitating urgent treatment (1). Indeed, this condition poses a threat to life prognosis, with a mortality rate exceeding 40% (2). Currently, there is no clear consensus on treatment. Some recommend surgery as the first approach, while others suggest anticoagulants for stable patients. Thrombolysis is also increasingly considered in this condition (3).

2. CASE PRESENTATION

We report the case of a 63-year-old female with diabetes, hypertension and end-stage renal disease on hemodialysis. Two months earlier, she had been hospitalized for the management of right-sided infective endocarditis with coagulase-negative staphylococci on a tunneled catheter, complicated by infectious spondylodiscitis. The patient received then antibiotic therapy and **has benefited from the removal of the catheter.**

After discharge, an echocardiographic follow-up showed a significant reduction in vegetation size and calcification. The biological markers of inflammation were negative. The patient was subsequently lost to follow-up with poor therapeutic adherence but presented one month later, asymptomatic and hemodynamically stable. Echocardiography revealed a huge, mobile thrombus in the right atrium, measuring 33x13 mm, partially protruding through the tricuspid valve and prolapsing into the right ventricle (Figure 1). Cardiac MRI was performed to better characterize the thrombus and rule out a septic origin. It identified a serpiginous thrombus measuring 40mmx18 mm, attached in its middle to the inferior vena cava by a slender appendage of 20x12 mm (Figure 2). Given the thrombus's size, mobility, and high hemorrhagic risk, unfractionated heparin anticoagulation was planned for urgent therapeutic intervention with thrombolysis. However, due to the patient's refusal of hospitalization, antivitamin K anticoagulation was initiated with strict monitoring. After a week of anticoagulation, echocardiography showed a spectacular improvement in the thrombus and its subsequent disappearance (Figure 3). The patient then received six months of anticoagulation and is currently stable, without recurrence or thromboembolic events.

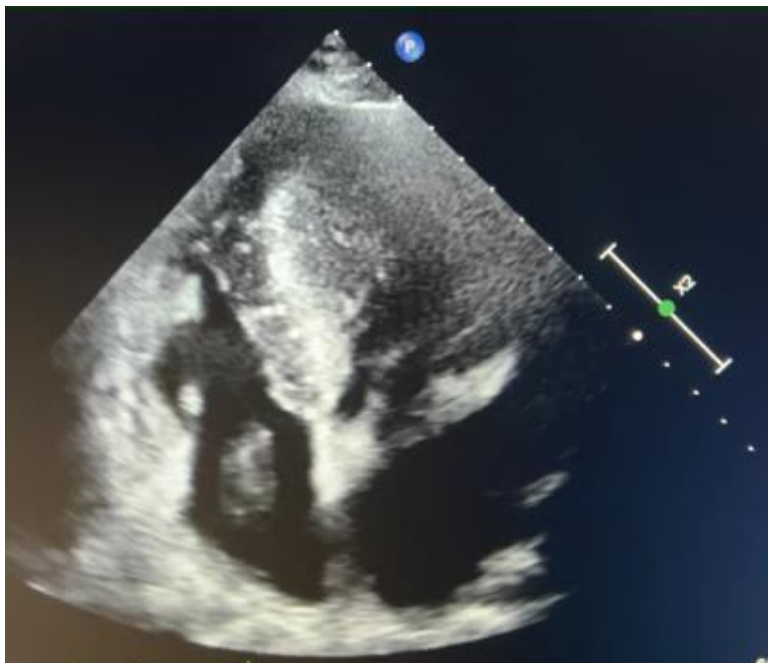


Fig. 1. Four-chamber echocardiographic section showing right atrial thrombus

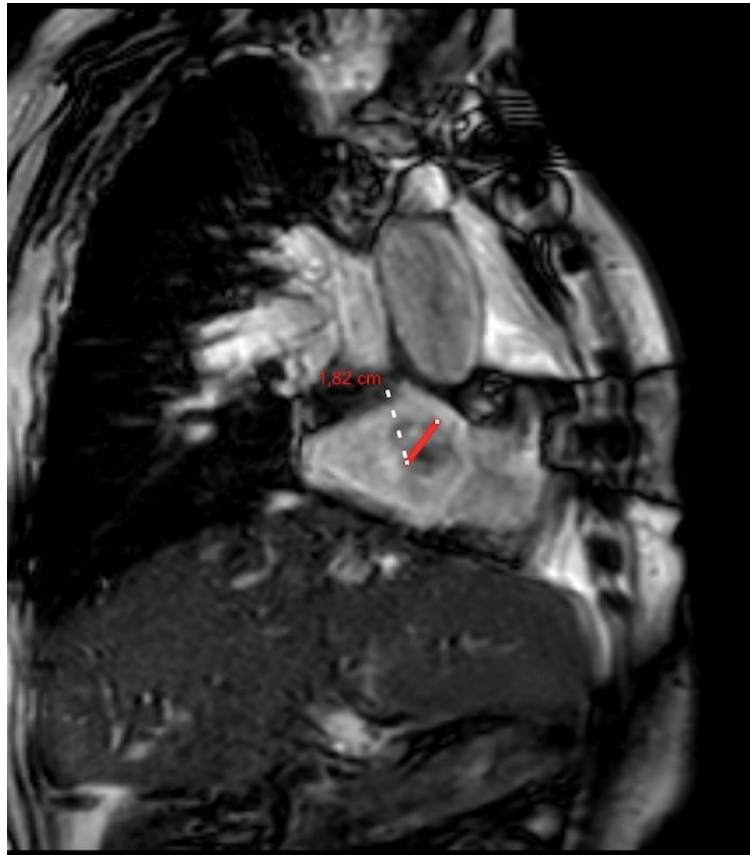

Fig.2. Cardiac MRI image showing a thrombus in the right atrium attached to the inferior vena cava by its appendage.

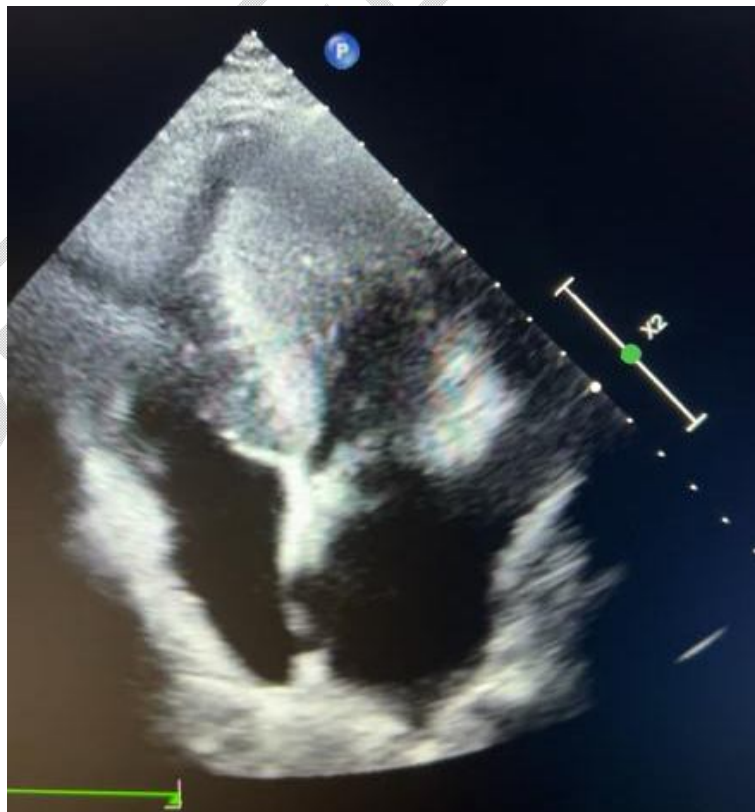

Fig.3.Four-cavity echocardiographic image after 7 days of anticoagulation showing the disappearance of the thrombus

3. DISCUSSION

Intracardiac thrombi can complicate various situations, including atrial fibrillation, heart failure, venous thromboembolic disease with a "transitional" thrombus migrating from the venous system to the heart. Patients with right heart thrombi often have an underlying condition promoting their formation, such as heart failure, neoplasia, or end-stage renal disease on hemodialysis. All these factors contribute to blood flow stasis, prothrombotic factor secretion, endothelial dysfunction, and endothelial damage (1). Different types of thrombi exist: Type A, originating in deep peripheral veins and traversing the right atrium, highly mobile, vermiform in shape with a high risk of embolization; Type B, originating in the right atrium, non-mobile; and Type C, rare, similar to a myxoma and extremely mobile (4). The embolic risk can reach 50% for mobile thrombi and 10% for immobile ones. Right heart thrombi are generally diagnosed by TTE, a non-invasive, readily available bedside examination. Transesophageal echocardiography may be useful for better visualizing the thrombus. Cardiac MRI can also distinguish subacute thrombi that do not enhance, provide more characteristics, and eliminate differential diagnoses (5). Indeed, right heart thrombi can be confused with primary tumors, cardiac metastases, vegetation, or congenital anomalies such as a persistent Eustachian valve (2,6). In our patient's case, there was a combination of Types A and C thrombi, making management even more challenging. Regarding therapy, three possibilities have been described: thrombolysis, anticoagulation, and thrombectomy by surgery or endovascular methods. The choice depends on the thrombus's morphology, mobility, and the risk PE (6). Thrombolysis is the initial option for patients in whom surgery is not feasible, especially for a flat and immobile thrombus with a lower risk of embolization (5). It can be useful as a first-line treatment to improve prognosis, especially in patients with pulmonary embolism, even without hemodynamic instability (2). It has the advantage of accelerating lysis, reperfusion, reducing pulmonary hypertension, and improving right ventricular function. It can dissolve the thrombus in three different locations: intracardiac, venous thrombus, and in the case of pulmonary embolism. However, the main risks are dislodging the thrombus and causing a PE, as well as bleeding, with rates ranging from 6 to 20% (7). Therefore, contraindications such as recent stroke or surgery must be ruled out before use. Surgical embolectomy is the classical treatment, especially if there is a contraindication to thrombolysis or ineffective anticoagulation. It has the advantage of allowing repair of a potential patent foramen ovale (2). New methods have emerged, such as endovascular thrombectomy using the "Angiovac" system inserted through the femoral or jugular venous network, which allows aspiration of the thrombus or vegetation. Few centers use it, and the literature on results is limited (8). Thus, for Type A thrombi, anticoagulation alone is insufficient; surgery or thrombolysis should be performed, unlike Type B thrombi where anticoagulation alone may suffice (9,10). Anticoagulation should be maintained for 3 to 6 months until thrombus resolution, although there are no clear recommendations for right heart thrombus treatment. Due to the complexity of our case, thrombolysis could not be performed due to the high hemorrhagic risk in our patient. Surgery was also not an option due to the high mortality risk associated with surgery. Warfarin anticoagulation was the only option, given that the patient could not be hospitalized. The mortality of right heart thrombi is high: 45%, especially within the first 24 hours of hospitalization. Untreated, this rate can reach 100% (11,13).

4. CONCLUSION

Right heart thrombi, whether formed in situ or in transition from the venous system, are rare but can lead to serious complications such as PE. There is no clear consensus on management, but urgent anticoagulation is essential to improve prognosis. The therapeutic strategy is based on the thrombus type, patient history, hemorrhagic risk, and the availability of different techniques (12). Several studies are still needed to determine the optimal therapeutic strategy and develop other more attractive alternatives, such as endovascular thrombectomy, which could be used in patients contraindicated for thrombolysis and surgery (2).

CONSENT

As per international standard or university standard, patient(s) written consent has been collected and preserved by the author(s).

Ethical Approval:

As per international standards or university standards written ethical approval has been collected and preserved by the author(s).

Disclaimer (Artificial intelligence)

Author(s) hereby declare that NO generative AI technologies such as Large Language Models (ChatGPT, COPILOT, etc.) and text-to-image generators have been used during the writing or editing of this manuscript.

REFERENCES

- 1- F.Q. Goh, A. Leow, A. Ho, B. Tan, L. Yeo, T. Li et al. Clinical characteristics, treatment and long-term outcomes of patients with right-sided cardiac thrombus. *Hellenic Journal of Cardiology* 68 (2022) 1-8.
- 2- L. Chartier, J. Béra, M. Delomez, P. Asseman, J. Beregi, J. Bauchart et al. Free-Floating thrombi in the right heart: diagnosis, management, and prognostic indexes in 38 consecutive patients. *Circulation*. 1999; 99:2779-2783.
- 3- B. Ozlek, E. Ozlek, B. Yildirm, M. Biteker. Right heart thrombi treatment. *Am J Med*, 2017 Jun; 130(6) doi: 10.1016/j.amjmed.2017.01.028.
- 4- M. Bergonti, C. Ascione, P. Agostoni, R. Castelli, C. Vignati. Massive right atrial thrombosis: are you brave enough to start anticoagulation? A case reports. *Frontier n cardiovascular medicine*. July 2021. Volume 8
- 5- S. Sontineni, M. White, S. Singh, A. Aroun, D. Cloutier, C. Nair et al. Thrombectomy reduces the systemic complications in device-related right atrial septic thrombosis. *Can J Cardiol* Vol 25. February 2009.
- 6- Benjamin M, Asim Afzal MD et al. Right atrial thrombus and its causes, complications and therapy. *Bayl Univ Med Cent*. 2017;30 (1): 54-56
- 7- Athappan G, Sengodan P, Chacko P, Gandhi S. Comparative efficacy of different modalities for treatment of right heart thrombi in transit: a pooled analysis. *Vascular medicine*. 2015, vol 20 (2); 131-138
- 8- I. Hameed, C. Laau, F. Khan, M. Wingo, M. Rahouma, J. Leonard et al. Angiovac for extraction of venous thromboses and endocardial vegetations: a meta-analysis. *J Card Surg*. 2019;1-11
- 9- Jimenez D, Yusen R. Clinical significance and management of right heart thrombi: more questions than answers. *Eur Respir J* 2016; 47:702-703.
- 10- Kronik G et al. The European cooperative study on the clinical significance of right heart thrombi. *European heart journal*. 1989; 10: 1046-1059.
- 11- P. Rose, N. Punjabi, D. Pearse. Treatment of right heart thromboemboli. *Chest* 2002; 121:806-814.
- 12- L. Burgos, J. Costabel, V. Brito, A. Sigal, D. Maymo et al. Floating right heart thrombi: A pooled analysis of cases reported over the past 10 years. *Am J Emerg Med*. 2018 Jun; 36(6):911-915. doi: 10.1016/j.ajem.2017.10.045.

ABBREVIATIONS

PE: Pulmonary embolism

TTE: Transthoracic echocardiography

MRI: Magnetic resonance imaging

UNDER PEER REVIEW