

**Diagnosis and treatment of a primary splenic hydatid cyst: a case report**

UNDER PEER REVIEW

**Introduction:**Hydatid disease is a parasitic infection caused by Echinococcus granulosus. The spleen is the third most common site of hydatid disease, after the liver and lungs. Splenic hydatid cyst can be either primary or secondary. We report the case of a primary splenic hydatid disease that was treated with a total splenectomy.

**Case report:**A 40-year-old Tunisian female, with no medical history, was referred to our general surgery department, due to heaviness-type abdominal pain concerning the left hypochondrium evolving in the last 2 years. Upon examination, we noticed a left upper quadrant tenderness and splenomegaly. Ultrasonography of the abdomen showed a large solid-cystic mass of the spleen measuring 99\*90 mm. CT abdomen confirmed a 12 cm cystic mass occupying almost the entire spleen, multivesicular with partial calcification of the membrane. There was no involvement of liver or other organs. Apart from antiparasitic treatment, she was vaccinated two weeks preoperatively. Laparotomy was performed through the left subcostal incision. Surgical exploration revealed a hydatid cyst occupying the lower pole of the spleen adherent to the left kidney. After short gastric vessels were sutured, total splenectomy was performed by ligation of the splenic artery and vein with close attention to not injure the pancreatic tail. Postoperative course was uneventful. She was discharged from hospital on the sixth postoperative day with antibiotic prophylaxis.

**Conclusion:** Primary splenic hydatid cysts are rare, even in endemic areas, and often present with non-specific symptoms. Surgical management, particularly total splenectomy, is the standard treatment to prevent complications and recurrence.

## **ABSTRACT**

*Keywords:Hydatid cyst, primary splenic hydatic cyst, total splenectomy, case report*

## 1. INTRODUCTION

“Splenic hydatid disease is a rare but serious condition caused by the larval stage of *Echinococcus granulosus*, a type of tapeworm”<sup>1</sup>. “Despite its rarity, splenic hydatid disease is a significant health concern in endemic areas due to its potential to cause serious complications, including rupture of the cysts and secondary infection”<sup>2</sup>.

“While liver is the most commonly affected organ, the spleen can also be involved, either alone or in conjunction with other organs”<sup>3</sup>. “It is the third most common site of hydatid disease, after the liver and lungs”<sup>4</sup>.

“Due to the asymptomatic nature of the disease, patients are often diagnosed incidentally during unrelated medical examinations”<sup>5</sup>.

“There is a lack of standardized diagnostic methods and treatment protocols for splenic cysts. Ultrasonography is essential for identifying splenic cysts, distinguishing between solid and cystic lesions, and detecting intracystic septa or irregular walls”<sup>6</sup>. “Computed tomography (CT) scans provide detailed information regarding the cyst’s morphology, fluid characteristics, precise location, and its relationship to adjacent structures”<sup>7</sup>.

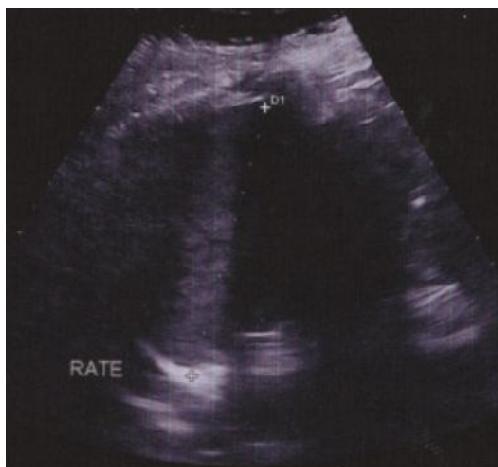“Chronic pericystic inflammation may cause adhesion with adjacent organs or even fistulization between cysts and nearby organs such as the stomach, pancreas, left colon, left kidney, or bronchus”<sup>8</sup>.

“Therefore, treatment usually involves conservative or non-conservative surgery, often accompanied by anti-parasitic medication”<sup>9</sup>.

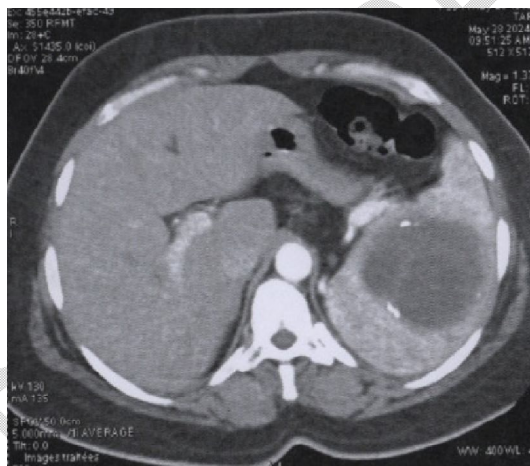
“The selection of effective approaches correlates with the size and location of the cysts and stage of the diseases. Surgical intervention like splenectomy is the main-stay of treatment”[20]. We aimed to describe a case with a patient complaining with dull abdominal pain for a long time.

## 2. CASE PRESENTATION

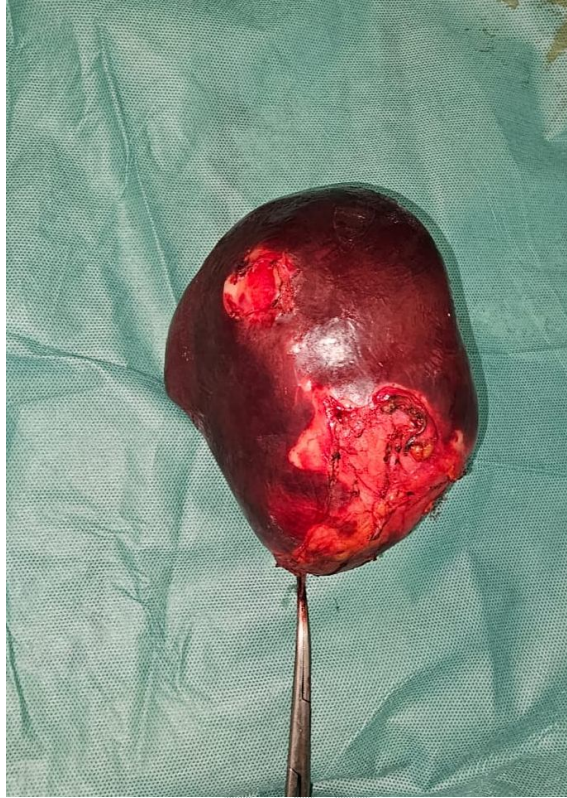A 40-year-old Tunisian female, without medical or surgical history, from a rural area with a history of sheep and dog farming, was referred to our general surgery department, due to heaviness-type abdominal pain concerning the left hypochondrium evolving in the last 2 years. The patient was hemodynamically stable. During the examination, we noticed a left upper quadrant tenderness and splenomegaly. Ultrasonography of the abdomen showed a large solid-cystic mass of the spleen measuring 99\*90 mm. CT abdomen confirmed a Large cystic mass occupying almost the entire spleen, multivesicular with partial calcification of the membrane. It measures 12\*9 cm. There was no involvement of liver or other organs. Apart from antiparasitic treatment, she was vaccinated against pneumococcus, meningococcus and haemophilus two weeks preoperatively. Laparotomy was performed through the left subcostal incision. Surgical exploration revealed a hydatid cyst occupying the lower pole of the spleen adherent to the left kidney. The spleen was pulled medially and dorsally when mobilized midline to avoid capsular tears. After short gastric vessels were sutured, total splenectomy was performed by ligation of the splenic artery and vein with close attention to not injure the pancreatic tail. The operation lasted two hours and thirty minutes. Postoperative course was uneventful. No thrombocytosis was noted. Macroscopic and microscopic examination of the specimen confirmed Hydatid cyst. The patient was discharged from hospital on the sixth postoperative day with antibiotic prophylaxis based on Clamoxyl 500 mg, 2 times a day for 2 years and enoxaparin.



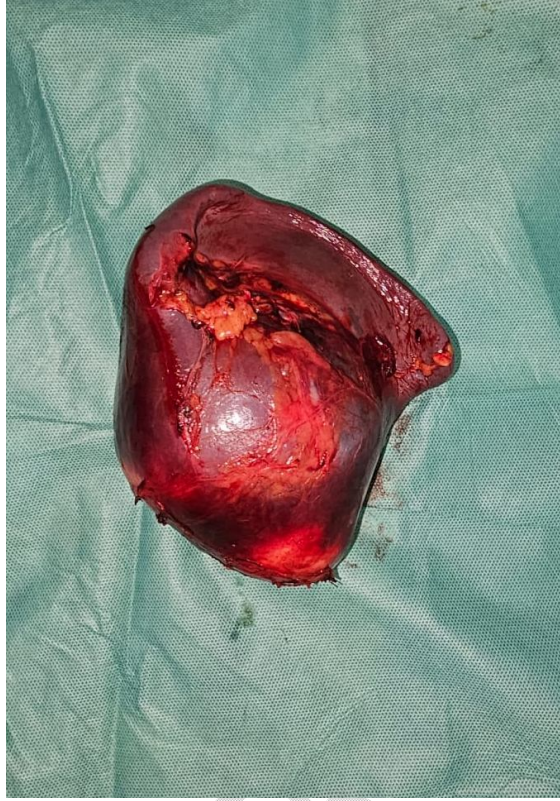*Figure 1 ultrasonographic appearance of a primary splenic hydatid cyst*



*Figure 2 CT axial scan view appearance of a primary splenic hydatid cyst*



*Figure 3 splenectomy specimen: anterior surface*



*Figure 4 splenectomy specimen: posterior surface*

### 3. DISCUSSION

The Mediterranean and the Middle East are endemic regions for hydatid cyst, with prevalence rates ranging from 1.2 to 23 cases per 100,000 inhabitants<sup>7</sup>. Tunisia has a high prevalence rate of 16.5 cases per 100,000, mainly due to the close contact between humans and dogs and the consumption of raw vegetables and fruits contaminated with parasite eggs<sup>10</sup>.

Splenic hydatidosis is a rare condition that occupies the third place in the majority of studies after the liver and lung. Its frequency varies from 2 to 5% of all this parasitosis<sup>11</sup>. "Cysts are mostly solitary but may sometimes be multiple, and may be associated with cysts in other intraabdominal organs in up to 30% of cases"<sup>12-13</sup>. "The parasite may reach the spleen through blood stream, through lymphatics and by reflux into the spleen from portal vein at the time of raised intra-abdominal pressure"<sup>10-14</sup>. "Isolated involvement of spleen is rare. Primary infestation of the spleen usually takes place by the arterial route after the parasite has bypassed the liver and lungs"<sup>10</sup>.

Splenic hydatidosis is characterized by its high clinical latency, which explains its discovery in adulthood<sup>5</sup>. It is a condition with an insidious onset, its discovery can be fortuitous<sup>14</sup>. The most frequently reported nonspecific symptoms include upper left quadrant abdominal pain, nausea, vomiting, unintentional weight loss, constipation, and dyspnea<sup>5</sup>. On physical examination, the most common findings are a mass in the upper left quadrant and splenomegaly<sup>5</sup>. The symptomatology can be made of signs of digestive or urinary type for lower polar cysts of the spleen or pleuropulmonary signs such as dyspnea or hemoptysis for upper polar cysts.

The Gharbi classification, developed by a Tunisian radiology professor<sup>6</sup>, is the leading method for evaluating hydatid liver cysts using ultrasound, significantly influencing treatment decisions. However, further investigation revealed that, similar to the WHO classification, this system is mainly designed for liver cysts and may not be suitable for splenic hydatid cysts. Computed tomography allows precise topographical diagnosis and the search for other associated locations. We distinguish two widely recognized classifications which are the WHO and the Gharbi classification identifies five types:

WHO-IWGE	Gharbi 1981 Description	Stage
CE1	Type I - Unilocularuniloc cystic lesion with double line sign.	Active
CE2	Type II - Multivesicular, multiseptated “honeycomb” rosette-like.	Active
CE3 A	Type III (cyst with detached membranes water-lily sign).	Transitional
CE3 B	Type III - Matrix with daughter cysts in solid matrix.	Transitional
CE4	Type IV - Heterogeneous hypoechoic/hyperechoic contents. No daughtercysts.	Inactive
CE5	Type V - Solid cyst with calcified wall.	Inactive

*Table 1 Hydatid cyst classification according to the World Health organization and Gharbi*

“Some patients may present with complications such as infection of the cyst, rupture of the cyst into the peritoneal cavity, fistula formation into hollow viscera like colon or stomach, bronchopleural fistula, sympathetic pleural effusion, calcification, hypersplenism, and severe urticaria”<sup>12</sup>.

“Pre-operatively Pneumococcal, meningococcal, and Hib vaccinations should be administered at least 14 days before a scheduled elective total splenectomy”<sup>15</sup>. Anti-parasitic treatment has been described as mandatory preoperatively. According to Velasco-Tirado V et al.<sup>16</sup>, based on their conducted systematic review and metanalysis published in 2018, treatment outcomes are better when surgery is combined benzimidazole drugs given pre- and/or post-operation. Albendazole chemotherapy was found to be the primary pharmacological treatment to consider in the medical management<sup>16</sup>. “This contributes to reduce the risk of anaphylaxis, decrease the tension in the cyst wall and to reduce the postoperative recurrence rate”<sup>2</sup>.

The treatment is principally surgical<sup>5</sup> to avoid spontaneous or traumatic rupture. The spleen plays a crucial role in the immune system, and its removal is a significant procedure with considerable morbidity and mortality risks, as well as long-term effects on a patient’s ability to combat infections. Consequently, spleen-sparing surgical methods are often preferred, though they come with their own set of challenges. While total splenectomy effectively removes parasitic elements to reduce cyst-related complications and recurrences, it is associated with a

high incidence of post-splenectomy sepsis-related mortality (4%) and morbidity<sup>5</sup>. Conservative surgery like partial splenectomy, cyst enucleation, unroofing of the cyst wall with omentoplasty have been described for superficial solitary cysts<sup>5</sup>. These are generally located in one pole of the spleen or are deemed unresectable due to enormous size and perisplenic adhesions<sup>12</sup>. Spleen preserving surgery minimizes long-term immune risks but presents an increased risk of bleeding when incising the splenic tissue, and unroofing the cyst wall has a risk of severe postoperative infection due to the residual space. Therefore, in the case of multiple splenic cysts or a large cyst, total splenectomy is advised, especially when there are adhesions between the spleen and nearby organs<sup>5</sup>.

Given the uncommon nature of splenic hydatidosis, there are no strict management guidelines. Instead, treatment decisions are usually made on an individual basis, tailored to the specific surgical circumstances.

Intra-operatively, protection of the operating field by fields soaked in hypertonic serum is preferred to prevent further spread or anaphylactic reaction in case of accidental break-in. Dorsal and medial traction should be kept when mobilizing to avoid capsular tears<sup>17</sup>. During the release of the spleen, it is recommended to proceed from lateral to medial<sup>17</sup>. This allows for better control of the vascular structures and minimizes the risk of complications<sup>17</sup>. A 1-2 cm cuff of peritoneum should be kept to prevent damage to surrounding organs and to carefully ligate the splenic artery and vein to avoid injury to the pancreatic tail<sup>17</sup>. In 75% of patients, pancreatic tail lies within 1 cm of the hilum, and of these, 30% actually touch it<sup>18</sup>.

“Laparoscopic splenectomy for hydatid cysts is a well-known procedure with a number of reports in the field. It is increasingly safely performed in advanced laparoscopic centers even in large cysts (>10 cm)”<sup>19</sup>. However, it is important to avoid protoscolex-rich fluid during surgery.

## **4. CONCLUSION**

Primary splenic hydatid cysts are rare, even in endemic areas, and often present with non-specific symptoms. Imaging techniques like ultrasound and CT scans are crucial for diagnosis. Surgical management, particularly total splenectomy, is the standard treatment to prevent complications and recurrence. Each patient's treatment should be individualized for the best outcomes.

## **CONSENT**

Written informed consent for publication of their clinical details and/or clinical images was obtained from the patients.

Ethical Approval:

As per international standards or university standards written ethical approval has been collected and preserved by the author(s).

## **DATA AVAILABILITY**

All data underlying the results are available as part of the article and no additional source data are required.

## **Disclaimer**

No generative AI technologies such as Large Language Models (ChatGPT, COPILOT, etc.) and text-to-image generators have been used during the writing or editing of this manuscript.

## REFERENCES

1. Derbel F, Ben M, Hadj Hamida MB, et al. Hydatid Cysts of the Liver - Diagnosis, Complications and Treatment. In: Derbel F, ed. *Abdominal Surgery*. InTech; 2012. doi:10.5772/48433
2. Dziri C, Haouet K, Fingerhut A, Zaouche A. Management of Cystic Echinococcosis Complications and Dissemination: Where is the Evidence? *World j surg*. 2009;33(6):1266-1273. doi:10.1007/s00268-009-9982-9
3. Makni A, Jouini M, Kacem M, Safta ZB. Extra-hepatic intra-abdominal hydatid cyst: which characteristic, compared to the hepatic location? *Updates Surg*. 2013;65(1):25-33. doi:10.1007/s13304-012-0188-6
4. Korkut E, Aksungur N, Öztürk G. A Retrospective Evaluation of Spleen Hydatid Cyst Treatments: The Spleen-Preserving Conservative Approach is Preferable to Splenectomy. *Eurasian J Med*. 2022;54(2):133-137. doi:10.5152/eurasianjmed.2022.20367
5. Akbulut S, Sogutcu N, Eris C. Hydatid Disease of the Spleen: Single-Center Experience and a Brief Literature Review. *Journal of Gastrointestinal Surgery*. 2013;17(10):1784-1795. doi:10.1007/s11605-013-2303-5
6. Gharbi HA, Hassine W, Brauner MW, Dupuch K. Ultrasound examination of the hydatid liver. *Radiology*. 1981;139(2):459-463. doi:10.1148/radiology.139.2.7220891
7. Chaouch MA, Hadj Taieb A, Ben Jabra S, et al. A case report of a large Splenic epidermoid cyst treated with partial splenectomy. *Annals of Medicine and Surgery*. 2024;86(2):1220. doi:10.1097/MS9.0000000000001675
8. Hosn SS. Splenic hydatid infection | Radiology Reference Article | Radiopaedia.org. Radiopaedia. doi:10.53347/rID-21741

9. Atmatzidis K, Papaziogas B, Mirelis C, Pavlidis T, Papaziogas T. Splenectomy versus Spleen-Preserving Surgery for Splenic Echinococcosis. *Digestive Surgery*. 2003;20(6):527-531. doi:10.1159/000073689
10. Taratuto AL, Venturiello SM. Echinococcosis. *Brain Pathology*. 1997;7(1):673-679. doi:10.1111/j.1750-3639.1997.tb01082.x
11. Moujahid M, Tajdine MT, Achour A, Janati MI. Kyste hydatique de la rate. À propos de 36 cas. Expérience du service. *J Afr Hepato Gastroenterol*. 2009;3(4):212-215. doi:10.1007/s12157-009-0134-5
12. Malik AA, Ul Bari S, Younis M, Wani KA, Rather AA. Primary splenic hydatidosis. *Indian J Gastroenterol*. 2011;30(4):175-177. doi:10.1007/s12664-011-0104-x
13. Durgun V, Kapan S, Kapan M, Karabiçak I, Aydogan F, Goksoy E. Primary Splenic Hydatidosis. *Digestive Surgery*. 2003;20(1):38-41. doi:10.1159/000068864
14. Singh H, Arora S. Primary Hydatid Cyst of the Spleen. *Med J Armed Forces India*. 2003;59(2):169-170. doi:10.1016/S0377-1237(03)80074-6
15. ACIP Altered Immunocompetence Guidelines for Immunizations | CDC. September 19, 2023. Accessed July 21, 2024. <https://www.cdc.gov/vaccines/hcp/acip-recs/general-recs/immunocompetence.html>
16. Velasco-Tirado V, Alonso-Sardón M, Lopez-Bernus A, et al. Medical treatment of cystic echinococcosis: systematic review and meta-analysis. *BMC Infect Dis*. 2018;18:306. doi:10.1186/s12879-018-3201-y
17. Albo D, Dalman R. *Operative Techniques in Surgery*. Wolters Kluwer; 2014.
18. Monson JR, Weiser MR. Sabiston Textbook of Surgery, 18th ed. The Biological Basis of Modern Surgical Practice. *Dis Colon Rectum*. 2008;51(7):1154-1154. doi:10.1007/s10350-008-9293-5

19. Yotsov TI, Dyulgerova S, Draganova D. Laparoscopic splenectomy for solitary splenic hydatid cyst: Case report. *J Minim Access Surg.* 2023;19(2):317-319.  
doi:10.4103/jmas.jmas\_113\_22

20. Jallali M, Chaouch MA, Zenati H, Hassine HB, Saad J, Noomen F. Primary isolated hydatid cyst of the spleen: A case report. *International Journal of Surgery Case Reports.* 2024 Apr 1;117:109552.

UNDER PEER REVIEW