

Original Research Article

A cone-beam computed tomographic study to evaluate variations in root canal morphology of mandibular premolars and its relation to mental foramen

ABSTRACT

Aim: Using cone beam computed tomography, the study intends to assess changes in mandibular premolar root canal shape and its link to the mental foramen in the Central Gujarat population.

Study design: This is a retrospective, cross-sectional analysis.

Place and Duration of Study: Between September 2021 and December 2022 the was conducted at the K M Shah Dental College in Vadodara, Gujarat, India, in combination with CBCT facilities in the Central Gujarat area.

Methodology: 250 CBCT scans of medium and large FOV were obtained with approval from the institutional ethics committee. The images were analyzed for anatomical differences between the mandibular first and second premolars as well as the position of the mental foramen and how it relates to the mandibular premolars.

Results: The most frequent morphologies in both the premolars were type I, that is 89.6 % and 72% respectively followed by type II 6.4% and 20.8%. Only one 1st Premolar [0.8%] and four 2nd premolars [3.2%] out of 250 were reported with type III Vertucci's canal configuration. The Prevalence rate of Straight root canals in both premolars was 98.1%. Mental foramen were most frequently found [58%] under the apex of the first premolar.

Conclusion: Type I Vertucci's canal configuration is the most prevalent morphological variation observed in the mandibular premolar population in central Gujarat, followed by type II Vertucci's canal configuration. Additionally, the mental foramen is most frequently found between the apex of premolars and below the apex of the mandibular second premolar.

Keywords: *mental foramen, canal configuration, mandibular premolar, Vertucci's classification, Computed tomography.*

1. INTRODUCTION

The success rate of root canal therapy can be increased by being aware of the anatomical variances in root canal systems beforehand. A contributing factor to the failure of root canal therapy is a lack of understanding of the variations in canal design and pulp architecture.

It is critical to understand both the pulp's typical design and any anticipated changes. Along with being able to identify the many types of normal and pathological pulp architecture, a dentist should be able to use specific procedures to choose the type of anatomy within the pulp during treatment [1,2]. Understanding the root numbers, the number of canals in each root and where they are located, the width and length of the root's cross-section, the root's most common curvature (especially in the buccoligal parts), and the outline form of each root in all dimensions[3-5].

The teeth with the highest prevalence of root canal variation are premolars, second molars, and mandibular incisors. Mandibular premolar canal variation was seen in 16.5% of instances[6], 12.9% of cases[7] and 8% of cases [8] Mandibular premolars usually have one root with a single canal (54- 88.5%)[9]. Between 11.5 and 46% of mandibular premolars have been reported to have several canals [10,11]. Two or more canals have been identified in about 24% of mandibular premolar instances [12]. Estimates indicate the percentage of mandibular second premolars having two or three root canals at 1.2% [9], 11% [13], and 0.4%, respectively.

The mental foramen is where the mental nerve (MN), a branch of the IAN, exits the mandible (MF). The MF can be situated anywhere between the first molars in the posterior and the distal to the mandibular canine in the anterior [14]. Both surgical and non-surgical endodontic treatments tend to injure this nerve, which manifests as paresthesia due to the way the MF and MN are positioned in relation to the mandibular posterior teeth's root apices [15]. The risk of harm to the MN increases if the MF is incorrectly identified and insulted [16]. The location of the MF is frequently difficult because there are no specific anatomical indicators to utilize as a point of reference.

Additionally, the majority of people cannot clinically see or feel the foramen. A range of techniques, including radiographic imaging and the dissection of human mandibles, are used to pinpoint the location of the MF [17]. However, there is a significant potential for misidentification considering the radiographic appearance of radiolucent MFs. As a result, a 3-dimensional (3D) picture of the MF and surrounding teeth is necessary as conventional radiographs cannot adequately inspect them [18].

In contrast to 2D radiography, Cone Beam Computed Tomography (CBCT) scans produce 3D pictures that accurately depict root canal systems, making them a dependable, non-invasive evaluation method applicable in all spatial planes [19]. Recent years have seen widespread adoption of CBCT in dentistry as a result of its advantages over traditional computed tomography (CT) [20,21]. This method allows for accurate measurements of the data obtained in terms of both linear geometry and three dimensions by using isotropic voxels, which have similar dimensions in all three planes of space.

Due to a lack of knowledge regarding variability in root canal morphological features of mandibular premolars and their correlation to the mental foramen, the goal of the current CBCT study was to evaluate the root canal structure of the mandibular first and second premolars and their relation to mental foramen in the Central Gujarat population.

2. MATERIALS AND METHODS

Between September 2021 and December 2022, this retrospective, cross-sectional analysis was conducted at the K M Shah Dental College in Vadodara, Gujarat, India, in combination with CBCT facilities in the Central Gujarat area. 250 scans of CBCT were acquired from five distinct CBCT centres situated in central Gujarat cities - Ahmedabad, Nadiad, Anand and Vadodara. The institutional Ethics Committee's prior approval was acquired [SVIEC/ON/Dent/SRP/SEP/20/22].

2.1 Sample Size Calculation:

The sample size was calculated according to a previous study done^[22], Using the formula $[Z^2 \cdot p [1-p] / e^2 / 1 + [Z^2 \cdot p [1-p] / e^2 p]$, the minimal sample size for CBCT was calculated to be 250 with a 95% confidence interval.

The estimated percent frequency of the outcome factor in the population (p) is 9.2% \pm 5, and the population size (for the finite population correction factor, or fpc) is 5000. The percentage of 100 (absolute \pm %) that represents the confidence intervals are as follows: d = 5%; p = 0.09 (proportion of the result under study); 95% confidence interval; 1.959964 Z-score.

2.2 Inclusion And Exclusion Criteria:

The high-quality CBCT scans of first, second premolar and first molar from the right or left side of mandibular jaws with medium and large FOV from the central Gujarat population, patients belonging to the age group of 18 to 60 years; premolars with the absence of periapical lesion; and with no previous endodontic treatment were included in the study. CBCT scans of missing mandibular premolars; scans with any artefacts that hinder the view of canals; fractured mandibular jaw and premolars with open apex and resorption were excluded from the study.

2.3 CBCT Evaluation:

All the scans of CBCT were evaluated by both the principal investigator and co-investigator who had undergone training to evaluate the CBCT scans. Then 15 CBCT scans were randomly allotted to the Principal investigator and Co-investigator. The Kappa test was done to check the Intra-examiner variability and inter-examiner variability and a minimum 85% value was set to get common consent. These scans were assessed till they reached an assessment value of (\leq 85%). The remaining 235 scans were further evaluated by both investigators in the same manner.

Sagittal, coronal, and axial parts of CBCT scan DICOM files were examined, and the following data was assessed:

1. In the sagittal and coronal sections of the CBCT, the root canal system configuration of the mandibular first and second premolars is as per Vertucci [1984].
2. The quantity of canals seen in the mandibular premolars on the CBCT's axial section.
3. The mandibular premolars' root canals exhibit bifurcation or trifurcations.
4. The degree of apical bifurcation, if any, or trifurcation
5. The separation between the mandibular posterior teeth's root apex and the mental foramen in the sagittal area of the CBCT.
6. Degree of root curvature in mandibular first and second premolars in sagittal or Coronal section.
7. This was then further evaluated by a blinded co-investigator who is well-versed in the evaluation of CBCT scans.

STATISTICAL ANALYSIS

The information was then assembled and computed. The analysis of the data was done using IBM SPSS Version 21.0. The data were expressed using the frequency for categorical variables and the mean SD for continuous variables.

3. RESULTS

Table 1: Frequent morphology found in mandibular premolars (Vertucci's canal configuration)

Vertucci's classification	1st mandibular premolar [%]	2nd mandibular premolar [%]
I	112 [89.6%]	90 [72%]
II	8 [6.4%]	26 [20.8%]
III	1 [0.8%]	4 [3.2%]
IV	0	0
V	3	1 [0.8%]
VI	0	0

Table 1 illustrates, 250 CBCT scans from people living in Central Gujarat were used in this investigation. In the first and second premolars, the most prevalent morphologies were type I, that is 89.6 % and 72% respectively followed by type II 6.4% and 20.8%. Only one 1st Premolar (0.8%) and four 2nd premolars (3.2%) out of 250 showed type III vertucci's canal configuration and only one second Premolar (0.8%) and three first premolars (2.4%) showed type V configuration. The rest five premolars did not fit into any of Vertucci's classifications as 2 of them displayed type I and 3 teeth appeared to be in Gulabiwala's classification.

This means that type I was the most prominent pattern detected in premolar root canals, followed by type II and occasionally type V, although type III, type IV, and type VI were less frequent.

Table 2: Prevalence of anatomic variation in mandibular premolars

Curvature	Straight – 245
	Curvature – 5 [7-40°]
C-shaped Canal	0
Number of Roots	Single Rooted – 247 [98.85]
	Bifurcation – 3 [1.2%]
	Trifurcation – 0

The Prevalence rate of Straight root canals in both premolars was 98.1% and only 5 premolars [2%] out of 250 showed curvature which ranges from 7-40° (Table 2). Only 3 teeth out of 250 (i.e. 1.2%) show bifurcation & other are single-rooted in which two were mandibular second premolar. (Table 2)

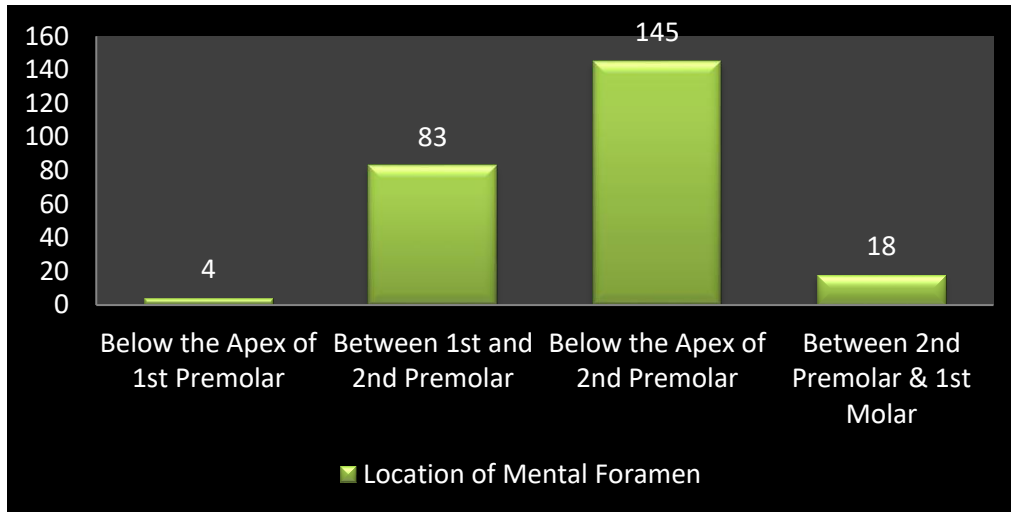


Fig. 1. Location of mental foramen in relation to mandibular premolars

The location of the mental foramen was found most frequently below the apex of the first premolar (58%), followed by the area between the first and second premolar (33.2%). less commonly it was found below the apex of the first premolar in 1.6% of cases. (Figure 1).

4. DISCUSSION

Researchers can perform root canal therapy more successfully and reduce the chance of failure by understanding the shape and structure of the root canals as well as the variations in appearance between various populations. Similar studies have helped us to understand the canal morphology of mandibular premolars better before endodontic treatment because they exhibit significant variance in that area. Specific forms of canal arise in different ethnic groups because genetic and racial variances are major factors that may alter root canal structure.

The current study examined the prevalence of anatomical variations in the mandibular premolars in people of central Gujarat, as well as their association with the mental foramen. We discovered that type I Vertucci's design is the most prevalent root canal configuration, with 89.6% and 72% of cases in the mandibular first and second premolars, respectively. Although Type I is widespread in different populations, the percentage varies. However, a study by Lu et al. and Yang et al. on the Chinese population found that only 54% and 86.8% of mandibular first premolars, respectively, had a single canal, but only 22% and 97.2% of mandibular second premolars did^[23] in contrast to 92% and 72% in our study on the central Gujarat population. Similar research on the south Indian population revealed that type I was most prevalent, with first and second premolars showing it in 83.88% and 93.48% of cases, respectively.^[24] The first and second premolars in the mandible had the highest prevalence of Type I morphology, according to research by Salar Pour et al. and Kim et al. using similar CBCT data on Iranian and Korean populations, respectively^[25,26].

Type II Vertucci's canal arrangement is the second most frequent variation identified in our investigation. In contrast with what our study found, type V was the second most common pattern among South Indian and Chinese groups. Parallel for the Iranian population, it was the second most common pattern of occurrence, however, the percentage differed in each population^[25]. 3.2% of first premolars and 0.8% of second premolars in the mandible in central Gujarat's population had type V vertucci's canal structure.

About 98.2 % of premolars exhibited single roots while only 3 Premolars included an apical bifurcation and two roots. These findings align with research conducted on the populations of South India and Thailand. [24]

In our study, the curvatures of the root and canal were also assessed. In our study, the most frequent shape was a straight root with a straight root canal. Only 2% of premolars had curvatures, ranging from 7 to 40 degrees, with the distal curvature being more common in both premolars. These findings are comparable to research done on the population of Iran.[25]

One of the most important anatomical features in the anterior part of the mandible is the mental foramen and numerous research has focused on determining its location, shape, opening angle, and distances from other significant anatomic landmarks. When performing some surgical treatments, such as apicectomy and genioplasty, the distance between the MF and the apex of the nearest adjacent root is a crucial element to take into account. To prevent harm to the neurovascular bundle leaving the Mental foramen, a surgeon and an endodontist must be aware of the precise distance of the MF from the root. Lower lip paresthesia can also be caused by neglecting the mental foramen.

Individual deviations may occasionally occur, but the most commonly documented location of the mental foramen in the scientific literature is the region of the second premolar in the fully formed jaw.

This study indicates that the mental foramen is most frequently found below the second mandibular premolar's apex and then between the first and second mandibular premolar's apices. The findings are comparable to those of another study conducted among Indians [27]

5. CONCLUSION

Within the limits of the study, it was concluded that Type I and Type II vertucci's canal configurations are the most prevalent morphological variations observed in the mandibular first and second premolars of the central Gujarat population. Mandibular premolars typically consist of a single root and one canal. Additionally, the mental foramen is most frequently found below the mandibular second premolar's apex and between the first and second premolar's apices. Further studies are required to know the canal configuration of premolars in various regions of the Indian population.

CONSENT

Not Applicable

ETHICAL APPROVAL

All authors hereby declare that all experiments have been examined and approved by the appropriate ethics committee and have therefore been performed in accordance with the ethical standards laid down in the 1964 Declaration of Helsinki.

REFERENCES

1. Endodontic Topics - Wiley Online Library <https://onlinelibrary.wiley.com/journal/16011546>.
2. Vertucci FJ. Root canal anatomy of the mandibular anterior teeth. *J Am Dent Assoc* 1974;89[2]:369–71.
3. Benjamin KA, Dowson J. Incidence of two root canals in human mandibular incisor teeth. *Oral Surg Oral Med Oral Pathol* 1974;38[1]:122–6.
4. Mauger MJ, Schindler WG, Walker WA. An evaluation of canal morphology at different levels of root resection in mandibular incisors. *J Endod*. 1998 Sep;24[9]:607–9.
5. Walker RT. Root canal anatomy of mandibular first premolars in a southern Chinese population. *Endod Dent Traumatol*. 1988 Oct;4[5]:226–8.
6. Liao Q, Han J li, Xu X. Analysis of canal morphology of mandibular first premolar 2011 Oct;20[5]:517–21.
7. Yu X, Guo B, Li KZ, Zhang R, Tian YY, Wang H, et al. Cone-beam computed tomography study of root and canal morphology of mandibular premolars in a western Chinese population. *BMC Med Imaging*. 2012 Jul 20;12:18.
8. Ok E, Altunsoy M, Nur BG, Aglarci OS, Çolak M, Güngör E. A cone-beam computed tomography study of root canal morphology of maxillary and mandibular premolars in a Turkish population. *Acta Odontol Scand*. 2014 Nov;72[8]:701–6.
9. Zillich R, Dowson J. Root canal morphology of mandibular first and second premolars. *Oral Surg Oral Med Oral Pathol*. 1973 Nov;36[5]:738–44.
10. Baisden MK, Kulild JC, Weller RN. Root canal configuration of the mandibular first premolar. *J Endod*. 1992 Oct;18[10]:505–8.
11. Khedmat S, Assadian H, Saravani AA. Root canal morphology of the mandibular first premolars in an Iranian population using cross-sections and radiography. *J Endod*. 2010 Feb;36[2]:214–7.
12. Trope M, Elfenbein L, Tronstad L. Mandibular premolars with more than one root canal in different race groups. *J Endod*. 1986 Aug;12[8]:343–5.
13. Pineda F, Kuttler Y. Mesiodistal and buccolingual roentgenographic investigation of 7,275 root canals. *Oral Surg Oral Med Oral Pathol*. 1972 Jan;33[1]:101–10.
14. Greenstein G, Tarnow D. The mental foramen and nerve: clinical and anatomical factors related to dental implant placement: a literature review. *J Periodontol*. 2006 Dec;77[12]:1933–43.
15. Ahonen M, Tjäderhane L. Endodontic-related paresthesia: a case report and literature review. *J Endod*. 2011 Oct;37[10]:1460–4.
16. Singh ID, Panat SR, Singh S, Kishore M, Jha A-. J. Position and symmetry of mental foramen: A radiographic study in bareilly population Alok A.
17. Aminoshariae A, Su A, Kulild JC. Determination of the location of the mental foramen: a critical review. *J Endod*. 2014 Apr;40[4]:471–5.

18. Currie CC, Meechan JG, Whitworth JM, Carr A, Corbett IP. Determination of the mental foramen position in dental radiographs in 18-30 year olds. *Dento Maxillo Facial Radiol.* 2016;45[1]:20150195.
19. Michetti J, Maret D, Mallet JP, Diemer F. Validation of Cone Beam Computed Tomography as a Tool to Explore Root Canal Anatomy. *J Endod.* 2010 Jul;36[7]:1187–90.
20. Freire-Maia B, Machado VD, Valerio CS, Custódio ALN, Manzi FR, Junqueira JLC. Evaluation of the accuracy of linear measurements on multi-slice and cone beam computed tomography scans to detect the mandibular canal during bilateral sagittal split osteotomy of the mandible. *Int J Oral Maxillofac Surg [Internet].* 2017;46[3]:296–302. Available from: <http://dx.doi.org/10.1016/j.ijom.2016.11.007>
21. Saito K, Araújo NS de, Saito MT, Pinheiro J de JV, Carvalho PL de. Analysis of the mental foramen using cone beam computerized tomography. *Rev Odontol UNESP* 2015;44[4]:226–31
22. Shah N, et al. CBCT-Based Evaluation of Root Canal Configurations of Mandibular Second Molars and Their Relation to Mandibular Canal in Central Gujarat Population-A Cross-Sectional Study. *J Dental Sci* 2022, 7[1]: 000329. 2022;8.
23. Lu TY, Yang SF, Pai SF. Complicated root canal morphology of mandibular first premolar in a Chinese population using the cross section method. *J Endod.* 2006 Oct;32[10]:932–6.
24. Shetty A, Hegde MN, Tahiliani D, Shetty H, Bhat GT, Shetty S. A Three-Dimensional Study of Variations in Root Canal Morphology Using Cone-Beam Computed Tomography of Mandibular Premolars in a South Indian Population. *J Clin Diagn Res JCDR.* 2014 Aug;8[8]:ZC22–4.
25. Salarpour M, Farhad Mollashahi N, Mousavi E, Salarpour E. Evaluation of the effect of tooth type and canal configuration on crown size in mandibular premolars by cone-beam computed tomography. *Iran Endod J.* 2013;8[4]:153–6.
26. Park JB, Kim N, Park S, Kim Y, Ko Y. Evaluation of root anatomy of permanent mandibular premolars and molars in a Korean population with cone-beam computed tomography. *Eur J Dent.* 2013 Jan;7[1]:94–101.
27. Sheth K, Banga KS, Pawar AM, Gutmann JL, Kim HC. Shape and anatomical relationship of the mental foramen to the mandibular premolars in an Indian sub-population: a retrospective CBCT analysis. *Restor Dent Endod.* 2022 Feb;47[1].