

Navigating Complexities: Mandibular Imaging in Breast Cancer and Dental Implant Interactions

Abstract

Neoplasms are uncontrolled growth of abnormal cells that can invade surrounding tissues and produce metastasis. At the molecular level, cancer is distinguished by mutations in genes that regulate the cell cycle, apoptosis, and DNA repair. These mutations can cause uncontrolled cell proliferation. Bone metastases in the jaw are relatively rare compared to other bone locations, such as the spine and ribs. However, when they occur in the jaw or maxilla, they can cause localized pain, inflammation, abnormal tooth mobility, and bone lesions visible on x-rays. In terms of oral implantology, challenges have arisen when we talk about rehabilitation using dental implants. Although there is no direct evidence to suggest that implant placement itself activates or induces neoplasia growth, the process of implant placement and the condition of the affected jaw may influence the management and course of the disease. Implant placement must be carefully planned in collaboration with the oncology team, since oncology treatment may affect the viability of the implant. The clinical case of a 57-year-old female patient who was diagnosed with breast cancer in 2019 and discharged by the treating oncologist in 2023 is presented. After that, the patient goes to the Mexican Center for Stomatology Campus Morelia at in order to be rehabilitated with dental implants in the jaw. The implantation is carried out and a radiographic follow-up is carried out for one year with an interval of 6 months in order to clarify that there is no risk of metastasis to the jaw.

Keywords: breast cancer, dental implant, metastasis, jaw

Introduction

Neoplasms are characterized by the uncontrolled growth of abnormal cells that can invade surrounding tissues and produce metastasis. This deregulated growth is the result of genetic and epigenetic alterations, as well as the cumulative influence of environmental factors on cells, leading to uncontrolled cellular behavior. At the molecular level, cancer is distinguished by mutations in genes that regulate the cell cycle, apoptosis, and DNA repair. These mutations can cause uncontrolled cell proliferation. Furthermore, alterations in tumor suppressor genes, such as TP53, can deactivate mechanisms that limit cell growth¹.

breast cancer

Breast cancer originates in the breast tissues, mainly in the ducts or lobes of the mammary gland. It is one of the most common types of cancer in women worldwide, although it can also affect men. The incidence of breast cancer has increased in recent decades. Within the subclassifications of breast cancer, there are invasive ductal carcinoma and invasive lobular carcinoma. Additionally, breast cancer can be classified based on the presence of hormone receptors and overexpression of the HER2 gene²⁻⁴.

Metastasis occurs when cancer cells spread from the primary site to other parts of the body. This process is complex and involves the spread of tumor cells through the bloodstream or lymphatic system. The most common metastases from breast cancer are located in the bones, liver, lungs and brain. However, metastases have also been reported in bones such as the jaw⁴.

Jaw metastasis

Bone metastases in the jaw are relatively rare compared to other bone locations, such as the spine and ribs. However, when they occur in the jaw or maxilla, they can cause localized pain, inflammation, abnormal tooth mobility, and bone lesions visible on x-rays. In some cases, the involvement can be more severe and cause pathological fractures in the affected bone⁵.

Trauma response

Metastases to the mandible and maxilla often cause structural weakening of the bone due to tumor invasion. This can result in a reduction in local bone density, making it more susceptible to fractures from minor trauma or even pathological fractures. In addition, it can cause local bone erosion and destruction of bone tissue. Trauma, local inflammation, or any injury to the affected area can exacerbate the inflammation, potentially increasing pain and swelling⁶⁻⁸.

Imaging

On orthopantomography, mandibular metastasis presents as areas of radiolucent bone destruction due to loss of bone density; These radiolucent areas indicate bone destruction caused by the tumor. Alterations can also be observed in the cortical bone, which manifest as irregularities or loss of definition on the edges of the jaw. On computed tomography, metastasis may appear as lytic or sclerotic lesions, providing detailed visualization of the extent of the disease, including invasion of surrounding structures. Hounsfield units (HU) in lytic lesions typically range between -200 and +200 HU, while sclerotic lesions can exceed +1000 HU. On MRI, metastases appear as hypointense lesions on T1 sequences and as hyperintense lesions on T2 sequences. In scintigraphy, using radiopharmaceuticals such as technetium-99m, which accumulate in areas of altered bone activity, metastases usually present as areas of increased uptake^{8,9}.

Diagnosis

The diagnosis of mandibular metastasis is made through imaging and biopsy techniques. Computed tomography and magnetic resonance imaging are particularly useful in evaluating the extent and location of bone lesions. Additionally, bone scan is used to detect metastases in other parts of the skeleton¹⁰.

Oral implants in cancer patients

Placing an implant in a metastatic jaw presents specific challenges and can have important implications. Although there is no direct evidence to suggest that implant placement itself activates or induces neoplasia growth, the process of implant

placement and the condition of the affected jaw may influence the management and course of the disease. Tumor invasion into the area can make the bone less stable and more prone to complications such as infections or fractures. Additionally, implant placement may induce an inflammatory response at the surgical site. Although inflammation alone does not activate neoplasia, an inflammatory environment could potentially affect tumor behavior¹¹.

Implant placement must be carefully planned in collaboration with the oncology team, since oncology treatment may affect the viability of the implant. Therapies such as radiotherapy can negatively influence bone healing. Planning should include the following steps¹¹⁻¹³.

1. Clinical history and oncologic evaluation: Determine cancer status, including cancer type, stage, current treatment, and prognosis. It is also important to know previous and current treatments, such as radiotherapy, chemotherapy or hormonal therapy, which can influence bone health.
2. Dental and oral evaluation: Perform a complete dental health examination, evaluating gums, teeth and bone.
3. Jaw evaluation: Examine the quality and quantity of bone available at the implantation site, supported by x-rays, tomography and magnetic resonance imaging.

Implant planning should include consultation with the oncologist to design a comprehensive treatment plan. It is essential that all professionals involved are aware of the patient's conditions and treatment objectives, considering the implications of oncological treatment. The choice of the type of implant and the most appropriate surgical technique should be based on the quantity and quality of the bone available^{10,11}.

Bone density on CT scan is crucial for implant stability. In cancer patients, bone density can be affected by treatments such as radiotherapy, which can induce a reduction in bone density. The bone volume available for implant placement must be adequate, and CT provides detailed images to measure this. Surgical planning

should determine the optimal position of the implant, using cross-sectional CT scans to plan the exact location, angle and depth, ensuring stable placement¹³.

Clinical case

A 57-year-old female patient presents for consultation at the Mexican Center for Stomatology Campus Morelia, stating that she wishes to restore her mouth with implants. When taking the anamnesis, she mentions that she has been treated by the oncologist for breast cancer detected in 2019, being treated with 8 sessions of chemotherapy and discharged at the beginning of 2023.

The intraoral examination revealed the presence of prosthetic restorations in the dental organs and upper and lower removable prostheses. Figure 1.

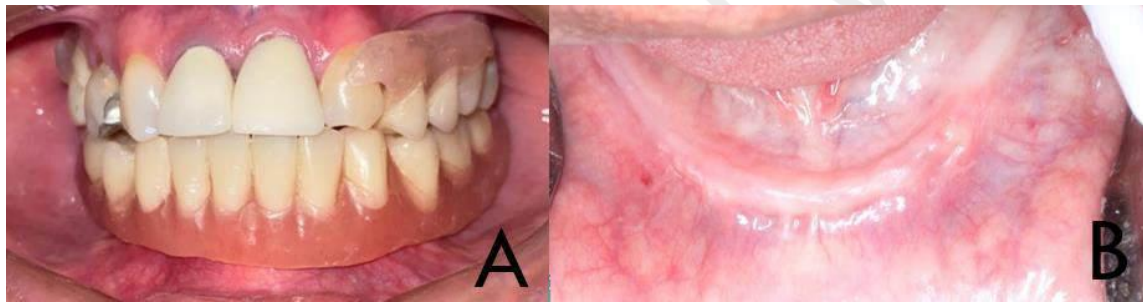


Figure 1: A) panoramic photograph of the oral cavity where the presence of restorations can be seen in dental organs 11,12, and the presence of a metal restoration in 14. Removable partial prosthesis can be seen in the maxilla and removable total prosthesis in the mandible. B) intraoral photograph of the jaw showing loss of bone height.

After communicating with the treating doctor and carrying out the necessary office and laboratory studies, it is determined that the patient is in a state of complete health to carry out the placement of dental implants. Laboratory studies and orthopantomography radiography, as well as computed tomography, are requested. Reporting erythrocytes of 5.2 million/AI, hemoglobin of 16.3g/dl, Hematocrit 48.1% platelets 284 million/AI, lymphocytes 11.1 million/AI, monocytes 8.1% million/AI, prothrombin time 13.3 seconds, INR 1.16 and partial thromboplastin time 25 seconds. Radiographically, residual ridge pathology is seen, with no data indicating

neoplastic growth in the mandibular bone. With the information collected, a consultation is requested with the treating oncologist who determines that the patient is in optimal health to undergo the surgical procedure. Figure 2.

Under regional anesthesia using articaine 1:200,000, we proceed to infiltrate with a truncal technique and supra-periosteal reinforcements in the mental region, infiltrate 288 mg. Once in the anesthetic plane, we proceed to implant four implants for the all-on-four technique with a guide. surgical. Planes are closed and prophylactic pharmacological therapy is indicated using amoxicillin 500 mg every 8 hours for 7 days and paracetamol 500 mg every 12 hours for 5 days. Figure 3.

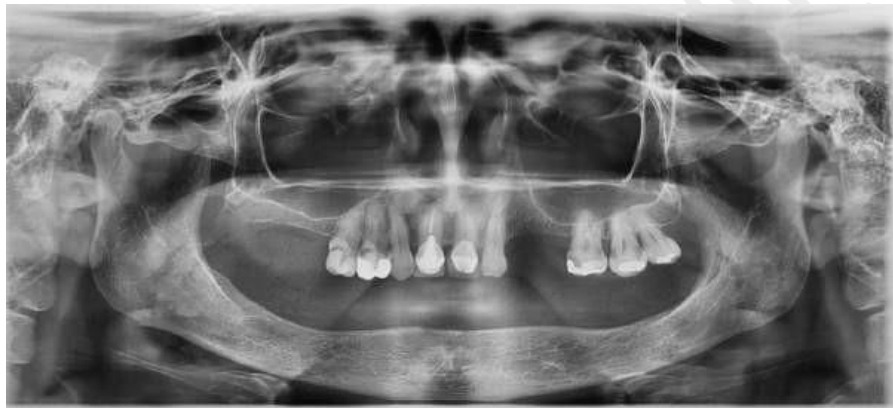

Figure 2: Panoramic radiograph with presence of remaining dental organs in the maxilla and presence of residual ridge pathology in the mandible. The presence of bone lesions is not appreciated.

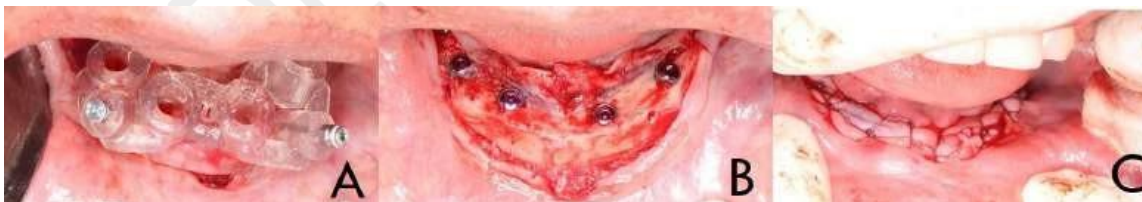

Figure 3: A) application of the surgical guide for the placement of dental implants for the all on four techniques. B) the implants implanted in the surgical bed can be seen. C) approximation of planes using 5-0 vicryl suture.

A 6-month radiographic review is indicated to assess the integrity of the implant and search for abnormal peri-implant growths. Figure 4.

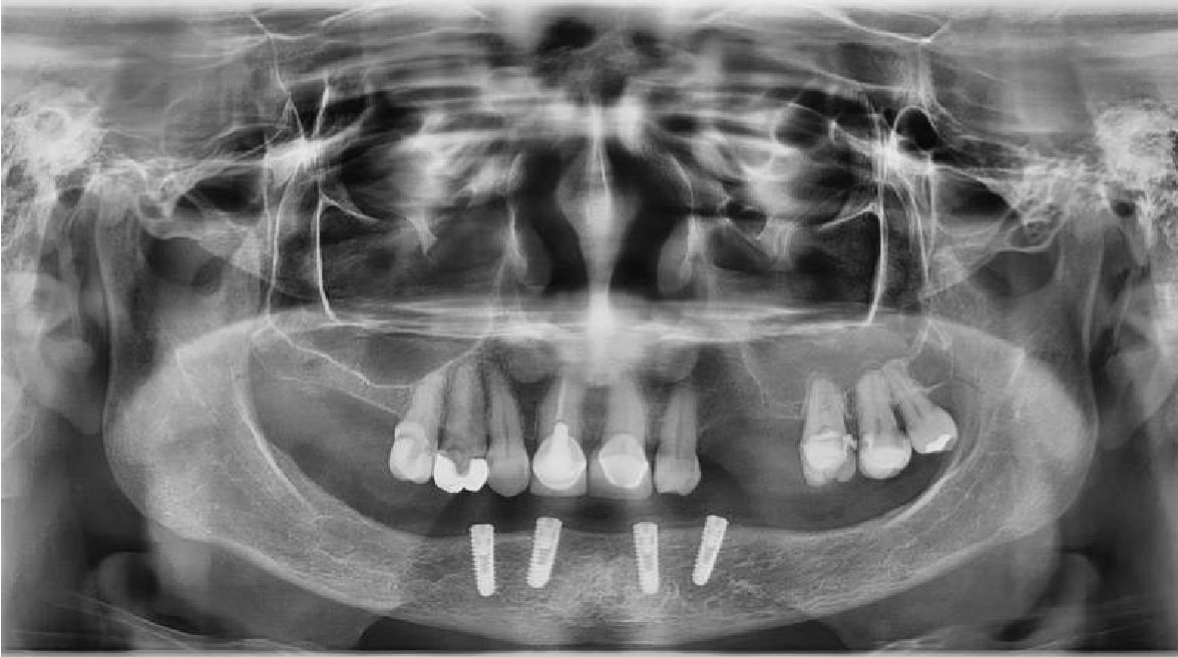


Figure 4: Panoramic radiograph showing the osseointegration of the four implants, with no signs of peri-implant growth, no bone loss or changes in the bone trabeculate.

After a year, another x-ray is requested in order to establish if there are structural changes. Figure 5.

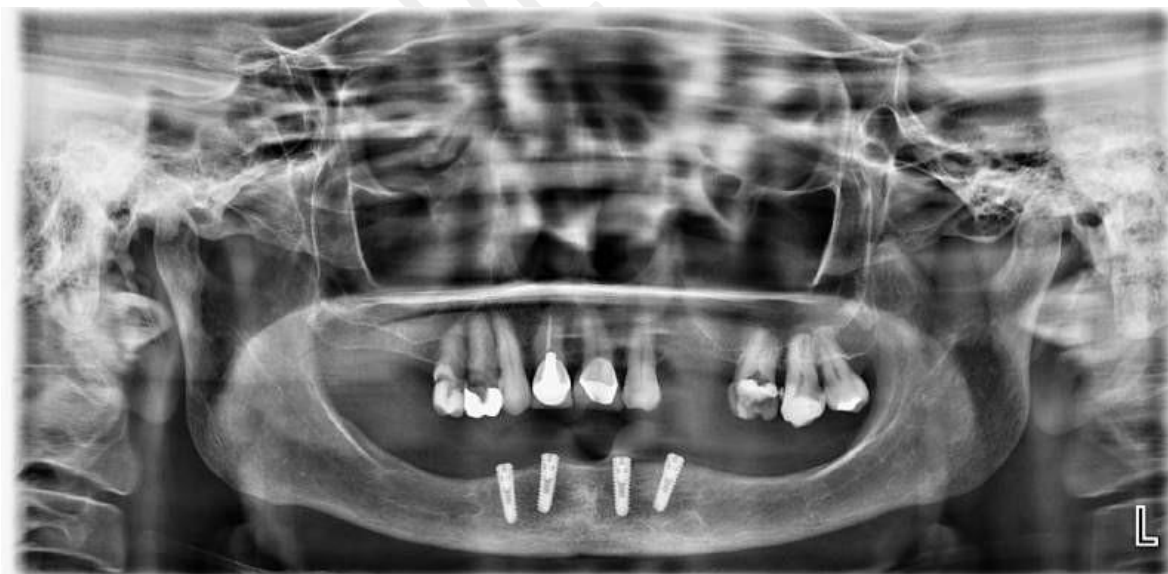


Figure 5: Panoramic radiograph one year after implant placement. There is minimal vertical bone decrease around the implants, there is no peri-implant bone loss, and no pathological anatomical changes are located.

Discussion

Alberga MJ, et al in 2020 carried out a study where they evaluated the placement of mandibular implants immediately after tooth extraction in patients with head and neck cancer, reporting a total of 29 oncological patients who underwent ablative surgery and subsequently underwent to implant surgery. All implants were placed with antibiotic prophylaxis with amoxicillin/clavulanic acid, considering an osseointegration period of 3 months with an implant survival rate of 93.1%. A functional overdenture could not be made in 9 patients. All underwent at least 2 panoramic radiographs, one directly after implant insertion and one during the final evaluation. Calculating the change in marginal bone loss in millimeters in relation to the implant shoulder¹¹.

Favia G, et al, in 2015 established that dental implants are not related to an increased risk of drug-related osteonecrosis of the jaw. However, more cases of maxillary osteonecrosis related to peri-implant medications have been described, thus becoming a health problem. Furthermore, it is not uncommon to find metastatic cancer deposits in peri-implant sites and this may represent an additional complication to treatment¹⁴.

Dib LL, et al in 2007 reported that metastases in the oral cavity and jaws are rare, therefore, oral clinical manifestations could frequently simulate general pathological entities. Which makes diagnosis a challenging process for dentists. They described that trauma facilitates the growth of blood-borne tumors. The primary tumor being a breast adenocarcinoma¹⁵.

Saucedo-Padilla JD in 2020 Determined that the use of implants in the rehabilitation of oncological patients is supported in the literature, having the advantage of the stability and support it provides to prosthetic rehabilitation, consequently, functional improvement. Being that the failure of implants usually derives from the loss of osseointegration, caused by different factors, both local and external. Radiotherapy and chemotherapy prior to implant application are frequent complications¹⁶.

Conclusion

The use of dental implants is an effective alternative for prosthetic rehabilitation in patients who have lost one or more dental organs, being a safe and comfortable method. In the particular case of oncology patients, the success of the treatment is based on having constant communication with the treating oncologist who will determine when it is prudent to begin the surgical treatment of dental implants.

Cancer patients who were discharged can be treated like a normal patient, as long as the care criteria are met with antimicrobial pharmacological therapy and a correct imaging diagnosis prior to the surgical procedure.

Ethical Approval:

As per international standards or university standards written ethical approval has been collected and preserved by the author(s).

Consent

As per international standards or university standards, patient(s) written consent has been collected and preserved by the author(s).

Disclaimer (Artificial intelligence)

Option 1:

Author(s) hereby declare that NO generative AI technologies such as Large Language Models (ChatGPT, COPILOT, etc) and text-to-image generators have been used during writing or editing of manuscripts.

References

1. Del Pino M, Rodriguez CL, Ordi J. Pathways of vulvar intraepithelial neoplasia and squamous cell carcinoma. *Histopathology*. 2012;62(1):161-175. <https://doi.org/10.1111/his.12034>
2. Palmero PJ, Lassard RJ, Juárez-Aguilar LA, Medina-Nuñez CA. Breast cancer:

an overview. *Ángeles group medical record*. 2022;19(3):354-360.
doi:10.35366/101727

3. Osorio BN, Bello HC, Vega BL. Risk factors associated with breast cancer. *Cuban Journal of Comprehensive General Medicine*. 2020;36(2):e1147.

4. Silva BB, Barbosa-Lopes AB, Beatriz TM, Pereira-Nunes PL, Lenhani T, Dias-Junior SF, Faglioni-Boleta Ceranto DD. Breast cancer: a literature review. *Brazilian Journal of Health Review*. 2021;4(3):30-35. <https://doi.org/10.34119/bjhrv4n3-357>

5. De Sousa-Silva GT, De Oliveira-Santos BC, Martins-Coelho BM, Azevedo-Sena AV, Bezerra-Pinto AS, Conceicao-Pinto MS, Da Paz OG. Mandibular osteonecrosis associated with a patient with breast cancer: case report. *FOCO Magazine*. 2023;16(9):1-13.

6. Ventura MS, García MC, Ortigosa SE, García-Vela JA, Thuissard-Vasallo IJ, Lorente-Ruifernández MT, Gallego GP, Martín RI, Esteban A. Immune response in breast cancer surgery. Comparative and prospective study of different anesthetic techniques. *Spanish Journal of Anesthesiology and Resuscitation*. 2022;69(6):336-344.
7. Barnabas-Mamani GM. Surgical-pharmacological treatment of osteonecrosis of the jaws in adult patients. (clinical surgical specialty thesis in oral surgery and hospital stomatology). Universidad Mayor de San Andrés Faculty of Dentistry Postgraduate Unit. 2023. <https://repositorio.umsa.bo/bitstream/handle/123456789/35000/TE-100.pdf?sequence=1&isAllowed=y>
8. Vargas A, Villaroel DM, Sanchez G, Manresa C. Simple imaging as an adjuvant in the diagnosis of lung metastasis in the oral cavity. Presentation of the case. *Dentomaxillofacial imaging report*. 2023;2(2): 12-25. <https://doi.org/10.60094/RID.20230202-26>
9. Escalona CN, Merino KP, Cartes VR. Use of 3D printing techniques in mandibular revolution. A brief review. *CES dental*. 2022; 34(2):1-14.
10. Argumedo-Pizaña YC, Perea-Ortega LM, Sánchez-Nieto JM. Diagnosis of oral cancer in the anterior area of the mandibular ramus in an older adult. Clinical case. *Cases and health reviews*. 2023;5(1):12-18.
11. Host MJ, Korfage A, Raghoobar MG. Mandibular dental implant placement immediately after teeth removal in head and neck cancer patients. Supportive care in cancer. 2020;28(1):5911-5918.
12. Zavattoni E, Ramieri G, Giovanni A, Massimo F, Garzino D, Paola MD, Borbon C. *Journal of craniofacial surgery*. 2021;32(2):e134-136. DOI: 10.1097/SCS.0000000000006874
13. Gonzalez GF, Redondo-González LM. Protocol of the oncology and reconstructive surgery unit in head and neck cancer. (undergraduate thesis).

University of Valladolid. Faculty of Medicine. 2021.
<https://uvadoc.uva.es/handle/10324/47510>

14. Favia G, Tempesta A, Limongelli L, Crincoli V, Piattelli A, Maiorano E. Metastatic Breast Cancer in Medication Related osteonecrosis around mandibular implants. American Journal of case reports. 2015;16(1):621-626. doi:10.12659/AJCR.894162

15. Dib LL, Soares AL, Lazzari SR. Breast metastasis around dental implants: case report. Clinical implantology and related research. 2007;9(2):112-115.
<https://doi.org/10.1111/j.1708-8208.2007.00033.x>

16. Saucedo-Padilla JD. Success of rehabilitation on implants in patients with oral cancer. (bachelor's degree thesis). University of Seville. 2020.
<https://idus.us.es/bitstream/handle/11441/105558/%c3%89xito%20de%20rehabilitaci%c3%b3n%20sobre%20implantes%20en%20pacientes%20con%20c%c3%a1nc er%20oral .pdf?sequence=1&isAllowed=y>