

# **CHEVRON BONE AND OS PENIS IN DOG: STRUCTURAL AND FUNCTIONAL ANATOMY**

---

## **ABSTRACT**

The study was conducted to record the structural and functional anatomy of chevron bone and os penis in dogs. The chevron bone along with coccygeal vertebra and os penis were collected from three adult dogs by natural wet maceration technique. The chevron bone was alphabet capital “V” or “Y” shaped bone which consisted of three processes namely, two lateral process and one ventral process. The two lateral processes were articulated with the haemal process of coccygeal vertebrae to form haemal canal. The chevron bones functionally protect the middle coccygeal artery which has important clinical role in assessing the animal health. The os penis was a heterotrophic bone situated inside the penis. It was triangular in outline with a base, a body and an apex. The body consisted of three surfaces and three borders. The ventral surface was made up of deep urethral sulcus which accommodated and protected the urethra.

*Keywords: Chevron bone, os penis, dog, structure, function, anatomy*

## **1. INTRODUCTION**

The prime intention of this study is to observe and document two important unusual bones present in dog which has peculiar features and clinical importance. The dog is a carnivorous mammal (*Canis familiaris*) closely related to the gray wolf that has been domesticated as a pet. They are broadly classified into different breeds based on their phenotypic characters, like size, shape, coat colour & pattern and is sometimes trained to perform special tasks such as herding, guarding, or acting as a service animal. The skeleton of tail is made up of the coccygeal vertebra in dog. The chevron bone presents as a separate bone articulated with coccygeal vertebra in domestic, wild even extinct animals like domestic dog [1, 2, 3], Beaked whale and Dolphin [4], Mink [5], Wild squirrel [6], Members of Sauropoda (Dinosaurs) [7, 8]. The presence of chevron bone in the coccygeal vertebrae helps to protect important arteries and veins, collectively called as vascular bundle which passes through it, which has not only clinically important function in domestic animals but also act as vascular counter current heat exchanger in Whale and Dolphin [4]. The os penis is another special bone present in penis of male dog, it is believed that the distal part of corpus cavernosum was converted into an os penis [1,2,9], which helps during copulation and protect the urethra. Apart from the canine family, the os penis is also observed in members of mink family and some rodent species as well as seals, walruses, and racoons [10]. Although apparent details about chevron bone and os penis are available in few textbooks and articles, but detailed structural and functional anatomy of chevron bones and os penis in dog is not available. Hence the present work was taken to document the detailed morphological features of chevron bone and os penis in dog for its clinical benefits.

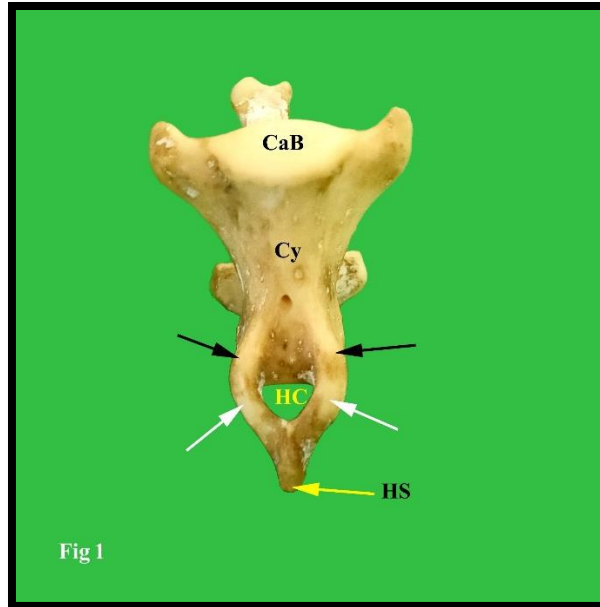
## **2. MATERIAL AND METHODS**

This study was conducted in chevron bones and os penis of four adult dogs which were donated by the owner after natural death to the Department of Veterinary Anatomy, Veterinary College and Research Institute, Theni for educational and research purpose. The dead carcasses were collected and processed by natural wet maceration technique [11] to separate the bones from other soft tissues and their attachments. Bones collected after maceration were soaked with 10 % bleaching powder solution for overnight to remove the minor tissue debris and make it white [12]. Finally, the coccygeal vertebrae along with chevron bones and os penis were identified and separated carefully. Then, the bones were photographed and studied for its peculiar gross anatomical features.

## **3. RESULTS AND DISCUSSION**

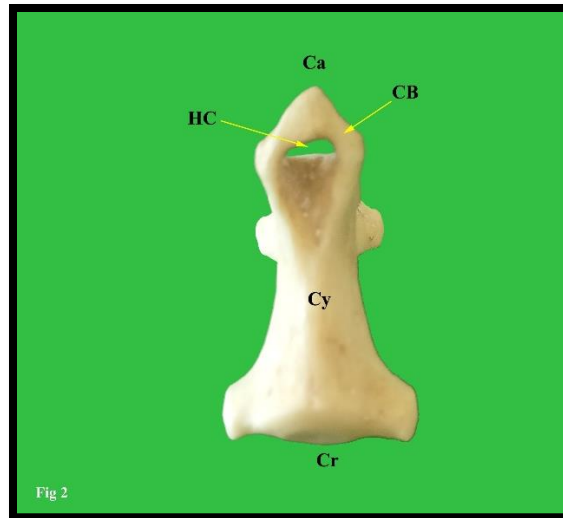
### **3.1 CHEVRON BONES**

The chevron bone also known as haemal arch was a special bone present in dog which were articulated with the body of third to sixth coccygeal vertebrae at posterior end on its ventral aspect (Fig 1). The chevron bone and coccygeal vertebrae articulated near its intercentral junction with subsequent coccygeal vertebrae as mentioned by [2] in dogs, who stated that haemal arches are present as separate bones that articulate with the ventral surfaces of the caudal ends of the bodies of the fourth, fifth, and sixth caudal vertebrae. [13] documented in dog, that the haemal processes are developed from the 4th caudal vertebra and become gradually indistinct caudally. On the 4th to the 7th or 8th caudal vertebra, they may unite to form a haemal arch. [1] stated that the haemal arches were found at caudal end of ventral surface of 4th to 6th coccygeal vertebra of dog. But contradicted with [14] in Ruppell's fox, who observed absence of haemal arch, instead presents of triangular haemal foramen in the 4<sup>th</sup> and 5<sup>th</sup> coccygeal vertebrae at its anterior centrum. The ventral aspect of coccygeal vertebrae comprised of a pair of processes called as the haemal processes (Fig 1). The haemal processes were very short and blunt, which alone enclosed a narrow space (haemal canal) at its middle in other domestic animals. Where as in dog, the space was created by the fusion of haemal processes of coccygeal vertebrae with lateral processes of chevron bone (Fig 1 & 2).



**Fig 1:** Showing ventral view of 'Y' shaped chevron bone fused with coccygeal vertebra (Cy). Haemal spine (HS), Haemal canal (HC), Caudal end of vertebral body (CaB), Haemal processes of coccygeal vertebrae (Black arrows), Lateral processes of chevron bone (White arrows).

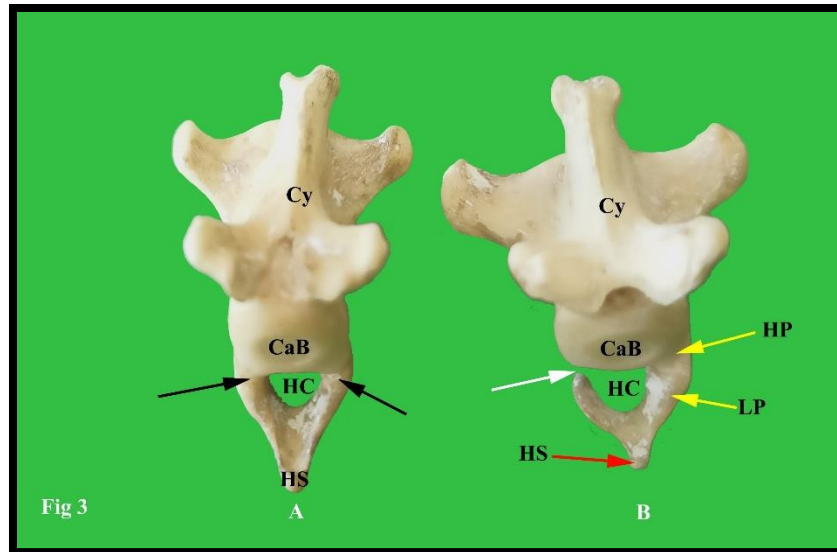
The chevron bones were capital "V" or "Y" shaped individual bone as reported by [2] with three processes (Fig 1 & 2). These are in accordance with the observations of [15] in carnivores. They were two lateral processes and one ventral process. The lateral processes were short, thin, flat and became thick after fused with each other and continued as ventral process. The ventral process extended from the fused part of two lateral process and they are also known as haemal spine (Fig 1). The haemal spine was thin at its origin and became thick then end as blunt in some coccygeals and pointed in some coccygeals. The articulation between the proximal end of lateral processes of chevron bone and haemal process of coccygeal vertebra were transformed from cartilaginous nature to ossified state as the age advances, which makes the separate chevron bone as a part of coccygeal vertebra (Fig 3A & B).



**Fig 2:** Showing ventral view of 'V' shaped chevron bone (CB) fused with coccygeal vertebra, Haemal canal (HC), Cranial end of vertebral body (Cr) and Caudal end of vertebral body (Ca).

The haemal spine was directed downward and backward, the spine presented with shallow groove dorsally, which may provide protection to the structure passes through the chevron bones. Based on the length of the haemal spine, the chevron bones get the shape either as alphabet 'V' or 'Y' (Fig 1 & 2). Similar findings were also recorded by [8] in carnivores, who stated that "V-shaped" chevron bones consisted of two dorsal rami that created a haemal canal, converged ventrally to a point, and articulated either directly with the ventral side of the vertebral bodies or with haemal processes extending ventrally from the vertebrae. "Y-shaped" chevron bones similarly possessed two rami, but instead of simply merging into a point, an additional process extended ventrally, like the stem of an uppercase "Y." The space between the lateral process of chevron bone and haemal processes of coccygeal vertebrae were known as haemal canal where middle coccygeal artery was lodged, which is used for recording the pulse in animals. The free movement and bending of tail in dog mostly likely take place at the level of third to sixth coccygeal vertebrae. Hence the extensive free movement of the tail in dog makes the middle coccygeal artery to easily get strangulated at inter-central articulation between adjacent vertebrae. To prevent the artery from damage, the chevron bones might have developed in coccygeal vertebrae especially between second to sixth coccygeal vertebrae of dog.

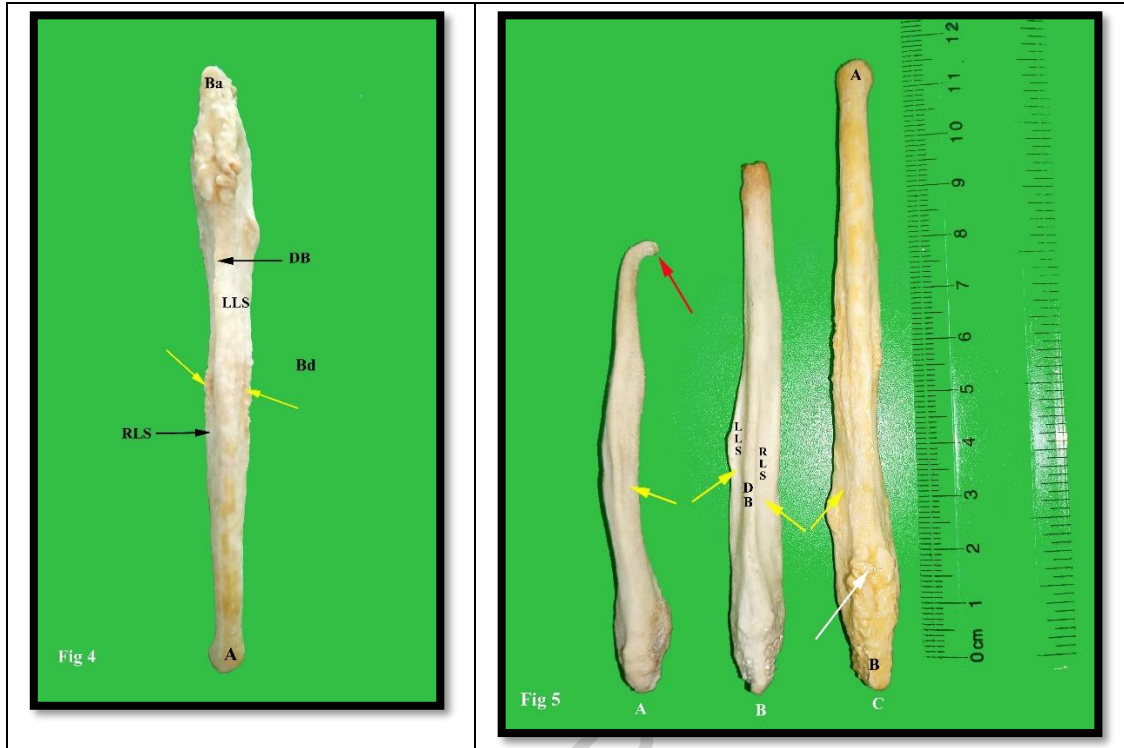
[7] observed four subtypes of Y-shaped haemal arches, Straight and open Y-shaped; Straight and closed Y-shaped; Curved and open Y-shaped and Curved and closed Y-shaped and Six subtypes of V-shaped haemal arches were Straight and open V-shaped; Curved and open V-shaped; Curved and closed V-shaped; Forked and open V-shaped; Forked and closed V-shaped and Asymmetric and open V-shaped in members of sauropods. But in the present study, all chevron bones were "curved and open Y shaped" and "open V shaped" in all the dog.



**Fig 3A:** Showing Posterior view of 'Y' shaped chevron bone fused (Black arrows) with coccygeal vertebra (A). **Fig 3B:** Showing chevron bone right side process fused with coccygeal vertebra, leaving left process open (White arrow), due to decomposed cartilaginous articulation. Coccygeal vertebra (Cy), Caudal end of vertebral body (CaB), Haemal canal (HC), Haemal spine (HS), Haemal process of coccygeal vertebra (HP) and Lateral process of chevron bone (LP).

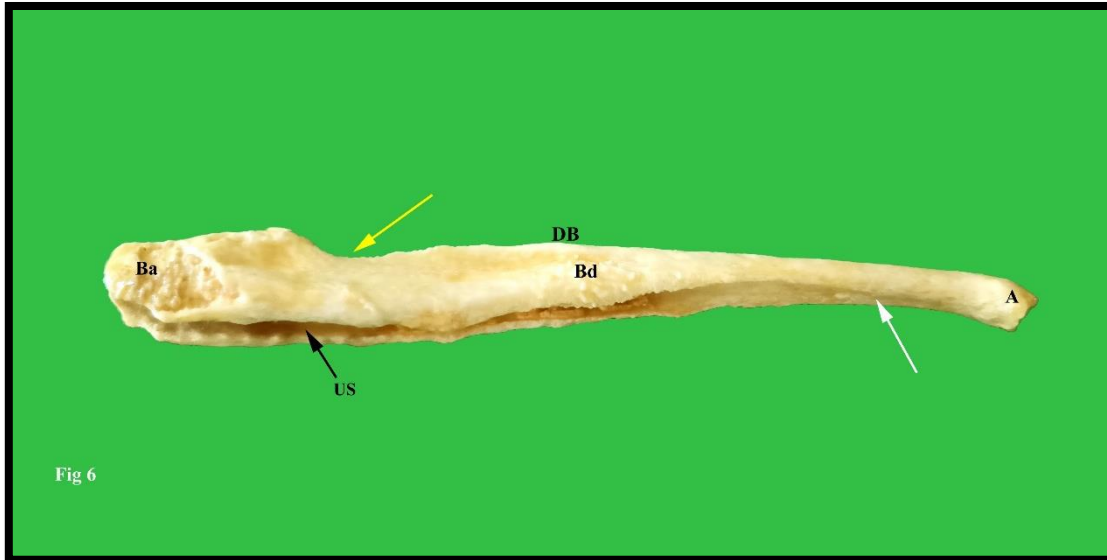
### 3.2 OS PENIS

The os penis also known as baculum [16] or os priapi [17] was a rare heterotrophic bone situated inside the penis of male dog. The os penis was triangular in outline with three sides, which extended from the root of the penis to the tip of penis (Fig 4). The maximum length of os penis in this study was 11.5 cm and length of urethral sulcus was 7.5 cm (Fig 5C), whereas, minimum length of os penis was 8.0 cm and length of urethral sulcus was 6.0 cm (Fig 5A). These observations were in accordance with [2,18,19], who observed that the length of os penis in large dog was 10 cm. But [9] observed 13 cm long os penis in local dog in his study. Also, [16] measured the overall length of the bacula varied between 83 and 128 mm (n = 9) with a mean: 104.4 mm. The os penis was made up of three surfaces, three borders, a base, a body and an apex (Fig 6) as reported by [16,20] in dogs. But [17] in dog, along with base, body, apex, he also considered cartilage as a part of os penis.



**Fig 4:** Showing dorsal view of os penis of adult male dog. Base (Ba), Apex (A), Right lateral surface (RLS), Left lateral surface (LLS), Dorsal border (DB) in the form of sharp crest, Body of os penis (Bd), Pitted rough areas presented on both lateral surfaces (Yellow arrows). **Fig 5A:** Showing smallest os penis of this study with laterally curved body and hook like apex (Red arrow). **Fig 5B:** showing os penis with Dorsal border (DB), Grooves (yellow arrows) in Right lateral surface (RLS), Left lateral surface (LLS). **Fig 5C:** Showing thick and wide base with rough pitted area and bifid dorsal border (White arrow) in longest os penis of this study.

The thickness of the os penis was broad at the base then decreases gradually ends as blunted narrow tip. The three surfaces were two lateral surfaces and one ventral surface, three borders were one dorsal border and two lateral borders. The dorsal border was in form of sharp crest which separated the two lateral surfaces distinctly. The two lateral surfaces presented with a groove and pitted rough areas for the attachment of muscles (Fig 5B). The two lateral borders were thick, convex and blunt, which converge downward and inwards, so that it enclosed a deep groove in the ventral surface from the base of the os penis till anterior one third length of the os penis. This deep groove in the ventral surface called as urethral sulcus, since it accommodated urethra during life (Fig 6) as already observed by [9,21]. The body was the longest portion among the three parts of os penis. Most of its length was triangular in outline, then continued cranially with apex.



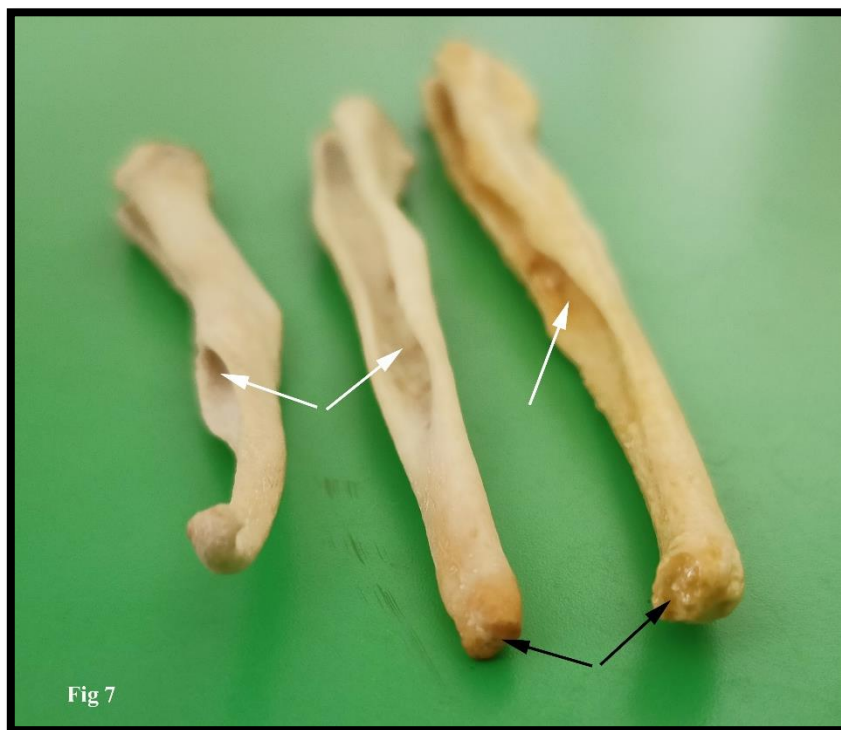
**Fig 6:** Showing lateral view of os penis. Base (Ba), Body (Bd), Apex (A), Dorsal border (DB), Urethral sulcus on ventral aspect (US), Depression on dorsal border just cranial to base for attachment of bulbous glandis (Yellow arrow) and flat ventral surface of apex of os penis with no sulcus (White arrow).

The position of urethra inside the urethral sulcus makes it as clinical importance because of the narrow entrance of the urethral sulcus at base of os penis may block the passage of urinary calculi via the urethra. Hence, it leads to positive as well as negative impact on functionality of the os penis. Positively, the urethra was well protected by the os penis from the external injury or damage. Whereas, negatively the urethra was covered by the os penis in dorsal, lateral and to some extent ventro-lateral aspect, leaving the ventral aspect of urethra uncovered by the os penis. This uncovered portion leads to dilatation or bulging out of urethra ventrally due to the pressure exerted by the calculi obstruction. The depth of the urethral groove was deeper at the level of junction between base and body of os penis, which decreases gradually towards anterior end as stated by [20] in dogs. Due to the deep location of urethra inside the os penis, caused frequent obstruction of urethra due to calculi which get easily lodged at the base of the urethral sulcus as opined by [22, 23] in dog. The preferred site for approaching urethra was mid ventral plane of penis, where the urethra was covered only by corpus spongiosum muscle.

The base of the os penis was thick and wide contained rough thick pitted areas (Fig 4) on both lateral aspect for the attachment of ligaments and other muscular structures. Just anterior to the base of the os penis, a depression was observed on its dorsal border for the attachment of bulbous glandis muscle (Fig 6). At the base of os penis, the dorsal border was bifid in appearance and ends as small tubercle, which was restricted to base posterior to the groove where bulbous glandis was attached (Fig 5C).

The apex of os penis was conical in shape with slightly flat ventral surface with no urethral sulcus (Fig 6). The anterior end of the apex of os penis was rough and pitted in appearance, which indicated its fibrocartilaginous continuation (Fig 7). This coincides with [24] in dog, who observed terminal cartilaginous portion of os penis at its apex end. The thickness of the apex of os penis varied between the individual animals was determined by their age, sex, breed, nutritional status and sexual activity. In the present study, the varied apex of the os penis observed was less thick and blunt, pointed, even the tip was directed downward,

twisted and turned backward formed hook like bend. These structural variations were also observed by [25] who reported almost ten different types of os penis in mustelidae family. Likewise, the varied structural differences in body of os penis observed was straight, dorsally curved body, ventrally curved body and laterally curved body of os penis.



**Fig 7:** showing rough and pitted anterior end of the apex of os penis (Black arrows) and Urethral sulcus (White arrows).

The line of demarcation between base, body and apex in os penis was indistinct. Arbitrarily the body of os penis started from the groove where bulbous glandis attached. Apex started from the region, where the urethral sulcus ends. Structure of the os penis directly influenced its functionality and surgical conditions. The importance of os penis in dog is to provide rigidity to penis for act of intromission, due to the delayed erection of bulbous glandis and glans penis during copulation as opined by [17].

#### **4. CONCLUSION**

In conclusion, the chevron bones and os penis are two fascinating anatomical special bones that play critical roles on the canine health. The chevron bones provide vital support and protection to the middle coccygeal artery and other structures passes through it. While, the os penis supports the penis during copulation and micturition as well as protect the urethra. Understanding these two structures is essential for the veterinarians, academicians, researchers, and dog owners to recognize and address potential health issues, surgical conditions and to develop effective treatment and management strategies related to it.

## DISCLAIMER (ARTIFICIAL INTELLIGENCE)

Authors hereby declare that, no generative AI technologies such as Large Language Models (ChatGPT, COPILOT, etc) and text-to-image generators have been used during writing or editing of manuscripts.

## REFERENCES

1. Singh B. Dyce, Sack and Wensing's Textbook of Veterinary anatomy. 5th ed, Elsevier, Missouri, 2018, 395 & 455.
2. Evans HE and de Lahunta A. Miller's Anatomy of the Dog. 4<sup>th</sup> ed, Elsevier Saunders, Missouri, 2013, 125 & 379.
3. Getty, R. (1975) 'Sisson and Grossman's the Anatomy of the Domestic Animals. W.B. Saunders Comp.', Philadelphia. pp. 1427-1482.
4. Rommel SA, Costidis AM, Fernández A, Jepson PD, Pabst DA, Mclellan WA. et al. Elements of beaked whale anatomy and diving physiology and some hypothetical causes of sonar-related stranding. *Journal of Cetacean Research and Management*. 7(3):189–209, 2006 189
5. Dursun N and Tipirdamaz N. 'Etudes macro anatomique-ment sur les os du squelette du vison (*Mustela vison*)', *J. Fac. Vet. Med. Univ Selçuk*, 1989; 5:13-27.
6. Grasse PP. *Traité de Zoologie, Anatomie, Systématique, Biologie*, Masson et Cie., Paris. 1967. 593-632.
7. Oteroa AB, Gallinac PA, Canaleb JI and Haluzad A. Sauropod haemal arches: morphotypes, new classification and phylogenetic aspects. *Historical Biology* iFirst article, 2011, 1–14
8. Mannion PD, Upchurch P, Schwarz D and Wings O. Taxonomic affinities of the putative titanosaurs from the Late Jurassic Tendaguru Formation of Tanzania: phylogenetic and biogeographic implications for eusauropod dinosaur evolution. *Zoological Journal of the Linnean Society*, 2019, 185, 784–909.
9. Alaa HS. Anatomical and histological study of local dog penis. *Mirror of research in veterinary sciences and animals*. 2016; 5 (3): 8-14. DOI: 10.22428/mrvsa. 2307-8073.2014.002184.x
10. Bone JF. *Animal Anatomy and Physiology*. Reston publishing company, Inc., Reston, Virginia, 1979.
11. Tamilselvan S, Iniyah K, Jayachitra S, Sivagnanam S, Balasundaram K and Lavanya C. Gross anatomy of Os coxae of Ostrich (*Struthio camellus*). *International Journal of Current Microbiology and Applied Sciences*. 2015; 4(4): 201-205.
12. Tamilselvan S, Jaiswal P, Mrigesh M, Singh B, and Mahanta D. Morphology of femur, tibiotarsus and fibula of local hill fowl of Uttarakhand. *Indian Journal of Veterinary Sciences and Biotechnology*. 2018; 13(4): 84-87.
13. Budras KD, McCarthy PH, Fricke W, Richter R. *Anatomy of the Dog*. 5<sup>th</sup> revised ed, Schlutersche. Germany, 2007, 8.
14. Youssef AK, Ahmed AW and Darnawi NA. Morphological study of the vertebral column and thoracic cage of the Rüppell's fox (*Vulpes rueppellii*) in the Benghazi area. *Libyan Journal of Science & Technology*, 2022; 14(1): 21-27
15. Zavodszky AM and Russo GA. Comparative and functional morphology of chevron bones among mammals. *Journal of Mammalogy*. 2020; 101(2): 403-416. DOI:10.1093/jmammal/gyaa010
16. Sharir A, Israeli D, Milgram J, Currey JD, Monsonego-Ornan E, and Shahar R. The canine baculum: the structure and mechanical properties of an unusual bone. *Journal of Structural Biology*. 2011; 175(3): 451-456. doi:10.1016/j.jsb.2011.06.006

17. Arnold RA. (1961). Anatomical and surgical considerations of the os penis of the dog as related to correction of urethral obstruction by calculi. A master thesis submitted to the Kansas university, Manhattan, Kansas.
18. Sisson and Grossmans. The anatomy of domestic animals. Vol 2 Chapter 53. W.B, Sundares co., Philadelphia, London, Toronto: 1975, 1583.
19. Salman MD and Dawood MS. Morphological and morphometrical study of penis in indigenous dog. *Biochemical & Cellular Archives*. 2022; 22(1): 1903-1909. DocID: <https://connectjournals.com/03896.2022.22.1903>
20. Misk NA, Ahmed IH and Ismail SF. Os penis in dogs. *Assiut Veterinary Medical Journal*. 1996; 35(69): 115-122. DOI: 10.21608/avmj.1996.183930
21. Patel VA, Bhayani DM and Harish bhai P. Gori. Sonoanatomical Studies on Penis of Dog (*Canis familiaris*). *International Journal of Current Microbiology and Applied Sciences*. 2019; 8(11): 1566-1572. <https://doi.org/10.20546/ijcmas.2019.811.181>
22. Venugopalan A. *Essentials of veterinary surgery*. 8<sup>th</sup> ed, Oxford & IBH Publishing. 2018, 155.
23. Boyd JS, Peterson C, May AH. *Colour atlas of clinical anatomy of the dog and cat*. 2<sup>nd</sup> ed, Mosby International Limited. An affiliate of Elsevier science limited, USA, 2001, 449.
24. Payan-Carreira R and Bessa ACM. Application of B-mode ultrasonography in the assessment of the dog penis. *Animal reproduction science*. 2008; 106(1-2): 174-180. doi:10.1016/j.anireprosci.2007.12.025
25. Baryshnikov GF, Bininda-Emonds OR and Abramov AV. Morphological variability and evolution of the baculum (os penis) in Mustelidae (Carnivora). *Journal of Mammalogy*. 2003; 84(2): 673-690. [https://doi.org/10.1644/1545-1542\(2003\)084<0673:MVAEOT>2.0.CO;2](https://doi.org/10.1644/1545-1542(2003)084<0673:MVAEOT>2.0.CO;2)