

INVESTIGATING THE PROTECTIVE EFFECTS OF ASCORBIC ACID AGAINST PARACETAMOL-INDUCED LIVER TOXICITY IN WISTAR RATS

Abstract

Paracetamol is one of the most widely used analgesics and antipyretics but can cause severe liver damage at high doses. This study explores the potential protective effects of ascorbic acid (vitamin C) against paracetamol-induced hepatotoxicity in Wistar rats. For this experimental study, 25 mature male Wistar rats, weighing 140–180g, were placed into five groups which were divided into five groups: Group 1 stands for the Normal Control. Group 2 received 25 mg of PCM for 21 days, whereas Group 3 received 500 mg of ascorbic acid. Furthermore, after PCM was given, rats in groups 4 and 5 were given 500 mg and 1000 mg of ascorbic acid, respectively. Following PCM and Ascorbic acid treatment, biochemical parameters and histoarchitectural studies were examined. Histopathological examination of liver tissue was performed to evaluate cellular architecture and damage. Results indicated that treatment with ascorbic acid significantly mitigated the elevation of liver enzymes and histopathological changes compared to the paracetamol-only group. In conclusion, the research underscores the potential role of ascorbic acid in safeguarding liver function.

Keywords

Paracetamol, Ascorbic Acid, Hepatotoxicity, Liver Injury, Wistar Rats.

1.0.Introduction

Paracetamol (PCM) is an effective, widely used, and easily available ache and fever reliever. However, excessive paracetamol dosages can result in hepatotoxicity, which is among the most typical causes of drug-induced liver failure¹. Data from the Paracetamol KwaZulu-Natal Poison Control Centre indicate that paracetamol exposure in KwaZulu-Natal is a growing problem. Exposure to paracetamol could be due to overdoses or due to the continued use of conventional paracetamol therapy regimens at therapeutic doses. Overdose can follow a single very large dose or the regular use of a few large doses over time^{2, 3}. Problems occur when the level of paracetamol in the body becomes excessive. Most of the paracetamol is broken down by the liver and excreted in the urine^{4, 5, 6}. Harmful substances are produced when the liver breaks down paracetamol, and these do not usually cause any harm. However, the liver's ability to break them down can become overloaded, leading to the rapid buildup of harmful substances⁷.

Despite its widespread therapeutic applications, paracetamol or acetaminophen (N-acetyl-p-aminophenol) is one of the main factors contributing to abrupt liver failure in the world. Paracetamol may cause hepatotoxicity at therapeutic doses in individuals with undernourishment or fasting states or following chronic ethanol consumption at lower total doses than typically required to cause toxicity⁸. In these toxic states, drug elimination may follow a minor pathway involving CYP2E1. Furthermore, Paracetamol produces an oxidative toxic metabolite that is concentrated in the liver and extremely reactive. The chemistry of paracetamol metabolism plays a significant role in the subsequent clinical management of paracetamol hepatotoxicity and the development of nonsteroidal anti-inflammatory drugs to provide synthetic safe alternatives to aspirin⁸.

Paracetamol's hepatotoxicity ranges from minor biochemically noticeable harm to severe liver damage, and it is the primary reason behind severe liver failure in the UK⁹. Accidental paracetamol overdose is a potential public health emergency, with potential high morbidity and mortality and significant public health economic burden on the NHS. Broad public health risks arise from the combination of paracetamol's lethality, widespread use, common over-the-counter availability, and low public awareness of both the increased poisoning from paracetamol in overdose and the safe limits of ingestion¹⁰.

In experimental animals, vitamin C has been found to be effective in controlling fever toxicity. However, research on its beneficial doses for excessive paracetamol has caused some controversy. Ascorbic acid, in the disturbance of the gate syndrome, has been found to reduce liver tissue damage. It is believed that this can be explained by its antioxidant and complex anti-inflammatory activities that it may exert through its antioxidant and leukocyte-mediated activities^{11, 12}. Ascorbic acid is a small and simple compound that functions as an antioxidant, facilitates enzymatic functions such as the synthesis of dihydrocollagen, and facilitates cell differentiation. Moreover, the stability of the salts' higher order structures is one of the numerous significant biological processes in which ascorbic acid (AA) is engaged. According to reports, vitamin C can prevent many oxidative damages induced by various pro-oxidant feed¹². The supplementation of rats with ascorbic acid, N-acetylcysteine, and tocopherols resulted in improved liver function, as indicated by the decrease in alanine aminotransferase and the increase in liver superoxide dismutase, class H glutathione transferase, reduced glutathione transfer^{13, 14}. Superoxide amino transferase, decreased lipid peroxide, and increased glutathione concentrations were also observed. Purified vitamin C has been shown to decline the carnage of oxidative stress and prevent liver injury in parkotic rats. Despite this, some researchers believe that efforts to avoid the gathering of cytogenetic donations due to increased donations may lead to lower ascorbic acid than the endogenous donors, which are, in fact, less toxic to the cell¹². The search for a smaller molecule or inhibitor, a method of stimulating the antioxidative qualities of the liver, reducing NAPQI formation or a less toxic paracetamol metabolism pathway, has led to a long search for novel hepatoprotective drugs, including herbal products¹³. Antidote is the standard treatment of a paracetamol intoxication and protects against a wide range of antioxidants, although paracetamol is generally not a very toxic compound at therapeutic doses. N-acetylcysteine, an effective paracetamol antidote, is a precursor of hepatic GSH and replenishes hepatic GSH banks. In the setting of numerous failures or contraindications, there will be a time delay due to the steep drop in the hepatotoxicity level of the liver¹².

With normal therapeutic doses, this intermediate is usually sequestered by hepatic glutathione (GSH) and excreted as a cysteine conjugate and mercapturate. Excessive paracetamol results in a depletion of hepatic GSH stores due to the excessive production of NAPQI, which becomes overwhelmed, rendered toxic and binds to cellular proteins, and causes mitochondrial oxidative damage and hepatic function, leading to liver failure¹¹.

Thus, the goal of this work is to look at how ascorbic acid affects the histo-biochemical processes that cause paracetamol-induced hepatotoxicity in wistar rats.

2.0. MATERIAL AND METHODS

The materials used in the experimental study are as follows: Dissecting set, Ascorbic acid, Wistar rats, animal cages, Paracetamol, Digital weighing balance, water bottles, beakers, glass slides, 2ml syringes, Orogastric tubes, Graduated measuring cylinder set, Molten paraffin wax, Rotary Microtome, 10% Formal saline, Xylene, Ehrlich's Haematoxylin, Eosin, Phosphate Buffered Solution.

2.1. Animal care

Adult male Wistar rats weighing 145g–200g were used for this study. The rats were obtained and bred in the animal house of Achievers University Owo, Nigeria. They were housed in plastic cages in an animal core facility that was free of diseases, had good ventilation, and had free access to water and pelletized rat chow under carefully regulated lighting. The rats were given extract two weeks prior to the start of the acclimation period. All experimental and laboratory procedures were approved by the Research Ethics Committee on Animal use of Ministry of Agriculture Akure, Ondo State, Nigeria with reference number (MNR/V.384/7) and performed following the Animal Reforms Guidelines and the National Institute of Health Guide for Laboratory animal care and usage.

2.2. Experimental design

Twenty-five adult male Wistar rats, each with five animals, were randomly assigned to five groups for this experimental study. Group 1 – control fed with animal feed and water alongside with normal saline. Group 2 – Fed with Animal feed and water alongside with 52g of (Paracetamol)PCM dissolved in water. Group 3 – Fed with Animal feed and water alongside with 500mg of ascorbic acid. Group 4 – Fed with Animal feed and water alongside with 52g of PCM in water and 500mg of ascorbic acid. Group 5 – Fed with Animal feed and water alongside with 52g of PCM in water and 1000mg of ascorbic acid. This was done once daily and blood samples and tissues were obtained for histopathological and biochemical studies. All administrations were carried out orally once per day between 8:00 am, and 10:00 am daily.

2.3. PREPARATION OF DRUGS

Six 500 mg paracetamol tablets were ground up using a mortar and pestle, then diluted in distilled water.

100 mg of vitamin C

Making the medication solution: Using a mortar and pestle, five tablets containing 100 mg of vitamin C (a total of 500 mg) were ground up and then dissolved in 10 milliliters of regular saline. Before using, the solution is chilled.

2.4. Procedure for animal euthanasia and liver collection

Following the completion of PCM and Vitamin C administration, the rats were euthanised by cervical dislocation. After taking blood samples from jugular vein, the liver from each rat was rapidly excised and washed in sterile Phosphate buffer solution before fixed in 10% Neutral Buffer Formalin for histological investigation. In order to homogenize the remaining portions in a sterile Phosphate buffer solution and determine the antioxidant defense and oxidative stress indicators, they were stored in a deep freezer at -30° C.

2.5. Biochemical analysis

Liver samples were homogenised in a mortar and pestle with a pinch of acid-washed sand. A total of 5mls of normal saline (0.9%) was added sequentially during the homogenisation process. The homogenates were centrifuged at 350rpm for 5 minutes with a centrifuge. The clear supernatants were collected using a micropipette and transferred into an empty specimen container, and refrigerated until needed for the assays.

2.5.1. Glutathione (GSH) level assessment

Glutathione activity was determined by Udi, *et al.*¹⁴. The tissues were thawed in PBS Lysis buffer (pH 7.4) containing 320mM sucrose, 1% of 1.0 M Tris – HCL (pH = 8.8), 0.098 mM MgCl₂, 0.076 mM EDTA, phosphatase inhibitor cocktail. The tissues were homogenised by ten quick pulses using the hand homogeniser. The homogenates were centrifuged at 14,000× g for 10 minutes to remove cellular debris, and the supernatants were separated to determine the total protein concentration using the BCA method. A detection kit from Arbor assays (K006 – H1) was used to measure concentrations of total reduced and oxidised forms of GSH. Samples were then assayed for GSH and presented in µm/ml.

2.5.2. Measurement of superoxide dismutase (SOD) activity

The SOD activity was determined by Udi, *et al.*¹⁴ method. 0.4ml aliquot of the supernatant was added to 5ml of 0.05M carbonate buffer (pH 10.2) and equilibrated in the spectrophotometer for 2–3 minutes. This reaction procedure is based on the ability of SOD to inhibit the autoxidation of adrenaline.

2.6. Histological procedure and photomicrography

Liver tissues were processed using a standard histological technique. It entails fixing the Liver tissues in 4% paraformaldehyde, dehydration in ascending grades of alcohol, clearing in xylene, and impregnating tissues in molten paraffin wax. Tissues were embedded using molten paraffin wax and embedding moulds and sectioned using the rotary microtome. Liver slices of the rat were stained with hematoxylin and eosin, a routine histology stain. The stained tissue images were captured using a digital microscopic eyepiece, 'SCOPETEK DCM 500, 8.0 MEGA PIXEL', connected to a computer. The stained slides were interpreted with a light microscope and analysed for histological changes across the groups.

2.7. Statistical analysis

The biochemical analysis data were presented as means \pm SEM and analysed using one-way ANOVA. Student Newman Keuls (SNK) post – hoc test for multiple comparisons was carried out to determine mean notable variations among groups using SPSS version 21. Levels of statistical significance were set at $P < 0.05$.

3.0 RESULTS

The findings demonstrated that, in comparison to rats in the control group, the oral administration of paracetamol resulted in a statistically significant increase in liver enzyme activity in rats. Furthermore, compared to the rats in the control group, the administration of PCM resulted in a depletion of GSH contents (Table 2). Furthermore, administering PCM resulted in a noteworthy rise in SOD (Table 2) activities.

Parameter	Group 1	Group 2	Group 3	Group 4	Group 5
Superoxide dismutase (U/mg)	9.22 \pm 0.27	3.7 \pm 0.11	17.18 \pm 0.57	4.86 \pm 0.06	5.35 \pm 0.07

Glutathione Peroxidase (μmoles) 116 \pm 1.60 54.83 \pm 1.32 43.9 \pm 1.62 63.86 \pm 2.24 64.46 \pm 3.54

Table 1: Mean and standard deviation of Superoxide dismutase and Glutathione Peroxidase in Test and Control Groups

Note; Group 1: Control, Group 2: Paracetamol only, Group 3: Paracetamol + 500mg Ascorbic Acid, Group 4: Paracetamol + 1000mg Ascorbic Acid, Group 5: Ascorbic Acid only

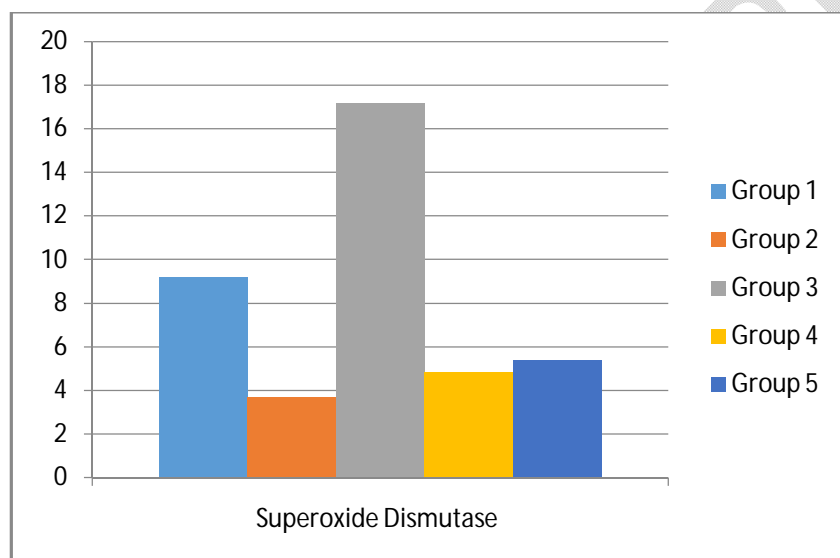


Fig 1: Comparative analysis of Superoxide dismutase in Test and Control Groups

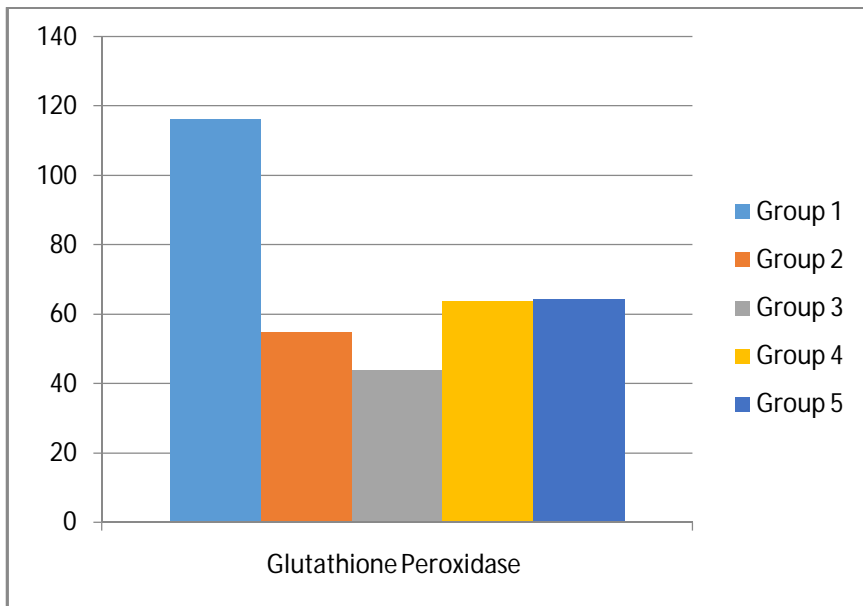


Fig 2: Comparative analysis of Glutathione Peroxidase in Test and Control Groups

HISTOPATHOLOGICAL RESULTS

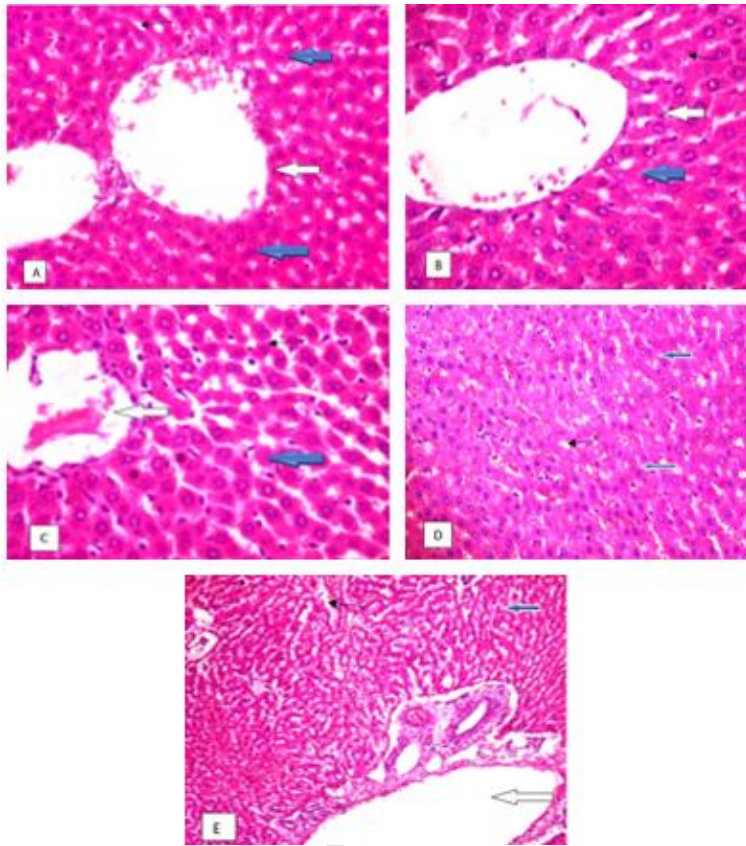


Fig. 3. Histopathological slides of liver (H&E 400X)

Group A Photomicrograph of a liver section stained by Hematoxylin and Eosin showing the central venules (white arrow), the morphology of the hepatocytes appears normal (blue arrow), the sinusoids appear normal and not infiltrated (slender arrow).

Group B Photomicrograph of a liver section stained by Hematoxylin and Eosin showing mildly congested central venules (white arrow), the morphology of the hepatocytes appears normal (blue arrow), the sinusoids appear normal and not infiltrated (slender arrow).

Group C Photomicrograph of a liver section stained by Hematoxylin and Eosin showing normal central venules (white arrow) and vessel with mild perivascular infiltration of inflammatory cells, the morphology of the hepatocytes appears normal (blue arrow), the sinusoids appear normal and not infiltrated (slender arrow)

Group D Photomicrograph of a liver section stained by Hematoxylin and Eosin showing mildly congested central venules, the morphology of the hepatocytes appears normal (blue arrow), the sinusoids appear normal and not infiltrated (slender arrow).

Group E Photomicrograph of a liver section stained by Hematoxylin and Eosin showing mildly congested central venules (white arrow), the morphology of the hepatocytes appears normal (blue arrow), the sinusoids appear dilated with mild hemorrhage (slender arrow)

4.0. Discussion

The results of the study revealed that administering paracetamol orally to rats resulted in a notable increase in the activities of liver enzymes, shedding light on the substance's potential hepatotoxic effects. This elevation in enzyme levels serves as a crucial biomarker for liver damage, indicating the organ's physiological response to the metabolization of the compound. Paracetamol, while widely recognized as a safe analgesic and antipyretic for humans when used at recommended doses, has a well-documented risk of hepatotoxicity, particularly when consumed in excessive amounts or in vulnerable populations^{15, 16}. The marked increase in liver enzyme activity observed in the text rats suggests that even standard dosages of paracetamol may invoke a stress response in the hepatic tissues, leading to cellular injury and subsequent leakage of these enzymes into the bloodstream. Such findings are significant as they not only raise concerns about the safety margins of paracetamol usage in both clinical and over-the-counter settings but also emphasize the importance of further investigating the biochemical pathways involved in paracetamol metabolism and its potential implications for liver health. These results also underscore the necessity for continuous monitoring of liver function biomarkers in patients undergoing treatment with paracetamol, particularly for those with pre-existing liver conditions or those consuming other hepatotoxic agents concurrently.

The study's findings unequivocally demonstrated that, in comparison to the control group, the administration of Paracetamol resulted in a marked reduction in glutathione (GSH) concentrations. Glutathione, a crucial antioxidant present in every cell, plays a vital role in combating oxidative stress and maintaining cellular homeostasis¹⁷. The observed reduction in GSH levels following PCM administration highlights the potential hepatotoxic effects of this common analgesic, which is often underestimated due to its widespread use and availability¹⁸. While PCM is generally considered safe when taken within therapeutic limits, excessive or prolonged exposure can overwhelm the liver's detoxification mechanisms, resulting in a decline in GSH, which is essential for neutralizing reactive oxygen species (ROS) generated during the drug's metabolism¹⁹. This deficiency may increase cells' vulnerability to oxidative damage and impede a number of physiological processes, which could result in liver damage and other harmful health effects. Moreover, the stark contrast between GSH levels in the PCM-treated group and the control group underscores the need for careful monitoring of antioxidant defenses in individuals exposed to PCM, particularly in those with existing liver conditions or those who consume alcohol concurrently. The administration of PCM has been shown to stimulate SOD activity significantly, suggesting a complex interplay between this ubiquitous drug and the

body's endogenous antioxidative responses. This elevation in SOD activity may serve as a compensatory mechanism to counteract oxidative damage, particularly under conditions of increased metabolic stress or injury, as well as after excessive exposure to free radicals²⁰. In recent studies, the introduction of ascorbic acid, known for its potent antioxidant properties, has been shown to counteract these detrimental effects^{8, 21, 22}. By enhancing the liver's antioxidant defense system, ascorbic acid helps to restore glutathione levels and reduces the burden of oxidative damage.

Histopathological examination reveals that the liver tissue from rats treated with paracetamol exhibits a lower degree of necrosis and inflammatory cell infiltration when compared to samples from rats that received ascorbic acid alone. This finding raises the possibility that ascorbic acid may protect the liver by reducing the negative effects of paracetamol. Ascorbic acid has been shown in a study to have an impact on several signaling pathways that are closely related to the processes of inflammation and apoptosis, or programmed cell death.^{23, 24} As a result, the administration of ascorbic acid appears to mitigate the overall impact of paracetamol toxicity on hepatic tissues. This potentially suggests that ascorbic acid could be beneficial in reducing the detrimental effects commonly associated with paracetamol overdose, possibly by reducing oxidative stress and regulating inflammatory responses within the liver. The mechanisms of ascorbic acid might enhance liver cell survival and maintain hepatic function even in the presence of paracetamol-induced damage²¹. Thus, the combination of paracetamol and ascorbic acid highlights a complex interaction that warrants further investigation to fully understand the underlying biological processes at play and to explore potential therapeutic interventions for managing paracetamol toxicity.

4.1 CONCLUSION

In summary, the study highlights the potential benefit of ascorbic acid for protecting liver function and advances our knowledge of its therapeutic potential in the setting of hepatotoxicity. This knowledge may help shape future suggestions for clinical interventions and dietary formulations that improve liver health. Future investigations should consider stratifying results based on factors such as age, sex, and dietary habits to evaluate how these variables may influence therapeutic outcomes.

CONSENT: It is not applicable.

Disclaimer (Artificial intelligence)

Option 1:

Author(s) hereby declare that NO generative AI technologies such as Large Language Models (ChatGPT, COPILOT, etc) and text-to-image generators have been used during writing or editing of manuscripts.

Option 2:

Author(s) hereby declare that generative AI technologies such as Large Language Models, etc have been used during writing or editing of manuscripts. This explanation will include the name, version, model, and source of the generative AI technology and as well as all input prompts provided to the generative AI technology

Details of the AI usage are given below:

- 1.
- 2.
- 3.

References

1. Silva, A., Costa, B., Castro, I., Mourão, J., & Vale, N. New Perspective for Drug–Drug Interaction in Perioperative Period. *Journal of Clinical Medicine*, 2023. 12:14.
2. Arnold, J., Boyle, K., Brent, J., Burkhart, K., Carey, J., Carreiro, S., Chenoweth, J., Chhabra, N., Cole, J., Connors, N., Garlich, F., Greene, S., Hendrickson, R., Hieger, M., Juurlink, D., Kao, L., Katz, K., Kerns, R., King, A., . . . Kopec, K. 2021 ACMT Annual Scientific Meeting Abstracts—Virtual. *Journal of Medical Toxicology*. 2021. 17(2), 93–153. -9.
3. Udi OA, Chris-Ozoko LE, Kingsley IA, Mamerhi ET, Ewere B. Histologic effect of garlic extract on the spleen of adult wistar rat. *J Pharm Biol Sci*. 2017;12:1-4.
4. Larder, C. E., Iskandar, M. M., & Kubow, S. Collagen Hydrolysates: A Source of Bioactive Peptides Derived from Food Sources for the Treatment of Osteoarthritis. *Medicines*. 2023. 10(9), 50.
5. Udi OA, Igbigbi PS, Chris-Ozoko LE, Oyeleke AA. Lead ii acetate induced physio-morphological changes in prefrontal cortex of ocimumgratissimum fed wistar rats. *Asian Journal of Research and Reports in Neurology*. 2018;1(1):1-10.
6. Orororo OC, Efekemo O, Udi OA. Changes in liver histomorphology, hematological parameters and lipid profile of cadmium exposed rats treated with combined leaf extract of verniniaamygdalina and ocimumgratissimum. *Asian Journal of Medicine and Health*. 2022; 20(11):195- 203
7. Larder, C. E., Iskandar, M. M., & Kubow, S. Collagen Hydrolysates: A Source of Bioactive Peptides Derived from Food Sources for the Treatment of Osteoarthritis. *Medicines*. 2023. 10(9), 50.
8. Gao, W., Guo, L., Yang, Y., Wang, Y., Xia, S., Gong, H., Zhang, B. K., & Yan, M. Dissecting the Crosstalk Between Nrf2 and NF- κ B Response Pathways in Drug-Induced Toxicity. *Frontiers in Cell and Developmental Biology*. 2022. 9.
9. Alqarni, M. M., Faloudah, A. Z., Alsulaihebi, A. S., Halawani, H. K., & Khan, A. S. A Case of Hepatotoxicity after Receiving a COVID-19 Vaccine. *Curēus*. 2021

10. Zellos, A., Debray, D., Indolfi, G., Czubkowski, P., Samyn, M., Hadzic, N., Gupte, G., Fischler, B., Smets, F., De Cléty, S. C., Grenda, R., Mozer, Y., Mancell, S., Jahnel, J., Auzinger, G., Worth, A., Lisman, T., Stauffer, C., Baumann, U., . . . Verkade, H. J. Proceedings of ESPGHAN Monothematic Conference 2020. *Journal of Pediatric Gastroenterology and Nutrition*, 2021. 74:3.
11. Oyem JC, Chris-Ozoko LE, Enahwo MT, Otabor FO, Okudayo VA, Udi OA. Antioxidative properties of *Ocimum gratissimum* alters lead acetate induced oxidative damage in lymphoid tissues and hematological parameters of adult wistar rats. *Toxicology Reports*. 2021;8: 215-222.
12. Zhang, J., Bottiglieri, T., & McCullough, P. A. The Central Role of Endothelial Dysfunction in Cardiorenal Syndrome. *Cardiorenal Medicine*, 2026. 7(2), 104–117.
13. Enye LA, Ebeye AO, Udi OA, Ishola AO, Igbigbi PS. *Mimosa pudica* ameliorated dichlorvos induced neuro-oxidation. *Toxicology International*. 2021; 28(3):203- 212.
14. Udi OA, Oyem JC, Ebeye OA, ChrisOzoko LE, Igbigbi PS, Olannye DU. The effects of aqueous extract of *Ocimum gratissimum* on the cerebellum of male wistar rats challenge by lead acetate. *Clinical Nutrition Open Science*. 2022; 44:28-41.
15. Alchin J, Dhar A, Siddiqui K, Christo PJ. Why paracetamol (acetaminophen) is a suitable first choice for treating mild to moderate acute pain in adults with liver, kidney or cardiovascular disease, gastrointestinal disorders, asthma, or who are older. *Current medical research and opinion*. 2022. 38(5):811-25.
16. Odi PA, Udi OA, Chris-Ozoko LE, Oyovwi MO. Mature wistar rats spleen and liver histomorphological changes related to the duration of atrazine exposure. *Asian Journal of Research in Medical and Pharmaceutical Sciences*. 2022.11(4):73- 78
17. Adwas AA, Elsayed A, Azab AE, Quwaydir FA. Oxidative stress and antioxidant mechanisms in human body. *J. Appl. Biotechnol. Bioeng*. 2019. 6(1):43-7.
18. Schweighardt AE, Juba KM. A systematic review of the evidence behind use of reduced doses of acetaminophen in chronic liver disease. *Journal of Pain & Palliative Care Pharmacotherapy*. 2018. 32(4):226-39.
19. Jaeschke H, Ramachandran A. Acetaminophen hepatotoxicity: paradigm for understanding mechanisms of drug-induced liver injury. *Annual Review of Pathology: Mechanisms of Disease*. 2024. 19(1):453-78.
20. Enye LA, Saka OS, Onoriode AU, Ebeye AO, Igbigbi PS. Investigating the effect of *Mimosa Pudica* on dichlorvos induced hippocampal neurodegeneration in mice. *Phytomedicine Plus*. 2023. 3(1): 100393.
21. Matic MM, Paunović MG, Milošević MD, Ognjanović BI, Saičić ZS. Hematoprotective effects and antioxidant properties of β -glucan and vitamin C against acetaminophen-induced toxicity: an experimental study in rats. *Drug and chemical toxicology*. 2021, 4;44(3):302-9.
22. Enye LA, Ebeye, AO, Udi OA, Ishiola, AO, Igbigbi, PS. *Mimosa Pudica* Ameliorate Dichlorvos induced Neuro-Oxidation. *Toxicology International*. 2021. 203-212.
23. Bhol NK, Bhanjadeo MM, Singh AK, Dash UC, Ojha RR, Majhi S, Duttaroy AK, Jena AB. The interplay between cytokines, inflammation, and antioxidants: mechanistic insights and therapeutic potentials of various antioxidants and anti-cytokine compounds. *Biomedicine & Pharmacotherapy*. 2024. 178:117177.

24. Udi, O.A., Ijeomah, T.A., Ogagayere, L.O., Okoro, G.O. Alfavaca Aqueous Leaf Extract Protective and Ameliorative Effects on Lead Induced Hippocampus in Wistar Rats. Asian Journal of Medicine and Health. 2023. 21(11): 8-15.

UNDER PEER REVIEW