

## Case report

### Case series of vesicovaginal fistulae in Nizwa Hospital, trend, outcome and Review of literature

#### Abstract

---

Vesicovaginal fistula (VVF) an iatrogenic complication is a distressful condition. In developed countries, the majority of fistula result from gynecological/urogynecological surgeries, whereas in under developed countries, obstructed labour remains a common cause. Accurate diagnosis and proper preoperative planning are essential for a successful outcome. Although the incidence of vesicovaginal fistula resulting from a hysterectomy is estimated to be less than 1%, we should still be cautious of the possibility of this occurrence, evaluate and treat as necessary when suspicion arises. In addition surgical experience, judgment and appropriate technique will enhance the outcome of fistula repair. We report three cases of vesicovaginal fistula occurring in different scenarios with their management.

Keywords: vesicovaginal fistula, hysterectomy, post-operative, Iatrogenic, Caesarean section

#### Introduction

---

Vesicovaginal fistula (VVF) is an abnormal communication between the urinary bladder and the vagina that results in the continuous involuntary leakage of urine into the vaginal vault. It is a worrisome and socially disturbing condition affecting the quality of life. It occurs most commonly as a result of obstetrical and gynecological injuries. [1] The existence of VVF is believed to have been known to the physicians of ancient Egyptian mummies before 2000 years BC. [1, 2] In developing countries, it is estimated that 80% of cases resulted from neglected obstructed labour [12, 20] with an annual worldwide incidence of up to 500,000 cases, most of them in Africa and southern Asia, whereas it is uncommon in the current Western world. [2,3, 18]. “In UK and USA over 70% follow pelvic surgery” [4]. “The rate of VVF formation varies with the surgical

approach. The highest is with laparoscopic procedures (2.2 in 1000), followed by transabdominal (1 in 1000), and the lowest is with the transvaginal approach (0.2 in 1000)” [5],

“While a pelvic surgeon (gynecologist, urologist, or urogynecologist) is almost always involved in caring for a patient with a vesicovaginal fistula, an entire interprofessional team of specialists is required for a successful repair. This team often includes nurses, obstetricians, pharmacists, radiologists, and anesthesiologists. The repair of VVF includes many routes and techniques, such as vaginal, abdominal, laparoscopic, robotic, and transurethral methods with a success rate reaching 100%. The spontaneous closure of vesicovaginal fistulae after bladder drainage alone for varying periods has been reported by many” [6,19]. “There is currently no gold standard technique for the management of genitourinary fistula. Traditionally fistula repair being done by either transabdominal or transvaginal route with cure rates ranging from 50 % to 100%” [21]. “This trend has changed as more and more minimally invasive approaches like laparoscopic and robotics are on the rise” [22] .

#### Case series

Case 1: 51years, Para 7, postmenopausal, with previous caesarean section underwent total abdominal hysterectomy with bilateral salpingo-ophorectomy, in view of large ovarian cyst. The cyst measured 71x56mm and was palpable abdominally up to 16 weeks gravid uterus size. Post-operative period was uneventful. A month later, she developed continuous dribbling of urine and incontinence suggestive of VVF. Computed tomography (CT) urogram confirmed presence of VVF [Figure 1] which was repaired laparoscopically with successful outcome. This was a simple hysterectomy complicated with formation of vesicovaginal fistula probably due to inadequate surgical skills.

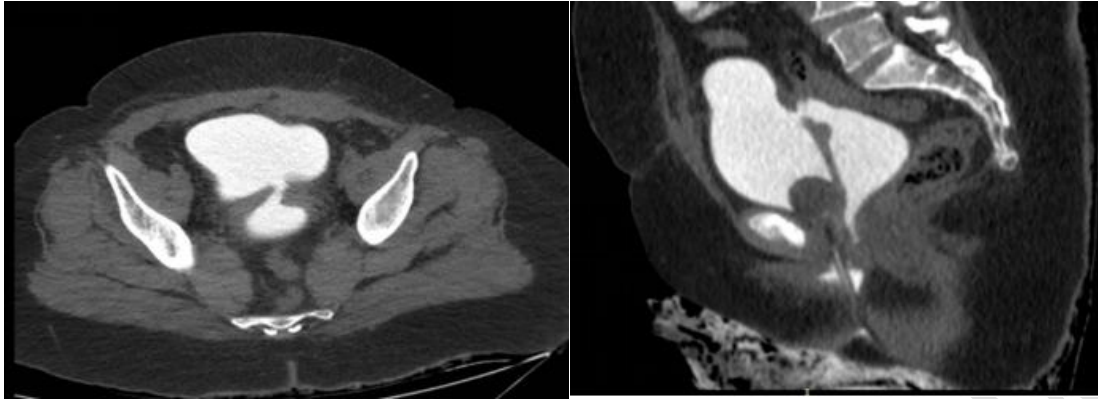


Figure 1: A: Axial CT cystogram image of the pelvis demonstrating the fistulous tract between the posterior urinary bladder and the vaginal vault with contrast both in the urinary bladder and vagina B:Sagittal CT cystogram image of the pelvis demonstrating the fistulous tract between the posterior urinary bladder and the vaginal vault with contrast both in the urinary bladder and vagina.

Case 2: 47 years Para 8 underwent emergency laparotomy for rupture uterus, after vaginal delivery. Subtotal hysterectomy along with repair of bladder tear was done. On postoperative day 7 she presented with complaints of urinary leakage. Initially she was treated conservatively with continuous catheterization for two months and she improved. After five months her symptoms re-occurred, and cystogram confirmed VVF of 3mm in the trigone. Primary VVF repair done with success. After 12 years she presented with persistent urinary symptoms of leakage, and was referred to tertiary urology center for expert management where CT cystogram revealed fistulous tract connecting the left posterior wall of urinary bladder to uterine stump [Figure 2] Subsequently cystoscopy was done, but the procedure was converted to laparotomy for successful repair. Postoperatively she was completely asymptomatic.

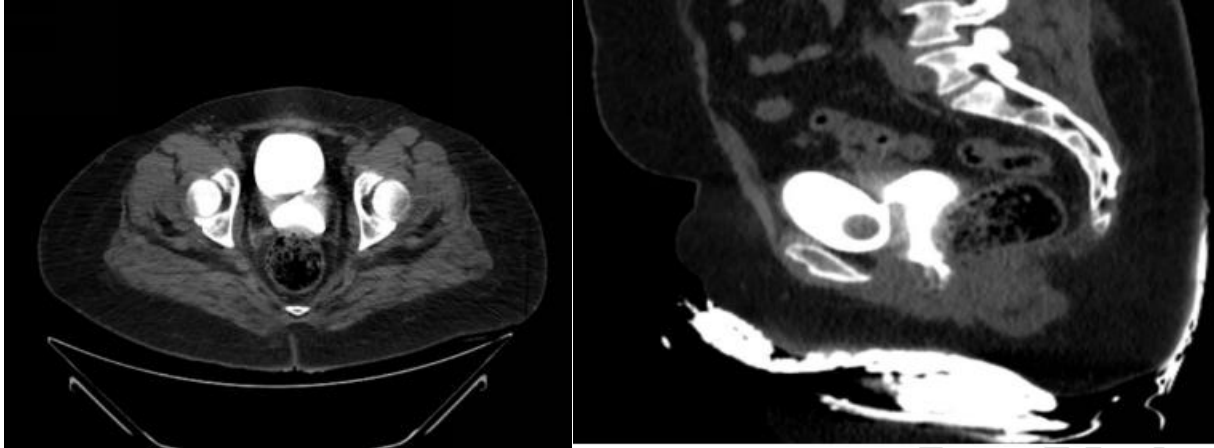


Figure 2: A: Axial CT cystogram image of the pelvis demonstrating the fistulous tract between the posterior urinary bladder and the vaginal vault with contrast both in the urinary bladder and vagina B:Sagittal CT cystogram image of the pelvis demonstrating the fistulous tract between the posterior urinary bladder and the vaginal vault with contrast both in the urinary bladder and vagina.

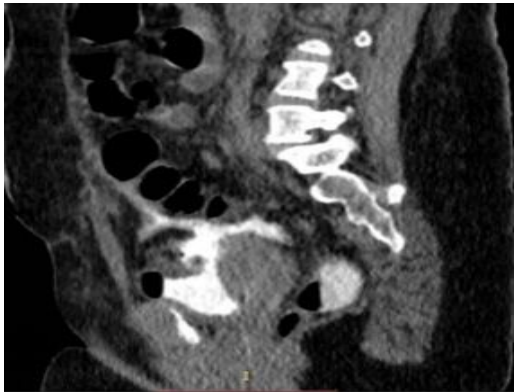


Figure 3: A: Axial CT cystogram image showing the extravasated contrast around the bowel loops indicated intraperitoneal rupture, B:Sagittal CT cystogram image showing intraperitoneal contrast extravasation from a small defect on the urinary bladder dome with tip of foleys catheter passing through the defect.

Case 3: Gravida 8 Para 5 with previous one lower segment caesarean section and cerclage, presented at 22 weeks with non-specific symptoms of pain abdomen, gastritis and vomiting.

Exploratory laparotomy was done as CT abdomen reported hemoperitoneum. Intraoperative findings showed scar pregnancy with placenta accreta which was profusely bleeding. Scar pregnancy was not detected in her antenatal visits. She underwent total abdominal hysterectomy as a life-saving measure. On postoperative day 5 continuous leakage of urine was noted. CT cystogram and Intravenous urogram(IVU) revealed a bladder dome tear, which was repaired. However the surgery was complicated with complex vesico-cervical fistula which was successfully managed with continuous indwelling catheterization for two months. She was completely free of her symptoms thereafter.

## Discussion

---

In most of the case series almost more than half of the fistula were noted in hysterectomy, as presented in our cases. With advances in the medical field and management as in Osman SA [7] which also demonstrates the rise of iatrogenic etiology.

The diagnosis of a vesicovaginal fistula can be made in an outpatient clinical setting. A thorough evaluation of the size, number, and location of the fistula is important before curative surgery is undertaken. Local speculum examination of the fistula and surrounding structures, is extremely important to evaluate for acute inflammation, infection, edema, necrosis, or other bladder or vaginal pathology.[8] Fistulae were usually detected between day 7-12, post obstetric and gynecologic surgery, [4, 18] as correlating in our case series. The imaging we used are CT cystogram and IVU. Dye testing, cystoscopic examination and contrast studies like intravenous pyeloureterogram and bilateral retrograde pyelography to rule out concomitant ureteric fistulas in 10-15% of cases before proceeding with surgical repair. [2,4, 12, 20] A high creatinine level of the vaginal fluid can detect discharge of urine from fistula, after ruling out other cause of incontinence [9]

A successful repair of VVF requires an accurate diagnosis and timely surgical intervention using basic surgical principles with or without the use of inter-positional flaps. The method of repair depends on the type and location of the fistula, and the surgeon's training and expertise. [11,14] For small and non-malignant vesicovaginal fistulas, which were detected early, conservative management with transurethral foleys catheter for 2-8weeks, combined with anticholinergic

medication would suffice for spontaneous closure of the defect. Surgical correction of the defect should be postponed up to 2 to 3 months for optimal tissue health. However, if there is no evidence of inflammation, and the tissue appears healthy, the surgery need not be postponed.[7,11] In Panwar et al.[14] it was quoted that surgical expertise is necessary for good outcome, and the same is noted in the management of our first case.

Complex vesicovaginal fistulas (related to pelvic irradiation) or recurrent fistulas may require the interposition of highly-vascularized tissue and dealt with a gap of at least 3 months for a chance at successful repair [11,14] likewise in our second case scenario, it was a complex fistula did not heal spontaneously, Although she required multiple surgery of no benefit, eventually she had to be referred to tertiary urology center for expertise and was successfully cured. She did not require flap.

It is well known that VVF is one of the complication of placenta percreta, [10] those which had percreta required multiple surgeries, as a single procedure may not be sufficient, [4,11] on contrary in our third case, primary repair had failed but in tertiary center, fistula healed spontaneously after prolonged catheterization.

Review of literature showed that “once the conservative trial fails, surgical correction of the fistula becomes necessary. The best chance of a successful vesicovaginal repair is at the first surgical attempt and a higher success rates are by vaginal route” [14].

“Laparoscopic extravesical VVF repair is a safe, effective, minimally invasive technique with excellent cure rates similar to those of the conventional transvesical approach in experienced surgeon’s hand, this was seen over a period of 20 years” [13]

If a simple vesicovaginal fistula is diagnosed later in pathogenesis, electrocoagulation of the mucosal layer could help in healing of the fistula along with the transurethral catheter placement for 2 to 4 weeks. [15] Fulguration performed either cystoscopically or vaginally can also be of benefit. Fibrin glue has also been described with varying results,[16] However surgical intervention appears more effective as per chinthkanan et al.[19]

In another literature showing robotic repair of supratrigonal VVF with sigmoid epiploica interposition is efficient and well tolerated. Although the outcome has been successful but there is limited perioperative data associated with this technique, and further research is needed to elucidate the potential benefits of epiploica interposition compared to interposition of other tissues. [17]

## Conclusion

Genitourinary fistula is a frustrating entity with potentially devastating consequence. Its management poses a tricky challenge to the surgeon. Accurate and timely diagnosis, adhering on basic surgical principle, repair by an experienced surgeon with comprehensive approach by psychoanalyst and multidisciplinary team will provide the optimum chance of cure. The rise in the injuries occurring iatrogenically, which are resulting in complex fistulas, has demanded the implementation of advanced treatment strategies.

## Disclaimer (Artificial intelligence)

Author(s) hereby declare that NO generative AI technologies such as Large Language Models (ChatGPT, COPILOT, etc.) and text-to-image generators have been used during the writing or editing of this manuscript.

Competing Interests: Authors have declared that no competing interests exist

Ethical approval: has been taken according to the standards

## References:

---

1. In: Drew, L.B., Ruder, B., Schwartz, D.A. (eds). Archeological Basis for Obstetrical Fistula: A Condition That Is as Ancient as Human Themselves. A Multidisciplinary Approach to Obstetric Fistula in Africa. Global Maternal and Child Health. Springer, Cham. Schwartz, D.A. (2022). [https://doi.org/10.1007/978-3-031-06314-5\\_3](https://doi.org/10.1007/978-3-031-06314-5_3)
2. P.Hilton. Vesico-vaginal fistulas in developing countries. *International Journal of Gynecology & Obstetrics*. Volume 82, Issue 3, September 2003, Pages 285-29 .
3. Shrestha DB, Budhathoki P, Karki P, et al. Vesico-vaginal fistula in females in 2010–2020: a systemic review and meta-analysis. *Reprod Sci*. 2022;29(12):3346–64.

4. Stamatakos M, Sargedi C, Stasinou T, Kontzoglou K. Vesicovaginal fistula: diagnosis and management. *Indian J Surg.* 2014 Apr;76(2):131-6 .
5. Medlen H, Barbier H. Vesicovaginal Fistula. 2023 Feb 6. In: StatPearls [Internet]. Treasure Island (FL): StatPearls Publishing; 2024 Jan-. PMID: 33232059.
6. Bazi T. Spontaneous closure of vesicovaginal fistulas after bladder drainage alone: review of the evidence. *Int Urogynecol J Pelvic Floor Dysfunct.* 2007 Mar;18(3):329-33.
7. Osman SA, Al-Badr AH, Malabarey OT, Dawood AM, AlMosaieed BN, Rizk DEE. Causes and management of urogenital fistulas. A retrospective cohort study from a tertiary referral center in Saudi Arabia. *Saudi Med J.* 2018 Apr;39(4):373-378.
8. Mubeen RM, Naheed F, Anwar K. Management of vesicovaginal fistulae in urological context. *J Coll Physicians Surg Pak.* 2007 Jan;17(1):28-31. [PubMed]
9. Srinivasan R, Cortes G, Richardson I, Guelfguat M. Salpingovesical fistula mimicking an enterovaginal fistula. *Radiol Case Rep.* 2020 Sep;15(9):1473-1476. [PMC free article] [PubMed]
10. Matsuzaki S, Matsuzaki S, Ueda Y, Egawa-Takata T, Mimura K, Kanagawa T, Morii E, Kimura T. Placenta percreta with a vaginal fistula after successful management by uterine transverse fundal incision and subsequent cesarean hysterectomy. *Obstet Gynecol Sci.* 2014 Sep;57(5):397-400.
11. Muhammad A Malik, Muhammad Sohail, Muhammad TB Malik, Nauman Khalid and Adeen Akram. Changing trends in the etiology and management of vesicovaginal fistula. *International Journal of Urology* (2018)(25,25-29 )
12. Priyadarshi V, Singh JP, Bera MK, Kundu AK, Pal DK. Genitourinary Fistula: An Indian Perspective. *J Obstet Gynaecol India.* 2016 Jun;66(3):180-4..
13. Miklos JR, Moore RD, Chinthakanan O. Laparoscopic and robotic-assisted vesicovaginal fistula repair: A systematic review of the literature. *J Minim Invasive Gynecol.* 2015;22:727-36
14. Panwar P, Bansal D, Lekha Raveendran R, Kumar A. Primary Bladder Neck Obstruction in a Young Woman: A Novel Technique of Bladder Neck Incision Using Holmium Laser. *J Endourol Case Rep.* 2020;6(3):153-155. [PMC free article] [PubMed]
15. Stovsky MD, Ignatoff JM, Blum MD, Nanninga JB, O'Connor VJ, Kursh ED. Use of electrocoagulation in the treatment of vesicovaginal fistulas. *J Urol.* 1994 Nov;152(5 Pt 1):1443-4. [PubMed]
16. Kanaoka Y, Hirai K, Ishiko O, Ogita S. Vesicovaginal fistula treated with fibrin glue. *Int J Gynaecol Obstet.* 2001 May;73(2):147-9. [PubMed]
17. Sanderson DJ, Rutkowski J, Attuwaybi B, Eddib A. Robotic repair of supratrigonal vesicovaginal fistula with sigmoid epiploica interposition. *JSLs.* 2018;22:pii: e2018.00055.)

18 Farzaneh Sharifaghdas<sup>1</sup> Maryam Emami<sup>2</sup> et al .Genitourinary Fistula: 5 Years' Experience of Five Referral Centers in Iran, March 2024 © The International Urogynecological Association 2024

19.Chinthakanan O, Sirisreetreerux P, Saraluck A. Vesicovaginal fistulas: prevalence, impact, and management challenges. *Medicina (Kaunas)*. 2023;59(11):1947.

20. Nawaz H, Khan M, Tareen FM, et al. Retrospective study of 213 cases of female urogenital fistulae at the department of urology & transplantation civil hospital Quetta, Pakistan. *J Pak Med Assoc*. 2010;60(1):28–32. [[PubMed](#)] [[Google Scholar](#)]

21. Alio AP, Merrell L, Roxburgh K, et al. The psychosocial impact of vesico-vaginal fistula in Niger. *Arch Gynecol Obstet* 2011; 284: 371–378.

22.Singh Vikram<sup>1</sup> , Yadav Om Kumar<sup>1</sup> , Sandhu Arjun Singh<sup>2</sup>, et al Genitourinary Fistula: epidemiology, changing trends in etiology and management: A tertiary care institute's perspective, *Urologia Journal* 2024, Vol. 91(2) 243–248

UNDER PEER REVIEW