

## Original Research Article

# Ameliorative effect of *Curcuma longa* ethanolic extract on the histology, hepatic glycogen content and some biochemical parameters of the liver in streptozotocin-induced hyperglycemic rats.

### ABSTRACT

**Introduction:** Diabetes mellitus is a life threatening disease that requires immediate medical treatment. Numerous medicinal plants have been known for their anti-diabetic effects and *Curcuma longa* (turmeric) is one of them. Its extracts have been known for their uses in the treatment or management of diseases like diarrhoea, peptic ulcers, psoriasis, arthritis and diabetes. This is possible due to the pharmacological properties of its health-promoting constituents.

**Aims:** In this study, the ameliorative potential of ethanolic extract of *Curcuma longa* was investigated on the liver of hyperglycemic adult wistar rats. The objectives were to determine its effects on liver histology, hepatic glycogen content and some liver biochemical parameters.

**Methods:** Forty (40) rats weighing between 120-180g were used for the research. Sixteen (16) rats were used for its acute toxicity study, while twenty-four (24) rats were grouped into four. The groups were labelled A to D and contained six rats each. Group A (normal control) rats were given food pellets and distilled water only. Group B (diabetic control) rats were given 65mg/kg BW of streptozotocin. Group C served as the metformin treated group animals were given 65mg/kg BW of streptozotocin + 250mg/kg BW of metformin, while Group D rats were given 65mg/kg BW of streptozotocin + 500mg/kg BW of *Curcuma longa* extract. The administration of streptozotocin and metformin were through the intraperitoneal route, while that of *Curcuma longa* extract was through the oral route with the aid of an oral gavage. The administration lasted for twenty-eight (28) days, after which the rats were made to fast overnight with access to only water. The rats were then weighed and then anaesthetized. Whole blood was collected through cardiac puncture and blood collected for biochemical analysis. Liver tissue was obtained for histological and glycogen content analyses.

**Results:** The results showed severe destruction of hepatocytes with widely spread cytoplasmic vacuolation, loss of hepatic lobules and hepatic inflammation in the diabetic group, whereas it showed prominent nuclei, hepatocytes and distinct sinusoidal spaces in the normal control group. The metformin group showed an intact architecture of the liver tissue, although binucleated cytoplasmic vacuolations of the hepatocytes were present, indicating regeneration in the liver. The *Curcuma longa* extract group showed a preserved cytoarchitecture of the liver with prominent and hypochromic hepatocytes and well out-lined sinusoids. There was a significant decrease ( $p < 0.05$ ) in the fasting blood glucose level and liver enzyme activities in the metformin and extract treated groups compared to the diabetic group ( $p < 0.05$ ). There was also improvement in glycogen content of the metformin and extract treated groups in comparison with the diabetic group ( $p < 0.05$ ). This shows that *Curcuma longa* possesses hepato-protective properties and a strong anti-diabetic potential, thereby making it useful in the management of diabetes mellitus and its complications.

**Conclusion:** The extract of *Curcuma longa* can be considered as an alternative drug in the management of diabetes mellitus.

**Keywords:** *Curcuma longa*, diabetes mellitus, metformin, liver, biochemical parameters.

## INTRODUCTION

The liver is a vital organ in vertebrates (1) that plays a role in controlling biochemical and physiological activities including the regulation of glucose metabolism and in insulin clearance (2). It is fundamental in the regulation of plasma glucose levels being an important player during both fasting and postprandial conditions mainly through hepatic glucose production and glycogen storage and so plays a role in the development of metabolic diseases including diabetes mellitus "DM" (3). Diabetes mellitus is a metabolic disease that involves abnormally elevated blood glucose levels resulting from the body's inability to produce insulin or resistance to insulin (4,5). DM has been shown to have many complications including cardiovascular disease (3), damage to nerves and eyes (6), encephalopathy (7), cardiomyopathy (8) and hepatopathy (9). These traits are hypothesized to damage cell membrane which is as a result of elevated reactive oxygen species (ROS) that are generated during hyperglycemia (10). The production of oxygen species is needed in certain amounts for normal metabolic processes, but when it becomes too high, it leads to oxidative stress (11). According to research, DM is associated with a number of liver abnormalities such as abnormal glycogen deposition, non-alcoholic fatty liver diseases "NAFLD", fibrosis, cirrhosis, hepatocellular carcinomas,

abnormal elevated hepatic enzymes, acute liver disease and viral hepatitis (12,13). As a collection of insulin-sensitive tissues, the liver is among the primary organs that are susceptible to the effects of hyperglycemia-induced oxidative stress (14,15,16). Pharmaceutically, metformin is considered to be the first choice agent for treatment of diabetes (17). It however, has undesirable side effects such as heart burn, nausea, weight loss, headache, anemia, hypoglycemia (18). On account of this side effects, there is advocacy for the use of medicinal plants (19) because they have been found to have little or no side effects (20). Numerous studies have demonstrated the therapeutic effects of medicinal plants, especially in the amelioration of tissue toxic effects caused by exposure to toxic substances (21,22,23,24,25,26,27,28,29,30,31,32,33) and one of such plants is *Curcuma longa* (turmeric). *Curcuma longa* is a member of the ginger family Zingiberaceae (34) and has been used for thousands of years as a remedy in the traditional Indian and folk medicine for the cure of a large variety of illnesses such as inflammation, infectious diseases and gastric, hepatic and blood disorders (35). It is called Ata ile pupa, Gangamau and Ntu ntu in Nigeria. Turmeric is a spice and a polyphenol substance (36) that is obtained from the root of *Curcuma longa* and it possesses anti-inflammatory, anti-platelet aggregation, antioxidant, anti-angiogenic, antimicrobial properties (37,38), antibacterial, antimalarial, antiviral, anti-aging, anticancer, anti-Alzheimer's disease and antifungal properties (39,40).

## **MATERIALS AND METHODS**

### **Plant acquisition, identification and preparation of extract:**

The rhizomes of *Curcuma longa* (turmeric) were purchased at Watt market, Calabar, Cross River state, Nigeria. It was then identified and authenticated at the department of Botany, Faculty of Science, University of Calabar and given a voucher number Bot/Herb/UCC/201. The fresh turmeric rhizomes were cleaned, chopped into tiny pieces and air-dried for 7days, after which they were grounded into powdered form. A measured amount of 950g of the powdered leaves was extracted using 2liters of 95% ethanol for 24 hours. The extract was first double-filtered with Chess cloth, then with filtered paper (Whatman No.1 filter paper). The filtrate (extract) was concentrated under reduced pressure at 45°C in a rotary evaporator to 10% volume. It was then dried using a vacuum water bath, yielding 58.9g (6.2%) of crude extract. The crude extract (paste) obtained was stored in a refrigerator until it when required for the experiment. The extraction of these rhizomes was carried out in the main laboratory of Biochemistry department, University of Calabar.

**Experimental design:**

Forty (40) rats weighing between 120-180g were obtained from the College of Medical sciences animal house, University of Calabar. The rats were sheltered in optimal environmental conditions of humidity, temperature and daylight/dark cycle. They were fed with were given food pellets and distilled water only. They were kept in this environment for a period of three weeks (to allow for acclimatization) before commencement of the experiment. Sixteen (16) rats were used for acute toxicity test of the leaf extract, while 24 were divided into 4 groups and placed in properly ventilated plastic cages labelled A to D, with each cage containing six rats. Group A was designated as the normal control group and were given food pellets and distilled water only. Group B was the diabetic control group and were given 65mg/kg body weight "BW" of streptozotocin "STZ". Group C served as the metformin treated group and were administered with 65mg/kg BW of STZ + 250mg/kg BW of metformin, while Group D rats were given 65mg/kg BW of STZ + 500mg/kg BW of *Curcuma longa* extract. The administration of STZ and metformin were through the intraperitoneal route, while that of *Curcuma longa* extract was through the oral route with the aid of an oral gavage. The administration lasted for twenty-eight (28) days. Pre and post-induction of STZ fasting blood sugar, as well as weight of the animals were assessed and these procedures were done daily throughout the course of the administration. The rats were then finally weighed and then anaesthetized. Whole blood was collected through cardiac puncture and the serum used for biochemical analysis involving liver enzymes (Alanine aminotransferase "ALT", aspartate aminotransferase "AST" and alkaline phosphatase "ALP"). Liver tissue was obtained and processed for histological staining and glycogen content analyses.

**Acute toxicity test:**

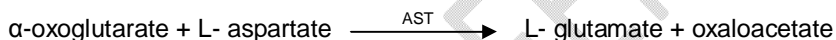
Sixteen rats were employed for the determination of the lethal dose "LD"<sub>50</sub> of *Curcuma longa* extract using Lorke's method (41). The rats were separated into four groups (3 rats each) for the first phase and received 500mg, 1000mg, 1500mg and 2000mg/kg BW respectively. They were observed for twenty-four hours. The second phase involved two groups of 2 rats each which were given 4000mg and 6,000mg/BW of the extract respectively. There was no death recorded and this agrees with a study by Niranjana and Prakash which illustrated that its extract is non-lethal in any concentration (42). The LD<sub>50</sub> was therefore >5,000mg/kg so we decided to make use of 5,000mg/kg as the LD<sub>50</sub>. The

dose of the extract was calculated as 10% of 5,000mg/kg (equal to 500mg/kg) body weight of the extract. The extract was dissolved in distilled water and given via oral intubation using a gavage. The extract was then administered to the rats based on their weights.

**Induction and confirmation of hyperglycemia:** Diabetes was induced in overnight fasted experimental rats by a single dose of STZ administered intraperitoneally. STZ was reconstituted in 0.5M Sodium citrate and administered at a dose of 65mg/kg.bw (43). Diabetes was confirmed 48 hours after the STZ administration using Accu-check glucometer with blood samples obtained from tails of the Wistar rats. The blood glucose levels (mg/dl) were checked before and after induction. It was also checked every three days during the administration of the metformin and plant extract to ascertain their hyperglycemic state. The rats with fasting blood glucose levels above 250mg/dl were deemed diabetic (44).

**Biochemical study for liver AST, ALT and ALP activities:**


**Procedure for estimation of aspartate transaminase (AST) activity using Agappe kit based on Reitman and Frankel (45):**



Oxaloacetate concentration is in proportion to aspartate consumed by the enzyme and hence its activity is measured by monitoring the concentration of oxaloacetate hydrazone formed with 2, 4-dinitrophenylhydrazine.

100  $\mu$ l serum was added to 1 ml of working reagent. The tubes were incubated for 1minute at 37°C after mixing. The change in absorbance per 20 second during 1 `minute was recorded against blank at 340 nm. Distilled water was used as blank.

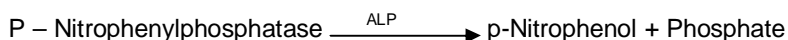**Procedure for estimation of alanine transaminase (ALT) activity using Agappe kit based on Reitman and Frankel (45):**



Pyruvate concentration depends on the amount of L-alanine transaminase and hence the activity of ALT is measured by monitoring the concentration of pyruvate hydrazone formed with 2, 4-dinitrophenylhydrazine at 546nM.

100  $\mu$ l of serum was added to 1 ml working reagent. After mixing tubes were incubated for 1 minute at 37°C. The change in absorbance per minute during 3 minute was recorded against blank at 340 nm.

**Procedure for estimation of alkaline phosphatase (ALP) activity using Agappe kit based on Schlebusch et al, (46):**



Alkaline phosphatase in serum, catalyzes the hydrolysis of P-Nitrophenyl phosphate to p-Nitrophenol and phosphate. The rate of formation of P. Nitrophenol is measured as an increase in the absorbance which is proportional to the ALP activity in the sample.

20 µl of serum was added to 1ml of working reagent. The tubes were incubated for 1 minute at 37°C. The change in absorbance per minute during 3 minute was recorded against blank at 405 nm.

### Determination of Hepatic Glycogen Content:

The measurement of glycogen levels was done using Abcam glycogen colorimetric assay kit. The procedure is as follows: The hydrolysis enzyme mixture, development enzyme mixture and glycogen standard were solubilized, while the OxiRed probe and buffers were thawed. The glycogen standard dilution for the desired detection method was 0.4 – 2 µg/well. The samples were prepared in optimal dilutions to fit standard curve readings. Plates were set up in duplicate for the standard (50 µL), samples (50 µL) and background sample control wells (50 µL). 2 µL of hydrolysis enzyme mixture was added to standard and sample wells only. The plate was then incubated at room temperature for 30 minutes. A master mixture for glycogen Reaction mixture was then prepared with a development buffer (46 µL), a development enzyme mixture (2 µL) and an OxiRed probe (2 µL). 50 µL of glycogen reaction mixture was then added to all the wells. The plate was incubated at room temperature for 30 minutes and protected from light. The optical density of the plate was measured at 570 nm.

The concentration of glycogen (µmol/µL) in the test samples was calculated as:

$$\text{Glycogen concentration} = \frac{\text{Ts}}{\text{Sv}} \times \text{D}$$

Where: **Ts** = amount of glycogen in the sample well calculated from standard curve (µmol) and **Sv** = sample volume added in the sample wells (µL). **D** = sample dilution factor.

### Histological study with hematoxylin and eosin stain “H&E”:

The paraffin slides containing liver tissue underwent a dewaxing process involving two rounds of exposure to xylene for a duration of 5 minutes each. Subsequently, rehydration was performed by sequentially immersing the slides in decreasing concentrations of alcohol (100%, 95%, and 70%) and rinsing them under tap water. Following rehydration, the sections were subjected to a 15-minute

staining procedure using hematoxylin, followed by a 5-minute rinse under tap water. To enhance visualization, the sections were then differentiated in acid alcohol for 1 minute and subsequently counter-stained with Eosin for another 1 minute. After a rinse in tap water, the sections underwent dehydration and clearing using xylene. Following this, the sections were allowed to air dry, and a few drops of dibutylphthalate polystyrene xylene "DPX" were applied to the slide surface before placing a coverslip on top. The resulting tissue units were then taken using a digital camera connected to a light microscope for further examination (47).

**Statistical analysis:**Data obtained from the experiment was analyzed statistically using one-way ANOVA and Duncan post hoc test using statistical package for social sciences (SPSS) software version 26.0 for Windows. The results were presented as mean±standard error of mean and considered statistically significant at  $p<0.05$ .

## RESULTS AND DISCUSSION

### Results:

#### Assessment of body weight:

The results of changes in the body weight of experimental animals after 28 days' period were assessed. The initial and final weights across the 28-day period are presented on figure 1. Observed from these results was a significant ( $p<0.05$ ) reduction in body weight of the experimental rats induced with diabetes ( $-37.00\pm 5.75\text{g}$ ) after subtracting the final weight from the initial weight of the rats. The normal control group A had a significant increase of  $+20.00\pm 1.14\text{g}$ . On treatment with the test drug (metformin), a weight increase of  $+0.80\pm 1.80\text{g}$  was observed, while that of the *Curcuma longa* extract was a decrease of  $-1.20\pm 2.08\text{g}$  ( $p<0.05$ ).

#### Assessment of fasting blood glucose:

The changes in fasting blood glucose "FBG" were determined in this study over the course of the 28-day experimental period. The initial and final FBG levels are presented in figure 2. At day zero, the blood glucose levels in all experimental groups were considered normal ranging from about 70 mg/dl to 107 mg/dl. From the results, it can be observed that elevated blood glucose concentration was seen in all diabetic groups following the administration of 65mg/kg body weight of STZ. The elevated FBG level (Figure 2) of the diabetic control group only exhibited an increase ( $p<0.05$ ) of  $24.40\pm 26.61\text{mg/dl}$  (gotten by subtracting the final FBG level from the initial FBG level after induction

with diabetes mellitus), while that of the metformin and extract treated groups had significantly decreased FBG levels of  $-227.60 \pm 24.32 \text{ mg/dl}$  and  $-236.60 \pm 25.14 \text{ mg/dl}$  respectively ( $p < 0.05$ ).

**Aspartate transaminase, alanine transaminase and alkaline phosphatase enzyme activities:**

The results of the effects of STZ, as well as the administration of metformin and the plant extract on serum liver enzymes (AST, ALT and ALP) are presented in figures 3 to 5. A significant increase in activity of the three enzymes was observed in group B after treatment with STZ when compared to the normal control group A. Upon treatment with metformin and 500mg/kg BW of *Curcuma longa* extract, the activities of the three enzymes were significantly reduced when compared to the diabetic control group B. It was also observed that AST and ALT enzyme activities in the plant extract group were significantly higher than that of group A, while that of ALP was not significantly different ( $p < 0.05$ ).

**Liver glycogen content:**

The results of the liver glycogen content analysis across the various groups showed that the glycogen concentration in group B was significantly higher than that of group A rats, but significantly lower than that of group C rats. The glycogen content in the extract treated group was found to be not significantly different from that of groups A, B or C ( $p < 0.05$ ).

**Histomorphological examination of the liver:**

The histological assessment of liver tissue sections across the experimental groups revealed a normal liver histology in group A rats (plate 1), detailing a central vein, well out-lined sinusoids and hepatocytes with abundant cytoplasm and prominent nuclei. In group B rats treated with 65mg/kg body weight of STZ (plate 2), severe destruction of hepatocytes with widespread vacuolation, loss of hepatic lobules and hepatic inflammation were observed. There was also patchy centrilobular necrosis. These features are indicative of hepatotoxicity. For group C rats (plate 3) treated with metformin, an intact liver structure was observed, although binucleated cytoplasmic vacuolations of the hepatocytes were present and indicative of liver tissue regeneration. Group D rats (table 1) treated with 500mg/kg BW of *Curcuma longa* extract displayed a regenerated liver tissue with features similar to that of group A rats. These include well outlined sinusoids, central vein and hepatocytes having abundant cytoplasm, as well as prominent nuclei.

**Discussion:**

Diabetes mellitus is a major source of worry to public health, as it is also a leading factor of mortality globally (48). Studies have shown that diabetes mellitus is associated with a number of liver

abnormalities such as fibrosis, abnormal glycogen deposition, cirrhosis, acute liver disease and abnormally elevated hepatic enzymes (48,49,50,51,12). In general, the liver plays many vital roles that help in the maintenance and performance of the body such as metabolism, storage, biosynthesis and detoxification (3). It is important in the modulation of plasma glucose levels through hepatic glucose production and glycogen storage, thereby playing a role in the development of metabolic diseases like diabetes mellitus (3). Streptozotocin is an antibiotic that is widely used experimentally to produce a model of type 1 and type 2 diabetes mellitus in experimental rats by causing pancreatic islets  $\beta$ -cells destruction (52).

The elevated serum FBS level observed in groups B, C and D rats that were induced with diabetes mellitus (by treatment with 65mg/kg BW of STZ) is due to the ability of STZ to induce hyperglycemia at a doses between 35mg/kg and 65mg/kg BW STZ administered intravenously or intraperitoneally (53). This agrees with many studies that have also reported successful induction of hyperglycemia with the STZ diabetic dose range in rats (52,54,53,44,50,49,55,56,57). Metformin qualifies as an oral anti-diabetic drug for the treatment of type 2 diabetes (20). It reduces serum glucose level by several mechanisms, notably through the suppression of hepatic glucose production (58). It activates the enzyme adenosine monophosphate kinase, resulting in the inhibition of key enzymes involved in gluconeogenesis and glycogen synthesis in the liver (20). In this study, administration of metformin was able to lower the serum FBG level in group C rats. This is in agreement with studies by Za'abiet *al* (59) and Horakova *et al* (58) who illustrated this effect in diabetic rats. *Curcuma longa* extract was also able to lower serum FBG level in group D rats and this could be due to its wealth of antioxidants which possess many pharmacological properties, including anti-diabetic potential (60). This is in line with studies by Chiu *et al* (61), Essa *et al* (56) Hussain (62) and Hodaeiet *al* (63) who illustrated the ameliorative effects of *Curcuma longa* on serum blood glucose. The possible mechanisms of the effect of *Curcuma longa* on blood glucose in diabetic models can be attenuated to the reduction of the absorption rate of carbohydrates in the gastrointestinal tract due to inhibition of the Na<sup>+</sup> - glucose co-transporter (64) and the fact that *Curcuma longa* is involved in activating of enzymes in the liver which are associated with glycolysis, gluconeogenic and lipid metabolic process (65).

The increase in AST, ALT and ALP enzyme activity observed in the diabetic group B (treated with 65mg/kg BW of STZ) when compared to group A can be attributed to the ability of STZ to elevate liver enzyme activity (50). This result corroborates with several studies (48), (51) that indicate that diabetes

mellitus is associated with elevated hepatic enzyme activities, that maybe a result of the liver cell destruction or changes in the membrane permeability indicating severe hepatocellular damage as observed by Schmatz *et al.* (66). The significant decrease in serum FBG seen in the metformin-treated group after hyperglycemia induction may be due to the anti-diabetic potential of metformin (58). A significant decrease was also seen in the *Curcuma longa* extract treated group and this may be due to the pharmacological activity of its bioactive constituents. This finding is in line with studies by Kahkasan *et al* (67), Rahmani *et al* (68), Guitierreset *al* (69) and Hussein *et al* (70) on the effect of *Curcuma longa* extract on liver enzyme activity. The reduction of AST, ALT and ALP activities by the extract is an indication of repair of tissue damage induced by diabetic complications and this is in agreement with Shahidi and wanasundara (71) who revealed that serum transaminase activities returned to normal with the healing of tissue parenchyma and regeneration of hepatocytes. Thus, administration of ethanolic extract of *Curcuma longa* showed protective activity against the toxic metabolites of diabetes mellitus as is also supported by histological the findings of this study.

The glycogen content concentration revealed a significant increase in the diabetic control group, compared to the normal control group. After 28 days post administration, a decrease in glycogen concentration was observed in the groups treated with metformin and the plant extract, but the decrease was only significant in the metformin treated group compared to the diabetic control group. The result suggests that metformin had a more potent effect in enhancing this parameter ( $P < 0.05$ ). The decrease in glycogen content by metformin may be due to its anti-diabetic potential (50), while the decrease by *Curcuma longa* extract could be linked to glucokinase activity and repression of glycogen content through enzyme Glucose 6-phosphate dehydrogenase and phosphoenolpyruvate carboxykinase as revealed by Seo *et al* (64). It may also be due to the fact that *Curcumia longa* increases glycogenesis and inhibits glycolysis in the liver, since deficiency of insulin in diabetic state inactivates the glycogen synthetase enzyme and leads to increased glycogen content in diabetic patients (72). This observation about *Curcuma longa* extract on hepatic glycogen content was also noticed in a study by Xie *et al* (73).

In this study, the diabetic control group displayed a distorted liver microstructure exhibiting necrosis, vascular obstruction and cellular degeneration when compared to the normal control group A. Liver tissue structural anomaly was due to metformin administration was also reported in a study by Hussein *et al* (70) congested mild inflammation, sinusoidal congestion with fatty degeneration in the

form of fat lake in the liver. The reaction is said to be provoked by the increased production of highly reactive intermediates of STZ which are normally detoxified by endogenous growth stimulating hormone (GSH) but when present in excess, can deplete GSH stores and affect liver tissue. The liver tissue of the rats in group C (treated with metformin) showed typical healthy features as those in the normal control group but with other minor degenerative changes. It has been postulated by Ahmad *et al* (74) and Jiang *et al* (75) that free radical generation resulted by glucose oxidation and protein glycation play a significant role in pathogenesis of diabetes mellitus. It was proposed that the most important cause of liver damage in diabetic patients is hyperglycemia-induced oxidative stress and subsequent disturbance in carbohydrate, protein or lipid metabolisms (76). The Liver tissue section of diabetic rats treated with the plant extract (500mg/kg BW) exhibited features of tissue restoration with no visible pathological lesion. The vacuolization observed in the diabetic group and metformin treated groups were not seen in the liver tissue of the plant extract treated group. Thus, treatment with 500 mg/kg BW of *Curcuma longa* extract attenuated this effect. The liver tissue amelioration observed in group D rats may be due to the action of the phenolic (antioxidant) compounds present in *Curcuma longa* extract (77). Phenolic compounds present in plants have been known to possess tissue-protective effects as seen in studies by Eruet *al.*(25), Eru *et al.*(26), Boussadia *et al.*(24), Anani *et al.*(21), Anani *et al* (22), Bassey *et al* (30), Oku *et al* (56), Eruet *al.*(27) and Eruet *al* (28). As suggested by Sadhwani (78) and Pharm-Huy *et al.*(79), phenols possess the ability to counteract excessive free radicals, thereby safeguarding cells and tissues against their toxic effects. This finding relates to the research done by Suresh and Srinivasan (80), who reported that *Curcuma longa* administration prevented hepatic lesions in STZ diabetic rats and protects against oxidative stress in hepatic cell lines. Xia *et al* (81) also reported on improved liver histology in rats due to the antioxidant activity of *Curcuma longa* administration after hyperglycemia induction.

## **CONCLUSION**

The present study illustrated that administered dosage of STZ led to hyperglycemia in the rats, leading to distortion in liver cytoarchitecture, weight loss, increased liver enzyme activity and increased hepatic glycogen content. The study also revealed ameliorative and anti-diabetic activities of *Curcuma longa* ethanolic extract in the various parameters. *Curcuma longa* therefore possesses hepatoprotective properties and a strong anti-diabetic potential, thereby making it useful in the management of diabetes mellitus and its complications.

## **Author's contributions**

**Conceptualization:** Mfon I. Akpaso

**Data curation:** Mfon I. Akpaso, Sadeyeng Ernest Anani, Michael E. Oku, Lydia E. Bassey.

**Formal analysis:** Mfon I. Akpaso, Sadeyeng Ernest Anani, Theresa E. Isamoh, Michael E. Oku

**Formal acquisition:** Michael E. Oku, Lydia E. Bassey, Williams A. Nnenna, Elton N. Takim.

**Investigation:** Mfon I. Akpaso, Sadeyeng Ernest Anani, Lydia E. Bassey, Eric A. Agaba

**Methodology:** Mfon I. Akpaso, Michael E. Oku, Sadeyeng Ernest Anani

**Project administration:** Sadeyeng Ernest Anani, Lydia E. Bassey, Elton N. Takim, Michael E. Oku,

**Resources:** Mfon I. Akpaso, Nsikak M. Umoh, Eric A. Agaba, Theresa E. Isamoh, Gideon Uzor.

**Software:** Nsikak M. Umoh, Elton, Williams A. Nnenna, Lydia E. Bassey, Gideon Uzor.

**Supervision:** Mfon I. Akpaso, Sadeyeng Ernest Anani

**Writing original draft:** Mfon I. Akpaso, Sadeyeng Ernest Anani, Michael E. Oku, Lydia E. Bassey

**Writing-review & editing:** Mfon I. Akpaso, Sadeyeng Ernest Anani, Michael E. Oku, Eru Mba Eru, Theresa E. Isamoh, Nsikak M. Umoh, Elton N. Takim, Eric A. Agaba.

## **Conflict of Interests**

The authors declare no conflicting interest

## **ETHICAL CONSIDERATION**

All authors hereby declare that "Principles of laboratory animal care" (NIH publication No. 85-23, revised 1985) were followed as well as specific national laws where applicable. All experiments have been examined and approved by Faculty Animal Research Ethics committee, Faculty of Basic Medical Sciences, University of Calabar, Cross River state, Nigeria and given a registration number 254ANA2923.

## ***Implication for health policy/practice/research/medical education***

The administration of *Curcuma longa* extract showed improved liver tissue structure, decreased blood glucose level and increased liver enzyme activity when compared to the streptozotocin-treated group. This may be attributed to the phytochemical components in the extract. The result shows that *Curcuma longa* possesses hepato-protective properties and a strong anti-diabetic potential, thereby making it useful in the management of diabetes mellitus and its complications.

**Please cite this paper as:** Akpaso MI, Anani SE, Oku ME, Bassey LE, Nnenna WA, Umoh NM, et al. Ameliorative effect of *Curcuma longa* ethanolic extract on the histology, hepatic glycogen content and some biochemical parameters of the liver in streptozotocin-induced hyperglycemic rats. J Complement Altern Med Res. 2024;

### **Funding/Support**

The authors thank Dr Mfon I. Akpaso & Dr Sadeyeng Ernest Anani and Lydia E. Bassey for providing financial assistance.

### **REFERENCES**

1. Abdel-Misih SR, Bloomston M. Liver anatomy. Surg Clin North Am. 2010, 90(4):643-53.
2. Younossi ZM, Golabi P, Avila L, Paik JM, Srishord M, Fukui N et al. The global epidemiology of NAFLD and NASH in patients with type 2 diabetes: a systemic review and meta-analysis. J Hepatol. 2019, 71 (4): 793-801.
3. Saeedi E, Gheini MR, Faiz F, Arami MA. Diabetes Mellitus and cognitive impairments. World J Diabet. 2016, 7 (17): 412-422.
4. American Diabetes Association. Diagnosis and classification of diabetes mellitus. Diabet Care. 2006, 29: 43-48.
5. Deshpande DD, Harris-Hayes M, Schootman M. Epidemiology of diabetes and diabetes-related complications. Phys Ther. 2008, 88 (11): 1254-1264.
6. Tesfaye S, Boulton AJ, Dickenson AH. Mechanisms and management of diabetic painful distal symmetrical polyneuropathy. Diabet Care. 2013, 36:2456–2465.
7. Leszek J, Trypka E, Tarasov VV, Ashraf GM, Aliev G. Type 3 diabetes mellitus: A novel implication of Alzheimers disease. Current Top Med Chem. 2017, 17(12): 1331–1335.
8. Kobayashi S, Liang Q. Autophagy and mitophagy in diabetic cardiomyopathy. Biochemica et Biophysica Acta. 2015, 1852 (2): 252-261.
9. Feldman EL, Nave KA, Jensen TS, Bennett DLH. New Horizons in diabetic neuropathy: mechanisms, bioenergetics and pain. Neuron. 2017, 93(6):1296–1313.
10. Jaganjac M, Tirosh O, Cohen G, Sasson S, Zarkovic N. Reactive aldehydes second messengers of free radicals in diabetes mellitus. Free Radic Res. 2013, 47(1):39–48.
11. Gomes EC, Silva AN, Oliveira MR. Oxidants, antioxidants and the beneficial roles of exercise-induced production of reactive species. Oxid Med Cell Longev. 2012, 2012: 12.
12. Levinthal GN, Tavill AS. Liver disease and diabetes mellitus. Clin Diabet. 1999, 17: 73.

13. Guven A, Yavuz O, Cam M, Ercan F, Bukan N, Comunoglu C, et al. Effects of melatonin on streptozotocin-induced diabetic liver injury in rats. *Acta Histochem.* 2006, 108:85–93.
14. Bugianesi E, McCullough AJ, Marchesini G. Insulin resistance: a metabolic pathway to chronic liver disease. *Hepatology.* 2005, 42:987–1000.
15. Manna P, Das J, Ghosh J, Sil PC. Contribution of type 1 diabetes to rat liver dysfunction and cellular damage via activation of NOS, PARP, I $\kappa$ B $\alpha$ /NF- $\kappa$ B, MAPKs, and mitochondria-dependent pathways: Prophylactic role of arjunolic acid. *Free Radic Biol Med.* 2010, 48:1465–84.
16. Palsamy P, Sivakumar S, Subramanian S. Resveratrol attenuates hyperglycemia-mediated oxidative stress, proinflammatory cytokines and protects hepatocytes ultrastructure in streptozotocin-nicotinamide-induced experimental diabetic rats. *Chem Biol Interact.* 2010, 186:200–10.
17. Inzucchi SE, Bergenstal RM, Buse JB, Diamant M, Ferrannini E, Nauck M et al. Management of hyperglycemia in type 2 diabetes: a patient-centered approach: update to a position statement of the American Diabetes Association and the European Association for the study of Diabetes. *Diabet care.* 2015, 38:140-149.
18. Abe M, Okada K, Soma M. Antidiabetic agents in patients with chronic kidney disease and end-stage renal disease on dialysis: metabolism and clinical practice. *Curr Drug Metabol.* 2011, 12:57-69.
19. Kooti W, Moradi M, Akbari SA, Sharafi-Ahvazi N, AsadiSamani M, Ashtary-Larky D. Therapeutic and pharmacological potential of *Foeniculumvulgare* Mill: a review. *J Herb Med Pharmacol.* 4:1–9.
20. Nasri H, Rafieian-Kopaei M. Metformin: common knowledge. *J Res Med Sci.* 2014, 19 (7): 658-664.
21. Anani SE, Oku ME, Eru EM, Uruakpa KC, Bassey IF, Udo-affah GU et al. Neuroprotective effect of *Dacryodes edulis* ethanolic leaf extract on the prefrontal cortex and long-term learning and memory in Wistar rats of ketamine-induced neurotoxicity. *Asian J Res Rep Neurol.* 2024, 7 (1): 86-97.
22. Anani SE, Eru EM, Okon DE, Uruakpa KC, Ugbem TI, Igiri AO. The effect of *Averrhoa carambola* (Star Fruit) aqueous fruit extract on the hippocampal astrocyte expression following diazepam-induced neurotoxicity in Wistar rats. *Trop J Nat Prod Res.* 2020, 4 (12): 1170-1173.
23. Beppe BJ, Dongmo AB, Foye HS, Tsabang N, Olteanu Z, Cioanca O et al. Memory-enhancing activities of aqueous extract of *Albizia adianthifolia* leaves in the 6-hydroxydopamine lesion rodent model of Parkinson's disease. *Complement Altern Med.* 2014, 2014 (14): 142.
24. Boussadia A, Kharoubi O, Lahouel Z, Benglia A, Aoues A. Effect of aqueous *Salvia officinalis* extract on aluminium-chloride-induced neurotoxicity in female rats. *Int J of Pharm Res Allied Sci.* 2020, 9 (2): 139-150.

25. Eru EM, Gabriel UU, Ifiok FB, Kelechi CU, Samson OP, Michael EO et al. Efficacy of aqueous extract of *Talinum triangulare* on the microanatomy of the hippocampus and short-term memory of scopolamine hydrobromide-induced alzheimer's type cognitive dysfunction rats. Niger. J. Physiol. Sci. 2024;39 (in press).
26. Paulinus SO, Eru EM, Udo-Affah GU, Oku ME, Bassey IF, Uruakpa KC. Lipid peroxidation and glutathione level following scopolamine-induced cognitive dysfunction in rats: potentials of *Telfairia occidentalis* seeds and *Talinum triangulare* leaves aqueous extracts. Asian J Res Rep Neurol. 2024, 7 (1): 98-106.
27. Eru EM, Anani SE, Paulinus SO. Otu ME, Uruakpa KC, Umoh NM, et al. Scopolamine-induced Alzheimer's disease in Wistar rats: aqueous *Talinum triangulare* potency on the hippocampal Nissl bodies and long-term learning and memory. Trop J Nat Prod Res. 2022, 6 (11): 117-122.
28. Eru EM, Paulinus SO, Udo-affah GU, Uruakpa KC, Oku ME, Anani SE, et al. Hippocampal astrogliotic reduction in scopolamine hydrobromide-induced Alzheimer's cognitive dysfunction Wistar rats following administration of *Telfairia occidentalis* (Hoof F.) Niger J Physiol Sci. 2021, 36: 241-244.
29. Eru EM, Udo-Affah GU, Paulinus SO, Uruakpa KC, Oku ME, Anani SE, et al. Restorative potentials of aqueous *Telfairia occidentalis* seeds extract on the hippocampal Nissl granules and short-term memory in Scopolamine hydrobromide-induced Alzheimer's type cognitive dysfunction rats. Trop J Nat Prod Res. 2021; 5(1):182-187.
30. Bassey IF, Udo-affah GU, Eru EM, Umoh NM, Mathias OA, Nnenna WA et al. Histochemical study of Nissl substance and astrocytes in a pentylenetetrazole-induced model of epilepsy treated with *Musa paradisiaca* stem juice. Niger. J. Physiol. Sci. 2024;39: (in press).
31. Kharoubi O, Slimani M, Hamadouche A, Krouf D, Aoues A. Protective effect of wormwood extract on lead-induced neurotoxicity and cognitive disorder. Int J Green Pharm. 2010, 4 (3).
32. Ononamadu CJ, Alhassan AJ, Ibrahim A, Imam AA, Ighebor GC, Owolarafe TA, et al. Methanol-extract fractions of *Dacryodes edulis* leaves ameliorate hyperglycemia and associated oxidative stress in streptozotocin-induced diabetic rats. J Evid Based Integr Med. 2019, 2019: 24.
33. Shafri MAM, Jais AMM, Jaffri JM, Kim MK, Ithnin H, Mohammed F. Cresyl violet staining to assess neuroprotective and neuroregenerative effects of Hanian traditional extract against neurodegenerative damage of ketamine. Int J Pharm Sci. 2012, 4 (4).
34. Kumar N, Sakhya SK. Ethnopharmacological properties of *Curcuma longa*: a review. Intl J Pharmac Sci Res. 2013, 11: 103-112.
35. Matias JN, Achete G, Campanari G, Guiguer ÉL, Araújo AC, Buglio DS. et al. A systematic review of the antidepressant effects of Curcumin: beyond monoamines theory. Aust New Z J Psychiat. 2021, 4867421998795.

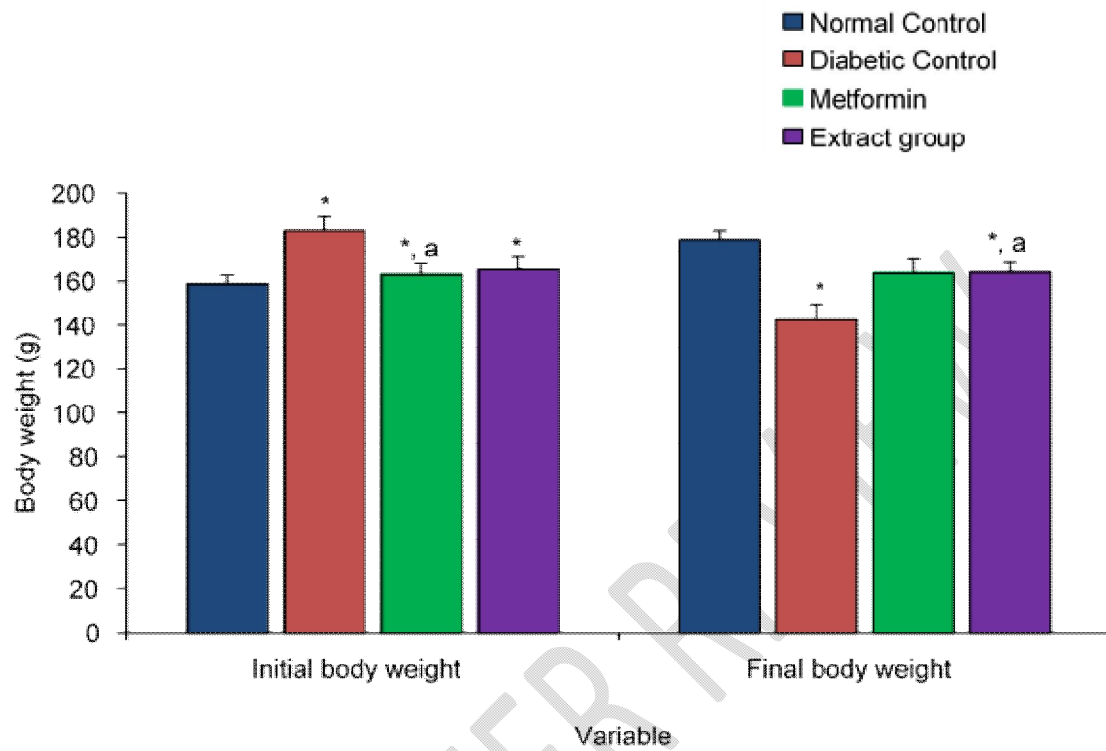
36. Olojede AO, Nwokocha CC, Akinpelu AO, Dalyop T. Effect of variety, rhizome and seed bed types on yield of turmeric (*Curcuma longa* L.) under a humid tropical agro-ecology. *Adv Biol Res.* 2009, 3 (1-2): 40-42.
37. Prasad S, Gupta SC, Tyagi AK, Aggarwal BB. Curcumin, a component of golden spice: from bench and back. *Biotechnol Adv.* 2014, 32 (6): 1053-1064.
38. Deogade S, Ghate S. Curcumin: therapeutic applications in systemic and oral health. *Int J Biol Pharm Res.* 2015, 6 (4): 284-290.
39. Martinez-Correa HA, Paula JT, Carolina A, Kayano AV, Queiroga AL, Magalhaes PM et al. Composition and antimalarial activity of extracts of *Curcuma longa* L. obtained by a combination of extraction processes using supercritical CO<sub>2</sub>, ethanol and water as solvents. *J Supercritical Fluids.* 2017, 119: 122-129.
40. Lorke D. A new approach to practical acute toxicity testing. *ArchivToxicol.* 1983, 541: 275-287.
41. Tobou FGD, Tendonkeng F, Miegoue E, Noumbissi BMN, Wauffo DF, Kuitche HM. Effect of dietary incorporation of *Curcuma longa* powder on haematology and serological properties of guinea pigs (*Cavia porcellus*). *Open J Anim Sci.* 2020, 10 (4): 750-760.
42. Niranjana A, Prakash D. Chemical constituents and biological activities of turmeric (*Curcuma longa* L.): A review. *J Food Sci Technol.* 2008, 45 (2): 109-116.
43. Ugochukwu NH, Cobourne MK. Modification of renal oxidative stress and lipid peroxidation in streptozotocin-induced diabetic rats treated with extracts from *Gongronemalatifolium* leaves. *Clin Chim Acta.* 2003, 336 (1-2): 73-81.
44. Thiraphatthanavong P, Wattanathorn J, Muchimapura S, Thukham-mee W, Lertrat K, Suriharn B. The combined extract of purple waxy corn and ginger prevents cataractogenesis and retinopathy in streptozotocin-diabetic rats. *Oxid Med Cell Longev.* 2014: 789406.
45. Reitman S, Frankel S. A colorimetric method for the determination of serum glutamic oxalacetic and glutamic pyruvic transaminases. *American J Clin Pathol.* 1957, 28: 56.
46. Schlebusch H, Rick W, Lang H, Knedel M. Standards in the activities of clinically important enzymes. *Deutsche medizinische Wochenschrift.* 1976, 99 (15): 765-766.
47. Avwioro OG. *Histochemistry and tissue pathology, principles and techniques.* 2010. Accessed 20 August 2020. Available: [https://www.researchgate.net/publication/315797013\\_Histochemistry\\_and\\_Tissue\\_Pathology](https://www.researchgate.net/publication/315797013_Histochemistry_and_Tissue_Pathology).
48. Karimabad MN, Khalili P, Ayoobi F, Esmaili-Nadimi A, Vecchia CL, Jamali Z. Serum liver enzymes and diabetes from the Rafsanjan cohort study. *BMC Endocr Disord.* 2022, 22: 127.
49. Rodriguez V, Plavnik L, Talamoni NT. Naringin attenuates liver damage in streptozotocin-induced diabetic rats. *Biomed Pharmacother.* 2018, 105: 95-102.

50. Yazdi HB, Hojati V, Shiravi A, Hosseinian S, Vaezi G, Hadjzadeh M. Liver dysfunction and oxidative stress in streptozotocin-induced diabetic rats: protective role of *Artemisia turanica*. J Pharmacopuncture. 2019, 22 (2) 109-114.
51. Guven A, Yavuz O, Cam M, Ercan F, Bukan N, Comunoglu C, et al. Effects of melatonin on streptozotocin-induced diabetic liver injury in rats. Acta Histochem. 2006, 108: 85–93.
52. Ghasemi A, Jeddi S. Streptozotocin as a tool for induction of rat models of diabetes: a practical guide. Excli J Expt Clin Sci. 2023, 22: 274-294.
53. Srinivasan K, Viswanad B, Asrat L, Kaul CL, Ramarao P. Combination of high-fat diet-fed and low dose streptozotocin-treated rat: a model for type 2 diabetes and pharmacological screening. Pharmacol Res. 2005, 52: 313-320.
54. Su HC, Hung LM, Chen JK. Resveratrol, a red wine antioxidant, possesses an insulin-like effect in streptozotocin-induced diabetic rats. Am J Physiol Endocrinol Metab. 2006, 290: 1339-1346.
55. Oku ME, Akpaso MI, Odey PA, Eru EM, Anani SE, Umoh NM. Sterological studies on ameliorative role of ethanolic extracts of *Gongronemalatifolium* against streptozotocin-induced diabetic splenic tissue damage in Wistar rats. Asian J Immunol. 2024, 7 (1): 131-148.
56. Essa R, Sadek AM, Baset ME, Rawash MA, Sami DG, Badawy MT et al. Effects of turmeric (*Curcuma longa*) extract in streptozocin-induced diabetic model. J Food Biochem. 2019, 43(9):e12988.
57. Saleem M, Hussain A, Akhtar MF, Saleem A, Sadeeqa S, Naheed S. Ameliorating effect of *Malva neglecta* on hyperglycemia and hyperlipidemia in diabetic rats. Braz J Pharm. 2021, 2021: 57.
58. Horakova O, Kroupova P, Bardova K, Buresova J, Janovska P, Kopecky J, et al. Metformin actually lowers blood glucose levels by inhibition of intestinal glucose transport. Sci Rep. 2019, 9: 6156.
59. Za'abi MA, Ali BH, Suleimani YA, Adham SA, Ali H, Manoj P. et al. The effect of diabetic and non-diabetic rats with experimentally-induced chronic kidney disease. Biomolecules. 2021, 11 (6): 814.
60. Iweala EJ, Uche ME, Dike ED, Etumnu LR, Dokunmu TM, Oluwapelumi AE et al. *Curcuma longa* (Turmeric): ethnomedical uses, phytochemistry, pharmacological activities and toxicity profiles-a review. Pharmacol Res Modern Chines Med. 2023, 6: 100222.
61. Chiu J, Khan ZA, Farhangkhoe H, Chakrabarti S. Curcumin prevents diabetes-associated abnormalities in the kidneys by inhibiting p300 and nuclear factor- $\kappa$ B. Nutrition. 2009, 25: 964–972.
62. Hussain HEM. Hypoglycemic, hypolipidemic and antioxidant properties of combination of Curcumin from *Curcuma longa* Linn and partially purified product from *Abroma augusta*Linn in streptozotocin-induced diabetes. Ind J Clin Biochem. 2002, 17 (2): 33-43.

63. Hodaiei H, Adibian M, Nikpayam O, Hedayati M, Sohrab G. The effect of curcumin supplementation on anthropometric indices, insulin resistance and oxidative stress in patients with type 2 diabetes: a randomized, double-blind clinical trial. *DiabetolMetab Syndr*. 2019, 11: 41.
64. Gorboulev V, Schürmann A, Vallon V, Kipp H, Jaschke A, Klessen D. Na (+)-D-glucose cotransporter SGLT1 is pivotal for intestinal glucose absorption and glucose-dependent incretin secretion. *Am J Physiol Renal Physiol*. 2013, 304 (2):156-67.
65. Seo KI, Choi MS, Jung UJ, Kim HJ, Yeo J, Jeon SM et al. Effect of curcumin supplementation on blood glucose, plasma insulin, and glucose homeostasis related enzyme activities in diabetic db/dbmice. *Mol. Nutr. Food Res*. 2008, 52(9):995–1004.
66. Schmatz R, Perreira LB, Stefanello N, Mazzanti C, Spanevello R, Gutierrez J et al. Effects of resveratrol on biomarkers of oxidative stress and on the activity of delta aminolevulinic acid dehydratase in liver and kidney of streptozotocin-induced diabetic rats. *Biochimie*. 2012, 94:374–383.
67. Rashid K, Sil PC. Curcumin ameliorates testicular damage in diabetic rats by suppressing cellular stress-mediated mitochondria and endoplasmic reticulum-dependent apoptotic death. *BiochemBiophys Acta*. 2015, 1852 (1): 70-82.
68. Rahmani S, Asgary S, Askari G, Keshvari M, Hatamipour M, Feizi A et al. Treatment of non-alcoholic fatty liver disease with curcumin: a randomized placebo-controlled trial. *Phytother Res*. 2016, 2016.
69. Gutierrez VO, Pinheiro CM, Assis RP, Vendramini RC, Pepato MT, Brunetti IL. Curcumin-supplemented yoghurt improves physiological and biochemical markers of experimental diabetes. *Br J Nutr*. 2012, 108: 440–448.
70. Hussein SA, Elhadary AEA, Elgzar YM. Biochemical study on the protective effect of curcumin on thioacetamide-induced hepatotoxicity in rats. *Benha Med J*. 2014, 27 (1): 175-185.
71. Shahidi F, WanasundaraPKJ. Phenolic antioxidants. *Crit. Rev. Food Sci. Nutr*. 1992, 32: 67-103.
72. Soguyko YUR, Krivko Yu, Barker EN, Novikov TOE. Morphofunctional characteristics of the rat liver in normal and diabetes in the experiment. *Modern Prob Sci Edu*. 2013, 2013: 52-59.
73. Xie Z, Zeng X, Li X, Wu B, Shen G, Wu Q, Wu C. Curcumin attenuates oxidative stress in liver in Type 1 diabetic rats. *Open Life Sci*. 2017, 12 (1): 452-459.
74. Ahmad FK, He Z, King GL. Molecular targets of diabetic cardiovascular complications. *Current Drug Targets*. 2005, 6 (4): 487-494.
75. Jiang Z, Woollard A, Wolff SP. Hydrogen peroxide production during experimental protein glycation. *Febs Letters*. 1990, 268 (1): 69-71.
76. Mohamed J, Nafizah AN, Zariyantey A, Budin SB. Mechanisms of diabetes-induced liver damage: the role of oxidative stress and inflammation. *Sultan Qaboos Univ Med J*. 2016, 16 (2): e132.

77. Yang Q, Cheng L, Zhang T, Yaron S, Jiang H, Sui Z et al. Phenol profiles, antioxidant and antiproliferative activities of turmeric (*Curcuma longa*). *Industr Crops Prod.* 2020, 152: 112561.
78. Sadhwani S. Carambola (starfruit) *Averrhoa carambola*. Accessed 17 April 2021. Available: <https://www.ayurtimes.com/carambola-starfruit-averrhoa-carambola/>.
79. Pharm-Huy LA, He H, Pharm-Huy C. Free radical: antioxidants in disease and Health. *Int J Biomed Sci.* 2008, 4 (2): 89-96.
80. Suresh BP, Srinivasan K. Amelioration of renal lesions associated with diabetes by dietary curcumin in streptozotocin diabetic rats. *Mol Cell Biochem.* 1998, 181: 87–96.
81. Xia Z, Chen W, Shi L, Jiang X, Li K, Wang Y et al. The underlying mechanisms of *Curcumin* inhibition of hyperglycemia and hyperlipidemia in rats fed a high-fat diet combined with STZ treatment. *Molecules.* 2020, 25 (2): 271.

UNDER PEER REVIEW

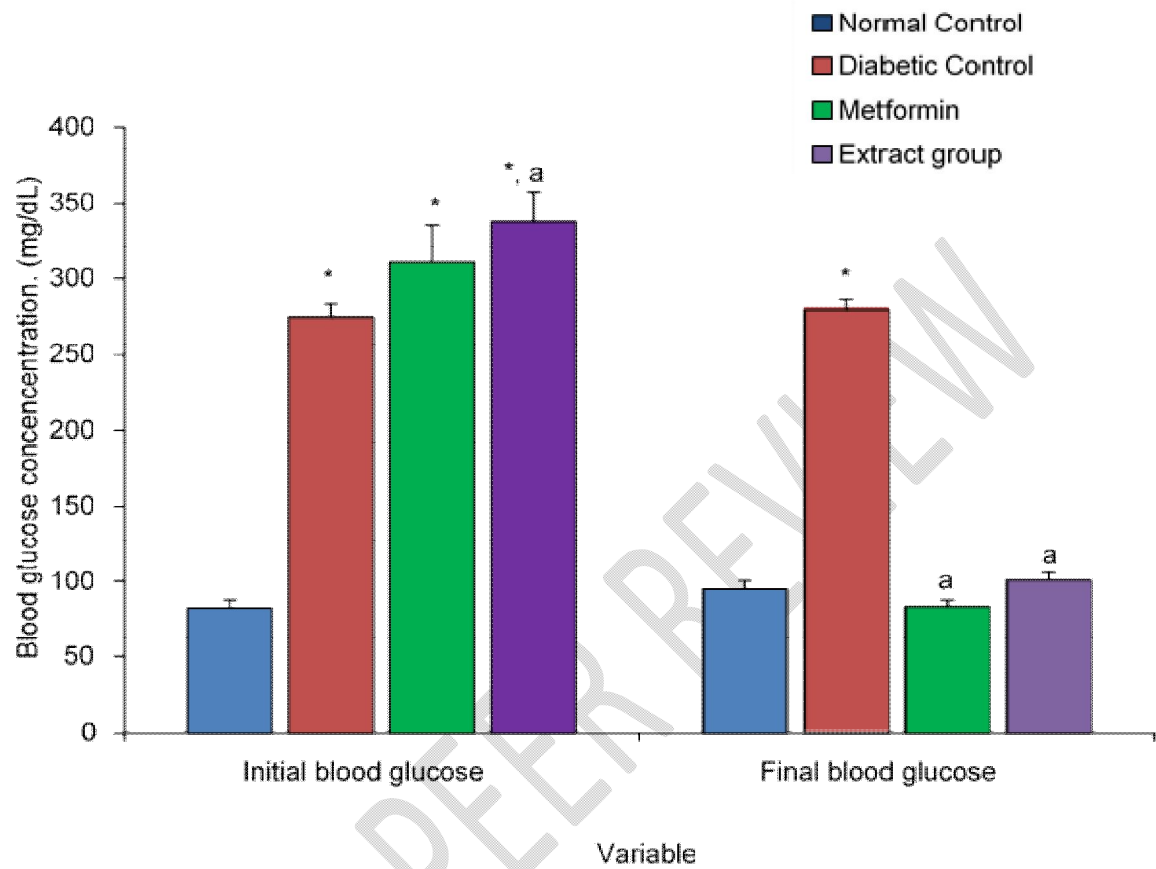


**Figure 1:** Initial and final body weights of the different experimental groups.

Values are expressed as mean +SEM, n = 4.

\* = significantly different from control at  $p < 0.05$

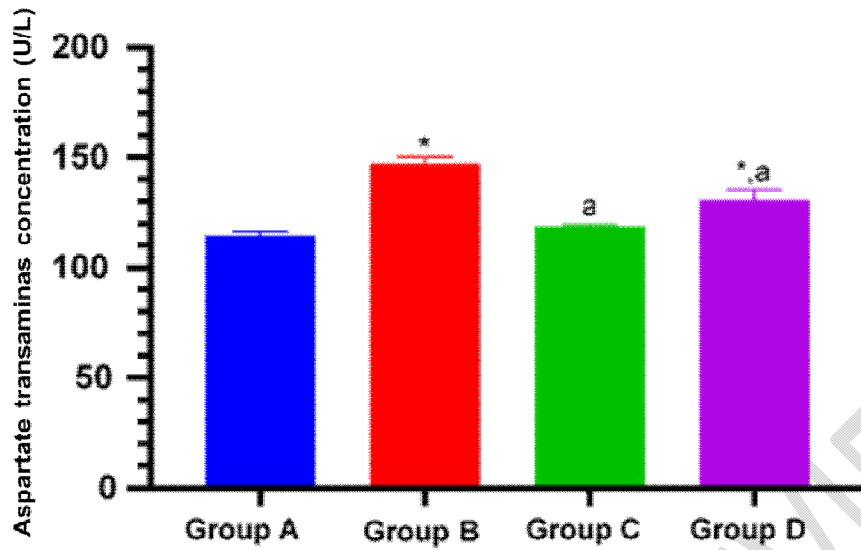
a = significantly different from diabetic control at  $p < 0.05$



**Figure 2:** Initial and final blood glucose concentrations of the different experimental groups.

Values are expressed as mean +SEM, n = 4.

a = significantly different from diabetic control at  $p < 0.05$

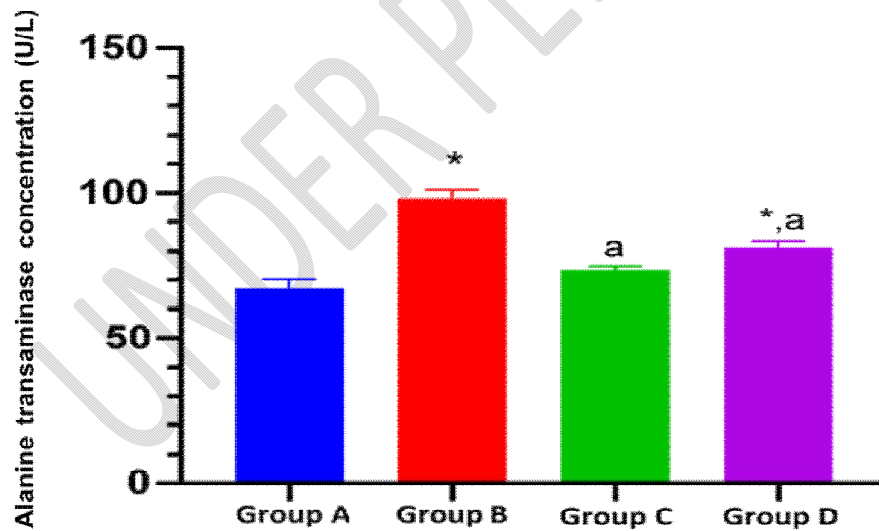


**Figure 3:** Comparison of Aspartate transaminase activities (U/L) in the different experimental groups.

Values are expressed as Mean  $\pm$  SEM, n=4 (Using One way Analysis of Variance).

\*= Significantly different from Group A at  $p < 0.05$

a= Significantly different from Group B at  $p < 0.05$

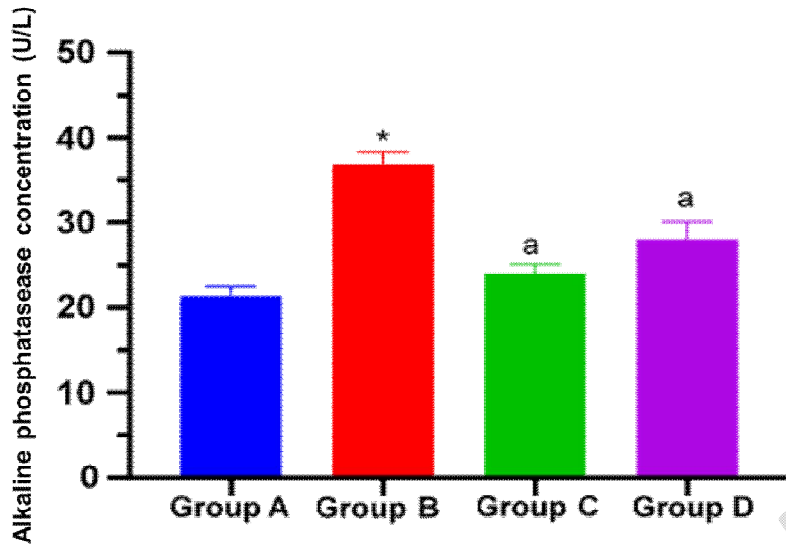


**Figure 4:** Comparison of Alanine transaminase activities (U/L) in the different experimental groups.

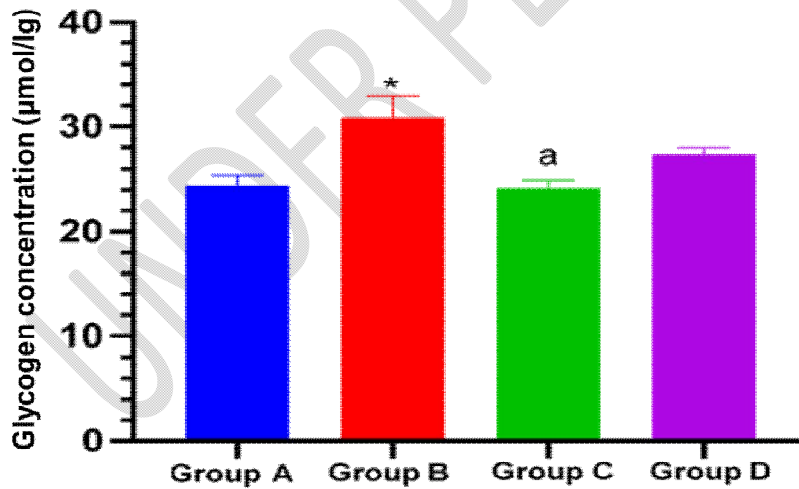
Values are expressed as Mean  $\pm$  SEM, n=4 (Using One way Analysis of Variance).

\*= Significantly different from Group A at  $p < 0.05$

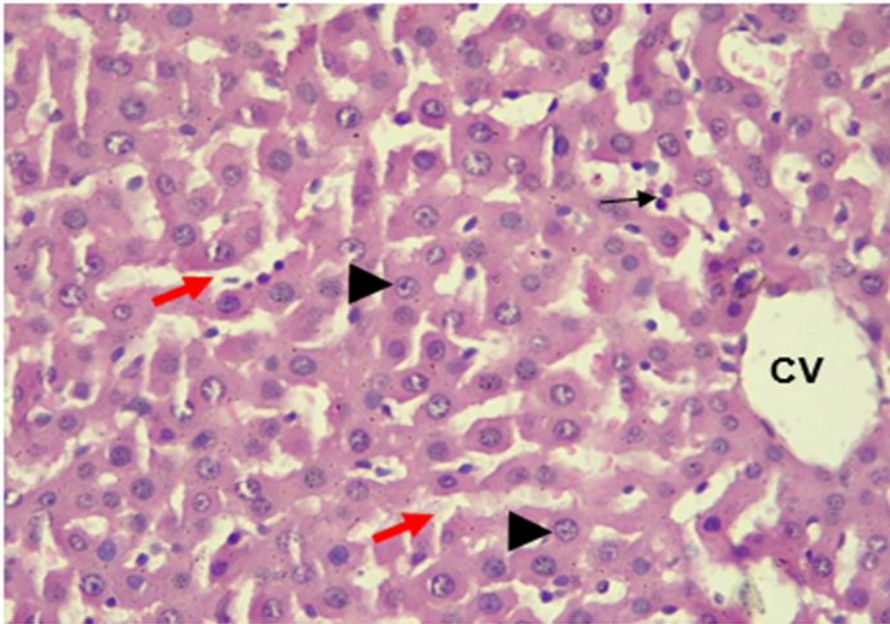
a= Significantly different from Group B at  $p < 0.05$



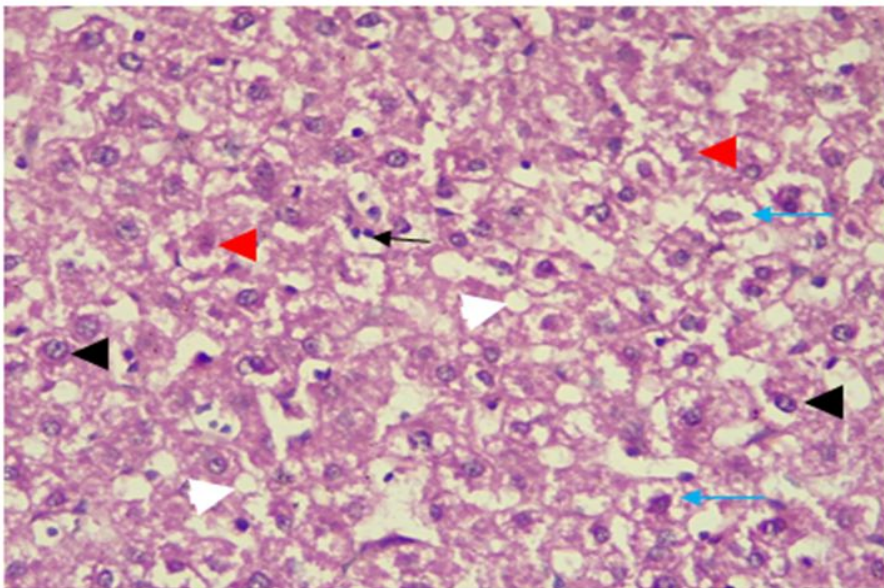
**Figure 5:** Comparison of Alkaline phosphatase activities (U/L) in the different experimental groups. Values are expressed as Mean  $\pm$  SEM, n=4 (Using One way Analysis of Variance).  
 \*= Significantly different from Group A at  $p < 0.05$   
 a= Significantly different from Group B at  $p < 0.05$



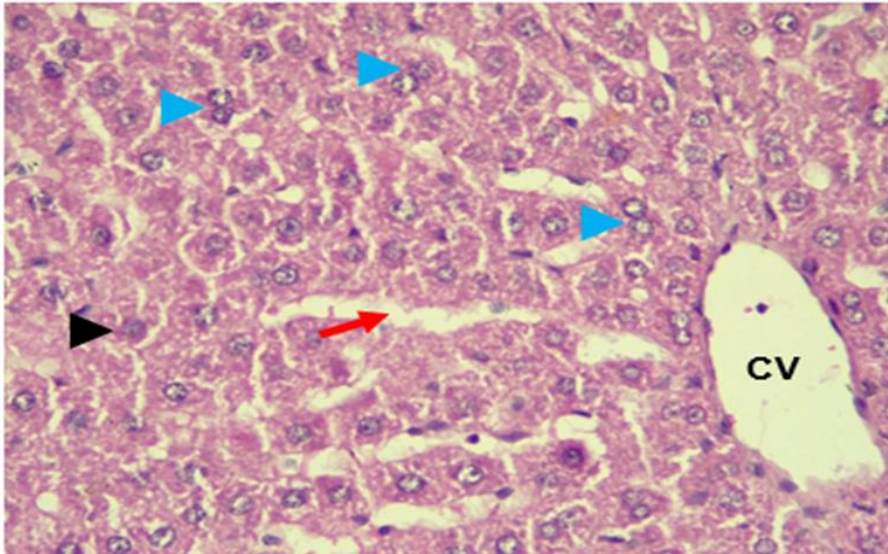
**Figure 6:** Comparison of Glycogen content in the different experimental groups. Values are expressed as Mean  $\pm$  SEM, n=4 (Using One way Analysis of Variance).  
 \*= Significantly different from Group A at  $p < 0.05$   
 a= Significantly different from Group B at  $p < 0.05$



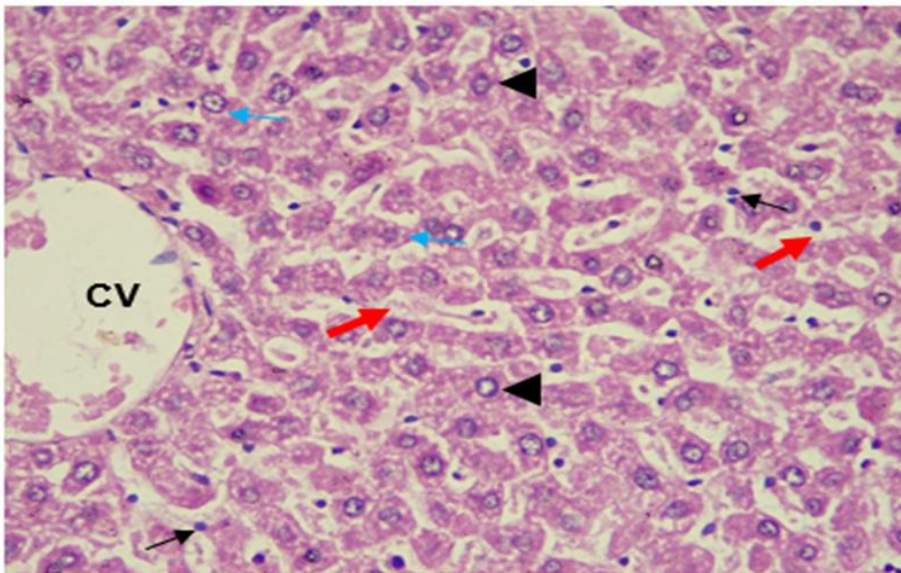
**Plate 1:** Photomicrograph (X400) of a unit of liver tissue (H&E-stained section) of group A rats (normal control group) displaying normal architecture with arrays of hepatocytes (arrowhead), Kupfer cells (thin arrows) in sinusoids (red arrow) and a central vein (CV). No lesion is seen.



**Plate 2:** Photomicrograph (X400) of a unit of liver tissue (H&E-stained section) of group B rats (diabetic control group) displaying widely spread cytoplasmic vacuolation (thin red arrow). Also seen are necrotic hepatocytes (blue arrowhead) and single-scattered macrovesicular steatosis (white arrowhead).



**Plate 3:** Photomicrograph (X400) of a unit of liver tissue (H&E-stained section) of group C rats (metformin group) displaying hepatocytes (arrowhead) with binucleated cytoplasmic vacuolations (blue arrowhead), a central vein (CV) and sinusoidal spaces. No pathological lesion seen.



**Plate 4:** Photomicrograph (X400) of a unit of liver tissue (H&E-stained section) of group D rats (*Curcuma longa* extract group) displaying an array of hepatocytes (arrowhead), central vein (CV) and Kupfer cells (thin black arrow) in the sinusoidal spaces (red arrows). The section shows a preserved architecture of the liver.