

Intrarectal migration of a surgical compress: a report case

Abstract

Rectal foreign body is a pathology that challenge by its complexity emergency departments around the world. The diagnosis and management need a delicate approach, the foreign body can be successfully extracted by digital maneuver, endoscopy or surgery. We report here a rare case of an transanal migration of a surgical compress after anal biopsy. The surgical compress was retrieved after defecation by using enema. This article was written to raise awareness about the possibility of transanally migration of medical objects and the management of such phenomena.

Introduction :

Rectal foreign body are a frequent clinical entity in visceral emergencies, and their management has been codified in the literature. However, they require special attention due to the nature of the object and the risk of perforation. We report the case of an accidental migration of a surgical compress through the anus.

Case

A 30 year old-male with no significant medical history, presented to our department with constipation and straining to start or finish a bowel movement, and the feeling a bulge outside the after defecation.

Colonoscopy was normal, and pelvic MRI didn't find any sign in favor of prolapsus, an anoscopy was performed showing a suspicious lesion which was biopsied, a surgical compress was used as a bandage.

The fellow-up was marked by the intra-rectal migration of the surgical compress, the patient was asymptomatic, the clinical examination was without abnormalities . An abdomino-pelvic X-ray showed the surgical compress in the abdomen (figure 1). A rectoscopy was performed but it didn't reach the compress, a 100 ml of enema was used and the compress was evacuated with the feces after defecation (figure 2)

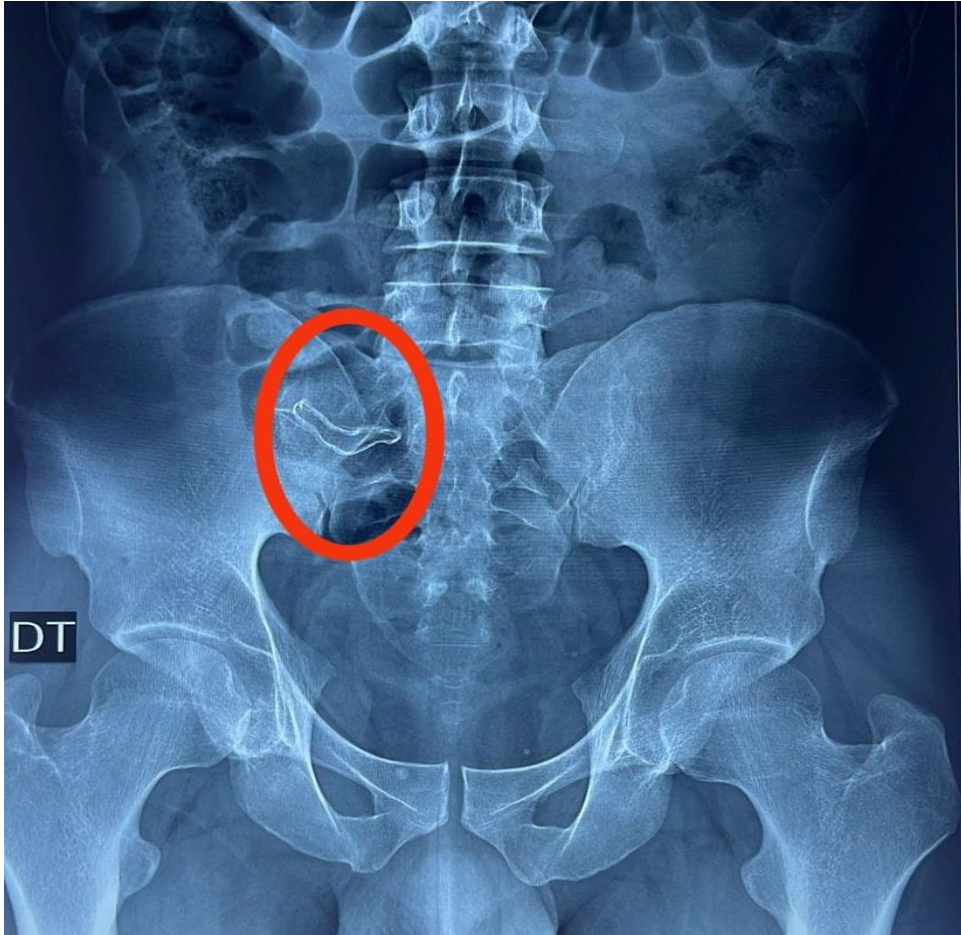


Figure 1 : Abdomino-pelvic X-ray showing the surgical compress

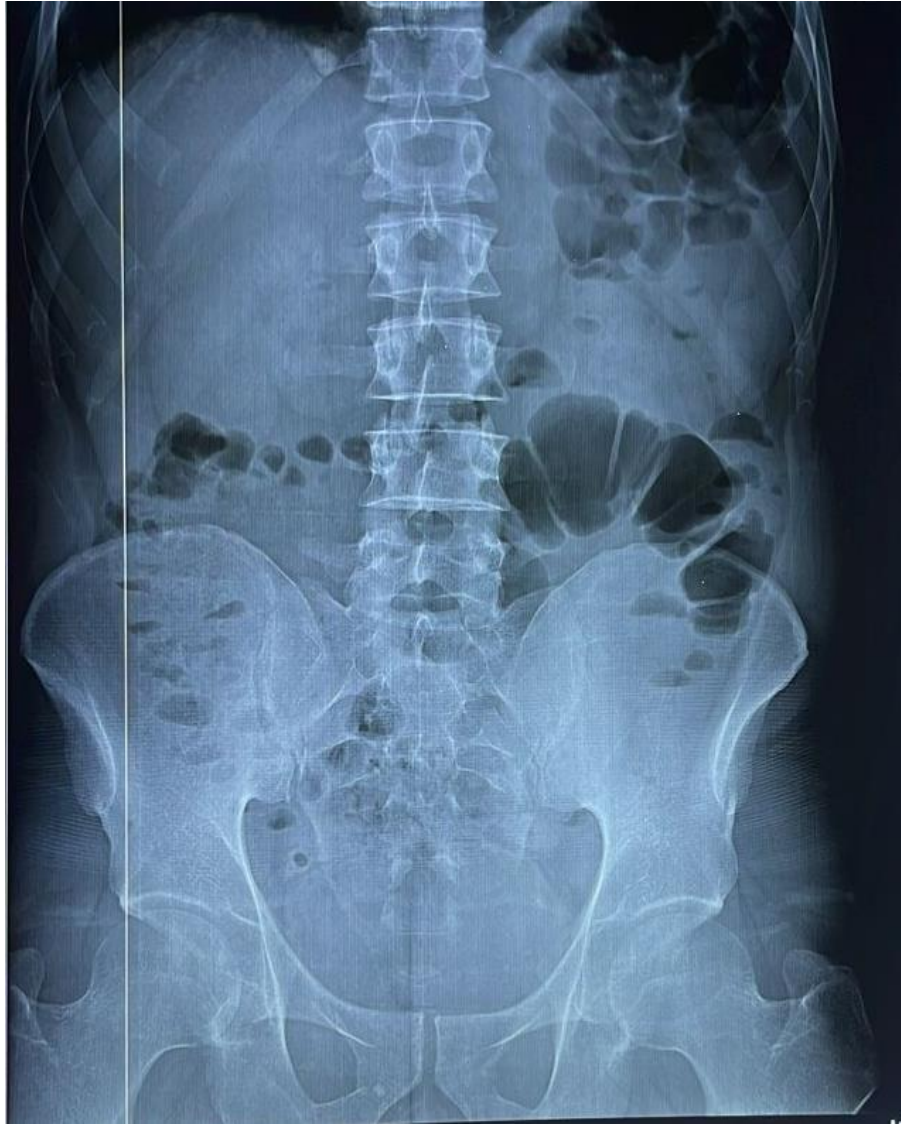

Figure 2 : Abdomino-pelvic X-ray after the use of enema

Discussion

Intra-rectal foreign body is an important emergency surgery due to its complications which are related with the object. In our case the object was a surgical compress.

Anal foreign bodies are introduced into the anus for sexual purpose, during rape or accidents and drug smuggling. It can be removed by digital examination, endoscopy or surgery.[1] due to the soft nature of the compress an enema

The diagnosis of a foreign body in the anorectal region relies on a thorough clinical history, a physical examination of the anus and abdomen to detect eventual signs of peritonitis. Symptoms typically include lower abdominal pain, anorectal discomfort, and bleeding, in our case the clinical examination was without abnormalities. [2]

Abdominopelvic X-rays are used to visualize the object position, chest X-rays should be conducted to check for pneumoperitonea under the diaphragm, which a recto-colic perforation [3] . The use of CT-scan is important, it can reveal sign of a perforation that cannot be seen in X-ray [4]. Anoscopy and

procto-sigmoidoscopy should be conducted to evaluate the distance of the rectal foreign body from the anal verge, to assess sphincter competency and to details eventual anal and rectal lesions [5].

If the diagnosis of a foreign body (FB) is confirmed the abdominopelvic X-ray, and it is detected in the low rectum a manual extraction should be attempted, However, this can be challenging due to the foreign morphology and the anatomy of the pelvic region. To help the patient's relaxation and reduce anal sphincter spasms different methods of anesthesia can be used : local anesthesia, spinal bloc, sedation [6].

The anal canal should be gently dilated, and the object should be removed. The use of speculum and the lube may help the operation. Asking the patient to perform a Valsalva maneuver during the procedure may facilitate the removal, for higher position endoscopy may be used for the extraction. In our case the rectoscopy didn't reach the object. Special care should be taken with fragile items, to avoid their breakage and further injury.[7]

After extraction of the foreign body, a procto-sigmoidoscopy must be performed to identify both mucosal injuries and perforations. In our case the foreign body was soft which permitted to use of enema and its evacuation by defecation.

If conservative methods are unsuccessful, or if a rectal perforation occurs surgical intervention becomes necessary [8]. The extraction by laparoscopic is based on the milking technique, which involves gently applying transperitoneal pressure to guide the migrating object back into the rectum for transanal removal, the milking technique can only be used in patients with soft foreign body because of the risk of perforation. Laparotomy is considered a last resort, typically required if transanal removal fails or if complications arise, such as pelvic abscess, intra-abdominal bleeding, or perforation. During the extraction by laparotomy, the milking technique is the initial step, pushing the object distally into the rectum for removal. If the object's shape is unsuitable for milking, a colotomy may be necessary for extraction. The colotomy can be repaired primarily, with or without a stoma. In cases of colonic wall damage, segmental colonic resection and anastomosis may be performed, with stoma placement. A stoma is crucial for patients experiencing perforation with significant fecal contamination, signs of sepsis, or hemodynamic instability [9,10]

Conclusion

Rectal foreign body is a recurrent pathology that need a particularly management, post-surgery transanally migration of medical device can occur for this reason the awareness of medical professionals and patients is important after anal and rectal procedure.

Ethical approval

Authors declare that the ethical approval has been exempted by my establishment

References :

1. Goldberg, Joel E. et Steele, Scott R. Rectal foreign bodies. *Surgical Clinics*, 2010, vol. 90, no 1, p. 173-184.
2. Cinar, H; Berkesoglu, M1; Derebey, M2; Karadeniz, E3; Yildirim, C4; Karabulut, K2; Kesicioglu, T5; Erzurumlu, K2. *Surgical Management of Anorectal Foreign Bodies. Nigerian Journal of Clinical Practice* 21(6):p 721-725, June 2018. | DOI: 10.4103/njcp.njcp_172_17
3. AYANTUNDE, A. A. et OKE, T. A review of gastrointestinal foreign bodies. *International journal of clinical practice*, 2006, vol. 60, no 6, p. 735-739.

4. COSKUN, Ali, ERKAN, Nazif, YAKAN, Savas, et al. Management of rectal foreign bodies. *World Journal of Emergency Surgery*, 2013, vol. 8, p. 1-5.
5. PENGFEI, Zhou, JIADONG, Zhang, JIGEN, Lu, et al. Colonoscopy-assisted removal of foreign body impaction at the rectosigmoid junction: a case and review of the literature. 2023.
6. CIROCCO, William C. Anesthesia facilitates the extraction of rectal foreignbodies. *Gastrointestinal endoscopy*, 2000, vol. 52, no 3, p. 452-453.
7. KASOTAKIS, G., ROEDIGER, L., et MITTAL, S. Rectal foreign bodies: a case report and review of the literature. *International Journal of Surgery Case Reports*, 2012, vol. 3, no 3, p. 111-115
8. KOKEMOHR, Pia, HAEDER, Lars, FRÖMLING, Fabian Joachim, et al. Surgical management of rectal foreign bodies: a 10-year single-center experience. *Innovative surgical sciences*, 2017, vol. 2, no 2, p. 89-95.
9. KIM, Ju Hun, UM, Eunhae, JUNG, Sung Min, et al. The management of retained rectal foreign body. *Annals of Coloproctology*, 2020, vol. 36, no 5, p. 335.
10. PLONER, M., GARDETTO, A., PLONER, F., et al. Foreign rectal body-Systematic review and meta-analysis. *Acta gastro-enterologica Belgica*, 2020, vol. 83, no 1, p. 61-65.

UNDER PEER REVIEW