

A Rare Case of Early Infantile Neuronal Ceroid Lipofuscinosis: Clinical and Diagnostic Insights

*G. Arsalane, A. Ourrai, R. Abilkassem, O. Agdar.
Pediatrics Department, Med V Military Hospital,
Rabat*

Abstract

The aim of the study : The aim of this work is to show the different specific clinical and paraclinical aspects of ceroid lipofuscinosis in its early infantile form named Santavuori-Haltia disease through a new case. Given its rarity especially in consanguineous populations for better understanding the clinical presentation, progression and management of the disease.

Introduction : The neuronal ceroid lipofuscinoses are a group of genetic brain diseases with an autosomal recessive manner characterized by the accumulation of an autofluorescent material in multiple tissues of patients. Clinically, they are progressive decline of mental and motor capacities, epilepsy and visual loss through retinal degeneration. In this work we report the early infantile neuronal ceroid lipofuscinosis or Santavuori-Haltia disease.

Report case : This is a 12-month-old infant from consanguineous parents who has presented with flexion spasms with eyelid clonia since the age of 1 month. The examination found microcephaly, and the neurological examination showed horizontal nystagmus with the absence of ocular pursuit and the presence of a pyramidal and extrapyramidal syndrome. Brain MRI shows delayed myelination. Skin biopsy confirms diagnosis. The Arg122Trp genetic mutation found is the most common one in this disease.

Conclusion : Santavuori-Haltia disease is a rare and serious disease, the prognosis is severe, it must be mentioned in the face of psychomotor regression and a picture of encephalopathy. Confirmation of the diagnosis is based on histological and molecular biology data.

• **Keywords:** Epilepsy; Myoclonus; Ceroid-lipofuscinosis, Santavuori-Haltia disease genetic disorder.

1/ Introduction

Santavuori disease is a lipofuscinosis, with autosomal recessive transmission. It is characterized by the accumulation of lipopigments in nerve cells. Ceroid lipofuscinosis represents a set of neurodegenerative hereditary diseases with autosomal recessive transmission, characterized by a mainly neuronal accumulation of autofluorescent lipopigments.

Four main forms can be distinguished according to clinical, electrophysiological and neuropathological criteria: the early infantile form, the late infantile form, the juvenile form and the adult form, but many clinical variants, electrophysiological and neuropathological criteria: the early infantile form, the late infantile form, the juvenile form and the adult form, but many clinical variants have also been reported. Recent advances in biochemistry and molecular biology have made it possible to link this clinical diversity to a great genetic heterogeneity. The overall incidence of ceroid lipofuscinosis is 1/12,500 in Anglo-Saxon countries. The early infantile form or Santavuori-Haltia disease begins between 3 and 18 months with hypotonia

Epileptic manifestations appear rapidly in the form of myoclonic jerks, then generalized seizures. Visual impairment is rapid. Very quickly, the picture is completed by spastic tetraplegia, blindness, major microcephaly, and epileptic manifestations resistant to therapy.

The onset of the disease is between 3 and 18 months with hypotonia, microcephaly. Epileptic manifestations appear quickly in the form of myoclonic jerks, then generalized seizures.

There may be stereotypies of the hands. Visual impairment is rapid with early optic atrophy and macular degeneration.

The diagnosis is confirmed by electron microscopy (skin, rectal, conjunctival or muscle biopsy) which highlights characteristic osmiophilic granular bodies, by molecular biology study, and by protein dosage. Indeed, the gene for the early infantile form is located in 1p32 and codes for a glycoprotein: the palmitoyl thioesterase protein which is of lysosomal origin.

The Arg122Trp mutation is the most commonly found, it's the one found in this case report.

2/ Observation

12-month-old child, born at term, consanguineous parents, normal delivery with a birth weight of 3200g. At the age of one month, the little girl presented with flexion spasms, with eyelid clonia, as well as attacks of hypertonia and crying. At the age of 4 months, stridor appeared with breathing difficulties.

The clinical examination found a eupneic child, in opisthotonos, did not seem to be in pain, his weight was 8.5 kg (- 1DS), his height was 75 cm (+ 1 DS), for a cranial perimeter of 42 cm (-2 DS).

She presents with bitemporal narrowness, small mouth, flat nasal root, hypertelorism, epicanthus, ogival palate. The child is very hypomobile, and frozen. No contact, no eye tracking. The osteotendinous reflexes are lively, bilateral Babinski, spasticity at the level of the adductors and Achilles. Pyramidal and extrapyramidal syndrome. No hepatosplenomegaly, no skin spots. The photomotor reflex is present with horizontal nystagmus.

The metabolic assessment shows a level of lactate, pyruvate, beta hydroxybutyrate, acetoacetate, amonemia, plasma copper, liver function test: normal. Amino acid and organic acid chromatography is normal. Skeletal X-rays are normal.

The EEG shows a sleep trace, invaded by slow delta voltaic activity, polymorphic, diffuse, synchronous reinforcement with large slow spikes, with a right maximum, flattening passage of 6-7 seconds, with clearer rapid rhythms on the right, some brief desynchronizations, some spasms. The FO is normal. The electroretinogram shows a very altered trace on both sides. VEP: not detected on both sides (stage IV retinopathy).

The brain scan shows a dilation of the ventricular system without dilation of the cerebral spaces, global cerebral atrophy, and a punctiform calcification of the left posterior lenticular nucleus. MRI suggests delayed myelination. The spectroscopic study shows in long ATE, a decrease in the NAA/CR ratio, an increase in the CHO/CR ratio, and therefore a decrease in the NAA/CHO ratio. The short ATE study is normal.

The skin biopsy confirmed the diagnosis of Santavuori-Haltia disease by showing numerous inclusions with more or less irregular contours and containing granular structure material. Molecular biology is in progress. The Arg122Trp mutation is found in this case.

Our patient is currently 18 months old, she is bedridden, and has breathing difficulties and requiring respiratory assistance and palliative treatment., she is fed by gastric tube and receives as anticonvulsant treatment: depakine and rivotril.

A genetic counseling is given to the family.

3/Discussion

Ceroid lipofuscinosis are a group of diseases characterized by deposits of autofluorescent lipopigments in the central nervous system and other organs (1). These autosomal recessive diseases are lysosomal storage diseases, with an enzyme deficiency and dysfunction of a structural protein.

Four main types have been defined on clinical, electrophysiological and neuropathological criteria, the early infantile form, the late infantile form (the case of our patient), the juvenile form and the adult form (2).

The early infantile form or Santavuori-Haltia disease has been reported in different ethnic groups (1). The onset is between 3 and 18 months, with significant hypotonia. Microcephaly is constant, severe and acquired.

Epileptic manifestations appear rapidly in the form of myoclonic jerks, then generalized seizures. There may be stereotypies of the hands. Visual impairment is rapid with early optic atrophy and macular degeneration. Very quickly, the picture is completed by spastic tetraplegia, blindness, major microcephaly, epileptic manifestations resistant to therapy.

The autofluorescence storage material has been shown to resemble ceroid and lipofuscin on histopathological stainings and the name neuronal ceroid lipofuscinosis was introduced by Zeman and Dyken. The NCLs were divided into four subtypes according to clinical facts, electrophysiological facts and the ultrastructure of the storage material: infantile neuronal ceroid lipofuscinosis, late-infantile neuronal ceroid lipofuscinosis, juvenile neuronal ceroid lipofuscinosis and adult neuronal ceroid lipofuscinosis but many variants have been characterized. At least 10 genetically distinct NCLs designated CLN1 to CLN10 are presently known. Estimates of global incidence is 1 in 12,500.(3)

The infantile neuronal ceroid lipofuscinosis begins between 3 and 18 months by muscular hypotonia and decreased head growth and retardation of psychomotor development become apparent. Other clinical features include epileptic seizures, ataxia, myoclonus and visual failure. The disorder leads to very severe brain atrophy and the patients lose the ability to walk by the age of 3 years. Histopathological findings are characterized by accumulation of lipopigment in several tissues and various degrees of brain atrophy: depletion of cortical neurons and cortical astrocytosis.

Death occurs during the first decade .On the EEG, the disappearance of occipital reactivity to opening and closing of the eyes is one of the first signs, then the disappearance of the "spindles" on the sleep tracings is noted during

stage II. The tracings become practically flat isoelectric ("vanishing" EEG). The electroretinogram (ERG) is almost always abolished before eleven months. The visual evoked potentials (VEPs) are extinguished before 40 months. The MRI shows severe and early cerebral and cerebellar atrophy and a very particular hypointensity of the thalamus and gray nuclei. The white matter involvement, visualized in T2 as a hypersignal, is initially periventricular, then extends to the periphery.

Proton magnetic resonance spectroscopy on the one hand highlights neuronal loss objectified by a very significant decrease in NAA, and on the other hand reveals a peak of N-acetyl-glucosamine which would indicate the increase in intracerebral dolichol (4). In SPECT, there is a clear cortical hypoperfusion, primarily fronto-occipital, appearing before the MRI images (5).

The diagnosis is confirmed by electron microscopy study (skin, rectal, conjunctival or muscle biopsy) which highlights characteristic osmiophilic granular bodies (GROD: granular osmiophilic deposits) (6), by molecular biology study, and by protein dosage. Indeed, the gene for the early infantile form is located in 1p32 and codes for a glycoprotein: the palmitoyl thioesterase protein which is of lysosomal origin. The Arg122Trp mutation is the most commonly found (7).

Prenatal diagnosis is possible and is based on the search for the characteristic accumulation on cells from chorionic villi (8). In this early infantile form, molecular biology allows for reliable prenatal diagnosis with good correlation with the ultrastructural study.

On the therapeutic level, the treatment of myoclonus is based on diazepam (Valium®), Urbanyl®, Rivotril® or sodium valproate.

Lamotrigine is a particularly effective therapy in this type of disease, however, Tegretol®, Dihydan®, and Sabril® often aggravate the symptoms. If myoclonus is in the foreground, it is possible to use Piracetam (Nootropyl®), which is well tolerated and effective at high doses, or Levetiracetam (Keppra®). The importance of nursing is considerable, a gastrostomy in advanced forms ensures a correct nutritional state. The importance of pain secondary to retractions should not be underestimated, and they must be treated effectively (9,10).

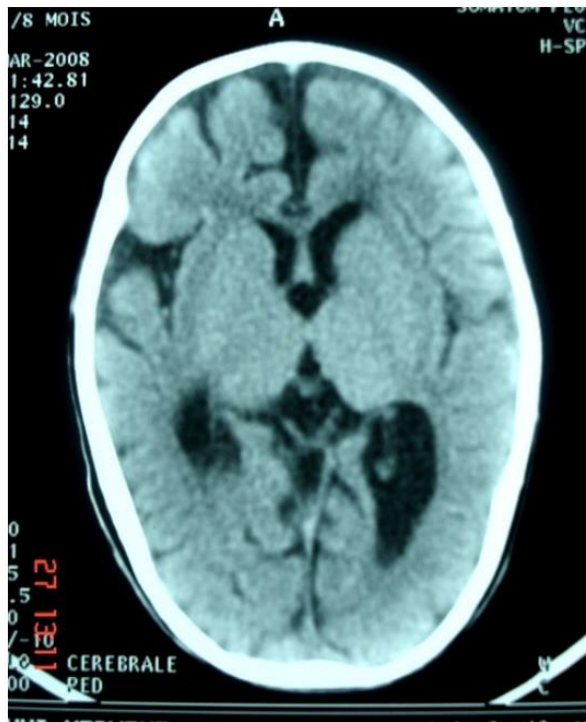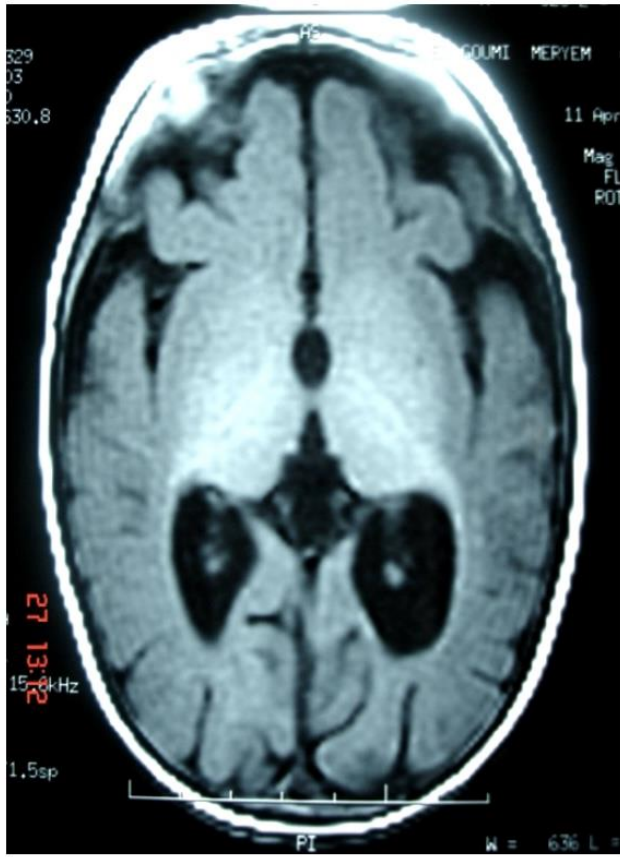
4/Conclusion

Santavuori-Haltia disease is a rare disease, which should be considered in the event of an association of early myoclonic encephalopathy, visual impairment and psychomotor regression.

The diagnosis is confirmed by histology and molecular biology. Prenatal diagnosis is possible and is based on the search for the characteristic accumulation on cells from chorionic villi, and molecular biology.

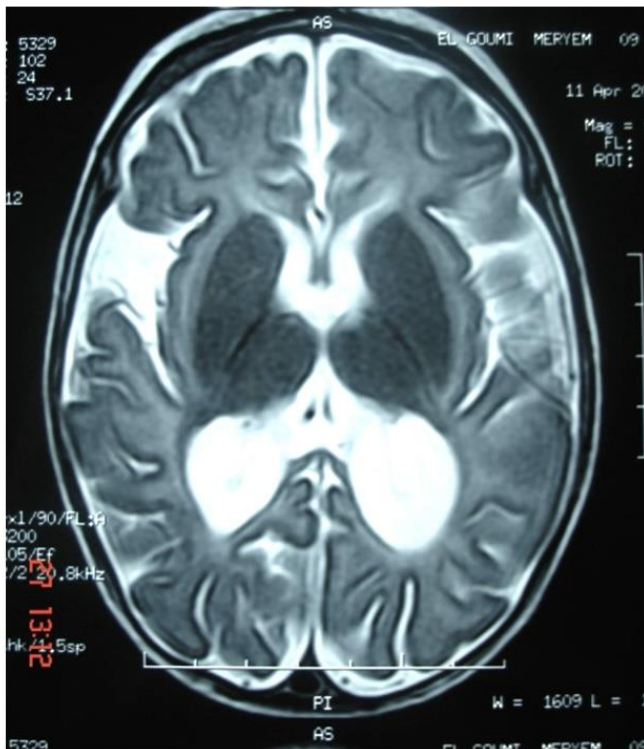
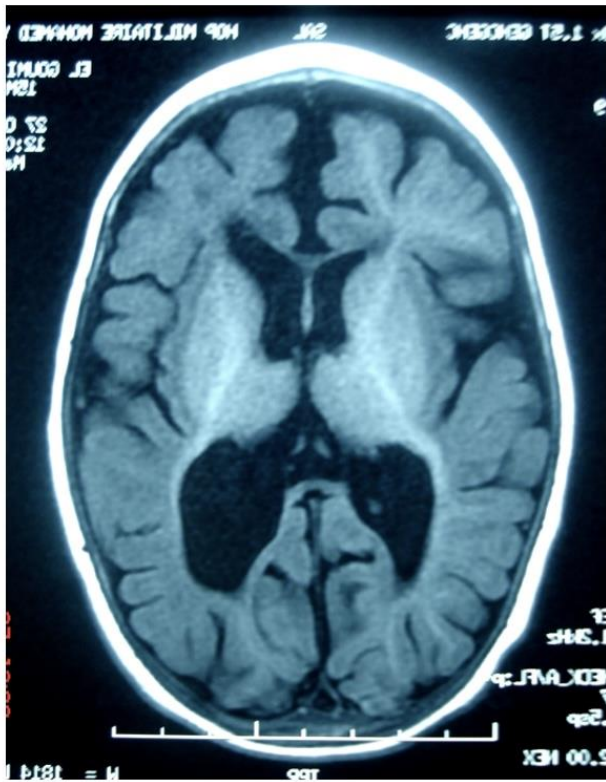
5/References

1. Roger J, Bureau M, Darvet CH, Genton P, Tassinari CA, Wolf P. Epileptic syndromes in children and adolescents. 4th edition, vol 20, chapter 28: 441-466.
2. Chabrol B et al. Les céroïdes lipofuscinoses. *Archive pediatrie* 1997; 4: 671-675.
3. Konrad Kaminiow, Sylwia Kozak, Justyna Paprocka. Phospholipid recent insight into the genetic basis, clinical features and diagnostic methods for neuronal ceroid lipofuscinosis. *International Journal of Molecular Sciences* 23(10)5729,2022.
4. Confort-Gouny S, Chabrol B, Vion-Dury J et al. MRI and localized proton MRS in an early infantile form neuronal ceroid-lipofuscinosis. *Pediatr neurol*, 1993, 9:57-60.
- 5- Vanahanen SL, Liewendahl K, Raininkho R et al. brain perfusion SPECT in infantile neuronal ceroid lipofuscinoses. Comparison with clinical manifestations and MRI findings. *Neuropediatrics*, 1996,27:76-83.
- 6 - Goebbels HH, Mole SE, Lake BD. The neuronal ceroid lipofuscinosis (Batten disease). IOS press; Amsterdam, Netherlands 1999.7-Haines JL, Boustanly RMN, Alroy J et al. Chromosomal localization of two genes underlying late-infantile neuronal ceroid lipofuscinosis. *Neurogenetics* 1998, 1: 217-222.
- 8- Wheeler R.R, Schlie M, Kominami E, Gerhard L, Goebel H.H. Neuronal ceroid lipofuscinosis. *Acta Neuropathol* (2001) 102: 485-488.
- 9- Thouraya Ben Younes, Ichraf Karaoua, Hedia Klau, Catherine Caillaud. Neuronal ceroid lipofuscinosis, clinical, electroencephalographic, radiological and genetic study of a Maghreb series. *Neurological Review* volume 176 supplement September 2020 s104-s105.
- 10-Variant late infantile neuronal ceroid lipofuscinosis because of CLM1 mutation. A.Simonati,A.Tessa,B.Dallal Bernardina..*Pediatric neurology* 40(4),271-276,2009.



Captions:

Cerebral CT: The cerebral CT scan shows a dilation of the ventricular system without dilation of the cerebral spaces, a global cerebral atrophy, and a punctate calcification of the left posterior lenticular nucleus.



Cerebral MRI: suggests a delay in myelination

