

# Review Article

## USE OF 3D GUIDES AND OPERATING MICROSCOPE IN PARENODONTIC SURGERY: A LITERATURE REVIEW

### ABSTRACT

**Aims:** Digital flow is a reality in contemporary Dentistry. In this sense, 3D guides and operating microscopes to improve the performance of endodontic surgeries have gained prominence and are becoming more accessible to dental surgeons. Therefore, the following literature review aims to verify the effectiveness of using these new technologies, comparing conventional surgical techniques with those that use digital means.

**Study design:** Literature Review

**Methodology:** The articles included in the work were found on the search platforms "Pubmed", "CAPES Platform", "Scielo" and "VHL health". Based on chosen terms, those that had been published in the last 10 years, in Portuguese, English or Spanish, were selected and which, after reading, were correlated with keywords in the development of the text and/or dealt with endodontic surgery performed with technological methods. After applying the described methodology, 38 articles were included.

**Conclusion:** When reviewing and analyzing the articles incorporated into the study, it was observed that the authors agreed that the incorporation of new technologies in endodontics, such as 3D guides and microscopes, had positive impacts, providing greater precision and safety. However, there is a need to expand studies and knowledge. This is due to the fact that these are recent techniques that are still being improved.

*Keywords: Apicoectomy; Three-Dimensional Printing; CAD-CAM; Microsurgery; Dental Surgery.*

### 1. INTRODUCTION

It is evident that technology has reached all areas of today's society, making it inevitable in the dental field as well. With the arrival of modernization brought by digital flow, processes have become more accelerated and simplified and cases that were previously complex and almost impossible to treat were resolved with the assistance from digital media.

According to Chaves et al. (2022), digital workflow is defined as any workflow that occurs primarily through the use of conversion of physical or analog structures into a digital format to be manipulated using computer-aided design software [1]. Lots of technological features are used in digital workflow such as beam computed tomography conical (TCFC), computer-aided design and manufacturing (CAD/CAM). A CBCT is widely used in Dentistry and, specifically in endodontics, has proved to be an accurate resource, improving diagnosis,

planning and handling complex cases. CAD/CAM technology allows the digitization of dental and oral cavity structures for the virtual design of simple and complex. This technology was revolutionary for both laboratory protocols as clinical. These resources have been combined in oral surgery, implant dentistry, and endodontics. Through this planning method, it is possible to obtain three-dimensional (3D) images before surgery to define the exact position where the drill will be placed, using printed guides, for example. In recent years, there has been an increased interest in endodontics for guided periapical surgery using 3D guides and electronic microscopes, due to the difficulty in treating challenging cases.

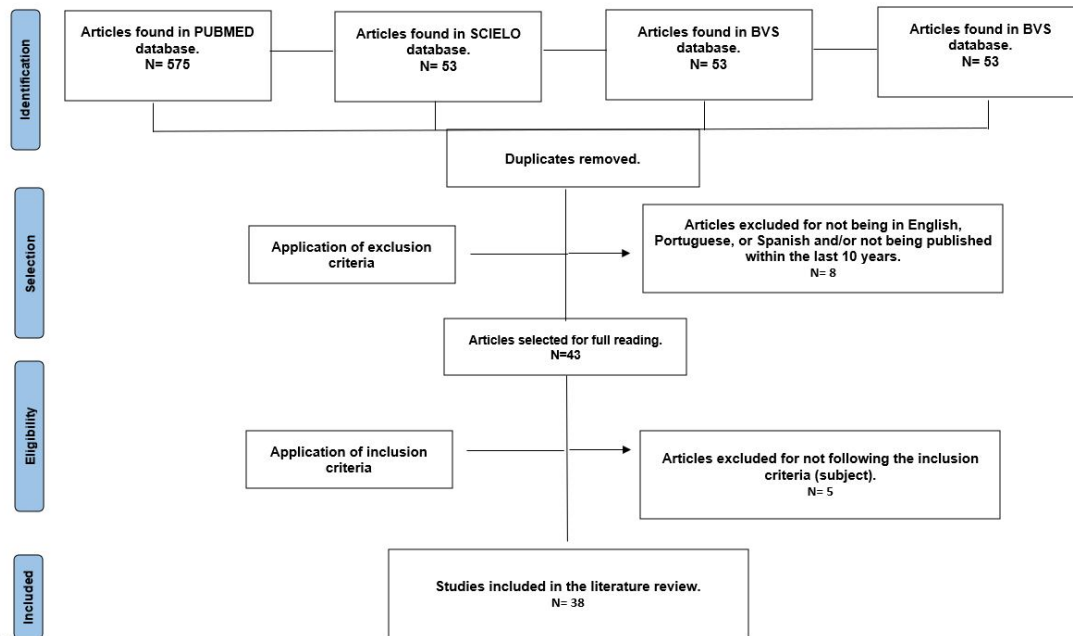
Inflammation of the pulp is a healing response that reveals the tooth's repair capacity, while pulp death is pulp necrosis. This can result in damage to the supporting periodontal tissues, which can become infected through the dentinal tubules. There is evidence that pulp necrosis is common among teeth that have been damaged by trauma (RIBEIRO et al., 2022) [2]. In these cases, the first treatment option is conventional endodontic treatment. However, sometimes this treatment alone is not capable of healing the periapical damage caused.

Periapical surgery is the treatment option for cases where conventional endodontic treatment has failed with persistent apical periodontitis, especially when non-surgical retreatment was not possible or successful. The goal of endodontic microsurgery is to locate the root apex, resect the apical 3 mm, prepare the root end, and fill it with a biocompatible material with excellent sealing ability. One of the main benefits of this modern surgical technique is the use of magnification devices, such as dental surgical microscopes. Surgical microscopes allow for microsurgical interventions with easy identification of the root apices, resulting in smaller ostectomies and shallower resection angles, thus ensuring the maintenance of the surrounding bone and the preservation of root length and dental structures (KIM et al., 2006) [3].

The present study aims to conduct a literature review on the effectiveness of using 3D guides and electronic microscopes in periapical surgeries, comparing conventional surgical techniques with those that utilize digital dentistry resources.

## **2. METHODOLOGY**

For this study, the searches were performed on platforms such as 'Pubmed', 'Plataforma CAPES', 'Scielo', and 'BVS saúde'. The terms 'Periapical Surgery', 'Digital Dentistry', 'Digital Technology', 'Digital Periapical Surgery', 'Surgical Guide', 'Modern Endodontic Microsurgery', 'Guided Root', 'Guided Endodontic Surgery', and '3D Guide' were used. A total of 711 articles were located. After removing duplicates and reviewing titles and abstracts, articles were selected based on the presence of keyword correlations in the text development and/or addressing periapical surgery performed with technological methods (guides and/or electronic microscopy). Articles written in English, Portuguese, or Spanish, published within the last 10 years, and other articles that were cited on the previously selected works and considered important were included. In the end, 38 articles were selected for literature review.



**Flowchart 1. PRISM Flow Diagram according to selection criteria.**

Source: self-authorship.

### 3. LITERATURE REVIEW

#### 3.1 Concepts related to digital dentistry

##### 3.1.1 Dental Digital Workflow

Digital workflow in dentistry has been increasing in recent years due to advances in technologies such as intraoral scanners and software programs, which have contributed to improving communication between clinicians and other professionals [4].

##### 3.1.2 Intraoral scanning

Intraoral scanning is a technique for digitizing real objects using images generated by capturing light reflection or through contact. There are intraoral scanners as well as benchtop scanners. Once the images are acquired through scanning, they are imported into planning software where they are manipulated. In these programs, the images or virtual gypsum model are processed to obtain the desired piece [5].

##### 3.1.3 Cone Beam Computed Tomography (CBCT)

Cone Beam Computed Tomography (CBCT) is a three-dimensional imaging technique that uses digital technology to capture detailed images of the maxillofacial region and the jaw [6]. Unlike conventional tomography, dental CBCT provides high-resolution 3D images, allowing for more precise visualization of dental structures, maxillary bones, temporomandibular joints, and surrounding tissues. The development of computed tomography (CT) in 1972, reported in 1973, enabled conditions to be diagnosed with 3D images. These devices have been used in various fields, and their use in dentistry became more common with the advent of implant surgery. Although CT devices are becoming more compact, they still tend to be

relatively large, expensive, and expose patients to relatively high doses of radiation. As a result, Arai et al. (1999) decided to develop a compact CT device specifically for dental use [6]

CBCT (Cone Beam Computed Tomography) uses an extraoral imaging scanner specifically designed for head and neck imaging, producing 3D images of the maxillofacial skeleton. It involves a unit that can be comparable in size to a conventional panoramic radiographic machine. Cone beam machines use X-rays in the form of a large cone that covers the surface of the head being examined. Instead of a linear array of detectors like in conventional CT, a two-dimensional planar detector (2D) is used. Because the cone beam irradiates a large volume area rather than a thin slice, the machine doesn't need to rotate as many times as traditional CT. It rotates only once, providing all the necessary information to reconstruct the Region of Interest (ROI) [7]

Tomography in dentistry is often integrated into the CAD/CAM (Computer-Aided Design/Computer-Aided Manufacturing) system to optimize dental procedures.

#### **3.1.4 CAD-CAM system**

The CAD-CAM system, according to the terminology, means CAD: Computer-Aided Design and CAM: Computer-Aided Manufacturing [5].

The CAM process, or computer-aided manufacturing, is essentially the materialization or fabrication of the virtual image manipulated in CAD software. Since Computer Numeric Control (CNC) machines were developed, the CAM process has also evolved. CNC machines or lathes controlled by computers perform machining operations with high precision based on a specific code. This code allows simultaneous control of multiple axes for cutting or shaping raw material. Therefore, the shape and details of the cut or machining are respected and controlled in an automated manner [5].

CAM machining can be classified as: (1) industrial; (2) in lab or laboratory; and (3) clinical. In lab and clinical lathes are typically smaller, lighter, and more cost-effective for the dental community in general. Industrial lathes, on the other hand, are larger, more expensive, and are usually acquired by companies or large enterprises that operate machining centers. The clinical process is the newest among the three and can involve all procedures (scanning, "virtual wax-up," and in lab machining) or only parts of them, such as when intraoral scanners send images to companies via communication networks (internet). Among these, the clinical process demands the largest initial investment by the dentist and likely involves forming a multidisciplinary team [5].

#### **3.1.5 3D printing**

There are several forms of 3D printing, including stereolithography (SLA), where a UV laser beam solidifies liquid material deposited in a movable vat to form layers; 3D printing, which involves depositing powder on a movable surface and jetting a fluid that agglomerates the powder to form the layers; and selective laser sintering (SLS), which selectively melts powder to create layers [8].

#### **3.1.6 Fabrication of guides**

The acquisition of surgical guides by CAD/CAM requires three-dimensional tomographic scanning and computer programs that assist in diagnosis and planning [9]. Obtaining images using this technology allows for a rehearsal of all procedures, ideally projecting and virtually

positioning correctly. These images are manipulated in a specific program, enabling the creation of a highly precise surgical guide [10].

Once the tomography data and planning have been completed, the surgical guide can be manufactured using various types of 3D printers or milling machines [9], providing the professional with a precise replica of the internal structures on which they will operate [10].

### **3.1.7 Dynamic navigation**

The 3D Dynamic Navigation System (3D-DNS) guides the dentist through real-time computer images, akin to satellite-guided navigation. This new technology offers greater precision and safety in minimally invasive procedures. Information is generated from cone beam computed tomography (CBCT) images of the patient, including virtually planned surgery images. Optical motion-tracking cameras (sensors) also detect the position of the contra-angle handpiece [12 e 13].

Initially, this technology was applied in implant dentistry starting from 2003, and there has been a significant increase in studies regarding its use in guided endodontics. It has been primarily applied in the localization of calcified canals, access cavity preparation, periapical surgery, endodontic retreatment, and intraosseous anesthesia [11].

In the case of periapical surgery, the precision of the 3D-DNS system has been compared to that of surgery performed freehand, demonstrating superior performance in apex localization and minimally invasive osteotomy [13].

### **3.1.8 Operate microscopy**

The use of the operative microscope (OM) in Dentistry was first proposed by Baumann in 1977, primarily due to its illumination that allows clearer visualization of oral cavity structures. Its application in Endodontics was subsequently introduced by Gary Carr [14].

The OM provides illumination and enhanced visualization of the operative field through light and high magnification. This tool assists in locating calcified canals, detecting microfractures, identifying isthmuses, observing internal aspects and complexities of the root canal system, removing fractured instruments, and accessing the coronal portion. Another advantage of its use is that it allows the surgeon to maintain an upright position, improving ergonomic comfort [14 e 15].

Furthermore, the benefits of magnification can be observed in both conventional endodontics and periapical surgeries. The advantages of using the microscope in surgeries include easier identification of the apex, smaller osteotomies, and visualization of isthmuses, microfractures, and lateral canals [16]. Therefore, it ensures higher success rates, greater safety, precision, and comfort for the patient [14].

## **3.2 Parendodontic Surgery**

### **3.2.1 Endodontic pathology**

Endodontic pathology originates from inflammation and is closely linked to microbial contamination of the root canals. The complexity of dental anatomy can exacerbate and further complicate this pathology. The dental pulp is in close proximity to the periodontium, whether through the presence of the apical foramen, lateral canals, accessory canals, apical deltas, inter-radicular canal, or due to root perforations. Endodontic infection arises from pulp

necrosis combined with decreased host defenses or following pulp removal during endodontic treatment. Bacteria are the primary etiological factor in this dental infection. Periradicular tissue inflammation develops due to the effects of bacterial products, and its progression is influenced by host factors and the bacterial population [17].

### **3.2.2 Indication for periradicular surgery**

In situations where failure of endodontic therapy is identified, retreatment of the root canal can be considered. However, in cases where retreatment is not feasible, periradicular surgery, also known as surgical endodontics, is an excellent alternative to resolve problems not addressed by conventional treatments. It is indicated when access to the root canal system is difficult due to calcified canals, canals obstructed by fractured instruments, cases of extruded obturation material, failure of conventional treatment, inability to retreat, apical perforations, or in teeth with cores or fixed prostheses [18].

Surgical exposure of the apex facilitates the biomechanics of the root canal, as well as eliminates concerns about potential extrusion of septic material. Additionally, it allows for more efficient obturation with vigorous condensation, aiming to reach lateral and/or secondary canals without the worry of obturation material extrusion. These reasons justify the recommendation for periradicular surgery [19].

### **3.2.3 Conventional periradicular surgery**

Surgeries in the periapical region receive names that differentiate them based on the desired outcomes of their results. Apical curettage, apicoectomy, and retrograde obturation are perhaps the most frequently mentioned [20].

Periradicular curettage involves the removal of pathological tissue or foreign bodies (extruded obturation material and instrument fragments) from the apical area that disrupts healing. The technique of root apex resection consists of making a cut to eliminate apical deltas, inaccessible segments of the canal, and areas of cemental resorption. This reduces apical morphological variations and iatrogenic effects from endodontic treatment, while providing better visualization of the surgical field and apical pathological processes. The extent of apicoectomy may vary depending on anatomical changes in the root canals, typically ranging from 2 to 4 mm, which aims to eliminate any dentin contaminated with debris or bacteria in the region. The apical resection should be sufficient to provide a larger surface area and expose lateral canals, typically involving half to one-third of the root [20].

The apical cut should be perpendicular to the long axis of the tooth, exposing a smaller number of dentinal tubules. In retrograde obturation, a cavity is prepared at the root apex and filled. It is indicated in cases involving inaccessible canals, prostheses and posts, perforations, fractured instruments, and dens invaginatus. This procedure can be performed using rotary instruments or ultrasonic tips. The retrofilling material should hermetically seal the sectioned apex and trap any remaining irritants within the root canal system, promoting apical cementogenesis repair [21].

Currently, materials such as IRM, Super EBA, and MTA are commonly used for this purpose. This sealing process confines any potential microorganisms within the root canal, thereby preventing aggression to periapical tissues and promoting repair. Therefore, any biocompatible retrofilling material that meets the physical sealing requirements at the apex can be utilized [20].

### **3.2.4 Limitations of conventional periradicular surgery**

The limitations and disadvantages of conventional periradicular surgery have become apparent due to rapid technological advancements. Firstly, approaching the root apex from the coronal direction of the root end inevitably increases damage and risk to non-pathological bone tissues. Secondly, conventional radiography provides only two-dimensional images that do not accurately depict the lesion area with precision and distinction. Thirdly, it is challenging for inexperienced dentists to balance minimizing damage to bone tissues while gaining access for root resection and root obturation [22].

### **3.2.5 New technologies applied to digital periradicular surgery**

In dentistry, 3D printing technology has been used for treatment planning, surgical guidance, and manufacturing dental models for orthognathic surgery, implant surgery, oral and maxillofacial surgery, orthodontics, and dental prosthetics. The high precision and extended flexibility of this technology make it highly promising. In endodontics, 3D printing has also gained wide application. Based on CBCT technology, CAD, and 3D printing, issues encountered with conventional techniques can be addressed. This arsenal constitutes what is referred to as digital periradicular surgery [22].

Therefore, it is necessary to expand the concepts and deepen the subject. Hence, there is a demand for a review of the studies already present in the current literature to identify established concepts and existing gaps in knowledge.

Thus, this literature review presents the following table regarding the included articles. It describes the authors, year of publication, study type, objectives, and the results or conclusions of each study. The inclusion criteria were described in the methodology discussed earlier. Articles were organized chronologically, and those published in the same year were sorted alphabetically by the initial of the author's surname.

**Table 1: Analysis of the articles included in the literature review**

<b>Author, year of publication</b>	<b>Type of study</b>	<b>Aim</b>	<b>Result/conclusion</b>
LIETZAU et al., 2013 [23]	Retrospective clinical study.	Examining the effectiveness of an Er:YAG laser used in conjunction with a surgical microscope for apicectomy, compared to the traditional surgical microscope procedure.	Post-operative healing was positively affected by the use of the Er:YAG laser, with additional control using a surgical microscope, compared to conventional apicectomy.

TESIS et al., 2013 [16]	Meta-analysis.	To evaluate, by means of a systematic review and meta-analysis results of modern endodontic surgery, as well as evaluate the factors that influence its results.	A success rate of success rate of 89.0% after more than 1 year of follow-up. It was also it was also defined that the type of material and the use of augmentation devices can affect the outcome. However, prospective clinical large-scale prospective clinical studies are still needed to determine possible success and failure factors.
LUI et al., 2014 [24]	Retrospective study.	To evaluate the outcome of endodontic microsurgery and examine prognostic factors related to healing.	The use of modern techniques in endodontic microsurgery achieved a cure rate and process of 78.5% in a period of 1 to 2 years after the procedure. There was greater treatment success among female public males. Regarding the position of the teeth, anterior maxilla were more successful than the anterior teeth of the mandible. Finally, probing depths less than or equal to 3 mm were associated with greater success.
STRBAC et al., 2017 [25]	Case report.	New technique in surgery using a guided osteotomy and root resection.	It is a viable technique that allows osteotomies and pre-defined root resections.
AHN, S.Y. et al., 2017 [26]	Case report.	Present a method that involves the application of a surgical procedure to guide the osteotomy and facilitate precise localization of the apex in a case involving thick buccal bone plate.	Introducing a CAD/CAM method in endodontic surgery helps minimize the extent of the osteotomy and facilitates the localization of the root apex in cases with thickness and intact buccal intact bone plate. The surgical template would be useful in surgery on teeth with problematic anatomical structures.
HERNÁNDEZ VIGUERAS, et al., 2017 [27]	Clinical study.	Evaluate and describe the image characteristics found in a group of patients referred for periapical surgery, using CBCT ( Cone Beam Computed Tomography).	The use of CBCT should be considered as a complement to conventional periapical radiographs. Its capability to display geometrically accurate three-dimensional images, elimination of adjacent anatomical noise, comparable sensitivity, and effective dose confer significant advantages for the diagnosis, assessment, and surgical planning of

			periapical lesions.
ANDERSON; WEALLEANS; RAY, 2018 [28]	Literature review.	Review the current applications of 3D printing in endodontics and speculate on future directions for research and clinical use in the specialty.	A literatura é limitada quanto a impressão 3D em endodontia, sendo resumida a relatos de casos e estudos pré-clínicos. Aplicações endodônticas para EMS guiado por stent, prototipagem rápida de dentes anômalos, autotransplante da tecnologia de impressão 3D em endodontia será possível à medida que mais pesquisas forem desenvolvidas. Aquisição de técnica e experiência dentro da endodontia é um obstáculo à implantação generalizada da tecnologia. Com os avanços, programas de pós-graduação em endodontia devem considerar a implementação da impressão 3D como parte de seu currículo. Maior expertise dentro da especialidade abrirá caminho para um conjunto de evidências mais robustas.
YE et al., 2018 [22]	Case report.	Presenting a new treatment approach for removing cortical bone and root apex during periapical surgery with the assistance of cone beam computed tomography (CBCT), computer-aided design (CAD), and three-dimensional (3D) printing technology.	The digitally designed directional model effectively facilitated periapical surgery as anticipated. Root ends were accurately located and excised. The surgical procedure was simplified, and treatment efficiency was improved. This technique minimized damage and reduced iatrogenic injuries.
ACKERMAN et al., 2019 [29]	Ex vivo study.	Explore the accuracy of access in endodontic surgeries using 3D-printed surgical guides designed from cone beam computed tomography compared to "freehand" approximate access performed on cadavers.	Surgeries with guides allow for more precise surgical access compared to the freehand method.
ANTAL et al., 2019 [30]	Case series.	Justify the clinical safety and precision of guided trephine root resection.	Studies support the use of guided trephination for root resection. However, research is in its early stages, leaving ample room for improvements in both the method and its assessment.
FAN et al., 2019 [31]	Ex vivo study.	Introduce a new method using cone beam computed tomography and prefabricated grids to guide apical access and compare	The method proposed in the article was more accurate than the unguided method. Further research on prefabricated grids is necessary to explore their applicability.

		its accuracy with the unguided method.	
GARCIA-SANCHEZ et al.,2019 [32]	Case report.	Illustrate the accuracy of a digitally planned 3D-printed guide for an apicoectomy procedure.	The authors did not present any conclusions in the paper.
KIM; SHIM; SHIN, 2019 [33]	Case report.	Presenting a case of endodontic microsurgery using a guide model to direct apex positioning for the treatment of an anterior tooth with calcified canals. This tooth was untreatable with conventional therapy, and the apex position could not be traced due to the absence of a fistula.	This method of endodontic microsurgery using a guide model can be beneficial in calcified canals.
POPOWICZ et al.,2019 [34]	Case report.	Describing root canal surgery with the use of DDSPro implant planning software (Natrodent Polska, Poland), a 3D printed surgical guide positioned accurately according to preoperative measurements from Computed Tomography, and a modified access to soft tissues, with the assistance of autogenous bone grafting.	The cases presented show potential for targeted endodontic microsurgery not only in execution, but also in achieving positive outcomes within a short follow-up period. The preservation of the cortical plate for use as an autogenous graft was an additional advantage of the technique.
ANTAL et al., 2020 [35]	Case report.	Transferring the precision of computer-assisted static guided dental implant placement to root resection using a custom trephine, drills manufactured specifically for use in targeted endodontic microsurgery.	Digitally guided endodontic surgery with a trephine appears to be an easily performed operation, a safe and uncomplicated method that allows for the resection and removal of the root apex in a single step. The approach itself is a step toward a standardized digital system and workflow dedicated to guided endodontic surgery.
GEORGE et al., 2020 [36]	Case report.	It presents a relatively easy method for manufacturing a surgical guide and demonstrates the benefits of a planned surgical guide in managing a periapical pathology near the mental	The high degree of precision that this technique offers means that it would be best utilized for cases where an osteotomy is essential to access the pathology, particularly when vital structures are in close proximity to the planned osteotomy and root resection procedures.

		nerve canal.	
HAWKINS et al., 2020 [37]	Surgical simulation comparison.	Comparison of surgical time, bevel angle, and volumetric profiles of the osteotomy and resection site performed by targeted endodontic microsurgery (TEMS) and traditional endodontic microsurgery in a surgical simulation model.	The methodology shows promise for future endodontic experiments. TEMS (targeted endodontic microsurgery) allowed certified endodontists to initiate surgery with less clinical evaluation time and conclude the osteotomy and root resection more efficiently, achieving more appropriate root resection volume and bevel angle.
KIM; KIM; KIM, 2020 [38]	Case report.	Describing the applications of computer-guided cortical bone window technique using piezoelectric saws that prevent any nerve damage during the performance of microsurgical endodontics on a lower molar.	Using a CAD/CAM-guided surgical splint and the bone window technique in endodontic surgery prevents the formation of large residual bone defects after microsurgery. The repositioned cortical bone obtained from the window can act as an autogenous bone graft, promoting early healing. Additionally, the introduction of a CAD/CAM-guided surgical splint and piezoelectric saws allows the surgeon to perform the surgery as planned safely, with less trauma and convenience.
PENG et al., 2021 [39]	In vitro study.	Evaluate the precision of digital endodontic surgical guide operation.	The application of the digital guide can improve the precision of root resection.
RAY et al., 2020 [40]	Case report.	Describing the considerations and guiding principles of the digital workflow for guided endodontic microsurgery.	If anatomical structures are accurately reproduced in digital format, the resulting files can generate a 3D model that serves as a design basis for a useful surgical guide.
TAVARES et al., 2020 [41]	Case report.	Here's a presentation on 3D-guided apicoectomy, a new method for performing ultraconservative guided endodontic surgery with conventional guided implant drills, describing its application in a case with complex anatomical features and close proximity to the maxillary sinus.	The method presented has proven to be very simple, reproducible, and reliable. Its applicability can be extended to other anatomically complex conditions and multiple cases of endodontic surgery. The reproducibility of the technique allows for the preservation of teeth indicated for endodontic surgery when anatomy poses a challenge.
BUNIAG; PRATT; RAY, 2021 [42]	Retrospective study.	Evaluate outcomes of guided endodontic microsurgery at least 1 year post-treatment.	These results are an early indication that guided endodontic microsurgery (TEMS) using root resection tips with guided trephine drill shows successful outcomes, presenting similar success rates to those found in resections using freehand

			diamond and carbide drills.
LANGALIYA et al., 2021 [43]	Case report.	Introducing a new guided microsurgical technique in endodontics with the assistance of 3D-printed surgical splints.	Guided osteotomy, apex localization, and root resection were performed for retrograde retrieval of separated instrument fragments, following the principles of modern endodontic surgery. Guided surgery shows promise.
NAGY et al., 2022 [44]	In vitro study.	To determine if there is an inherent tendency for excessive penetration in apicoectomy with a trephine and to test if the addition of a stop could effectively prevent excessive penetration and improve the precision rate of trephine apicoectomy.	The lack of depth control is a significant source of error when guided apicoectomy is performed with a conventional trephine. The use of a customized product with a stop has proven effective in reducing this error to a safe and acceptable level. With adequate depth control, the precision of apicoectomy was comparable to guided implant surgery. However, this surgical approach is novel, and further testing is needed before definitive conclusions can be drawn. Additionally, other safety issues such as intraosseous heat generation during these interventions also require further clarification. The results indicate that customized trephines with an integrated stop provide an ideal solution to the problem of excessive penetration.
ANTAL, 2022 [45]	Literature review.	Summarize the evolution of static guided periapical surgery, presenting its challenges and technical solutions.	The author does not provide any conclusion in the article.
CHAVES et al., 2022 [1]	Case report.	Present a new workflow possibility where apical surgery on lower molars with thick buccal bone plate is performed using a surgical guide planned solely with Cone Beam Computed Tomography (CBCT), eliminating the need for 3D intraoral scanning.	Current 3D-printed guides can be planned and printed for periapical surgeries on lower molars through a simplified workflow using only CBCT (Cone Beam Computed Tomography).
FU et al., 2022 [46]	Case series.	Present a new approach to dynamic navigation-assisted endodontic microsurgery and describe its application in posterior teeth.	Dynamic navigation has proven to be a viable, predictable, and time-saving system to assist in endodontic microsurgery concerning issues in molar areas. With the system's assistance, surgeons can minimize the extent of osteotomy and easily locate root apices in cases involving anatomically challenging areas in posterior teeth. Moreover, surgical time is notably reduced by decreasing the time needed to locate root apices, while preliminary work can be enhanced through pre-operative design and calibration.

HAN et al., 2022 [47]	Randomized controlled trial (RCT).	Compare and evaluate the clinical effects of the Dynamic Navigation System technique compared to the freehand technique in cases of endodontic microsurgery with labial lesions/buccal cortical bone.	It will end in June 2024.
REDDY et al., 2022 [48]	Case report.	Present two case reports that elucidate the application of 3D surgical guides using cone beam computed tomography (CBCT) alongside microsurgery.	Guided endodontic microsurgery produced a localized osteotomy with predictable angulation and diameter, proving to be more precise and minimally invasive than conventional surgery. Guided endodontic microsurgery represents a viable alternative to advancing technological and clinical expertise in the field of endodontics.
SETZER; KRATCHMAN, 2022 [49]	Literature Review.	Focus on the current landscape, comparing materials and techniques used in endodontic microsurgery today with those more widely used in the past.	Endodontic surgery has a considerable history and is evolving with improvements in both research development and clinical applications. The current landscape of endodontic microsurgeries has demonstrated successful short- and long-term results. The technical arsenal and materials available to clinicians have allowed it to become a more standardized technique for specialized professionals
CABEZON et al., 2023 [50]	Ex vivo study.	To evaluate the accuracy of new 3D-printed open-structure metal surgical guides compared to virtual planning in an ex vivo endodontic surgical simulation using a pig mandible.	This proof-of-concept study demonstrates its feasibility in an ex vivo model and suggests the potential for 3D-printed metal surgical guides to be used in endodontic microsurgeries.
IQBAL et al., 2023 [51]	Narrative Review.	To define and characterize guided endodontic surgery, as well as its advantages and disadvantages.	Surgically guided endodontics is a relatively new and still maturing area of study. It has many applications, such as access and location of root canals, micro-endodontic surgery, endodontic retreatment, and removal of fiberglass posts. Additionally, regardless of the operator's experience, the procedure can be completed in less time and provides greater precision and safety than conventional endodontics.
KISCSATARI et al., 2023 [52]	In Vitro study.	To evaluate the accuracy of osteotomy and apicoectomy performed using a polymeric guide, both with a drill and a trephine, and to compare the accuracy achieved with the two instruments.	Guided microsurgery provides a level of precision considered clinically acceptable, regardless of the instrument used. However, validation through additional and potentially clinical investigations is warranted.

MAHENDRAN et al., 2023 [53]	Case series.	Introducing a new endodontic surgical technique using a 3D-printed surgical guide for guided osteotomy and root resection.	3D-printed surgical models were used to assess more accurately the size, extent of the lesion, and adjacent structures. Thus, it can be concluded that the application of 3D printing in surgical endodontics is highly beneficial, presenting promising scope compared to traditional approaches.
MARTINHO et al., 2023 [54]	Ex vivo study.	Compare the accuracy, efficiency, and feasibility of static systems and dynamic techniques in computer-assisted surgical navigation for osteotomy and root apical resections.	Within the limitations of this study conducted on cadavers, completely static computer-assisted guided endodontic microsurgery was as accurate as dynamic computer-assisted endodontic microsurgery. Both were efficient in terms of the time required for osteotomy and apical resection.
SUDHA et al., 2023 [55]	Case report.	Present two clinical cases where cone beam computed tomography (CBCT)-guided surgery was used for retrieval of fractured instruments located beyond the limits of the root canals in a lower molar and an upper premolar.	The guided approach has proven advantageous over conventional management in cases of calcified canals, surgical endodontics, retrieval of separated instruments, and dental autotransplantation. Unlike the conventional approach, guided treatment is more conservative, precise, and time-efficient, with minimal risk of damage to surrounding tissues. In this case series, guided endodontic surgery was performed without the need for apicoectomy.
WESTBROOK et al., 2023 [56]	Comparative study.	Compare the accuracy and efficiency of a new computer-assisted static surgical technique using a 3D-printed surgical guide (3DSG) with a fully guided drilling protocol (3D-SG FG) to freehand osteotomy (FH) and root resection (RER)	The 3D-SG FG protocol demonstrated greater precision than FH osteotomy and RER. Additionally, the 3D-SG FG drilling protocol significantly reduced surgical time.
ZHAO et al., 2023 [57]	Clinical study.	Design a new three-dimensional (3D) printed surgical guide and evaluate its accuracy in assisting endodontic microsurgeries.	The newly designed 3D printed surgical guide could effectively assist in endodontic microsurgery and improve its accuracy by fixing the position and angle of apicoectomy.

Source: self-authorship

#### 4. RESULTS AND DISCUSSION

A challenge encountered in conventional endodontic surgery is directing the osteotomy to remove the desired section with the greatest possible precision, as it is performed freehand, depending on the manual skill of the dental surgeon and is based on a radiographic, thus two-dimensional, image to locate the root apex.

Recently, it has become possible to use CAD/CAM design and three-dimensional printing technology to create 3D printed models. These models have the potential to increase precision and accuracy, reduce intraoperative time, as well as postoperative complications, which are not achieved when conventional surgery is adopted [53].

Thus, the constant evolution of digital means and the emergence of new techniques and applications in different areas of Dentistry are undeniable. Periapical surgeries have also benefited from this advancement, as according to Ye et al. (2018), the digitally designed directional model worked in all aspects to facilitate periapical surgery, allowing root ends to be located and resected with greater precision. Therefore, in the near future, conventional techniques will not be as recommended as those using these new technologies, as they increase the predictability and success of the treatment. [22]

In light of this, this work aims to contribute to the understanding of the complexities and challenges inherent in the digital age associated with endodontic surgeries. After reviewing and analyzing the articles included in the study, it is evident that there is agreement among the authors that the use of new technologies in endodontics (3D guides and microscopy) has been positive and has brought greater precision and safety in both the short and long term. Another point of consensus was the need to further explore studies in order to implement these technologies more widely in endodontics, as these tools are still evolving and have not yet been fully consolidated in the literature.

Regarding the success rates of modern techniques in endodontic microsurgery, which involve the use of surgical operating microscopes combined with ultrasonic tips, only two of the analyzed articles included this data. In the studies by Lui et al. (2014), a healing rate of 78.5% was determined within a period of 1 to 2 years after the procedure [24]. Meanwhile, Tsesis et al. (2013) found a success rate of 89.0% after more than 1 year of follow-up [16]. These findings confirm the benefit of using new technologies in endodontic surgery.

In this context of technological advancement, it is crucial to explore the pros and cons associated with these innovations. Therefore, some advantages of using three-dimensional guides and surgical microscopes are highlighted, such as increased precision and safety during the surgical act of root apex resection [29]. The procedure is considered minimally invasive, promoting reduced iatrogenic injuries [48, 22], requiring less manual dexterity from the surgeon, and providing greater predictability in treatments. Surgical time is also reduced [35,37]. Additionally, according to Kim; Kim; Kim (2020), surgery becomes less traumatic, avoiding the formation of large bone defects and preserving vital structures near ostectomy and root resection procedures, with the potential to preserve the cortical plate for use as an autogenous graft [38]. It also allows for more accurate evaluation of the size, extent of the lesion, and adjacent structures [34, 36, 53].

However, it is crucial to analyze with discernment the limitations and adverse implications of these resources. Among these disadvantages, the need for a technological arsenal for planning and fabrication of the guides stands out [49], requiring training of the dentist for handling the equipment used [28], and preliminary work may be increased concerning pre-operative design and calibration [46].

Considering these considerations, the relevance of the topic transcends mere intellectual curiosity, extending to gaps in current scientific knowledge. The scarcity of studies dedicated to this topic, as discussed by Anderson; Wealleans; Ray (2018), highlights the urgent need to explore this still relatively uncharted field [28].

## 5. CONCLUSION

Currently, digital workflow in dentistry has advanced treatments, bringing more precision and safety to procedures. The use of various 3D guides was initially applied to implantology but has increasingly found application in endodontics. This technology can be applied to both access to the pulp chamber and surgical endodontics, proving beneficial in both cases. When considering its use in periradicular surgery, a considerable success rate is observed, along with reduced iatrogenic incidents and less traumatic surgery compared to freehand (conventional) endodontic surgery.

Another tool that has gained prominence in endodontics is the surgical operating microscope, which allows for better visualization, illumination, and magnification of the treatment area. The microscope can also be used in periradicular surgeries, enabling the dentist to more effectively visualize their operative field, leading to greater precision and treatment success.

Considering the advantages and limitations related to the use of new technologies in periradicular surgery found in this literature review, as well as the scarcity of broader reviews and studies on the subject, it is clear that there is a need to expand knowledge to define a technique that can be replicable by dentists. These are recent techniques still undergoing refinement.

---

### Consent

It is not applicable.

### Ethical approval

It is not applicable

### References

1. Chaves GS, Capeletti LR, Miguel JG, Loureiro MA, Silva EJNL, Decurcio DA. A novel simplified workflow for guided endodontic surgery in mandibular molars with a thick buccal bone plate: a case report. *J Endod.* 2022;48(7):930–935.
2. Ribeiro D, Reis E, Marques JA, Falacho RI, Palma PJ. Guided endodontics: static vs. dynamic computer-aided techniques - a literature review. *J Pers Med.* 2022;12(9):1516.
3. Kim S, Kratchman S. Modern endodontic surgery concepts and practice: a review. *J Endod.* 2006;32(7):601–623.
4. Stanley M, Paz AG, Miguel I, Coachman C. Fully digital workflow, integrating dental scan, smile design and CAD-CAM: case report. *BMC Oral Health.* 2018;18(1):134.
5. Bernardes SR, Tiozzi R, Lam S, Thomé G. CAD/CAM technology applied to dental prostheses and implants: what it is, how it works, advantages and limitations - a critical literature review. *J ILAPEO.* 2012;06(1):08-13.
6. Arai Y, Tammisalo E, Iwai K, Hashimoto K, Shinoda K. Development of a compact computed tomographic apparatus for dental use. *DentoMaxillo Facial Radiology [Internet].* 1999; 28(4):245–8.
7. Nasseh I, Al-Rawi W. Cone beam computed tomography. *Dent Clin North Am.* 2018;62(3):361-391.

8. Mion JA, Morgon F. The use of 3D printers as a tool in the production process of dental prostheses. 16a CONIC. Faculdade ENIAC; 2016.
9. Jaber M, Sarment DP. Advanced surgical guidance technology: a review. *Implant Dent*. 2006;15(2):135-141.
10. Widmann G, Widmann R, Widmann E, Jaschke W, Bale R. Use of a surgical navigation system for CT-guided template production. *Int J Oral Maxillofac Implants*. 2007;22(1):72-78.
11. Aldahmash SA, Price JB, Mostoufi B, Griffin IL, Dianat O, Tordik PA, Martinho FC. Real-time 3-dimensional dynamic navigation system in endodontic microsurgery: cadaver study. *J Endod*. 2022;48(7):922-929.
12. Kalaivani G, Balaji VR, Manikandan D, Rohini G. Expectation and reality of guided implant surgery protocol using computer-assisted static and dynamic navigation system at present scenario: evidence-based literature review. *J Indian Soc Periodontol*. 2020;24(5):398-398.
13. Wang Z, Chen C, Qin L, Li F, Chen Y, Meng L. Accuracy and efficiency of endodontic microsurgery assisted by dynamic navigation based on two different registration methods: an in vitro study. *J Endod*. 2023;49(9):1199-1206.
14. Feix LM, Bojink D, Ferreira R, Wagner MH, Barletta FBI. Operating microscope in endodontics: visual magnification and luminosity. *RSBO (Online)*. 2010;7(3):340-348.
15. Jadun S, Monaghan L, Darcey J. Endodontic microsurgery. Part two: armamentarium and technique. *Br Dent J*. 2019;227(2):101-111.
16. Tsesis I, Rosen E, Taschieri S, Strauss YT, Ceresoli V, Fabbro MD. Outcomes of surgical endodontic treatment performed by a modern technique: an updated meta-analysis of the literature. *J Endod*. 2013;39(3):332-339.
17. Pavelski MD, Portinho D, Casagrande-Neto A, Griza GL, Ribeiro RG. Paraendodontic surgery: case report. *RGO - Rev Gaúch Odontol*. 2016;64(4):460-466.
18. Moreti LCT, Nunes LR, Ogata M, Fernandes KGC, Boer NCP, Cruz MCC, et al. Paraendodontic surgery as an option for special cases: case story. *Arch Health Invest*. 2019;8(3):134-138.
19. Kuga MC, Okamoto T, Brito JRO, Junior PDR, Tanaka H. Clinical and radiographic evaluation of periapical surgery: comparison of surgical technique and control period. *Rev Assoc Paul Cir Dent*. 1997;51(2):136-140.
20. Nogueira FP, Novais HC, Nascimento VR, Nogueira DP, Pfau EA, Brunini SHS, Tomazinho LF. Cirurgia paraendodôntica: uma alternativa para o sucesso endodôntico. *Braz J Surg Clin Res*. 2019;29(1):49-55.
21. Leal JM, Bampa JU, Polissell AN. Cirurgias paraendodônticas: indicações, contra-indicações, modalidades cirúrgicas. In: Leonardo MR, editor. *Endodontia – tratamento de canais radiculares: princípios técnicos e biológicos*. São Paulo: Artes Médicas; 2005. p. 263-343.
22. Ye S, Zhao S, Wang W, Jiang Q, Yang X. A novel method for periapical microsurgery with the aid of 3D technology: a case report. *BMC Oral Health*. 2018;18(1):1-7.
23. Lietzau M, Smeets R, Hanken H, Heiland M, Apel C. Apicoectomy using Er: YAG laser in association with microscope: a comparative retrospective investigation. *Photomed Laser Surg*. 2013;31(3):110-115.
24. Lui JN, Khin MM, Krishnaswamy G, Chen NN. Prognostic factors relating to the outcome of endodontic microsurgery. *J Endod*. 2014;40(8):1071-1076.
25. Strbac GD, Schnappauf A, Giannis K, Moritz A, Ulm C. Guided Modern Endodontic Surgery: A Novel Approach for Guided Osteotomy and Root Resection. *J Endod*. 2017;43(3):496-501.
26. Ahn SY, Kim NH, Kim S, Karabucak B, Kim E. Computer-aided design/computer-aided manufacturing-guided endodontic surgery: guided osteotomy and apex localization in a mandibular molar with a thick buccal bone plate. *J Endod*. 2017;44(4):665-670.

27. Viguera SH, Zúñiga MD, Tobar CS, Olave JL, Carrasco SR. Evaluación de Lesiones Periapicales en Pacientes Derivados a Cirugía Periapical Mediante Tomografía Computarizada de Haz Cónico. *Int J Odontostomatol.* 2017;11(2):128–132.
28. Anderson J, Wealleans J, Ray J. Endodontic applications of 3D printing. *Int Endod J.* 2018;51(9):1005–1018.
29. Ackerman S, Aguilera FC, Buie JM, Glickman GN, Umorin M, Wang Q, Jalali P. Accuracy of 3-dimensional-printed Endodontic Surgical Guide: A Human Cadaver Study. *J Endod.* 2019;45(5):615–618.
30. Antal M, Nagy E, Braunitzer G, Fráter M, Piffkó J. Accuracy and clinical safety of guided root end resection with a trephine: a case series. *Head Face Med.* 2019;15(1):15–30.
31. Fan Y, Glickman GN, Umorin M, Nair MK, Jalali P. A Novel Prefabricated Grid for Guided Endodontic Microsurgery. *J Endod.* 2019;45(5):606–610.
32. Garcia-Sanchez A, Mainkar A, Ordonez E, Sanchez S, Weinstein G. 3D-printed guide for endodontic surgery. *Clin Dent Rev.* 2019;3(1):7-13.
33. Kim JE, Shim JS, Shin Y. A new minimally invasive guided endodontic microsurgery by cone beam computed tomography and 3-dimensional printing technology. *Restor Dent Endod.* 2019;44(3)
34. Popowicz W, Palatyńska-Ulatowska A, Kohli MR. Targeted Endodontic Microsurgery: Computed Tomography-based Guided Stent Approach with Platelet-rich Fibrin Graft: A Report of 2 Cases. *J Endod.* 2019;45(12):1535-1542.
35. Antal M, Nagy E, Sanyó L, Braunitzer G. Digitally planned root end surgery with static guide and custom trephine burs: A case report. *Int J Med Robot Comput Assist Surg.* 2020;16(4):2115.
36. George R, Cameron A, Meer M. Streamlining and simplification of surgical stent fabrication for micro-endodontic surgery. *Aust Endod J.* 2020;46(3):445–451.
37. Hawkins TK, Wealleans JA, Pratt AM, Ray JJ. Targeted endodontic microsurgery and endodontic microsurgery: a surgical simulation comparison. *Int Endod J.* 2020;53(5):715–722.
38. Kim U, Kim S, Kim E. The application of “bone window technique” using piezoelectric saws and a CAD/CAM-guided surgical stent in endodontic microsurgery on a mandibular molar case. *Restor Dent Endod.* 2020;45(3).
39. Peng L, Zhao J, Wang ZH, Sun YC, Liang YH. Accuracy of root-end resection using a digital guide in endodontic surgery: An in vitro study. *J Dent Sci.* 2021;16(1):45-50.
40. Ray JJ, Giacomino CM, Wealleans JA, Sheridan RR. Targeted Endodontic microsurgery: digital workflow options. *J Endod.* 2020 Jun; 46(6):863-871.
41. Tavares WLF, Fonseca FO, Maia LM, de Carvalho Machado V, França Alves Silva NR, Junior GM, Ribeiro Sobrinho AP. 3D Apicoectomy Guidance: Optimizing Access for Apicoectomies. *J Oral Maxillofac Surg.* 2020;78(3):357.e1-357.e8.
42. Buniag AG, Pratt AM, Ray JJ. Targeted Endodontic Microsurgery: A Retrospective Outcomes Assessment of 24 Cases. *J Endod.* 2021;47(5):762–769
43. Langaliya A, Chaudhari E, Patel A, Shah J. Computer-aided design-CAM-guided endodontic microsurgical localization and retrieval of two separated instruments from the periapical area of a mandibular second molar. *Endodontology.* 2021;33(2):112-117.
44. Nagy E, Braunitzer G, Grysckha DG, Barrak I, Antal MA. Accuracy of digitally planned, guided apicoectomy with a conventional trephine and a custom-made endodontic trephine: An in vitro comparative study. *J Stomatol Oral Maxillofac Surg.* 2022;123(4):388-394.
45. Antal MA. Evolution and the difficulties of static guided periapical surgery. *Clin Dent Rev.* 2022;6(1):5-14.
46. Fu W, Chen C, Bian Z, Meng L. Endodontic Microsurgery of Posterior Teeth with the Assistance of Dynamic Navigation Technology: A Report of Three Cases. *J Endod.* 2022;48(7):943–950

47. Han B, Wang Y, Zheng C, Peng L, Sun Y, Wang Z, Wang X. Evaluation of a dynamic navigation system for endodontic microsurgery: study protocol for a randomised controlled trial. *BMJ Open*. 2022;12(12)
48. Reddy S, Gadhiraaju S, Quraishi A, Kamishetty S. Targeted endodontic microsurgery: a guided approach - a report of two cases. *Contemp Clin Dent*. 2022;13(3):280-283.
49. Setzer FC, Kratchman SI. Present status and future directions: Surgical endodontics. *Int Endod J*. 2022;55(4):1020-1058
50. Cabezon C, Aubeux D, Pérez F, Gaudin A. 3D-Printed Metal Surgical Guide for Endodontic Microsurgery (a Proof of Concept). *Appl Sci*. 2023;13(2):1031
51. Iqbal A, Sharari TA, Khattak O, Chaudhry FA, Bader AK, Saleem MM, Issrani R, Almaktoom IT, Albalawi RFH, Alserhani EDM. Guided Endodontic Surgery: A Narrative Review. *Medicina (Kaunas)*. 2023;59(4):678.
52. Kiscsatári R, Nagy E, Szabó M, Braunitzer G, Piffkó J, Fráter M, Antal MA. Comparison of the Three-Dimensional Accuracy of Guided Apicoectomy Performed with a Drill or a Trephine: An In Vitro Study. *Appl Sci*. 2023;13(17):9642-9642
53. Mahendran K, Mohamed Hussain MA, Maloor SA, Saminathan K. Guided endodontic surgery - Case series. *Indian J Dent Res*. 2023;34(1):94-97
54. Martinho FC, Rollor C, Westbrook K, Aldahmash SA, Fay GG, Rivera E, Parsa A, Price JB, Tordik PA. A Cadaver-based Comparison of Sleeve-guided Implant-drill and Dynamic Navigation Osteotomy and Root-end Resections. *J Endod*. 2023;49(8):1004-1011.4
55. Sudha A, Krishnan A, Samant PS, Dubey S. Guidodontics: A global positioning system (GPS) to surgical Endodontics – A case series. *J Conserv Dent*. 2023;26(2):241-245.
56. Westbrook K, Rollor C, Aldahmash SA, Fay GG, Rivera E, Price JB, Griffin I, Tordik PA, Martinho FC. Comparison of a Novel Static Computer-aided Surgical and Freehand Techniques for Osteotomy and Root-end Resection. *J Endod*. 2023;49(5):528-535.
57. Zhao D, Xie W, Li T, Wang A, Wu L, Kang W, Wang L, Guo S, Tang X, Xie S. New-designed 3D printed surgical guide promotes the accuracy of endodontic microsurgery: a study of 14 upper anterior teeth. *Scientific Reports*, v. 13, n. 1, 2023