

REPRODUCTIVE OUTCOMES IN TWO NIGERIAN WOMEN WITH SEPTATE UTERUS: CASE SERIES AND LITERATURE REVIEW.

Abstract

Uterine factor infertility occurs either from a congenital absence of the uterus or a non-functioning uterus from natural or acquired causes or from congenital anomalies affecting any part of the uterus. There is strong positive correlation between septate uterus and adverse pregnancy outcomes. This case series focuses on successful pregnancy and live birth following two incidental cases of non-diagnosed uterine septum managed successfully in a resource limited setting.

Keywords: Symptomatic uterine septum, live birth, congenital uterine anomalies, miscarriage, 3-Dimensional ultrasonography.

UNDER PEER REVIEW

Introduction

Mullerian duct anomalies are seen in 5.5% of the unselected population, in 8% amongst infertile women, and in 13.3% of those with miscarriages.^{1, 2}

There have been several attempts to classify these uterine anomalies in literature. However, the most accepted classification system universally is the one by the American Society for Reproductive Medicine's (ASRM) which uses a descriptive terminology to classify these anomalies (as "Mullerian agenesis, cervical agenesis, unicornuate uterus, uterus didelphys, bicornuate uterus, septate uterus, longitudinal vaginal septum, transverse vaginal septum, and other complex anomalies").³ Other classification systems are the ones by the European Society of Human Reproduction and Embryology (ESHRE), Acien's classification and Congenital Uterine Malformation by Experts.

Septate uterus is the commonest Müllerian anomalies.^{3, 4} It has been implicated in uterine factor infertility, severe dysmenorrhoea, recurrent miscarriages and preterm delivery.⁵

Septate uterus can be diagnosed using hysterosalpingography or two-dimensional (2D) ultrasonography, with three-dimensional (3D) ultrasonography and or magnetic resonance Imaging (MRI).^{3, 4} It is very amenable to surgical correction either by using hysteroscopic metroplasty which is viewed as gold standards by many fertility gynaecologists or by laparoscopic or open transmyometrial repair. Other less popular mode of repair which is not currently advocated because of high risk of uterine rupture associated with it or other maternal morbidities includes Jones metroplasty and Tompkins metroplasty which involves abdominal transfundal repair.^{5, 6} The low morbidity and simplicity of hysteroscopic metroplasty favours liberal intervention in women with septate uterus prior to assisted reproductive treatment (ART), or to prevent miscarriages and complications during labour^{3, 6}

However, notwithstanding the success associated with hysteroscopic metroplasty and pregnancy outcome, there is varied opinion in literature on whether surgery improves live birth rate.⁶

While some authors found significance evidence on the use of metroplasty and improved live birth rate, others argued that other maternal clinical and demographic variables such as age, body mass index, medical comorbidities and reproductive history and non-uniformity on the indications for surgery may have been co-founders affecting fertility and pregnancy outcomes.

With the foregoing it is therefore imperative that the treatment of septate uterus is individualized. We therefore present two cases of septate uterus diagnosed incidentally in pregnancy and managed successfully.

UNDER PEER REVIEW

Case 1:

A 26-yr old nulliparous lady with history of recurrent miscarriage. She was yet to see her menses after the third miscarriage which was 12 weeks ago. A serum pregnancy test done at presentation was positive and a transvaginal scan done showed an uterus with two separate endometrial cavities with a gestational sac in the right cavity and the left cavity was empty. Serial follow up scans showed a viable fetus which continued to advance in gestation in the right half of the endometrial cavity and a subtle indentation noticed on the fundal region of the uterus. Pregnancy was complicated by several admissions on account of preterm contractions which was managed with Nifedipine, analgesics and intravenous fluids. She subsequently had emergency caesarean section at 36 weeks following spontaneous rupture of fetal membranes. She was delivered of a live female neonate weighing 2.8kg. The ovaries were grossly normal.

Findings at surgery showed an anterior mid-uterine septum with a fundal indentation which was excised and haemostasis secured. (Figure). Her puparium was uneventful. She spontaneously conceived again and had a repeat elective caesarean section at 38 weeks. (figure 11-13).

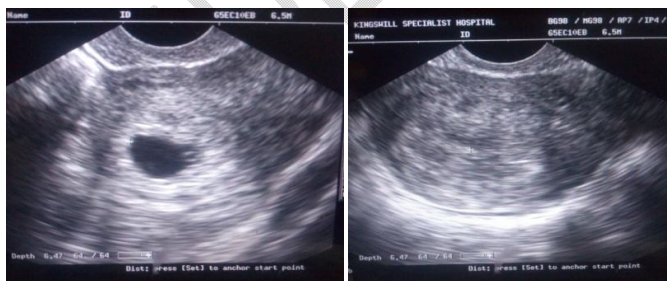

Fig 1(a) & (b).

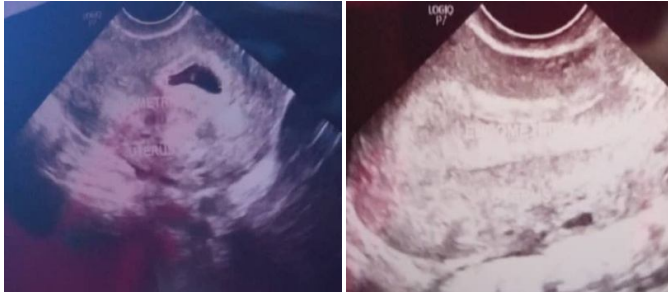

Fig 2 (a) & (b).

Fig 1&2; Another Trans vaginal ultrasound scans showing right endometrial cavity containing gestational sac at 5 weeks (1a and 2a),and left empty endometrium (1b and 2b).

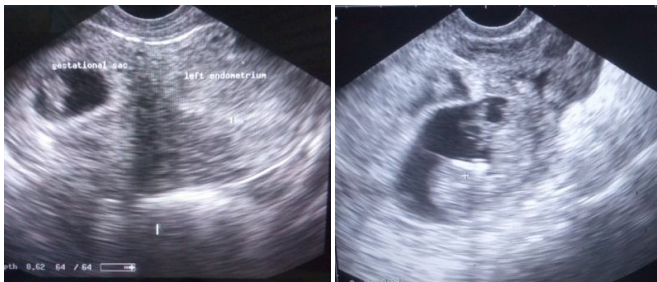

Fig 3 (a) & (b).

Transvaginal ultrasound scan at 7 weeks; transverse view with fetus in right endometrium and empty left endometrium (a) and lateral view (b).

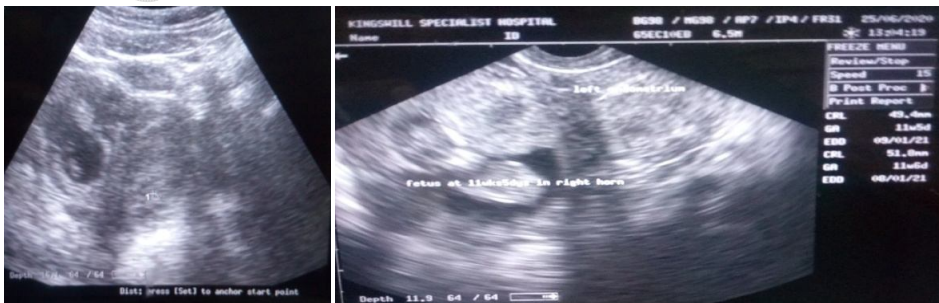

Fig 4 (a) & (b).

Pelvic scan at 11 weeks showing fundal indentation (a), and TV scan at 11 weeks with fetus in right endometrium and empty left endometrium (b).

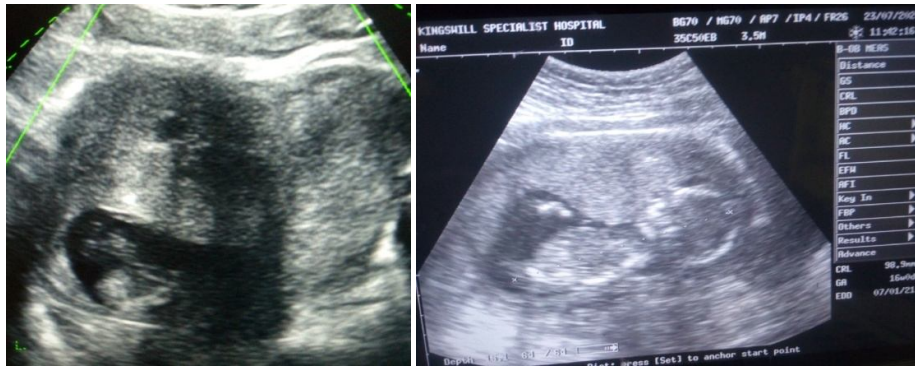

Fig 5 & Fig 6

Pelvic scans at 13 weeks showing fetus in right half of uterus and fundal indentation (a) and at 16 weeks showing placenta to be anterior (b).

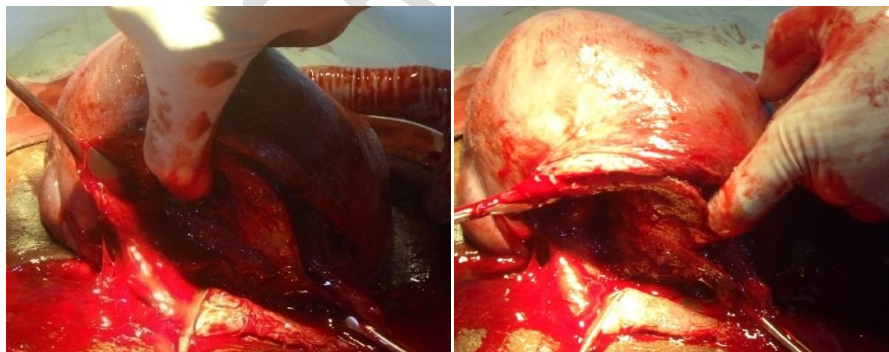

Fig 7 (a) and (b).

Operating finger probing the right endometrial cavity after fetus and placenta extraction (a) and probing the left cavity (b).

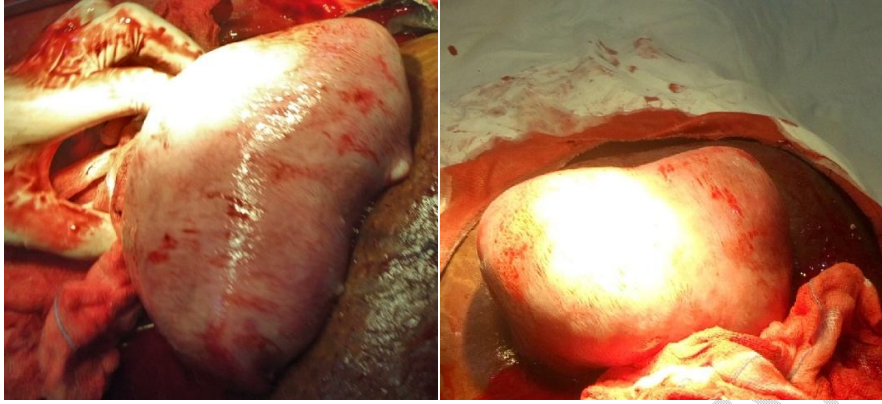


Fig 8 (a) and (b)

Fundal (a) and posterior (b) surface of uterus after delivery showing a subtle fundal indentation.

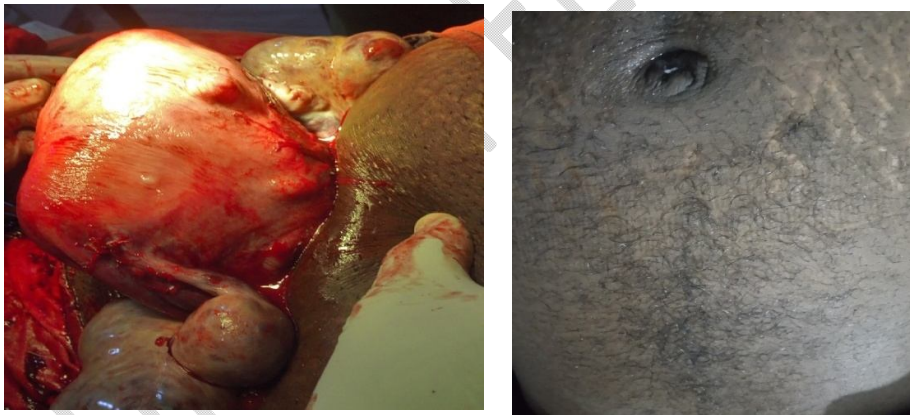

Fig 9& 10.

ovaries seen after delivery (Fig 9) and abdomen showing significant hirsutism (Fig 10).

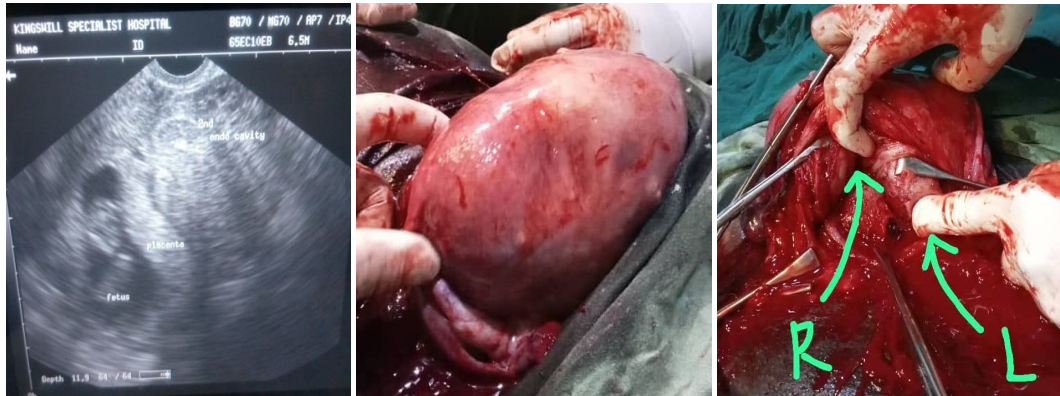


Fig. 11, 12 and 13; intrauterine gestation in the right endometrial cavity at 9 weeks , uterine fundus at delivery and operating fingers in the both half of the non-communicating endometrial cavities respectively.

Case 2:

She was a 43-year-old with two previous miscarriages. She had presented for ante natal care with a third pregnancy at 8 weeks gestation. Just as with the prior miscarriages, index pregnancy was also conceived by intra-uterine insemination. A transvaginal ultrasound scan done at presentation showed two separate endometrial cavities with the fetus in the left cavity and the right cavity empty. She had a threatened miscarriage at 9 and 13-weeks' gestation, which she was admitted and managed. Subsequent ultrasound scans showed same finding with progressive fetal development. A cervical cerclage was done at 15weeks. She had another episode of threatened miscarriage at 19- and 23-weeks' gestation. She had preterm contractions at 31 and 35 weeks which was successfully averted. She had an elective caesarean section at 38 weeks with the delivery of a live male neonate weighing 3.4kg .

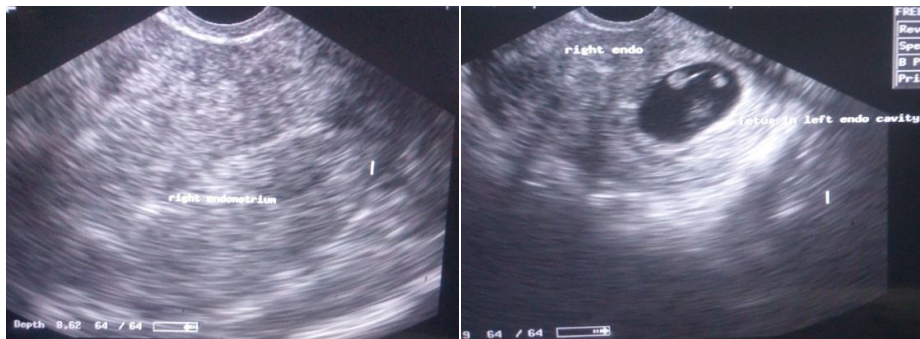

Fig 14 & 15

Transvaginal scan at 8 weeks showing the right endometrium (Fig 14), and left endometrium containing fetus and an empty right endometrium (Fig 15).

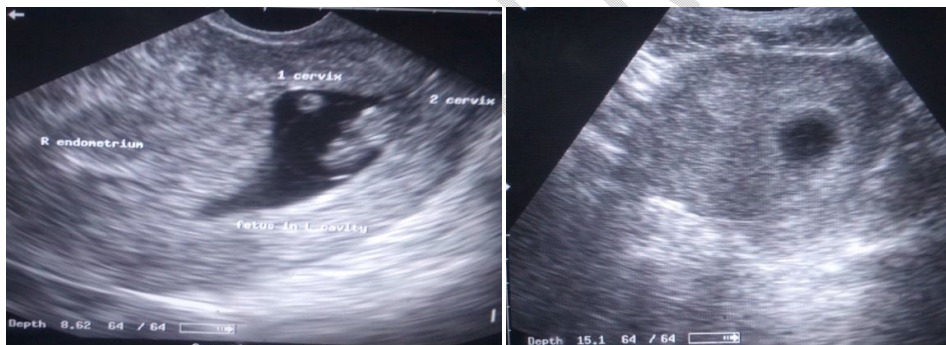


Fig 16 & 17.

Transvaginal scan at 8 weeks showing both endometrial cavities with fetus in the left cavity with a centrally located cervix and an eccentric lower segment of the right cavity not communicating with the central cervical canal (Fig 16). Pelvic scan at 8 weeks not revealing any obvious contour distortion. (Fig 17).

Discussion

Uterine septum is the most common type of structural uterine anomaly (34%–48%)^{6,7}. It is also the most frequently encountered Mullerian defect in the presence of recurrent pregnancy loss, with an incidence of 5.5%¹. The persistence of the partitioning from a defective fusion of paramesonephric ducts during embryogenesis is the basis for uterine septum. It is known to be responsible for reproductive failures such as miscarriages, recurrent pregnancy loss of the first and second trimester, intrauterine growth restriction, and abnormal fetal presentation. It is largely asymptomatic making the true prevalence difficult to ascertain⁷.

Just as other congenital uterine anomalies, it is more likely to be associated with reduced fecundity, reduced live birth rate, increased abortions, preterm birth, low birth weight, fetal malpresentation, uterine rupture, caesarean delivery and perinatal mortality⁷. It also leads to a reduction in pregnancy rate and increases the abortion rate after assisted conception.⁴The extent of septal division does not correlate with symptomatology for reasons unknown as the

septum has been shown sonographically to stretch during pregnancy.⁴The two cases presented has history of miscarriages and preterm contractions.

Although these patients had histories of miscarriages and benefited from septal resection during caesarean section, incidental finding of uterine septae may not necessarily be an indication for surgery as it has been shown in some studies that surgery may not improve pregnancy outcome.⁸However, when there is associated adverse events such as miscarriages or infertility, hysteroscopic resection may be an option.

During surgical treatment for symptomatic cases, optimal treatment entails resection of at least 90 percent of the uterine septum.⁸ Post resection, hysterosalpingogram or either 2 or 3D dimensional ultrasound scan is usually scheduled two months later to determine the extent of the resection. Septal remnant of up to 1cm is an indication for a repeat surgery.⁹ Following successful surgical repair, patients are advised to attempt conception from 2-3 months.

Conclusion

Non-uterine factors should be excluded in the setting of primary infertility. Prognosis of pregnancy can be favourable even amongst the previously symptomatic patient.

Disclaimer (Artificial Intelligence)

We hereby declare that no generative AI technologies such as Large Language Models (ChatGPT, COPILOT, etc.) and text-to-image generators have been used during writing or editing of manuscripts.

Consent

A written consent was obtained from the patient for publication of this case report.

References

1. T. Ghi, Musso F, Maroni E, Youssef A, Savelli L, Farina A, et al. The pregnancy outcome in women with incidental diagnosis of septate uterus at first trimester scan. *Human Reproduction* [Internet]. 2012 Jun 29 [cited 2023 Sep 7];27(9):2671–5. Available from: <https://academic.oup.com/humrep/article/27/9/2671/626478>
2. Jiang Y, Wang L, Wang B, et al. Reproductive outcomes of natural pregnancy after hysteroscopic septum resection in patients with a septate uterus: a systematic review and meta-analysis. *Am J ObstetGynecol MFM* 2023; 5:100762.
3. Valle RF, Ekpo GE. Hysteroscopic metroplasty for the septate uterus: review and meta-analysis. *J Minim Invasive Gynecol* 2013; 20:22.
4. Ajah L, Okezie O, Ugwu E, Adiri C, Umeh U. Case report on septate uterus: An incidental finding in a multiparous woman who had an emergency cesarean section. *Journal of Basic and Clinical Reproductive Sciences*. 2014;3(1):74.

5. Carrera M, Pérez Millan F, Alcázar JL, et al. Effect of Hysteroscopic Metroplasty on Reproductive Outcomes in Women with Septate Uterus: Systematic Review and Meta-Analysis. *J Minim Invasive Gynecol* 2022; 29:465.
6. Chang Y, Shen M, Wang S, Guo Z, Duan H. Reproductive outcomes and risk factors of women with septate uterus after hysteroscopic metroplasty. *Front Endocrinol (Lausanne)*. 2023 Jun 8; 14:1063774. doi: 10.3389/fendo.2023.1063774. PMID: 37361532; PMCID: PMC10285310.
7. Martinez-Peñuela CRE, Zabaleta J, Campo G, Elizalde FJ, Pérez B. A Successful Pregnancy Outcome in a Complete Septate Uterus. *J Reprod Med GynecolObstet*; 2019; 4: 025.
8. Rikken JFW, Kowalik CR, Emanuel MH, et al. Septum resection versus expectant management in women with a septate uterus: an international multicentre open-label randomized controlled trial. *Hum Reprod* 2021; 36:1260.
9. Miller CM, Shenoy CC, Khan Z. Three degrees of separation: complete uterine and cervical septa. *Fertil Steril*. 2021 Sep;116(3):915-916. doi: 10.1016/j.fertnstert.2021.04.027. Epub 2021 May 18. PMID: 34016433