

## Minireview Article

### Ectopic tooth eruption – Integrative Literature Review

**Abstract:** Ectopic eruption designates teeth that deviate from their normal eruption pattern. Its multifactorial etiology includes local and systemic factors, somatic disorders, and genetics. The objective of this study is to know the most common teeth that can present ectopic eruption, their prevalence, and associated clinical factors. A bibliographic search of scientific articles indexed in the PUBMED® and VHL databases was performed in September 2023, with the following descriptors: "Tooth Eruption; Ectopic; Dentistry". A total of 42 articles published in the last 5 years were found. Of these, 16 addressed ectopic eruptions and were included. The reviewed literature highlights the following clinical aspects: delayed eruption, partial appearance of the crown, changes in the eruption axis, transpositions, and gyro versions. The most affected teeth are the first permanent molars, with approximately 2 to 6%, and the canines with approximately 1.5 to 4.6%. It is essential to diagnose ectopic eruption early and identify the etiological factors, to obtain early treatment, preventing the development of this pathology and, consequently, the appearance of malocclusion.

**Keywords:** Tooth Eruption; Ectopic; Dentistry.

#### 1. INTRODUCTION

Tooth eruption is a phenomenon characterized by the axial movement of the tooth from its position of development in the alveolar bone until it reaches its functional site within the dental arches [1]. When there is a deviation from the normal tooth eruption pattern, and one or more teeth emerge out of anatomical position, an ectopic eruption occurs [2].

The interaction between the oral epithelium and germ cells plays an important role in tooth development [2]. Developmental disorders, pathologies, cellular processes with

mutations, or iatrogenic activity during embryonic development can cause an abnormal relationship or migration of these cells to an atypical position [2,3].

In this context, the pathogenesis of ectopic eruption may be directly related to the processes of odontogenesis [2,3]. However, the etiology is multifactorial and not yet well understood [1,4]. Somatic disorders and genetic factors such as hypothyroidism, Down Syndrome, and Cleido Cranial Dysplasia are described as predisposing [1,4].

In addition, local factors such as supernumerary teeth, atresia and clefts in the bone bases, discrepant tooth morphology and sizes, and prolonged retention of deciduous teeth are conditions commonly associated with ectopic eruption [1,4,5].

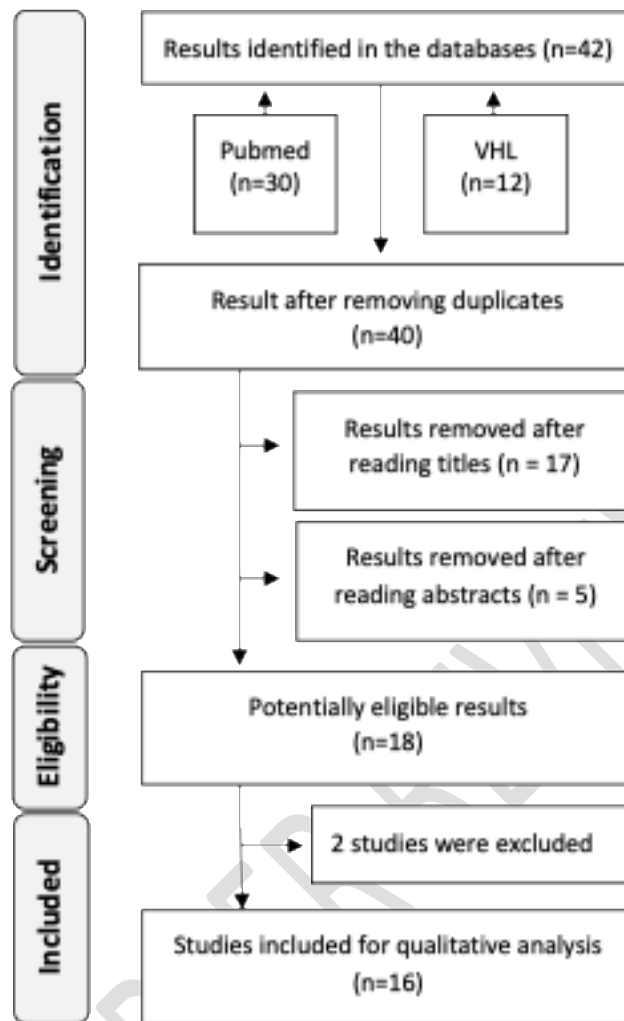
Epidemiology establishes that ectopic eruption most often affects the first permanent molars and canines, both in the mandible and maxilla [1,6]. In other regions outside the oral cavity, this condition is rare, although there are reports of teeth in the maxillary sinus, mandibular condyle, coronoid process, palate, chin, and nasal cavity [1,6,7,8].

Considering the functional and aesthetic impacts related to ectopic eruption, the objective of this study was, based on an integrative review of the literature, to discuss the main etiological and clinical management aspects of ectopic teeth.

## **2. METHODOLOGY**

A bibliographic search of scientific articles indexed in the PUBMED® and VHL databases (Virtual Health Library), carried out in September 2023, was carried out with the following descriptors: "Tooth Eruption; Ectopic; Dentistry". The descriptors were chosen to include all types of ectopic teeth (incisors, canines, premolars, and molars). Articles published in the last 5 years were included as potentially relevant. A total of 30 were identified on PUBMED® and 12 on VHL, totaling 42 articles. After the analysis of all articles, 17 were excluded by title, 7 were excluded after reading the abstract and 2 were removed because they were duplicates, so 16 articles were selected for full reading and all were included in this study. The exclusion criteria are articles that have been published for more than 5 years, articles for which it was not possible to obtain the full text, and articles with subjects that blur their theme about the central theme.

**Figure 1:** Flowchart of the selection process of the included articles



**Table 1:** Characteristics of the included studies

Article name	Authors/references	Incidence/prevalence	Tooth	Study type	Summary of the article
--------------	--------------------	----------------------	-------	------------	------------------------

<b>Treatment of ectopic eruption of the maxillary first permanent molar in children and adolescents: A scoping review</b>	[1]	The prevalence of ectopic eruption is up to 6% and affects both sexes equally.	1st molar	Scoping review	To conduct a scoping review to collect the most relevant studies published in the last 30 years regarding the ectopic eruption of the first permanent molar. Its local eruptive behavior is disturbed during the development of mixed dentition.
<b>Ectopic Tooth in Mandibular Canal, Maxillary Sinus, and Mandibular Condyle</b>	[9]	Uncertain	Teeth in general	Case description	To describe the ectopic eruption, which although rare, there have been cases in the maxillary sinus, mandibular condyle, nasal cavity, chin, palate, and orbital floor. It has been reported that odontogenic tumors and cysts can develop around the ectopic tooth. Therefore, ectopic teeth can be monitored regularly if they do not present signs and symptoms.
<b>Management of rare ectopic teeth eruption: case series</b>	[10]	80.0% male, with an average of 23.3 years of age.	3rd molar	Case series	To report a case series of ectopic teeth in rare locations in the mandible and highlight the associated pathology and experience in surgical management. Of these, ten cases of ectopic teeth were identified during the study period. The antrum and lower border of the mandible represented 50.0% and 40.0% of ectopic locations, respectively.
<b>Laser-assisted management of ectopic eruption of permanent incisors</b>	[11]	The most frequently influenced teeth are the upper first molars, accompanied by the upper canines.	Incentives	Case report	The use of Er, Cr: YSGG lasers for correction of hyperplastic soft tissues involving ectopically erupting permanent incisors is portrayed considering two cases.
<b>Ectopic tooth in maxillary sinus compressing the nasolacrimal canal: A case report</b>	[2]	Uncertain	A tooth with a dentigerous cyst	Case report	To present a rare case of an ectopic tooth with a dentigerous cyst in the maxillary sinus compressing the nasolacrimal duct.
<b>Ectopic Eruption of First Permanent Molars for Pediatric Patients Attended King Saud University.</b>	[12]	Male 28 (2.9%), female 17 (1.6%). 47 (78.33%) maxilla, 13 (21.66%) mandible	1st molar	Case report	The study aimed to determine the prevalence of ectopic eruption of the upper first permanent molar in the pediatric population and analyze whether there is a relationship between this anomaly and dental-skeletal characteristics using Ricketts cephalometry.

<b>Ectopic Eruption of Maxillary First Permanent Molars: Preliminary Results of Prevalence and Dentoskeletal Characteristics in Spanish Pediatric Population</b>	[6]	Prevalence of maxillary ectopic eruption (MEE), 8.7%. Age group 7 years of age (18.8%) and bilateral.	1st molar	Prevalence study (Spain)	To determine the prevalence of EEM in children and analyze whether there is a relationship between EEM and dental-skeletal characteristics. 322 children were analyzed using the Ricketts cephalometric study and descriptive and analytical statistical analyses were performed.
<b>Ectopic Permanent Molars: A Review</b>	[13]	7 to 8 years old	Molars	Literature review	Elucidate the etiology, clinical characteristics, and consequences of ectopic molar eruption, in addition to highlighting the importance of future research on the variables that contribute to irreversible results of ectopic molars.
<b>Ectopically Positioned Tooth Piercing the Philtrum</b>	[14]	Uncertain	Incisive	Case report	Case report of a 70-year-old woman who presented to the Department of Oral and Maxillofacial Surgery, Karnavati School of Dentistry, Uvardsad, Gandhinagar, Gujarat, India reporting an abnormally positioned tooth piercing her upper lip. According to the patient's history, the labially erupted tooth had been perforating the philtrum for 60 years, it was visible extra orally and was painful.
<b>Ectopic Mandibular Canine with Partial Anodontia - A Rare Case Report</b>	[15]	Rare case	Canine	Rare case report	To present a rare case of non-syndromic partial anodontia and ectopic eruption of the permanent lower canine in a female patient.
<b>Evaluation of the position of the permanent maxillary canine and its relationship to dental anomaly patterns in the pediatric patient</b>	[16]	The prevalence of ectopic eruption of the permanent upper canine was 9.23%.	Superior canine	Descriptive/transversal/observational and descriptive	To evaluate the prevalence of ectopic eruption of the permanent upper canine in patients between 6 to 10 years of age and its relationship with other dental anomalies, age, and sex of the patient.
<b>Management of ectopically erupting permanent molars in a seven-year-old girl: A case report</b>	[17]	Uncertain	Permanent molar	Case report	To report the case of a seven-and-a-half-year-old girl with ectopic eruption of the permanent upper and lower first molars, treated with orthodontic separators and cutting the distal surface of the adjacent deciduous second molar separately. Regular examination and timely interception are important during the management of children's oral health and are of great importance in alleviating the side effects of ectopic eruption.

<p><b>Case Report: Ectopic third molar in the maxillary sinus with infected dentigerous cyst assessed by cone beam CT</b></p>	<p>[18]</p>	<p>Uncertain</p>	<p>3rd molar/case report</p>	<p>Case report</p>	<p>Report the case of a 13-year-old student who presented with purulent secretion behind her right upper second molar with a bad taste and foul odor. Radiographic examination revealed a third upper molar located on the posterosuperior surface of the right maxillary sinus with a hyperdense lesion surrounding the crown, obliterating the sinus cavity. Both the tooth and the dentigerous cyst were surgically removed under general anesthesia via a Caldwell-Luc antrostomy.</p>
<p><b>Canine Transposition - Prevalence, Distribution and Treatment Considerations among Orthodontic Patients</b></p>	<p>[19]</p>	<p>3 (20%) men and 12 (80%) women with a prevalence of 0.5%.</p>	<p>Canine</p>	<p>Prevalence /cross-sectional</p>	<p>To determine the prevalence and distribution of canine transposition in a sample of orthodontic patients and present treatment alternatives and outcomes.  Study design: The records of 3,000 consecutive orthodontic patients treated at a university clinic were searched to detect the transposition of canines in both dental arches.</p>
<p><b>Corrective Treatment of Ectopic Eruption of Permanent First Molars: Case Report / Tratamiento correctivo de erupción ectópica de primeros molares permanentes: Reporte de casos</b></p>	<p>[3]</p>	<p>Uncertain</p>	<p>1st molar</p>	<p>Case report</p>	<p>The objective of the present study was to report two clinical cases where the ectopic eruption of the first permanent molars was corrected using elastic separators.</p>
<p><b>Tooth transposition: a multidisciplinary approach</b></p>	<p>[20]</p>	<p>Uncertain</p>	<p>Teeth in general</p>	<p>Review with a case report</p>	<p>Discuss the treatment modalities for dental transposition, their advantages, and disadvantages, and present a clinical case of transposition between canine and lateral incisor in the upper right hemiarch. The therapeutic choice was the extraction of one of the transposed teeth, requiring a multidisciplinary approach with the participation of Orthodontics, Dentistry, and Periodontics so that adequate aesthetic and functional results were achieved.</p>

### 3. RESULT AND DISCUSSION

#### 3.1 *Types of ectopic eruption*

A variety of eruption disorders can occur during the period of intraosseous tooth formation up to the occlusion position. This change is more frequent during the transitional period, in the dentition stage, in which the deciduous dentition is replaced by the permanent successors [20].

An ectopic tooth is displaced at a considerable distance from its normal anatomical location [10]. One of the most common types of ectopic eruption is tooth transposition, which results in a change in the position of the teeth and an abnormal sequence of permanent teeth in the dental arch [19].

“Transposition can be complete when all the crowns and root structures of the teeth involved are in transposed malposition, or incomplete (also described as "pseudo" or "partial") when only the crowns are transposed, but the root apices remain in normal positions” [19]. “Transposition has been reported to occur most frequently between the maxillary permanent canine and the first premolar, and occasionally involving the maxillary canine and lateral incisor or the mandibular canine and lateral incisor. This anomaly is more often found unilaterally than bilaterally, with a predominance of the left side and more often in women than in men” [19].

“Transposition of maxillary teeth is an eruptive disturbance occurring in approximately 1 of every 300 orthodontic patients. Such cases are frequently very challenging in terms of treatment planning and orthodontic management. The canine is one of the most commonly transposed teeth, ectopically positioned with either the lateral incisor or the first premolar” [21]. “This condition may be one of the most challenging in orthodontics, as it modifies the occlusion, causes a negative aesthetic impact, and compromises the future stability of the permanent dentition” [21].

#### 3.2 *Prevalence of eruption abnormality*

“The prevalence of eruption abnormality has been reported to be between 1.8% to 6%, affecting both sexes equally. It is believed that there is a familial tendency (higher occurrence in siblings)” [1]. “It is also evidenced as an expression of numerous syndromes and in children who present concomitant orofacial and dental anomalies, such as cleft palate (with a four-times higher prevalence), congenital absence of teeth, supernumerary teeth and dental size anomalies” [1].

“The teeth most affected by ectopy are the first permanent molars, comprising 2 to 6%, and the canines with approximately 1.5 to 4.6%. Ectopy is identified in the incisors, second molars, premolars, and, more uncommonly, in the third molars (these are more frequently reported as impaction)” [1,13,19].

“There are 2 types of ectopic eruption of the first permanent molar: self-correcting (SC) and irreversible (IRR). The SC type may become detached from the distal contour of the second primary molar at the age of 7 to 8 years, and no interceptive treatment should be initiated. The IRR type may remain blocked after the age of 8 years and, if left untreated, may lead to premature loss of the second primary molar and subsequent shortening of the dental arch length, displacement of the first permanent molar, and supra eruption of the opposing molar. Early prediction of the outcome of IRR and early initiation of interceptive treatment should be performed to avoid detrimental consequences” [22].

### *3.3 Etiology and clinical manifestations*

“The etiology of an ectopic eruption is still uncertain and may occur due to local and systemic factors. Several theories have been presented to describe the appearance of this condition, such as developmental disorders like cleft palate; pathological processes such as large cysts, which displace the tooth buds to other areas; odontogenic and rhinogenic infections; or iatrogenesis” [16,18].

“Permanent teeth on the cleft side erupt more slowly. This long-lasting eruption makes it more susceptible to ectopia and increases the risk of impaction. A relationship between tooth agenesis, clefts, and genetic disorders has been suggested” [23].

“The proper development of the dental arches, including the eruption and correct positioning of the canines for example, in the arch, is essential for the oral health of growing patients. Impacted teeth not only give rise to functional challenges but also pose esthetic issues for patients” [24].

“Ectopic foreign bodies in the maxillary sinus occur rarely. Ectopic tooth eruption rarely occurs in the orbit, nasal cavity, maxillary sinus, and elsewhere. Ectopic eruption of teeth in the maxillary sinus is most commonly associated with wisdom teeth and is rarely associated with supernumerary teeth” [25]. “This rare phenomenon may be accompanied by chronic recurrent sinusitis with headaches and facial pain. However, fibro-osseous lesions in the paranasal sinuses are discovered incidentally on X-ray images and are often asymptomatic” [25].

“Ectopic teeth are rare and not always associated with pathology. A dentigerous cyst is the most common pathology of unerupted or impacted teeth, which may present with swelling and other vague symptoms. A high index of suspicion and radiological investigation are necessary for diagnosis” [10]. “The type of associated pathology and location should inform the decision regarding a surgical approach and possible complications. A more extensive multi-center study is warranted to determine the prevalence of ectopic teeth other than the third molar” [10].

In the oral cavity, a clinical variety of inclinations, angulations, and transpositions are observed. It can be present even in other regions of the body such as the maxillary sinus, condylar process, coronoid process, nasal cavity, and orbit [5].

“The atypical rash is usually a painless abnormality and commonly not noticed by patients. However, it may be associated with recurrent infections characterized by pain, swelling, and purulent discharge, dentigerous cysts, bone expansion, or may be discovered incidentally during other investigations” [5]. “This highlights the need for early diagnosis using panoramic radiographs, particularly during the ages of 9 and 10, to ensure effective patient management” [26].

### *3.4 Diagnosis and Treatment*

The diagnosis is essentially clinical and radiographic. Evaluation is done through panoramic radiographs and telerradiography, or in more complex cases CBCT. Clinically, more frequent changes in position are observed in the initial mixed dentition from 6 to 7 years of age. This local condition is grouped into self-correcting or reversible when the ectopic tooth eventually goes into occlusion after the end of its eruption; or irreversible when the ectopic element remains in an altered position even after the irruptive period [1,18].

In this context and to avoid functional and aesthetic problems as a result of this condition, an early diagnosis is necessary. The management sequence includes careful anamnesis, clinical and radiographic diagnosis, and appropriate treatment. The individual tooth position should be evaluated before the irruptive process and its intermaxillary relations in the three-dimensional context of the maxilla and mandible [1,5,16].

Preventive treatment should focus on three objectives: favoring tooth eruption in the normal position, maintenance of the irruptive sequence, and arch perimeter. These measurements can create space and bone direction so that the teeth can occupy their correct position in the dental arch [9]. In this sense, the planning can include the use of

orthopedic appliances for the expansion of the dental arches, as well as serial and planned extractions for the correct alignment and leveling of the teeth at the bone bases [9].

As a consequence of this process and the lack of early diagnosis and treatment, there is a tendency for prolonged retention or early loss of deciduous teeth, root resorption, caries lesions in adjacent teeth, migration of neighboring teeth, referred pain, alignment problems and alteration in normal occlusion [1,16,19].

Therefore, eruption guidance during deciduous and mixed dentition-stages is an integral part of comprehensive oral health care to achieve occlusal harmony, function, and aesthetics [1,16,19].

#### **4. CONCLUSION**

The orientation of the eruption during the deciduous and mixed dentition stage is an integral part of comprehensive oral health care to achieve occlusal harmony, function, and aesthetics.

As a result of the failure of the eruption or the inadequate positioning of the teeth, there may be changes in the ideal pattern of mandibular excursive movements, prolonged retention of deciduous teeth, root resorption in the teeth proximal to this condition, among other functional and aesthetic problems.

Thus, it is essential to diagnose ectopic eruption early and identify etiological factors to obtain early treatment to prevent the development of this pathology and, consequently, the onset of malocclusion.

#### **Declaration of generative AI in scientific writing**

The authors did not use generative AI for writing this article at all.

#### **6. REFERENCES**

[1] Garrocho-Rangel A, Benavídez-Valadez P, Rosales-Berber MÁ, Pozos-Guillén A. Treatment of ectopic eruption of the maxillary first permanent molar in children and adolescents: A scoping review. *Eur J Paediatr Dent.* 2022;23(2):94–100.

- [2] Yang P, Liang H, Zou B, Liu J, Yuan D, Meng Z, et al. Ectopic tooth in maxillary sinus compressing the nasolacrimal canal: A case report. *Medicine (Baltimore)*. 2021;100(18):e25514.
- [3] Gutiérrez-Marín N. Corrective Treatment of Ectopic Eruption of Permanent First Molars: Case Report. *Odovtos International Journal of Dental Sciences*. 2020; 23(2):19–26.
- [4] Ciuraj M, Lipowicz A, Graja K, Zwolska P, Myśliwiec A. Physiotherapeutic methods of treatment of mandibular distal occlusion and the progress of therapy: A case report. *J Bodyw Mov Ther*. 2022; 29:26–32.
- [5] Chintakanon K, Boonpinon P. Ectopic eruption of the first permanent molars: prevalence and etiologic factors. *The Angle Orthodontist*. 1998 Apr 1;68(2):153-60.
- [6] Helm A, Martín-Vacas A, Molinero-Mourelle P, Caleyá AM, Gallardo NE, Mourelle-Martínez MR. Ectopic Eruption of Maxillary First Permanent Molars: Preliminary Results of Prevalence and Dentoskeletal Characteristics in Spanish Paediatric Population. *Children (Basel)*. 2021;8(6):479.
- [7] Bjerklin K, Kurol J, Valentin J. Ectopic eruption of maxillary first permanent molars and association with other tooth and developmental disturbances. *The European Journal of Orthodontics*. 1992 Oct 1;14(5):369-75.
- [8] Ismail MQ, Lauridsen E, Andreasen JO, Hermann NV. Ectopic eruption of the second premolar: an analysis of four different treatment approaches. *European Archives of Paediatric Dentistry*. 2020 Feb;21:119-27.
- [9] Akbas M, Karabıyık Z, Varol A. Ectopic Tooth in Mandibular Canal, Maxillary Sinus, and Mandibular Condyle. *Case Rep Dent*. 2022;2022:3118998.
- [10] James O, Suleiman IK, Ahmad MM, Olasoji HO. Management of rare ectopic teeth eruption: case series. *J Korean Assoc Oral Maxillofac Surg*. 2023;49(2):86–90.
- [11] Ciftci V, Uguz HN, Ozcan M. Laser-assisted management of ectopic eruption of permanent incisors. *Niger J Clin Pract*. 2019;22(2):276–80.

- [12] Aldowsari MK, Alsaidan M, Alaqil M, BinAjian A, Albeialy J, Alraawi M, et al. Ectopic Eruption of First Permanent Molars for Pediatric Patients Attended King Saud University, Riyadh, Saudi Arabia: A Radiographic Study. *Clin Cosmet Investig Dent*. 2021;13:325–33.
- [13] Alfuriji S, Alamro H, Kentab J, Alosail L, Alali L, Altuwaijri N, et al. Ectopic Permanent Molars: A Review. *Dent J (Basel)*. 2023;11(9):206.
- [14] Mehta PD, Desai N, Matariya R, Patel Y. Ectopically Positioned Tooth Piercing the Philtrum. *Ann Maxillofac Surg*. 2019;9(2):475–7.
- [15] Hemamalini R, Mahabob MN, Anbuselvan GJ, Sivagami M, Yamunadevi A, Vijayalakshmi D, et al. Ectopic Mandibular Canine with Partial Anodontia - A Rare Case Report. *J Pharm Bioallied Sci*. 2023;15(Suppl 1):S795–6.
- [16] Díaz-González L, Guinot F, García C, Baltà L, Chung-Leng I. Evaluation of the position of the permanent maxillary canine and its relationship to dental anomaly patterns in the pediatric patient. *Eur J Paediatr Dent*. 2022;23(4):281–7.
- [17] Meng M, Zhou X, Zhang Q, Zou J. Management of ectopically erupting permanent molars in a seven-year-old girl: A case report. *J Pak Med Assoc*. 2021;71(12):2809–11.
- [18] Elmorsy K, Elsayed LK, El Khateeb SM. Case Report: Ectopic third molar in the maxillary sinus with infected dentigerous cyst assessed by cone beam CT. *F1000Res*. 2020;9:209.
- [19] Finkelstein T, Shapira Y, Pavlidi AM, Davidovitch M, Blumer S, Schonberger S, et al. Canine Transposition - Prevalence, Distribution and Treatment Considerations among Orthodontic Patients. *J Clin Pediatr Dent*. 2020;44(4):268–73.
- [20] Matsumoto MAN, Stuani MBS. Tooth transposition: a multidisciplinary approach. *Dental Press J Orthod*. 2018;23:97–107.
- [21] Pedalino A, Matias M, Gaziri D, Vieira B, Alves B, Ursi B; Treatment of maxillary canine transposition. *Angle Orthod* 1 November 2020; 90 (6): 873–880. doi: <https://doi.org/10.2319/121719-808.1>

[22] Chen X, Huo Y, Peng Y, Zhang Q, Zou J. Ectopic eruption of the first permanent molar: Predictive factors for irreversible outcome. *American Journal of Orthodontics and Dentofacial Orthopedics*. 2021 159(2), e169–e177. doi:10.1016/j.ajodo.2020.09.020.

[23] Braga BMR, Leal CR, Carvalho RM, Dalben GS, Azawa TO. Outcomes of permanent canines on the cleft side after secondary alveolar grafting using different materials in complete unilateral cleft lip and palate. *J Appl Oral Sci*, 2023;31:e20220478.

[24] Memè L, Quinzi V, Coli G, Caciari E, Sampalmieri F, Gallusi G. Unconventional use of Invisalign® in the treatment of ectopic palatal maxillary canines. *Eur J Paediatr Dent*. 2024 Mar 1;25(1):61-68. doi: 10.23804/ejpd.2024.2123. Epub 2024 Feb 1. PMID: 38329027.

[25] Kataoka T, Amemiya K, Goto T, Kina H, Tajima E, Okamoto T. A Unique Case of Supernumerary Teeth Erupting Inside a Maxillary Sinus Osteoma. *J Clin Med*. 2024 Jul 11;13(14):4067. doi: 10.3390/jcm13144067. PMID: 39064108; PMCID: PMC11277642.

[26] Alanzi A, Bufersen N, Haider S, Abdulrahim M. Prevalence and Distribution of Dental Anomalies in Schoolchildren in Kuwait. *Int Dent J*. 2024 Jun;74(3):566-572. doi: 10.1016/j.identj.2023.10.019. Epub 2024 Jan 29. PMID: 38290916; PMCID: PMC11123520.