

# **A self-inserted foreign body in the urinary bladder and urethra due to autoerotism: Two case reports**

## **Abstract**

Most foreign bodies in the lower genitourinary tract are self-inserted through the urethra, often due to psychosexual issues, sexual curiosity, or autoerotic behaviour. A variety of foreign objects have been reported, including screws, pens, nuts, electrical or telephone wires, plastic tubes, and writing utensils like pens and pencils.

Diagnosis typically involves taking a thorough clinical history, conducting a physical examination, and utilizing imaging studies. Treatment depends on the size, location, shape, and mobility of the foreign body. In most cases, minimally invasive procedures, such as endoscopic removal, are preferred to prevent bladder and urethral injuries. However, in certain cases, more invasive approaches, such as open surgery or suprapubic cystostomy, may be necessary.

We present two cases of self-inserted foreign bodies in the urinary bladder and urethra. The foreign body in the urethra was removed via cystoscopy, while the foreign body in the bladder was extracted through an open suprapubic cystostomy.

**Keywords:** Electrical wire, foreign bodies, urethra, urinary bladder, suprapubic cystostomy

## **Introduction**

Foreign bodies in the lower urinary tract are uncommon, but numerous cases have been documented. These objects, if left undetected, can linger for extended periods, causing severe discomfort, hematuria (blood in the urine), and persistent urinary tract infections. Symptoms may also include increased urinary frequency, dysuria (painful urination), urethral obstructions, strictures, fistulas, and sharp pain. [1,4,6]

Imaging plays a critical role in determining the exact position, shape, and size of these foreign bodies. Though rare, urethral foreign bodies present a unique challenge in both urology and general surgery, as every case tells a different story. Each patient's decision to insert an object into their urethra or bladder is deeply personal, often driven by psychiatric conditions or a desire for autoerotic stimulation. [1,2,7]

Early detection using advanced imaging techniques is vital. In emergencies, swift intervention by skilled endoscopic urologists or general surgeons is necessary to minimize complications and ensure safe removal, especially in peripheral medical settings where resources may be limited. [2,7,8]

## **Case presentation:**

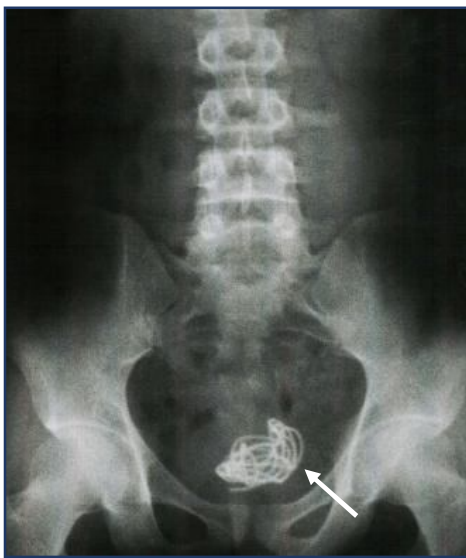### **Case I – A 40 cm Electrical wire in the urinary bladder**

A 32-year-old college student was admitted to our centre on October 10, 2020, with complaints of hematuria and burning during urination for the past 15 days. Radiological investigations, including an X-ray of the kidney, ureter, and bladder (KUB), revealed a coiled metallic wire in the pelvic region. A urine examination showed the presence of numerous red blood cells (RBCs) and pus cells. The patient recounted that four-month prior; he had self-inserted a 40 cm electrical wire through his

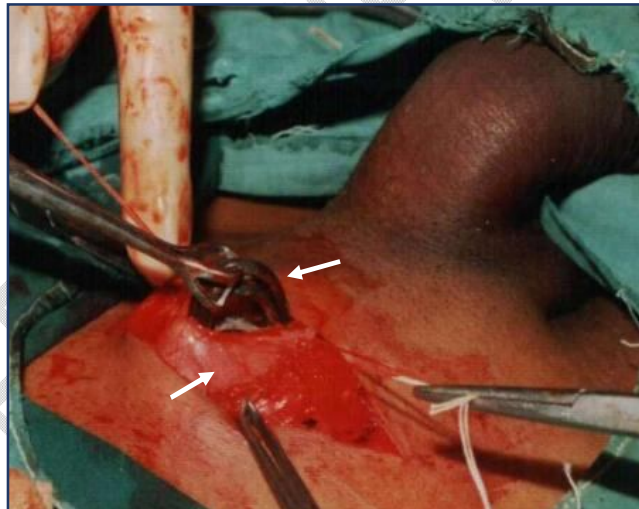
urethra into his bladder. After inserting the wire, he experienced penile erection and engaged in masturbation, believing that the wire would come out. However, due to the contraction of the perineal muscles and bladder, the wire was instead pulled further into the bladder.

Four months after the insertion, he presented to our centre with hematuria and burning urination. We conducted an X-ray KUB to rule out bladder stones but were surprised to find a metallic coiled wire inside the bladder. Laboratory findings confirmed microscopic hematuria and pyuria, though the complete blood count and kidney function tests were normal. Based on these results, we diagnosed the presence of a foreign metallic wire in the bladder, which had led to the formation of secondary phosphate stones around it.

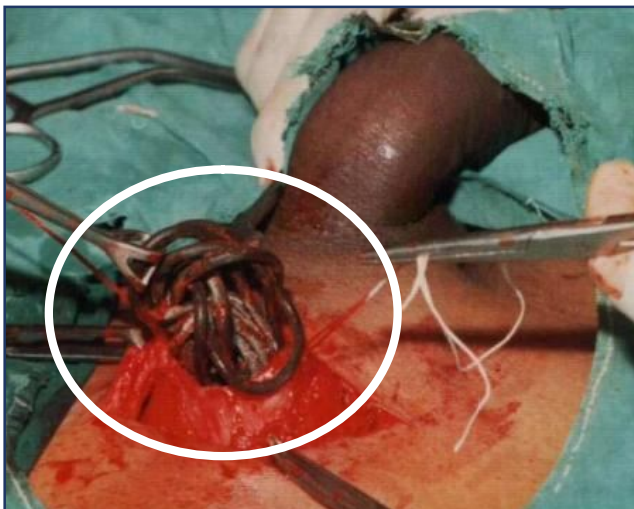
We opted for a suprapubic cystostomy under spinal anaesthesia to remove the 40 cm electrical wire. Postoperatively, the patient recovered well and was discharged on the eighth day. Although psychiatric evaluation was recommended, the patient declined further assessment. **(Fig 1-4)**



**Fig 1.-Plain x-ray KUB showed, coiled metallic wire in the pelvis**



**Fig 2.-Intraoperative photograph showing suprapubic cystostomy with extraction of electrical wire**



**Fig 3.-Intraoperative photograph showing suprapubic cystostomy with extraction of electrical wire**

**Fig 4.- Photograph showing 40 cm electrical wire**

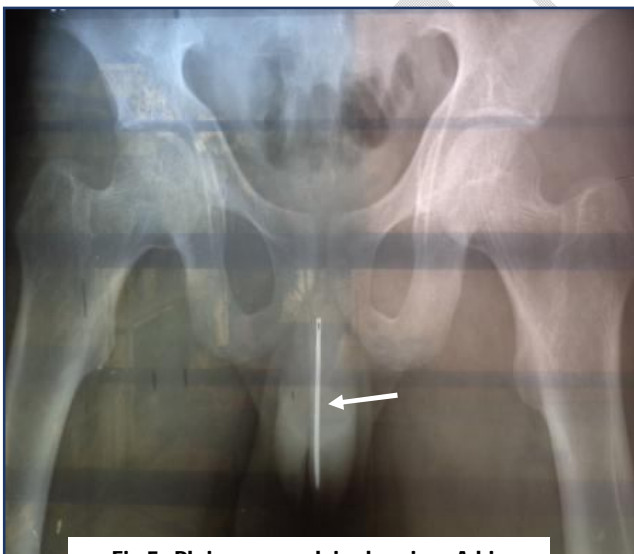### **Case II – A Big sewing needle impacted in the urethra**

A 17-year-old boy with a history of mental disability was admitted to our centre on October 6, 2021, after self-inserting a sewing needle into his urethra. He was brought in by his parents with complaints of fresh hematuria and urethral pain. On physical examination, the boy appeared mentally disabled, and further evaluation revealed a long sewing needle lodged in the urethra.

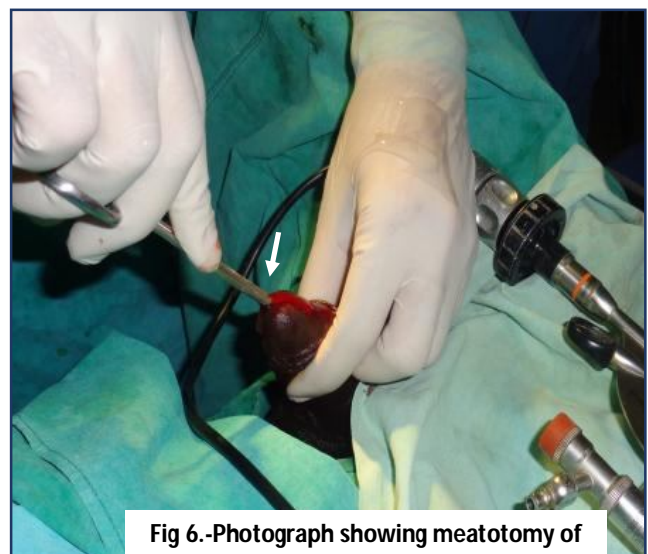Radiological imaging, an X-ray (KUB), and pelvis, confirmed the presence of a large metallic foreign body, specifically a sewing needle, impacted in the urethra. During the physical exam, the needle was palpable on the ventral side of the penile shaft, and laboratory tests showed normal results.

Under general anaesthesia, a urethral cystoscopy was performed, revealing small mucosal abrasions in the pendulous and bulbar urethra. The cystoscope was advanced into the urethra, where a 10 cm sewing needle was found, with the blunt end (eye-side) embedded in the proximal urethra and the sharp tip pointing toward the distal end. Using forceps, the needle was successfully grasped and completely removed through the cystoscope.

Postoperatively, the patient was able to void normally and was discharged the following day without complications. The needle was measured to be 10 cm long, with a blunt eye on one end and a sharp, pointed tip. **(Fig 5-10)**



**Fig 5.-Plain x-ray pelvis showing, A big sewing needle in the urethra**



**Fig 6.-Photograph showing meatotomy of penile urethra**

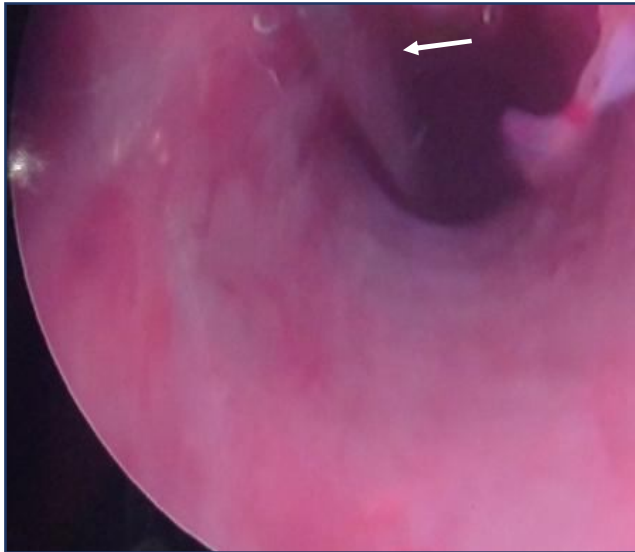


Fig 7.-Photograph showing cystoscopic of urethra with metal foreign body

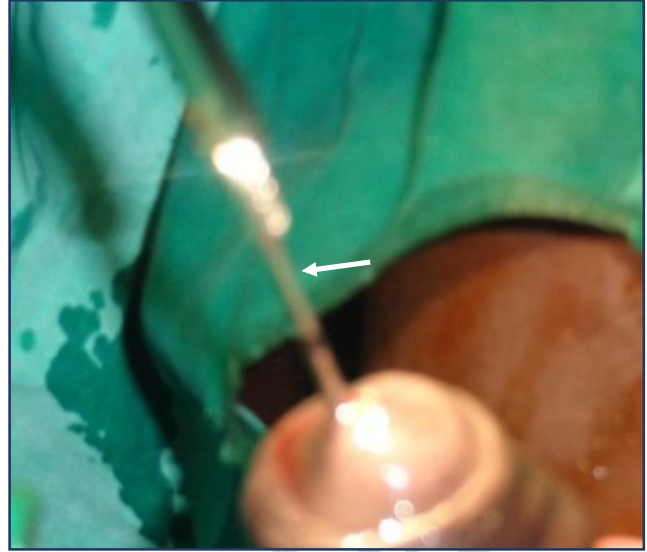


Fig 8.-Intraoperative Photograph showing cystoscopic removal of foreign body

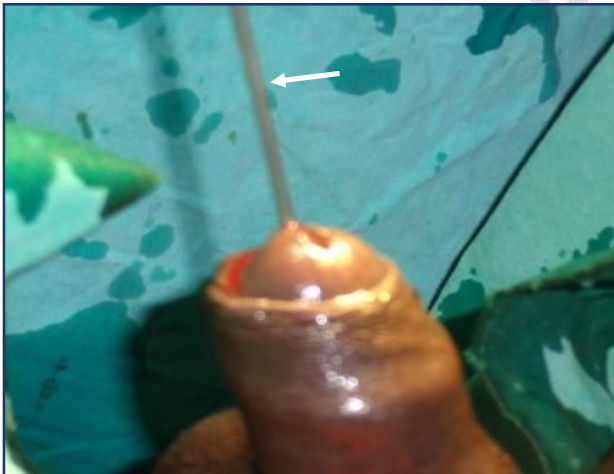


Fig 9.-Intraoperative Photograph showing cystoscopic removal of foreign body



Fig 10- Photograph showing 10 cm big sewing needle

### Discussion

Causes of foreign bodies in the lower urinary tract include psychological factors and iatrogenic incidents during urological procedures. Psychologically, reasons may involve exotic impulses, mental

illness, sexual curiosity, or practices related to sexual gratification, such as masturbation and autoerotic behaviour. [2,7,8]

The urethra is the primary entry point for foreign bodies inserted into the urinary tract. These objects often migrate into the urinary bladder due to being pushed further or through perineal muscle contractions, particularly in about 20-25% of cases involving an erect penis. [1,2,10]

Radiological evaluation is essential to determine the size, number, and location of the foreign body. In most cases, a pelvic radiograph is sufficient for identifying and locating the object. If further clarification is needed, CT scans or ultrasonography can be helpful. [1,4,5]

### **Clinical Management:**

1. **Initial Steps:** The first step in managing these cases is to determine the location, size, and nature of the foreign object. If the object is small, mobile, and palpable in the distal urethra, manual extraction can be attempted. The use of forceps or graspers may help reduce trauma to the urethra. [2,8,9]
2. **Endoscopic Management:** Minimally invasive procedures, such as cystoscopy, are preferred to minimize bladder and urethral injuries. Cystoscopy provides precise visualization of the foreign body and allows for its removal in about 80% of cases. It is considered a safe and effective method for foreign body retrieval. [9,10]
3. **Open Suprapubic Cystostomy:** This procedure is the ideal treatment for foreign bodies in the urinary bladder, especially when secondary bladder stones have formed due to prolonged retention of the object. While the primary goal is foreign body removal, the potential for short- and long-term complications, such as urethral strictures, fistulas, diverticula, erectile dysfunction, and incontinence, must be considered. [6,7]

If a foreign body remains in the urinary tract for an extended period, complications such as infection, stone formation, or fistula development can occur. Psychiatric consultation should be considered in these cases to prevent future attempts of foreign body insertion. [1,2,3]

### **Conclusion**

Foreign bodies in the urethra and urinary bladder represent a rare urological emergency. Endoscopic management has a high success rate and offers the advantage of minimizing injuries to the urethra and bladder. However, in certain cases, an open procedure such as suprapubic cystostomy may be necessary depending on the nature and complexity of the foreign body. Lastly, psychiatric evaluation is recommended to prevent recurrence of such incidents.

### **Disclaimer (Artificial intelligence)**

#### **Option 1:**

**Author(s) hereby declare that NO generative AI technologies such as Large Language Models (ChatGPT, COPILOT, etc.) and text-to-image generators have been used during the writing or editing of this manuscript.**

#### **Option 2:**

Author(s) hereby declare that generative AI technologies such as Large Language Models, etc. have been used during the writing or editing of manuscripts. This explanation will include the name, version, model, and source of the generative AI technology and as well as all input prompts provided to the generative AI technology

Details of the AI usage are given below:

1.

2.

3.

#### **Ethical Approval:**

As per international standards or university standards written ethical approval has been collected and preserved by the author(s).

#### **Consent**

As per international standards or university standards, patient(s) written consent has been collected and preserved by the author(s).

#### **References**

1. Palmer CJ, Houlihan M, Psutka SP, Ellis KA, Vidal P, Hollowell CM. Urethral Foreign Bodies: Clinical Presentation and Management. *Urology*. 2016 Nov;97:257-260. doi: 10.1016/j.urology.2016.05.045. Epub 2016 May 31. PMID: 27261182.
2. Moon SJ, Kim DH, Chung JH, Jo JK, Son YW, Choi HY, Moon HS. Unusual foreign bodies in the urinary bladder and urethra due to autoerotism. *Int Neurourol J*. 2010 Oct;14(3):186-9. doi: 10.5213/inj.2010.14.3.186. Epub 2010 Oct 31. PMID: 21179338; PMCID: PMC2998407
3. Krishanth Naidu, Amanda Chung, Maurice Mulcahy, An unusual urethral foreign body, *International Journal of Surgery Case Reports*, Volume 4, Issue 11, 2013
4. AmirrezaFotovat, Samira Yavari, Mohsen Ayati, Mohammad Reza Nowroozi, Laleh Sharifi, A case report of a self-inserted foreign body in the urethra/bladder causing urinary calculus formation, and a review of the literature, *Heliyon*, Volume 9, Issue 3, 2023, <https://doi.org/10.1016/j.heliyon.2023.e14038>.
5. Bo Yang, Ying Ke, Aixin Qiu, Lijie Wen, Xiaolong Xv, Xiaoyun Liu, Yue Zhang, Migrating foreign bodies of penis: a case report and literature review, *Basic and Clinical Andrology*, 10.1186/s12610-024-00224-3, 34, 1, (2024).

6. Li, Yubing MD\*; Gao, Yunqiu MD; Chen, Xiangdong PhD; Jiang, Shaobo MD. Rare foreign body in bladder: A case report. *Medicine* 97(17):p e0519, April 2018. | DOI: 10.1097/MD.0000000000001051
7. Kong, X.; Wei, C. Clinical Features and Management of Urethral Foreign Bodies in Children: A 10-Year Retrospective Study. *Children* 2022, 9, 1468. <https://doi.org/10.3390/children9101468>
8. Üntan, i; Ersekerici, E. A Sewing Needle as a Urethral Foreign Body: A Case Report and Literature Review. *Nigerian Journal of Clinical Practice* 26(10):p 1588-1590, October 2023. | DOI: 10.4103/njcp.njcp\_168\_23
9. Tuncer H, Karacam H, Cam B (July 11, 2021) A Self-Inserted Foreign Body in the Urinary Bladder and Urethra. *Cureus* 13(7): e16322. doi:10.7759/cureus.16322
10. Stravodimos, K.G., Koritsiadis, G. &Koutalellis, G. Electrical wire as a foreign body in a male urethra: a case report. *J Med Case Reports* 3, 49 (2009). <https://doi.org/10.1186/1752-1947-3-49>