

Original Research Article

Studies on diagnostic and surgico-therapeutic management of perineal tumours in dogs

Abstract

The study was conducted on 11 cases of perineal tumour, it was observed that intact male dogs were more predisposed to the condition and Indian Spitz was most commonly affected breed. Varying size of perineal tumours were recorded along with anorexia, faecal and urinary incontinence as common clinical signs. Castration was performed in intact male dogs. 2-4 weeks after the castration, surgery was performed for tumour excision in 9 dogs and in 2 dogs suffered from venereal granuloma, the growth was regressed by administration of chemotherapeutic agent inj. Vincristine sulphate I/V once in a week. In the haematological studies, there was significant decrease in neutrophil and increase in lymphocyte and monocyte count. Biochemical parameters indicated a non-significant decline. In cytological and histopathological analysis, it was confirmed that 5 dogs had perianal adenoma, 2 had perianal epithelioma, 2 had venereal granuloma, 1 had anal gland adenoma and 1 had adenocarcinoma.

Keywords: Perineal tumour, venereal granuloma, cytological, histopathological, adenoma

Introduction

Perianal adenomas appear as slow-growing, non-painful masses around the anus. They can arise as single, multiple or diffuse masses. Occasionally, they will be ulcerated and infected on their surface. Dogs frequently develop perineal tumours and the two most common tumours are perianal gland adenoma and anal sac adenocarcinoma. Due to their histological similarities to hepatocytes, perianal glands are also known as hepatoid glands. The benign form comprises more than 80% of the perianal tumours and is third most common tumour in male dogs [1]. The biological behaviour of these tumours varies greatly and they are typically benign or occasionally malignant [2]. As compared to female dogs, intact males are at high risk [3]. Treatment comprises removal of tumour surgically concomitant with orchietomy. In adult and elderly male dogs, androgenic stimulation causes hyperplasia and neoplastic transformation of the hepatoid glands [4].

Canine transmissible venereal tumour (CTVT) is most commonly found in young sexually mature stray dogs with uncontrolled reproductive activity and typically resembles a cauliflower which is friable and ranges in colour from red to flesh. The disease is horizontally transmissible from male to female during breeding among affected animals or vice-versa [5]. For confirm diagnosis of tumours, cytology and histopathology are helpful procedures that are typically utilized [6].

The present study was conducted to diagnosis the type of perineal tumour and their surgico-therapeutic management.

Material and Methods

The present study was conducted in eleven dogs presented with perineal tumour at Veterinary Clinical Complex (VCC), College of Veterinary Science and Animal Husbandry, Mhow from June, 2022 to February, 2023. Their age, sex, breed,

size of tumour and clinical history was recorded. Clinical, physical, radiographic and ultrasonographic examination of affected dogs was also done accordingly.

In uncastrated male dogs first castration was done 2-4 weeks before excision of tumour via open prescrotal castration method.

For haemato-biochemical examination parameters including Total erythrocyte count (TEC) (million/ μ l), Packed cell volume (PCV) (%), Total leukocyte count (TLC) (thousand/ μ l), Haemoglobin (Hb) (g/dl), Differential leukocyte count (DLC) (%), Aspartate transaminase (AST) (IU/L), Alanine aminotransferase (ALT) (IU/L), Blood urea nitrogen (BUN) (mg/dl) and Creatinine (mg /dl) were on 0 day (on the day of presentation of animal) and 7th day (after therapeutic management or surgery).

Dogs were prepared aseptically at the site of perineal region and operated under general anaesthesia using inj. Atropine sulphate @ 0.02–0.04 mg/kg b.wt. and inj. Xylazine @ 0.5-1 mg/kg b.wt. I/M as preanesthetic followed by inj. Ketamine @ 5-10 mg/kg b.wt. I/V for induction. Anaesthesia was maintained by combination of inj. Diazepam and inj. Ketamine in 1:1 (volume:volume) ratio I/V as and when required.

For removal of tumour, dogs were positioned in ventral recumbency with elevated hindquarter and tumour was dissected from subcutaneous tissue and external anal sphincter with minimal trauma. The skin was sutured and tumour was then sent for histopathological examination.

Antibiotic inj. Ceftriaxone @ 20 mg/kg b.wt. I/M, BID and analgesic inj. Meloxicam @ 0.2 mg/kg b.wt. I/M, OD were given for 7 days and 3 days respectively. Antiseptic dressing was done and owner was advised to feed the dog

with laxative diet. Skin sutures were removed at 10-12th day postoperatively as per healing.

In cases of venereal granuloma of perineal region cytological examination was done by taking fine needle aspirate from the tumour tissue. For regressing the growth administration of inj. Vincristine sulphate was done on weekly basis and side effects were managed symptomatically.

The data was analysed by using Complete Randomized Design (CRD) and paired 't' test as per the standard procedure outlined by Snedecor and Cochran, 1994 [7].

Results and Discussion

In the present study period, 11 cases of perineal tumour were recorded. The occurrence of perineal tumour was more in age group of more than 6 years (10 dogs) and only one case was of less than 6 years of age. Males (8 dogs) were presented more with perineal growth as compared to females (3 dogs). The occurrence of perineal tumour was noticed more in Indian Spitz (4 dogs) followed by Mongrel (3 dogs), Labrador (3 dogs) and Golden Retriever (1 dog) during the observation period (Table 1).

Similarly, Shabeeba *et al.* (2021) [8] also concluded that males with mean age of 9.8 years were more predisposed to the condition. Madheswaran *et al.* (2021)[9] and Kokila *et al.* (2016) [10] also presented similar results.

The high risk for development of perianal adenomas is found in aged and intact males due to androgen dependency [11] as hyperplasia and neoplastic transformation of hepatoid glands is induced by androgenic stimulation in aged male

dogs [4]. The steroid sex hormones suggested to stimulate the proliferation of perianal gland tumours by acting as local growth factors [12]. Pisani *et al.* (2006) [13] also reported that presence of immunohistochemical expression of androgen receptors is higher in hepatoid gland tumours.

In the present study, Indian Spitz were found to be most predisposed to perineal tumours. Batra (2001) [14] also reported similar findings during management of perianal tumours in 10 dogs while contrary to these findings Kokila *et al.* (2016) [10] revealed highest incidence of anal tumours in German Shepherd. Tozonet *al.* (2005) [1] reported that Mongrels were mostly predisposed while number of tumour nodules were maximum in German Shepherd breed of dog. However the predisposition of certain breed depends on availability of different breeds in a particular geographical location.

Varying size of perineal tumours were recorded on the basis of visual examination which revealed three dogs had large sized growth (approximately more than 10 cm), three had moderate sized growth (approximately 5-10 cm) and five dogs had small sized growth (approximately less than 5 cm). In two dogs, the tumourous growth was ulcerated and in one dog growths were multiple in number. Most of the dogs (10 dogs) were presented with clinical sign of biting at perineal region. Anorexia was reported in five dogs, faecal incontinence in four dogs, urinary incontinence in two dogs and haematochezia was present in two dogs (Table 01, Table 02,).

Resultsof present study are in agreement of Shabeebaet *al.* (2021) [8] who mentioned clinical history of perianal growth, loss of appetite, faecal incontinence, severe itching, haemorrhages and ulcers on perineal region during her study on hapatoid gland tumours in five dogs. Similarly, Kokila *et al.* (2016)

[10]mentioned common clinical signs like swelling in perineal area, anorexia, bloody discharge, biting perineal area, discomfort, weight loss, ulceration, tail lifting, lethargy, dysuria, constipation, necrosis and dyschezia in affected dogs which is consistent with the present findings. Devi *et al.* (2012) [15] also mentioned lesions of varying size from nodules to large ulcerated and haemorrhagic forms which compressed the anal opening, leading to difficulty in defecation.

Table 1: Signalment of the dogs affected with perineal tumour (n=11)

Case No.	Age (years)	Sex	Breed	Type of tumour	Size of tumour
1.	03	M	Mongrel	Perianal adenoma	Large
2.	13	F	Labrador	Anal sac gland adenoma	Moderate
3.	08	M	Labrador	Perianal adenoma	Small
4.	14	M	Indian spitz	Perianal epithelioma	Small
5.	09	M	Labrador	Perianal adenoma	Large
6.	13	F	Indian spitz	Perianal adenoma	Moderate
7.	15	M	Indian spitz	Perianal adenocarcinoma	Moderate
8.	15	M	Mongrel	Perianal epithelioma	Small
9.	10	M	Mongrel	Perianal adenoma	Large
10.	08	M	Golden Retriever	Venereal tumour	Small (Multiple)
11.	06	F	Indian spitz	Venereal tumour	Small

Table 02: Clinical signs in dogs affected with perineal tumour (n=11)

S. No.	Clinical signs	No. of dogs
1.	Biting of perineal region	10
2.	Anorexia	5
3.	Faecal incontinence	4
4.	Haematochezia	2
5.	Urinary incontinence	2
6.	Ulceration of tumourous mass	2

The anaesthetic protocol and animal preparation was satisfactory for all the dogs. Analgesia, muscle relaxation was noticed to be adequate for the surgical procedure and all the dogs recovered post-operatively.

Castration was performed in 5 intact male dogs as mentioned in material method. After the castration, surgery was performed for tumour excision as per standard protocol in 9 dogs. While excision, the major complication was bleeding in some cases although it was managed.

Kokila *et al.* (2016) [10] also considered surgical excision as the routine therapy. The preferred course of treatment for intact male dogs with perianal adenoma, according to Thomas and Fox (1998) [16], is to remove the tumour and neuter the dog, which can reduce recurrence rates by 95% as castration eliminates the major source of testosterone. Generally, neutering of male dogs early in life will help to prevent the development of perianal adenomas, adenocarcinomas and other such type of growths. Wilson and Hayes (1979) [17] also opined that perianal adenomas

generally occurred in tissues around the rectum that were responsive to androgens, hence castration resulted in regression of the tumour as Pisani *et al.* (2006) [13] also reported that presence of immunohistochemical expression of androgen receptors is higher in hepatoid gland tumours.

As per clinical and cytological examination, 2 dogs were treated by chemotherapeutic agent, inj. Vincristine sulphate @ 0.025 mg/kg b.wt. I/V on weekly basis. One dog was treated for 2 weeks and the other one for 3 weeks. The reduction in growth was noticed in both the dogs after one week and complete resolution of growth occurred in 2 weeks in one dog and 3 weeks in other dog. Vomition and anorexia were noticed in dogs during chemotherapeutic treatment but managed accordingly without any serious complication.

Anusha *et al.* (2022) [5] reported in her study on canine transmissible venereal tumours that when a group of 6 dogs treated with inj. Vincristine @ 0.025 mg/kg b.wt. mixed with normal saline and administered I/V once in a week, showed appreciable tumour regression within 4-6 weeks which is in agreement with the present study. The vincristine was potent in the treatment of canine transmissible venereal tumour (CTVT) which showed complete regression of tumours with some side effects like vomition and anorexia.

Antibiotic and analgesic were given for 7 days and 3 days respectively. Antiseptic dressing was done for 2 weeks on daily basis and sutures were removed on 10-12th day post-operatively as per healing. Laxative diet was advised to owners for all the dogs. In two dogs wound dehiscence was observed on 3rd and 5th day respectively after the surgery which was corrected by resuturing of the wound. Wound dehiscence was the common post-operative complication due to self-

mutilation, negligence of owner, mobility during defaecation and difficulty in bandaging due to anatomical position. In most of the dogs, slight faecal incontinence was also noticed and managed by laxative drugs and diet.

The mean values of haemoglobin, packed cell volume, total erythrocyte count and leukocyte count decreased non-significantly on 7th day as compared with the pretreatment 0 day. In differential leukocyte count statistically, there was significant decrease in neutrophil while increase in lymphocyte and monocyte count. Although, the values of both the days were within normal physiological range. There was non-significant changes seen in the mean values of eosinophil and basophil (Table 03).

Madheswaran *et al.*(2021) [9] revealed that haematological parameters of the affected dogs did not show any significant changes for total erythrocyte count, haemoglobin and total leukocyte count. Kumar *et al.* (2018) [18] also reported non-significant decrease of mean haemoglobin, packed cell volume and total erythrocyte count with insignificant alteration of leukocyte count. These findings are in accordance with the present study. Javanbakht *et al.* (2013) [19] also revealed similar findings in his study on anal sac adenocarcinoma tumour in a Spitz dog.

Table 03: Mean values (\pm SE)of haematological parameters in dogs affected with perineal tumour (n=11)

Interval (days)	Hb (g/dl)	PCV (%)	TEC (million/ μ l)	TLC ($10^3/\mu$ l)	DLC(%)				
					Neutrophil	Lymphocyte	Monocyte	Eosinophil	Basophil
0	13.80 \pm 0.20	41.40 \pm 0.62	6.90 \pm 0.10	13.66 \pm 0.20	71.81 ^a \pm 0.48	19.45 ^a \pm 0.52	5.45 ^a \pm 0.24	1.90 \pm 0.25	1.20 \pm 0.19
7	13.62 \pm 0.20	40.88 \pm 0.62	6.81 \pm 0.10	13.15 \pm 0.22	68.27 ^b \pm 0.60	22.36 ^b \pm 0.41	6.00 ^b \pm 0.23	2.00 \pm 0.19	1.36 \pm 0.15

Mean value with different superscripts differ significantly (p<0.05) within days.

The mean values of blood urea nitrogen, creatinine, alanine aminotransferase and aspartate transaminase showed non-significant decrease at 7th day as compared to day 0 (Table 04).

Kokila *et al.* (2016) [10] also reported that the mean values of blood urea nitrogen and creatinine were within the normal range in the dogs with anal tumours throughout the study period which is in complete agreement of the present study. Similar observations were also recorded by Madheswaran *et al.*(2021) [9]and Kumar *et al.* (2018) [18] during their study period.

Table 04: Mean values (\pm SE)of biochemical parameters in dogs affected with perineal tumour (n=11)

Interval (days)	BUN (mg/dl)	Creatinine (mg/dl)	ALT (IU/L)	AST (IU/L)
0	22.13 \pm 0.59	1.26 \pm 0.04	36.10 \pm 0.92	34.71 \pm 1.08
7	21.86 \pm 0.58	1.17 \pm 0.04	35.41 \pm 1.01	33.76 \pm 1.04

Radiographs were taken in two dogs to analyze the extent of tumour. No other organs were found to be suppressed by the tumourous mass. Ultrasonography was also done in two dogs to determine the nature of perineal swelling and hyperechoic image confirmed the swelling as tumorous growth. The swelling was found to be only in the subcutaneous area without any warranted suppression of the nearby organs(Fig. 01, Fig. 02).

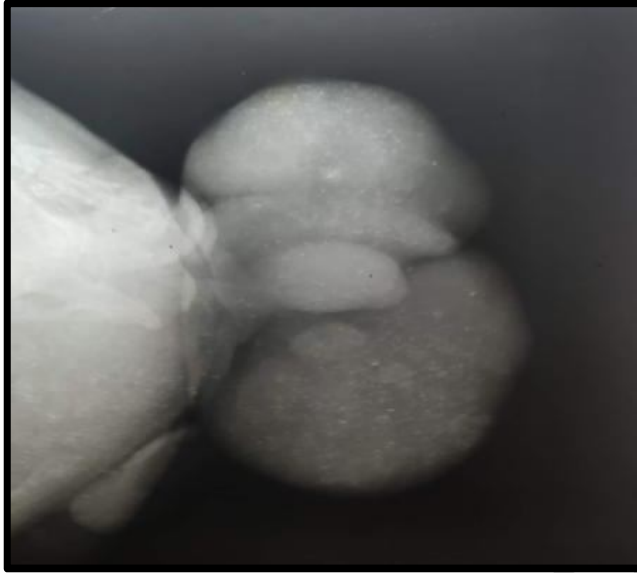


Fig. 01: Radiographic image of perineal tumour

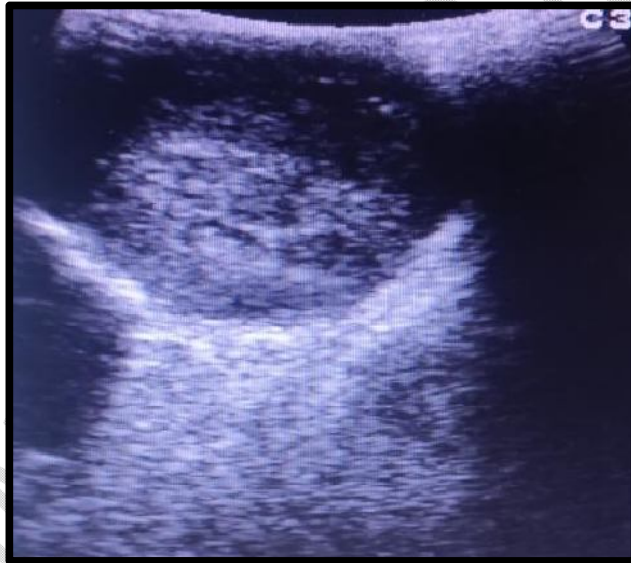

Fig. 02: Ultrasonographic image of perineal tumour

Kokila (2011) [10] observed that radiographs of animals suffering with perineal tumours showed soft tissue swelling in urogenital perineal region which is in consonance of the present study.

Fine needle aspirate was taken in two dogs for cytological study, they were diagnosed as venereal granuloma of perineal region with oval to round shaped nucleus, clear cytoplasmic vacuoles (Fig. 03, Fig. 04).

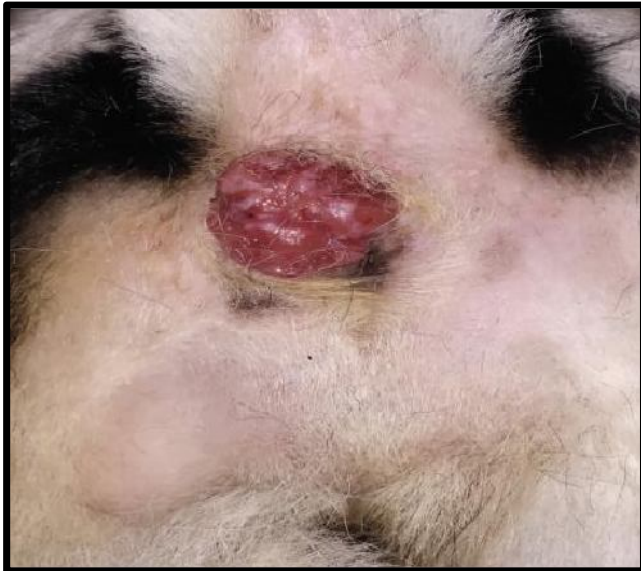

Fig. 03: Gross appearance of venereal granuloma of perineal region.

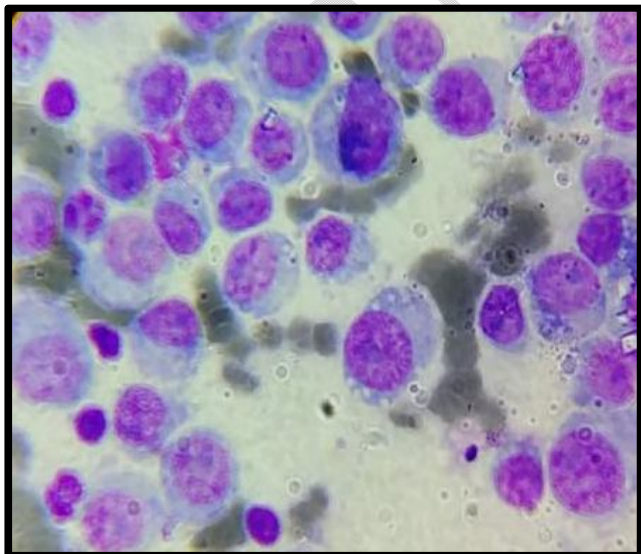


Fig. 04: Cytology of venereal granuloma showing oval to round shaped cells and clear cytoplasmic vacuoles.

The present study is in agreement with Anusha *et al.* (2022) [5]; Thangathuria *et al.* (2008) [20]; Purohit (2009) [21] and Tella *et al.* (2004) [22] who also observed similar presence of clear cytoplasmic vacuoles in CTVT affected dogs.

Histopathological study was performed in 9 dogs for confirmatory diagnosis and revealed that 5 dogs were affected with perianal adenoma characterized by discrete bundles of large and round neoplastic cells which were round to polygonal in shape and appeared as packed hepatocytes, 1 dog with anal sac gland adenoma characterized with proliferation of hepatocytes like hepatoid cells, 2 dogs with perianal epithelioma characterized by presence of basaloid reserve cells with some hepatocyte like cells, 1 dog with perianal adenocarcinoma characterized grossly as firm and ulcerated while microscopically, revealed marked pleomorphic cells with multinucleated giant cells (Fig. 05, Fig 06, Fig. 07, Fig 08).

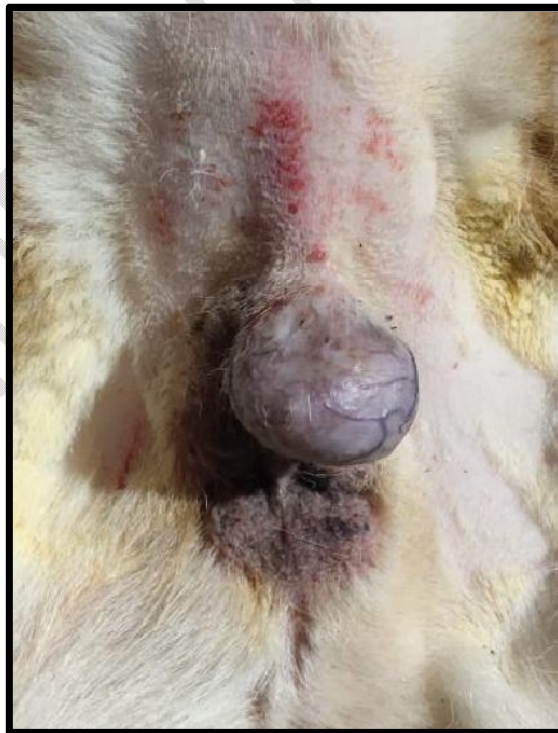


Fig. 05: Gross appearance of perianal adenoma

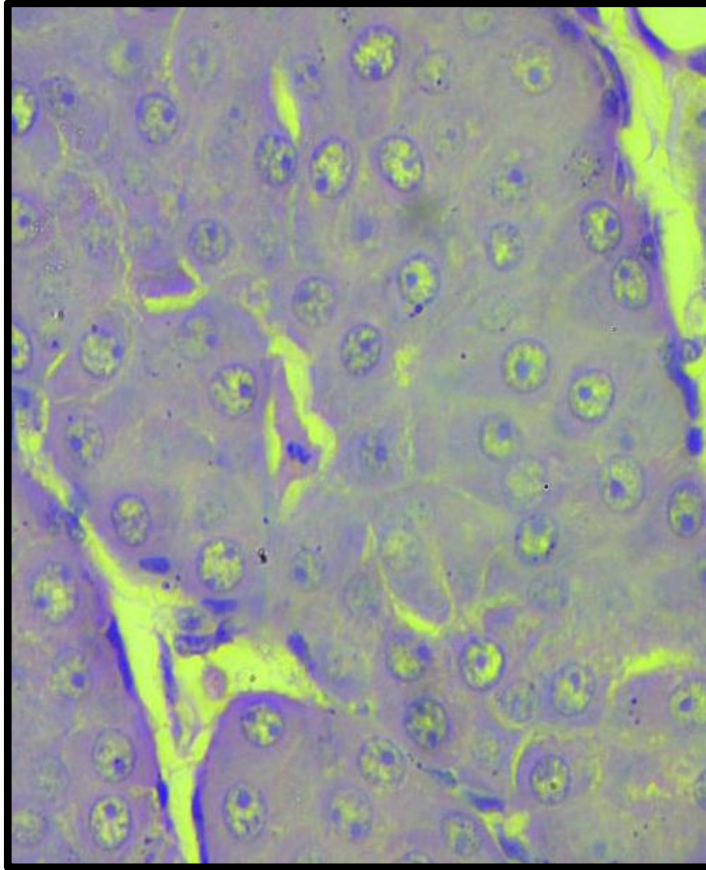


Fig. 06: Histopathology of perianal adenoma showing hepatoid cells with vesicular nucleus

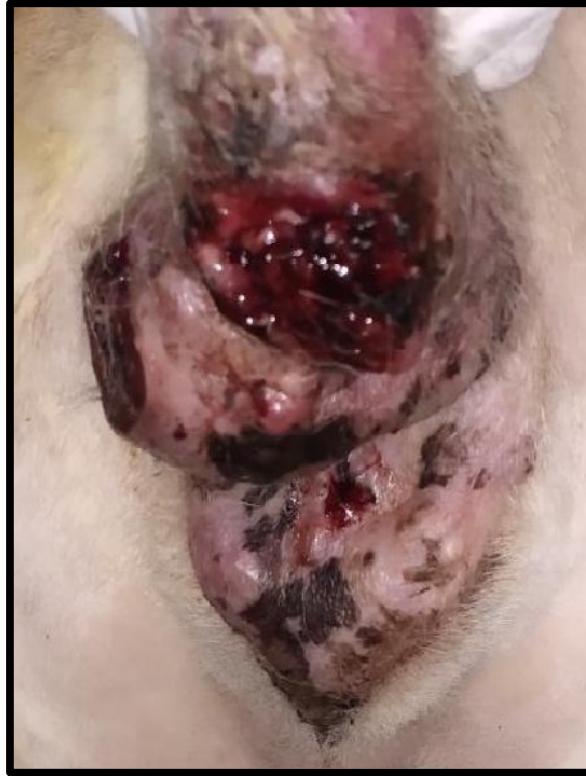

Fig. 07: Gross appearance of anal gland adenocarcinoma.

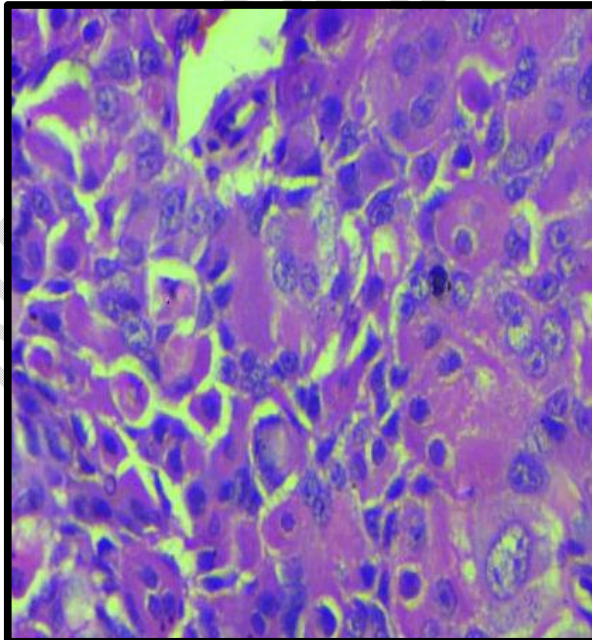


Fig. 08: Histopathology of anal gland adenocarcinoma showing multinucleated giant cells.

Madheswaran *et al.* (2021) [9] also confirmed histopathologically, 6 cases of adenoma and 3 cases of adenocarcinoma during clinico-pathological study in perianal gland tumours of nine dogs which is in close agreement of histopathological analysis of present study. The histopathological features of perianal gland tumours obtained in the present study are also in accordance with Meuten (2017) [2]; Trangadia (2014) [20] and Pereira *et al.* (2013) [23]. Shabeeba *et al.* (2021) [8] also confirmed histopathologically, presence of hepatoid gland adenoma in two cases, hepatoid gland epithelioma in one case and two cases of adenocarcinoma during her study of canine hepatoid gland tumours in five dogs which is also in close agreement of the present study on perianal tumours.

Conclusion

The present study concluded that most common perineal tumour was perianal adenoma and could be managed successfully along with confirm histopathological diagnosis after removal of the tumour.

References:

1. Tozon N, Kodre V, Sersa G, Cemazar M. Effective treatment of perianal tumors in dogs with electrochemotherapy. *Anticancer Res.* 2005;25(2):839-845.
2. Meuten DJ. *Tumors in domestic animals.* 5th ed. Iowa State Press, USA: A Blackwell Publishing Company; 2017.
3. Dernell WS. Perianal tumours. In: 19th The North American Veterinary Conference Proceedings, Orlando, Florida, 8-12, January 2005, Eastern States Veterinary Association. 2005;254-255.

4. Brodzki A, Lopuszynski W, Millan Y, Tataro MR, Brodzki P, Kulpa K, Minakow N. Androgen and estrogen receptor expression in different types of perianal gland tumors in male dogs. *Animals*. 2021;11(3):875.
5. Anusha A, Ramana KV, Reddy KCS, Swathi B. Studies on transmissible venereal tumour (TVT) in canines. *J Pharm Innov*. 2022;11(6):1544-1547.
6. Choi EW. Deep dermal and subcutaneous canine hemangiosarcoma in the perianal area: Diagnosis of perianal mass in a dog. *BMC Vet Res*. 2019;15(1):1-5.
7. Snedecor GW, Cochran WG. *Statistical Method*. 7th ed. New Delhi: Oxford and IBH Publishing Co; 1994:312-317.
8. Shabeeba PM, Sajitha IS, Devi SS, Divya C, Nair SS. Histopathological study of canine hepatoid gland tumours. *J Vet Anim Sci*. 2021;52(3):277-280.
9. Madheswaran R, Prabhakaran KP, Srinivasan P, Balasubramaniam GA, Balachandran P, Sasikala M, et al. Clinico-pathological studies and immunohistochemical expression of hormonal receptors in perianal gland tumors of dogs. *Indian J Vet Pathol*. 2021;45(3):190-194.
10. Kokila S, Veena P, Kumar RV, Srilatha C. Clinical studies on anal tumors in dogs. *Indian J Anim Res*. 2016;50(4):629-631.
11. Withrow S, Vail D, Page R. *Withrow and MacEwen's Small Animal Clinical Oncology*. 5th ed. Philadelphia, U.S.A.: WB Saunders; 2012:164-173.
12. Kaldrymidou H, Leontides L, Koutinas AF, Saridomichelakis MN, Karayannopoulou M. Prevalence, distribution and factors associated with the presence and the potential for malignancy of cutaneous neoplasms in 174 dogs admitted to a clinic in northern Greece. *J Vet Med Series A*. 2002;49(2):87-91.

13. Pisani G, Millanta F, Lorenzi D, Vannozzi I, Poli A. Androgen receptor expression in normal, hyperplastic and neoplastic hepatoid glands in the dog. *Res Vet Sci.* 2006;81(2):231-236.
14. Batra P. Chemotherapeutic and surgical management of perineal affections in dogs. M.V.Sc. thesis (Surgery and Radiology), Punjab Agricultural University, Ludhiana; 2001.
15. Devi LG, Choudhari A, Singh ND, Banga HS, Gadhave PD. An incidental case of perianal gland adenoma in a stray dog. *Sci J Anim Sci.* 2012;1(2):71-74.
16. Thomas RC, Fox LE. Tumors of the skin and subcutis, perianal (hepatoid) gland tumors. In: Morrison WB, editors. *Cancer in Dogs and Cats.* Baltimore: Williams & Wilkins; 1998:497-498.
17. Wilson G, Hayes H. Castration for treatment of perianal gland neoplasms in the dog. *J Am Vet Med Assoc.* 1979;174:1301-1303.
18. Kumar AV, Kumari NK, Kumar SK, Gireesh V, Kumar S, Lakshman M. Hemato-biochemical changes in perianal tumors affected dogs. *The Pharma Innovation Journal.* 2018;7(3):25-27.
19. Javanbakht J, Tavassoli A, Sabbagh A, Hassan MA, Samakkhah SA, Shafiee R, et al. Evaluation of an anal sac adenocarcinoma tumor in a Spitz dog. *Asian Pac J Trop Biomed.* 2013;3(1):74-78.
20. Trangadia BJ, Patel JM, Vihol PD, Prasad MC, Suthar DN, Tyagi SK. Pathology of perianal gland tumors in dogs. *Indian J Vet Pathol.* 2014;38:122-123.
21. Purohit GN. Canine transmissible venereal tumor: A review. *The Internet J Vet Med.* 2009;6(1):1-10.

22. Tella MA, Ajala OO, Taiwo VO. Complete regression of transmissible venereal tumor (TVT) in Nigerian mongrel dogs with vincristine sulphate chemotherapy. *African J Biomed Res.* 2004;7(3):133-138.
23. Pereira RS, Schweigert A, de Melo GD, Fernandes FV, Sueiro FAR, Machado GF. Ki-67 labeling in canine perianal glands neoplasms: a novel approach for immunohistological diagnostic and prognostic. *BMC Veterinary Research.* 2013;9(1):1-7.

UNDER PEER REVIEW