

Partial Fetal Maceration in a goat – A case reports

Abstract:

A rare case of fetal maceration in a goats were observed here at teaching veterinary clinical complex, Faculty of Veterinary and Animal Sciences, Banaras Hindu University, Barkachha, Mirzapur. Two distinct cases in goats with different history and clinical signs were effectively handled and uneventful recovery was observed. The details of successful management are discussed in this case article.

Key word: Goat, Fetal maceration, Management, Treatment.

Introduction:

Generally, fetal maceration occurs when endocrine support of pregnancy is lost. Abortion, maceration or mummification leads to fetal death. Abortion may be identified by the presence of the fetus or abnormal vaginal discharge. This condition is more common in cattle and buffalo than mare and caprine (Noakes *et al.*, 2009, Bashiru *et al.*, 2020, Rautela *et al.*, 2016, Purohit *et al.*, 2011). Fetal maceration observed when fetus unable to abort and decompose itself in a uterus resulting in remaining of fetal bone in the reproductive tract and causes further fertility complications (Noakes *et al.*, 2019). Fetal maceration and fetal emphysema results in fetal mortality post development of fetal skeleton in which cervix is partially or completely dilated, putrefaction and dissolution of soft tissue due to ascending infections (Kumar *et al.*, 2007). This obstetrical condition may be caused by variety of microorganism found in the uterus. Microorganisms enter into uterus via dilated or partially dilated cervix, soft tissue of the fetus or embryo digested by combination of putrefaction and autolysis (Mehta *et al.*, 2005). In case of sheep and goats, enzootic abortion caused due specifically a bacteria *Chlamydia abortus* Stamp *et al.*, (1950). Another most common cause of abortion, embryonic mortality, stillbirths is *Toxoplasma gondii*. (Noakes *et al.*, 2019). *Listeria monocytogene*, *Chlamydomphila abortus*, *Brucella melitensis*, *Coxiella burnett*, *Mycoplasma spp*, *Leptospiraspp*, *Salmonella abortus-ovisc*, *Campylobacter spp.*, *Toxoplasma gondi*, *Sarcocystis*, *Akbane virus*, *Caprine herpesvirus*, *Border disease virus* involves in abortion, still birth, fetal mummifications, fetal maceration (Daniel Givens and Marley 2008).

Case 1:

History

A primiparous black bangal doe came to the Teaching Veterinary Clinical Complex (TVCC), Faculty of Veterinary and Animal Sciences (FVAS), Banaras Hindu University (BHU), Barkachha, Mirzapur with the history of pregnant of 2 ½ months. Placenta hanging out through vaginal passage. Reduced feed intake, Mucopurulent vaginal discharge with foul smell. Noted rectal temperature was 105 °F. Animal was slightly dull and depressed.

Materials and Methods:

Animal was stabilized by giving some fluid therapy. Externally the placenta hanging out of the vaginal passage was dried, removed gently with gloved hand. Afterwards the tail hairs were trimmed and vaginal passage was cleaned. Vaginal passage was lubricated by applying liquid paraffin and a macerated single fetus was removed. It was unrecognized of gestational period but bone development was observed. Thick mucopurulent, foul smelling vaginal discharge was completely removed from the uterus and intra uterine antibiotics inj. Lenovo AP™ – 20 ml administrated I/U (, inj. Pragma™ 0.5 ml (250 mcg – Cloprostenol sodium) given I/M. The doe was further treated for 5 days with inj. Lenovo AP™- 20 ML I/U (Levofloxacin 20 mg, Ornidazole 40mg, alpha Tocopherol 5mg each ml), inj. Intacef™ 12 mg /kgI/M (Ceftriaxone), . Inj. Melonex™ 1 mg/kg I/M (Meloxicam), Inj. Zeet™ 1 ml I/M (Clorpheniramin maleat), the dam was completely recovered with normal feeding and watering post treatment.

Case 2

History:

A doe aged 2.5 years was presented in Teaching Veterinary Clinical Complex (TVCC), Faculty of Veterinary and Animal Sciences (FVAS), Banaras Hindu University (BHU), Barkachha, Mirzapur with the history of per vaginal mucopurulent discharge from past 10 days. She had been reported with reduced feed and water intake. The vital parameters like rectal temperature noted were 103.4 F, Heart rate 73/min, and respiration rate 28/min.

Materials and Methods:

On per vaginal examination, cervix was found completely open and fetal parts were palpable. With abundant lubrication using CMC (Carboxyl Methyl Cellulose powder) gel, two macerated fetuses were removed which were partially putrefied but bone separation was not observed. The animal was treated

with inj. Pragma™ 0.5 ml I/M (Cloprostenol sodium 125mcg), inj. Melonex™ (Meloxicam 1mg/kg), inj. Enrogil™ 3ml I/M,(Enrofloxacin 2.5 mg/kg), and intra uterine therapy with inj. Lenovo AP™ 20 ml I/U (Levofloxacin 20 mg, Ornidazole 40mg, alpha Tocopherol 5mg each ml) for 5 days. The doe recovered uneventfully.

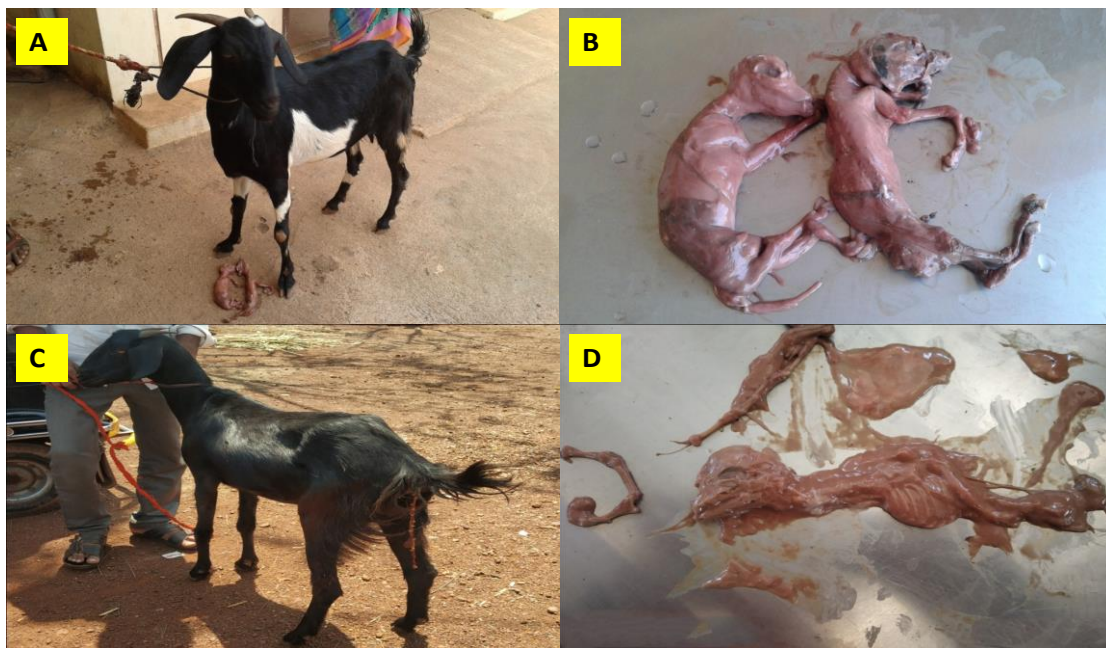


Fig. 1: (A- Dam with fetuses and C-Dam in which placenta is hanging out, B- partially macerated fetuses without separation of bones, D- Macerated fetus with few bone separations).

Discussion:

Case study 1 indicates that there is early gestational fetal maceration in a single fetus. Fetal placenta hanging out of vaginal passage were reddish with necrosed cotyledons might be a reason of *Toxoplasma gondii* in caprine. As fetal maceration can be noticed as early as in 70 days of gestation after bone

development. In the case study 2, fetal maceration noticed in both of the fetuses. The fetal consistency and configuration were observed as partially putrefied with pus filling inside. Bacterial infections can lead to putrefaction, autolysis and uterine damage but viral infections don't cause uterine damage. Maceration may occur at any stage of pregnancy and has been observed in all species. This rare obstetrical condition in goats is more serious and fatal due to the presence of the dead, decomposed fetus (es), failure to dilate cervix and uterine inertia. Severe degenerative and sclerotic changes occurs in endometrium which severely affects the fertility of animal with poor prognosis (Roberts 2004).

Conclusion:

In management of such cases removal of fetal bones and to perform cesarean section to save the life of dam. But here in these case studies it was not a long standing cases it was diagnosed and treated successfully at early stage and dead macerated fetuses were removed. In both the cases to evacuate the uterine content prostaglandin hormone, intra uterine antibiotics along with NSAIDS , Antihistaminic, was given and complete recovery was observed.

References:

Bashiru G, Nura A, Abubakar BH, Ekaete OI, Salisu AU, Rambo GU. Laterogenic uterine perforation resulting in fetal maceration in an ewe. *Research Journal of Veterinary Practitioners*. 2020; 8(2):15-19.

Daniel Givens M, Marley MSD. Infectious causes of embryonic and fetal mortality. *Theriogenology*. 2008; 70: 270-285.

Kumar AG, kuriakose AM, Ghosh KNA, Sreekumaran T. Fetal maceration in a goat. *Indian Journal of Animal Reproduction* 2007; 28: 107-108.

Mehta V, Sharma MK, Bhatt L, Pandey V, Bharti M. Macerated fetus in goat. *Indian Journal Animal Reproduction*. 2005; 26: 75.

Noakes DE, Parkinson TJ, England GCW, Arthur GH. Infertility and sub fertility in the ewe and doe (female goat) in: *Veterinary Reproduction and Obstetrics*. 10th edn, Elsevier Sci Ltd; 2019. 203.

Purohit GN, Gaur M. Etiology, antenatal diagnosis and therapy of fetal complications of gestation in large and small domestic ruminants. *Theriogenology Insight*. 2011; 1:43-62.

Rautela R, Yadav DK, Katiyar, Singh SK, Das GK, Kumar H. Fetal maceration in goat: a case report. *Internal Journal of Science Environment and Technology*. 2016; 5:2323-26.

Roberts SJ. *Veterinary obstetrics and genital diseases* (Theriogenology). 2nd Edt. CBS Publishers and Distributors (Indian reprint), 2004, 174-175.

Stamp JT, Watt JA, Nisbuet DI. Veterinary Record. 1950; 62:251.

UNDER PEER REVIEW