

Histopathological Alterations and Ki-67 Proliferation Index Evaluation following Nitroso bis Amine-Induced Cerebral Toxicity in Experimental Animal Model treated with Curcumin

ABSTRACT

The search for more accurate prediction of biological behavior of brain tumors in experimental neuro-oncology where non-human animal tumor models are involved has been on the increase especially as it relates to its role in evaluating various therapeutic and clinical trials using natural products with anti-cancer properties. An investigation into anti-proliferative effect of curcumin was carried out on nitroso bis amine - induced cerebral injury in animal tumor model by assessing Ki67 proliferating cell marker, necrotic focal points and histopathological alteration. Rats brain tumor models received increasing concentration of curcumin for 21 days. Immunohistochemical test included assessment of Ki-67 proliferative index, while necrotic focal points and histopathological examination was also carried out using light microscope after routine hematoxylin and eosin (H&E) staining technique. Results show that expression of Ki-67 proliferative cell marker was significant at ($p \leq 0.05$) in sections of cerebral cortex placed on 250mg/kgbw and 500mg/kgbw of curcumin when compared to tumor control. Formation of necrotic focal points was significantly reduced and histopathological alteration restored to normal in sections of cerebral cortex following administration of curcumin. This study revealed that curcumin has the potentials to regulate expression of Ki-67 proliferative index and cause reversal in histopathological alterations associated with cancer progression in experimental neuro-oncology model.

Key words: cerebrum, curcumin, ki-67, proliferation, tumor.

INTRODUCTION

As the knowledge about cell cycle deregulation in cancer keep increasing, the search and introduction of phytochemicals from natural sources, which can regulate cell cycle by modulating pathways in cancer therapy is now on front burner [1]. Major classes of disease-preventing phytochemicals function as immunity-potentiating, antioxidant and detoxifying agents. One of such dietary phytochemicals include curcumin (diferuloylmethane), a polyphenol derived from *curcuma longa* plant, commonly known as turmeric. It is a nontoxic natural product which is used as a yellow coloring agent for food and drugs and reported for its anti-cancer activities [2].

Researchers have demonstrated that one of the molecular targets of agents used in cancer therapy is the inhibitory effect on some biological signaling pathways that lead to proliferation [3]. One very important and reliable pathological grading marker of biological pathway in neuro-oncology progression is the activity of Ki-67 proliferation index used in diagnosis of cancer in brain, breast, prostate and testicular tissues [4,5]. Antigen Ki-67, a molecular target in diagnosis of cancer, is a protein that is encoded by MKI67 gene and referred to as proliferation marker [6,7].

Ki-67 has become the most accepted prognostic and predictive marker for cancer diagnosis and treatment, therefore, therapy that is capable of blocking Ki-67 can lead to the arrest of cell proliferation thereby inhibiting the progression of cell cycle [8]. Expression of Ki-67 is strongly associated with growth of tumor cells and considered the most widely used marker in routine onco-pathological investigations [9,10].

This research is therefore intended to investigate effect of curcumin on Ki-67 proliferation index as well as assessment of histopathological alterations, necrotic focal points and inflammatory cells

infiltration in **nitroso bis** amine - induced cerebral injury in experimental neuro-oncology in Wistar rats.

MATERIALS AND METHODS

Preparation of Extract

Curcuma longa was obtained from Watt market, in Calabar South Local Government Area of Cross River State and taken to the department of biological sciences, University of Calabar, Nigeria for identification. The rhizome was dried at room temperature, powdered and subjected to crude extraction with ethanol. 200g of *Curcuma longa* was soaked in 1000ml of ethanol, labelled and covered for 72 hours, after which a clean filter paper was used to filter extracts. The filtrate was evaporated to dryness at 40°C in a vacuum using a rotary evaporator. The extract (curcumin) was weighed and kept at 4°C in refrigerator until further use.

Experimental Animals

Twenty (20) adults male Wistar rats with average weight of 150g were used for this research. The rats **were** kept in clean cages and divided into four groups designated A, B, C and D with five rats in each group. The rats were allowed to acclimatize for two weeks in animal house, University of Calabar and allowed unrestricted access to commercially available chow (livestock feed) and water.

Experimental Design

Experimental animals were divided into Four (4) groups and given treatment as shown in Table 1.

Table 1: Treatment of experimental groups

GROUP	DESIGNATION	TREATMENT
A	Normal control	Distilled water
B	Tumor control (TC)	5mg/kg.bw of Nitroso bis amine only
C	Tumor + Curcumin (Low Dose)	5mg/kg.bw of Nitroso bis + 250mg/kg.bw Curcumin
D	Tumor + Curcumin (High Dose)	5mg/kg.bw of Nitroso bis + 500mg/kg.bw Curcumin

[mg/kg.bw – milligram per kilogram bodyweight]

Ethical approval

This was obtained from Faculty of Basic Medical Sciences Animal Research Ethical Committee, University of Calabar, Calabar with the Registration Number: FBMS/EC/24/087.

Administration of Agents

Group A, Normal Control was placed on 1ml of Normal saline orally, throughout the experiment. Experimental animals in Groups B received weekly intragastric treatment with 5mg/kgbw of **Nitroso bis** (2-oxopropyl) amine. Groups C and D were administered 250mg/kg.bw and 500mg/kg.bw Curcumin respectively after treatment with **Nitroso bis** as shown in Table 1

Administration of Extract

Curcuma longa extract administration commenced one week after treatment with cancer inducing agent by oral gastric intubation and lasted for 21 days. The experimental protocol was maintained for a total of 28 days.

Termination of Experiment and Collection of Samples for Analysis

At termination, animals were anaesthetized with chloroform, sacrificed and the brain tissue removed and plotted with filter paper. Cerebrum was weighed and then suspended in Bouins fluid for fixation, preparatory to histological processing. [10,11].

Histological Studies

Brain tissue collected, and suspended in buffered neutral formaldehyde for further processes with conventional histological techniques. Sections were cut at 5.0 μ , stained in Hematoxylin and Eosin (H & E) and examined under a light microscope. [12].

Evaluation of Ki-67

Immunohistochemical staining method BenchMark Ultra (Ventana medical system, Inc, USA) was performed on 5 micros sections taken from each tissue block, Ki67-positive cells appeared dark brown while other cells retain blue stain. Estimation of Ki67 marked cells was done visually by counting the cells within the hotspot, that is field of maximum staining. Ki-67 values in percentage were evaluated by dividing the total number of positive-staining tumor cells in each field by the total number of tumor cells all multiplied by 100.

Statistical Analysis: Quantitative data from this research was recorded. Statistical significance of the differences between the groups was determined using one way analysis of variance (ANOVA).

SPSS statistical analysis program version 20 was applied and p values at 0.05 were considered significant.

RESULTS

KI-67 Proliferating Expression

As shown in fig 1, significantly higher number of Ki-67 positive cells were expressed in fig 1B and 1C when compared to the normal control (Fig 1A) at $p \leq 0.05$. However, the number of deep brown stained Ki-67 positive cells reduced significantly in the tumor animals placed on 500mg per kilogram bodyweight (500mg/kgbw) of curcumin (fig 1D). A graphical representation of Ki-67 expression in sections of cerebral cortex of experimental animal groups is shown in Fig 2. The tumor control (group B) recorded about $84.43 \pm 0.23\%$ of Ki-67 expression. p value at 0.05 were statistically significant when compared to the values expressed by normal control (group A).

Fig 1

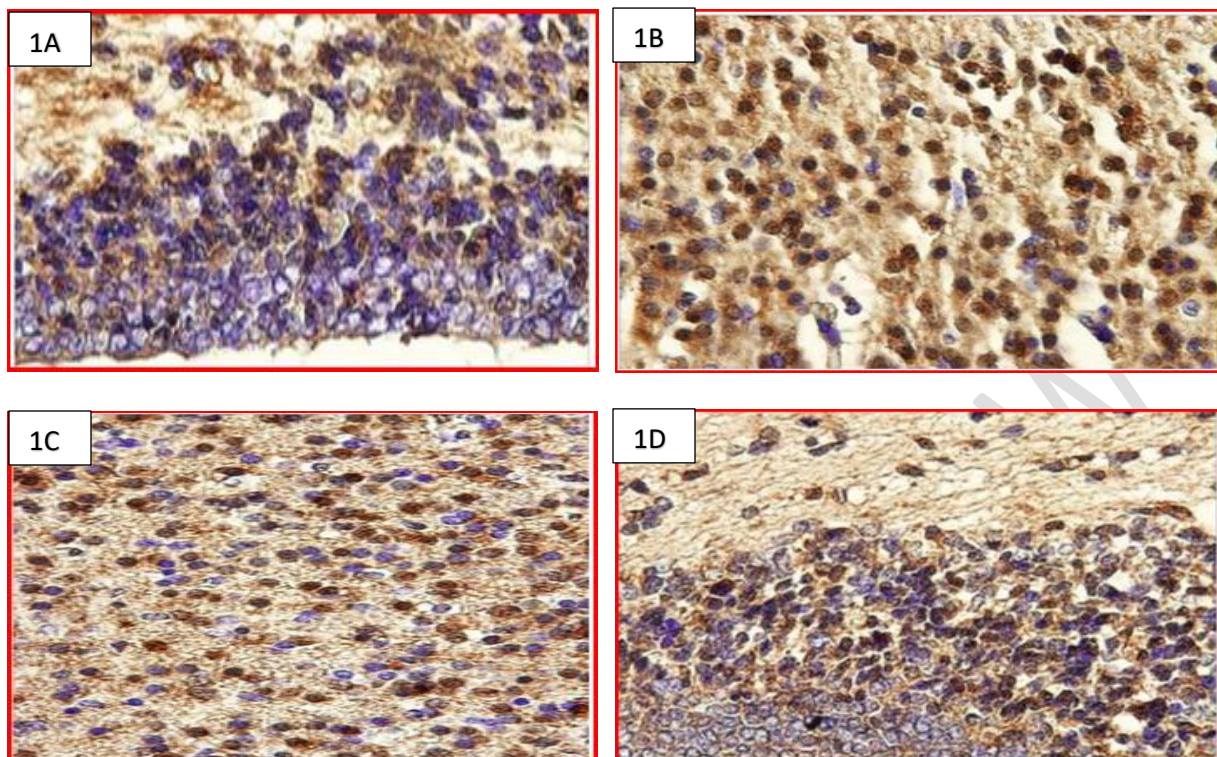
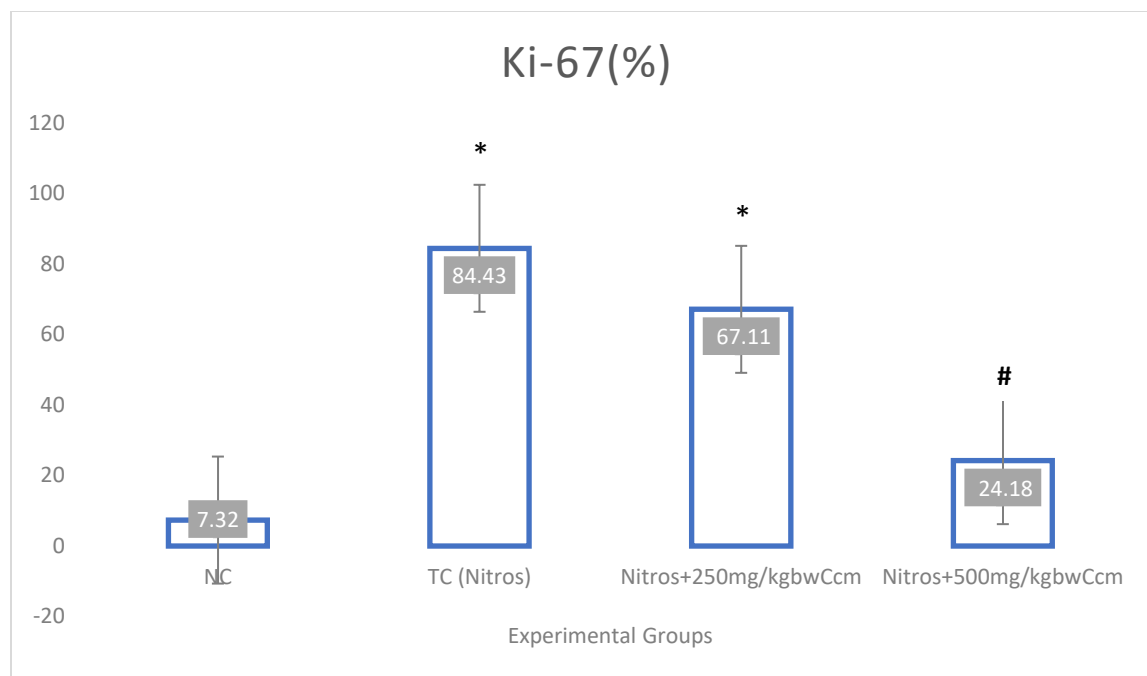


Fig 1: Showing results of Ki-67 proliferation marker test in experimental groups **Fig 1A** (NC): About 95% of cells are Ki-67 negative (retain blue color). **Fig1B** (TC): Over 80% of cells are Ki-67 positive, appeared dark brown in color. **Fig 1C**: About 67% of cells in section are Ki-67 positive. **Fig 1D**: Only about 24% cells are Ki-67 positive.



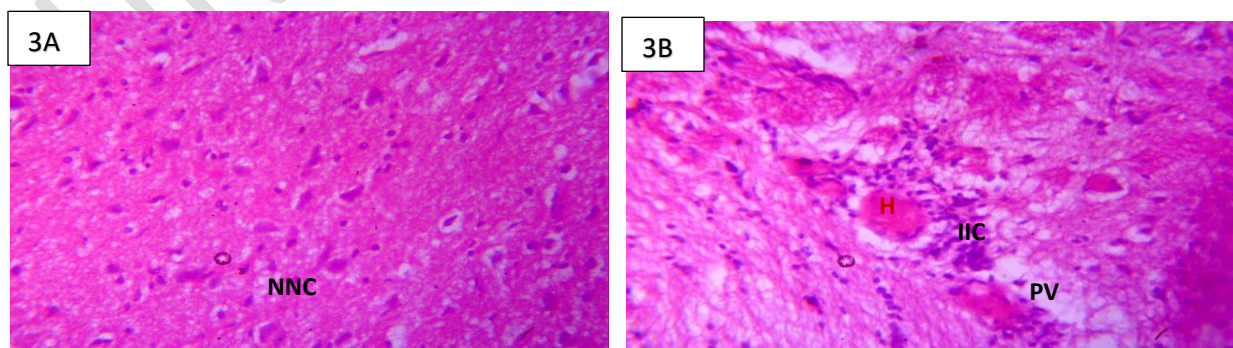
NC – Normal Control, TC – Tumor Control, Nitros – Nitroso bis Amine, Ccm – Curcumin

Fig 2: Comparison of expression of Ki-67 marker (%) in different experimental groups. Values are expressed in Mean \pm SEM. N = 5. * = Values are remarkably increased when compared to Normal Control at $p < 0.05$. # = Values are remarkably decreased when compared to Tumor Control (TC) at $p < 0.05$.

Histopathological Observation

Fig 3 reveals sections of cerebrum of different experimental groups. Photomicrograph of sections in group B administered with 5mg/kg.bw of Nitrosobis amine only (fig 3B) reveals severe degeneration with perivascular vacuolation, focal aggregate of inflammatory cells around the hemorrhagic area (H) with infiltration of inflammatory cells (IIC). Photomicrograph of Group C (5mg/kg.bw of Nitrosobis + 250mg/kg.bw Curcumin) shows section of cerebral cortex moderate focal area of necrosis(N) (Fig 3C). Photomicrograph of Group D (5mg/kg.bw of Nitrosobis + 500mg/kg.bw Curcumin, shows moderate micro cystic spaces (MS) (fig 3D)

Fig 3



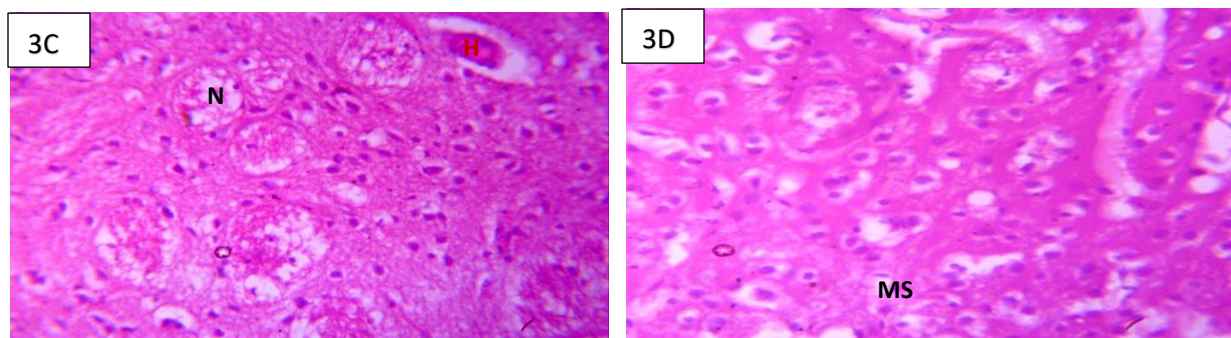


Fig 3A: Photomicrograph of group A: Normal Control x400 (H/E). Section of cerebral cortex shows cerebral cortex with normal neuronal cells (NNC). **Fig 3B:** Photomicrograph of group B(H/E) x400: 5mg/kg.bw of Nitroso bis amine only. Section of cerebral cortex shows severe degeneration with perivascular vacuolation, focal aggregate of inflammatory cells around the hemorrhagic area (H) with infiltration of inflammatory cells (IIC). **Fig 3C:** Photomicrograph of Group C (H/E) x400: 5mg/kg.bw of Nitroso bis + 250mg/kg.bw Curcumin. Section of cerebral cortex administered with nitro and low dose extract shows moderate focal area of necrosis(N). **Fig 3D:** Photomicrograph of Group D(H/E) x400: 5mg/kg.bw of Nitroso bis + 500mg/kg.bw Curcumin. Section of cerebral cortex induced with nitro and high dose extract, shows moderate micro cystic spaces (MS).

DISCUSSION

Expression of Ki-67 is strongly linked to cells proliferation and it is considered the most widely used maker in routine pathological investigations [9,13]. Researchers have demonstrated that any therapy that is capable of blocking Ki-67 expression, can be effective in arresting cell proliferation and inhibit progression in cell cycle [8]. Interestingly, this study has shown the anti-proliferative effect of curcumin on cerebrum of nitrosobis amine-induced animal tumor model. Observation from this study shows a significant decrease in Ki-67 proliferation marker expression following treatment with curcumin. All intermediate biological mechanisms and pathways that drive cell proliferation do have an intrinsic growth suppressive factor. Findings from this research indicates that curcumin may have supported and conferred stability on some, or perhaps all of these innate growth-suppressive processes and factors which may include the expression of activities of various proteins such as enzyme transcription factors, inflammatory cytokines and gene products linked with cell survival and proliferation, thereby reversing carcinogenesis. This is consistent with findings of Hua et al., 2010 [14], who reported that curcumin having the chemical formular (1,7-bis(4-hydroxy-3-methoxyphenyl)-6,6-heptadiene-3,5-dione), is a strong antioxidant with an antiproliferative and apoptotic effect on breast cancer.

Benerjee et al., (2010) [15] has also demonstrated that curcumin inhibits cell proliferation by inhibiting the assembly of dynamic microtubules and further activating mitotic checkpoints. Arguably, even though Ki-67 is a predictive marker in tumor cells and can independently be used to detect malignancy, it is important when histopathological changes are also examined in tumor models because at the peak of histopathological alterations, proliferation activities seem to be constant. Stojiljkovic et al., (2003) [16] and Li et al., (2015) [17] reported similar findings.

In this study, proliferation activities revealed by expression of Ki-67 proliferative cell marker were not proportional to histopathological alterations, variations existed between the parameters relating

to tumor progression, invasion, and formation of necrotic focal points shown in histological sections of cerebrum. Presence of increased necrotic focal points revealed in sections corresponded to declining values of Ki-67 expression. However, hypoxia, angiogenesis and inflammation have been found to be closely associated with tumor progression [18,8,12]. Necrotic focal points may have developed as a result of tumor growth and its resultant inadequate blood supply initiated by tissue hypoxia. Angiogenesis may have resulted in hemorrhagic spots observed in sections while inflammation is indicated in infiltrating inflammatory cells. All observed histopathological alterations were reversed following treatment with curcumin in a dose dependent manner.

This research has therefore shown unique activities of curcumin directed towards inhibition of proliferation by suppressing Ki-67 index via a variety of cellular signaling pathways in brain tumor models. Reduction in necrotic focal points, hemorrhagic spots and infiltrating inflammatory cells is an indication of reversal in histopathological alterations associated with cancer progression.

The mechanisms by which curcumin exerts its anti-cancer properties are diverse, meant to target regulations in the processes of cellular growth and apoptosis at various levels [19]. Apart from curcumin's direct effect on various transcription factors, signaling proteins and oncogenes, it also acts on temporal stages of carcinogenesis [19]. This study has confirmed report by Gao H., [20], Kim TK., [21] and Soumoy L., [22] that anticancer agents inhibit lipid peroxidation by its free radical-scavenging activities, suppressing DNA mutagenesis and detoxification of toxic metabolites. Curcumin is therefore a potent anticancer agent that can play a role in inhibitory effect on initial stages of carcinogenesis.

CONCLUSION

This study revealed that curcumin regulated expression of Ki-67 proliferative index and caused reversal in alterations associated with cancer progression in experimental neuro-oncology model. Histopathological observation from this research have shown that curcumin has therapeutic potentials to restore alterations resulting from cerebral injury caused by cancer inducing agent.

DISCLAIMER (Artificial Intelligence)

Author(s) hereby declares that NO generative AI technology such as Large Language Models (ChatGBT, COPILOT, etc.) and text-to-image generators have been used during the writing or editing of this manuscript.

Disclaimer (Artificial intelligence)

Option 1:

Author(s) hereby declare that NO generative AI technologies such as Large Language Models (ChatGPT, COPILOT, etc.) and text-to-image generators have been used during the writing or editing of this manuscript.

Option 2:

Author(s) hereby declare that generative AI technologies such as Large Language Models, etc. have been used during the writing or editing of manuscripts. This explanation will include the name, version, model, and source of the generative AI technology and as well as all input prompts provided to the generative AI technology

Details of the AI usage are given below:

- 1.
- 2.
- 3.

REFERENCES

1. Sharma RA, Gescher AJ, Steward WP. Curcumin: the story so far. *Eur J Cancer*. 2005;41: 1955-1968. doi: 10.1016/j.ejca.2005.05.009.
2. Campbell FC, Collett PG. Chemopreventive Property of Curcumin. *Future Oncol*. 2005; 1:405-414. doi: 10.1517/14796694.1.3.405.
3. Alkhaibary A, Alassiri AH, AlSufiani F, Alharbi MA. Ki-67 labeling index in glioblastoma; does it really matter? *Hematol Oncol Stem Cell Ther*. 2019;12(2):82-88. doi: 10.1016/j.hemonc.2018.11.001.
4. Kontzoglou K, Palla V, Karaolanis G, Karaiskos I, Alexiou I, Pateras I, Konstantoudakis K, Stamatakis M. Correlation between Ki67 and breast cancer prognosis. *Oncology*. 2013;84(4):219-25. doi: 10.1159/000346475.
5. Fukumura, M., Nonoguchi, N., Kawabata, S. *et al.* 5-Aminolevulinic acid increases boronophenylalanine uptake into glioma stem cells and may sensitize malignant glioma to boron neutron capture therapy. *Sci Rep* **13**, 2023; 10173. <https://doi.org/10.1038/s41598-023-37296-6>
6. Theresia E, Malueka RG, Pranacipta S, Kameswari B, Dananjoyo K, Asmedi A, Wicaksono AS, et al. Association between Ki-67 Labeling index and Histopathological Grading of Glioma in Indonesian Population. *Asian Pac J Cancer Prev*. 2020; 1;21(4):1063-1068. doi: 10.31557/APJCP.2020.21.4.1063.
7. Rukayat AI, Akeem AO, Fatimo AS, Abubakar I, Emmanuel Y, Olushola OO, Salihu MA. Exogenous melatonin restored the cyto-architectural integrity and biochemical activities of the cerebrum in sodium fluoride induced toxicity. *Eur J Anat*. 2021;25 (5): 533-540
8. Yang C, Zhang J, Ding M, Xu K, Li L, Mao L, Zheng J. Ki67 targeted strategies for cancer therapy. *Clin Transl Oncol*. 2018;20(5):570-575. doi: 10.1007/s12094-017-1774-3.
9. Lian H, Yang L, Cole A, Sun L, Chiang AC, Fowler SW, et al. NFκB-activated astroglial release of complement C3 compromises neuronal morphology and function associated with Alzheimer's disease. *Neuron*. 2015;7;85(1):101-115. doi: 10.1016/j.neuron.2014.11.018.
10. Agbor CA, Fischer CE, Agaba EA, Nnenna WA. Neuroprotective effect of beta-D-glucan polysaccharide on hyperglycaemia-induced cerebral injury in diabetic animal model. *Eur J Anat*. 2022;26(2), pp. 217–224. <https://doi.org/10.52083/WCXG2854>.
11. Tejada S, Becerra-Castro MV, Nuñez-Cordoba J, Díez-Valle R. Ki-67 Proliferative Activity in the Tumor Margins as a Robust Prognosis Factor in Glioblastoma Patients. *J Neurol Surg A Cent Eur Neurosurg*. 2020;82(1):53-58. doi: 10.1055/s-0040-1709730.
12. Agbor CA, Fischer CE, Agaba EA, Nnenna WA. Neuroprotective Effect of Beta-D-glucan Polysaccharide Fractionate of *Auricularia Polytrichaon* Hyperglycaemia-Induced Cerebral

- Injury in Diabetic Animal Model. Trop J Nat Prod Res. 2021;5(12):2182-2186. doi.org/10.26538/tjnpr/v5i12.24
13. Eru EM, Anani SE, Paulinus SO, Mesembe OE, Uruakpa KC, Umoh NM, et al. Scopolamine-Induced Alzheimer's Disease in Wistar Rats; Aqueous *Talinum Triangulare* Potency on the Hippocampal Nissl Bodies and Long-Term Learning and Memory. Trop J Nat Prod Res. 2022; 6(1):117-122.
 14. Hua WF, Fu YS, Liao YJ, Xia WJ, Chen YC, Zeng YX. Curcumin induces downregulation of EZH2 expression through the MAPK pathway in MDA-MB-435 human breast cancer cell. Eur J Pharmacol. 2010; 637:16-21
 15. Benerjee M, Singh P, Panda D. Curcumin suppresses the dynamic instability of microtubules, activates the mitotic checkpoints and induces apoptosis in MCT-7 cells. FEBS J. 2010; 277:3437-48
 16. Stojiljkovic M, Piperski V, Dacevic M, Rakic L, Ruzdijic S, Kanazir S. Characterization of 9L glioma model of the Wistar rat. J Neurooncol. 2003 May;63(1):1-7. doi: 10.1023/a:1023732619651.
 17. Li LT, Jiang G, Chen Q, Zheng JN. Ki67 is a promising molecular target in the diagnosis of cancer (review). Mol Med Rep. 2015 Mar;11(3):1566-72. doi: 10.3892/mmr.2014.2914.
 18. Yinayk AAK, Nelson F, Richard M (2007) Robbins Basic Pathology. 8th. Philadelphia: Saunders Elsevier.
 19. He LF, Chen HJ, Qian LH: Curcumin protects pre-oligodendrocytes from activated microglia in vitro and in vivo. Brain Res. 2010, 1339: 60-69. 10.1016/j.brainres.2010.04.014
 20. Gao H, Xi Z, Dai J, Xue J, Guan X, Zhao L, Chen Z, Xing F. Drug resistance mechanisms and treatment strategies mediated by ubiquitin-specific proteases (USPs) in cancers: new directions and therapeutic options. Mol Cancer. 2024;23(1):88.
 21. Kim TK, Vandsemb EN, Herbst RS, Chen L. Adaptive immune resistance at the tumour site: mechanisms and therapeutic opportunities. Nat Rev Drug Discov. 2022;21(7):529–40
 22. Soumoy L, Ghanem GE, Saussez S, Journe F. Bufalin for an innovative therapeutic approach against cancer. Pharmacol Res. 2022;184:106442.