

Case study

Study on unguided temporary pacing via the jugular vein at the Mohamed VI University Hospital of Marrakech: safety, effectiveness and practicability

ABSTRACT

Temporary pacing is commonly performed by cardiologists under fluoroscopic, echocardiographic, or electrocardiographic guidance. However, in primary and secondary health care centers in developing countries, resources are limited, and there are often not enough cardiologists or access to catheterization laboratories or echocardiography. This leads to delays in the care of patients requiring temporary pacing, thereby increasing mortality. This study aims to evaluate the safety, effectiveness and practicability of insertion of a temporary pacemaker without guidance at the Mohamed VI University Hospital of Marrakech.

Keywords : Temporary pacing, Heart block, Bradycardia, Myocardial infarction, Internal jugular vein.

Introduction

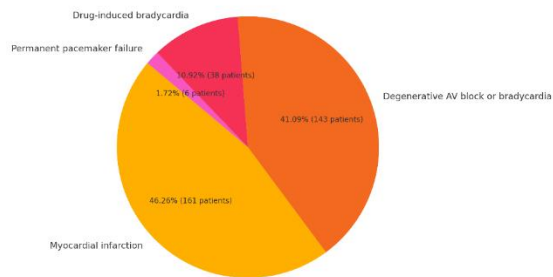
Temporary pacing is needed in symptomatic bradycardias of various etiologies either as a bridge to permanent pacing or till recovery of spontaneous rhythm. It is done via a jugular, subclavian, or femoral venous approach either under fluoroscopic, echocardiographic, or under ECG guidance. In most of the developing world, this procedure is done blindly. Limited resources, expertise, and time constraints are the most important factors which restrict the use of the imaging while performing any procedure. In the developing world, there are not an adequate number of cardiologists, and also C-arm, catheterization laboratories, or echocardiography are not available at primary or secondary healthcare facilities [13].

METHODS :

An open, single-center study, on a series of 348 patients who presented an indication for emergency temporary pacing, was conducted between June 2020 and June 2024. The procedures were performed by second and third year cardiology residents.

RESULTS :

Patient characteristics : Among the 348 patients included, the mean age was 63.14 ± 9.54 years. The majority of patients were men (218, or 62.64%) and 130 were women (37.36%). Indications for temporary pacing were dominated by myocardial infarction (161 patients, 46.26%), followed by degenerative atrioventricular block or bradycardia (143 patients, 41.09%), drug-induced bradycardia (38 patients, 10.92%) and permanent pacemaker failure (6 patients, 1.72%).

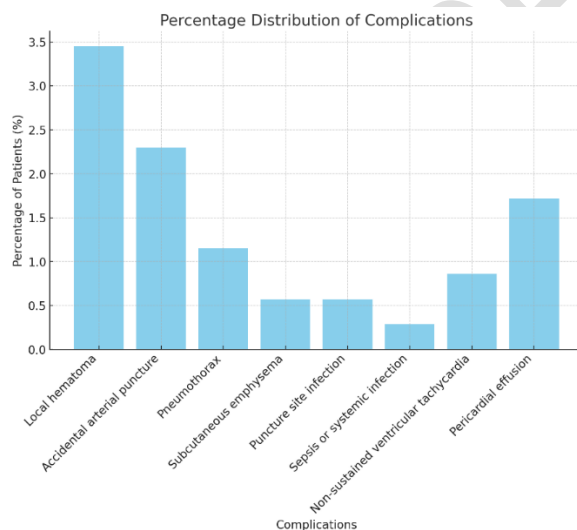


Pic 1. Indications for Temporary Pacing

The procedure was successful in 347 patients (99.71%). Only one patient required a femoral vein approach due to brachiocephalic vein obstruction caused by a history of permanent pacemaker leads. Access to the right internal jugular vein was successful in 312 patients (89.66%). In the majority of cases (231 patients, or 66.38%), access was obtained on the first attempt, with an average of 1.54 ± 0.85 attempts. The average procedure time was 11.5 ± 2.1 minutes.

The position of the tip of the pacing catheter was identified in the right ventricular cavity, at the level of the interventricular septum or free wall, in 269 patients (77.30%). The position was at the right ventricular apex in 66 patients (18.97%) and in the right ventricular outflow tract (RVOT) in 13 patients (3.73%).

A total of 37 patients (10.63%) developed complications, mainly minor. Complications included local hematoma (12 patients, 3.45%), accidental arterial puncture (8 patients, 2.30%), pneumothorax (4 patients, 1.15%), subcutaneous emphysema (2 patients, 0.57%), puncture site infection (2 patients, 0.57%), sepsis or systemic infection (1 patient, 0.29%), non-sustained ventricular tachycardia during insertion (3 patients, 0.86%), and pericardial effusion (6 patients, 1.72%). No deaths attributable to the procedure were observed.



Graph 1. Percentage Distribution of Complications

DISCUSSION :

In most primary and secondary care settings, the number of cardiologists and imaging equipment is insufficient to meet the needs of the majority of the population, resulting in wasted valuable time when transferring patients requiring stimulation temporarily to tertiary care centers. This increases the risk of mortality. This situation could be avoided if clinicians in these institutions could perform temporary stimulation without imaging guidance. This study aims to evaluate the safety, effectiveness and feasibility of insertion of a temporary pacemaker without guidance by cardiology fellows .

The internal jugular, subclavian, femoral, or brachial veins are usually used for insertion of the temporary pacing wire, with the choice of access site depending on physician preference and experience. The right internal jugular and left subclavian veins are often favored, due to their high rate of correct placement in emergency situations [3, 4]. Our study demonstrates that cardiology fellows can perform this procedure without image guidance with great success and a low complication rate. We have observed that the preference for central cannulation generally follows the order: right internal jugular, left internal jugular, then subclavian vein, due to the easier access to the internal jugular. A total of 982 (89.75%) patients were cannulated via the right internal jugular vein, and the majority of them, 717 (65.59%), were successful on the first attempt. In some cases, access to the subclavian vein was favored due to the short neck length or obesity of the patients.

In only one case, temporary stimulation could not be achieved by a blind approach. Although cannulation of the internal jugular was successful on the second attempt, the stimulation wire could not be inserted easily. A venogram revealed stenosis of the subclavian and brachiocephalic vein, requiring femoral access. In the study by Zhong C et al., stimulation failed in one out of 95 patients in the no-guidance group, who subsequently had Ebstein's anomaly. In the other 94 patients, stimulation was successful on the first attempt in 97% of cases, and on the second attempt in 3% of cases [2].

The mean number of attempts required for successful venous cannulation was 1.54 ± 0.85 ; however, in the majority of patients, 726 (66.42%), central vein cannulation was successful on the first attempt. In the study by Karimi-Sari H et al., they found that the mean number of attempts for blind central venous cannulation was 1.58 ± 0.64 , although it was significantly lower in the ultrasound-guided group (1.12 ± 0.3 , $P < 0.001$) [5].

The tip of the pacing wire was located in the right ventricular cavity, in contact with the interventricular septum or the free wall, in 843 (77.20%) patients. This could be explained by the curvature and stiffness of the temporary stimulation wires. Only in 42 (3.85%) patients, the tip of the wire ended up in an unfavorable position, at the right ventricular infundibulum (RVOT); however, no sustained arrhythmia was observed in these patients (Fig. 1).

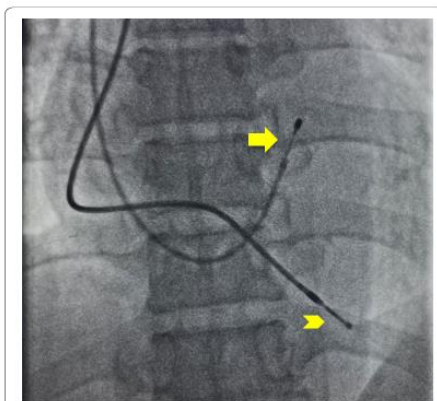


Fig. 1 Temporary pacing lead tip (arrow) abutting Interventricular septum and permanent pacing lead (arrowhead at right ventricular apex)

Although complications occurred in 117 (10.70%) patients, most were minor. Pneumothorax developed in 12 (1.1%) patients; however, only 2 (0.18%) patients required intercostal tube insertion; the rest were managed conservatively. Both of these patients were obese and had COPD, and several attempts at cannulation were necessary. The intercostal tube was removed in one patient on the third day and in the other on the fifth day. Vascular perforation due to the wire developed in 1 (0.09%) patient. A perforation of the right internal jugular occurred during insertion of the temporary stimulation wire in a patient who developed subclavian and brachiocephalic vein stenosis after permanent pacemaker implantation performed 9 years ago. In this patient, temporary stimulation could not be achieved via the jugular or subclavian vein, requiring femoral access. Subclavian and brachiocephalic vein stenosis have been reported after placement of intravascular devices such as central venous catheters, pacemaker or defibrillator wires, and dialysis catheters [6–8]. Venous obstruction has been attributed to thrombus formation or fibrosis due to chronic irritation of the endothelium [9]. After device implantation, some venous stenosis has been noted in 30–50% of patients [10, 11]. These obstructions are most often asymptomatic and are usually identified during reoperations, either to

upgrade a device to a dual chamber or for wire replacement. Balloon venoplasty and stenting have been used in some situations to manage these patients . It is important to be aware of this complication and be prepared to use an opposing site for the procedure if possible.

Complication	n	%	Comments
Total Complications	117	10.70	Majority were minor.
Pneumothorax	12	1.1	2 patients required chest tube insertion; others managed conservatively.
Chest Tube Insertion	2	0.18	Tubes removed on the third and fifth day.
Vascular Perforation (Lead)	1	0.09	Right jugular vein perforation in a patient with subclavian and brachiocephalic stenosis post-pacemaker implantation.
Vein Stenosis (Subclavian/Brachiocephalic)	-	-	Occurred after intravascular device placement; often asymptomatic.
Pericardial Effusion	21	1.92	Majority mild (<10 mm); 2 patients with moderate effusion (10-20 mm).

Table 1 Complications (N = 1093)

Pericardial effusion was observed on echocardiography in 21 (1.92%) patients; most of the time it was mild (<10 mm), and only 2 patients had moderate effusion (10-20 mm). It could not be determined whether this effusion was due to the procedure or another cause. However, AK Pradhan et al. found that the incidence of pericardial effusion in patients after temporary pacemaker placement was 10.0%, but in the majority of cases, 4.2% of effusions were detected after wire removal , and a duration of > 7 days was the only significant predictor of pericardial effusion after temporary pacemaker implantation [12]. No deaths attributable to the procedure have been reported.

CONCLUSIONS :

Unguided temporary pacing via a jugular venous approach in an emergency setting is possible with a high success rate and low complication rate. Therefore, this procedure is safe and effective, and clinicians working in primary and secondary healthcare settings should be encouraged to perform it.

REFERENCES

1. Blanco P (2019) Temporary transvenous pacing guided by the combined use of ultrasound and intracavitary electrocardiography: a feasible and safe technique. *Ultrasound J* 11:8. <https://doi.org/10.1186/s13089-019-0122-y>
2. Zhong C, Mao S, Guang J, Zhang Y (2021) Application of the improved simple bedside method for emergency temporary pacemaker implantation suitable for primary hospitals. *Sci Rep* 11(1):16850. Published 2021 Aug 19. doi:<https://doi.org/10.1038/s41598-021-96338-z>
3. Wald DA (2001) Therapeutic procedures in the emergency department patient with acute myocardial infarction. *Emerg Med Clin North Am* 19(451–67):2
4. Bressman ES (2004) Emergency cardiac pacing. In: Roberts JR, Hedges JR (eds) *Clinical procedures in emergency medicine*, 4th edn. Saunders, Philadelphia, pp 283–304
5. Karimi-Sari H, Faraji M, Mohazzab Torabi S, Asjodi G (2014) Success rate and complications of internal jugular vein catheterization with and without ultrasonography guide. *Nurs Midwifery Stud* 3(4):e23204. <https://doi.org/10.17795/nmsjournal23204>
6. Lee JA, Zierler BK, Zierler RE (2012) The risk factors and clinical outcomes of upper extremity deep vein thrombosis. *Vasc Endovascular Surg* 46(2):139–144

7. Winsters JP, Callas PW, Cushman M, Repp AB, Zakai NA (2015) Central venous catheters and UEDVT in medical inpatients: the Medical Inpatient and Thrombosis [MITH] study. *J Thromb Haemost* 13(12):2155–2160
8. Verso M, Agnelli G (2003) Venous thromboembolism associated with long-term use of central venous catheters in cancer patients. *J Clin Oncol* 21(19):3665–3675
9. O’Leary B, Allaqaband S (2015) Subclavian vein stenosis/occlusion following transvenous cardiac pacemaker and defibrillator implantation: incidence, pathophysiology and current management. *J Patient Cent Res Rev* 2:112–117. <http://dx.doi.org/https://doi.org/10.17294/2330-0698.1074.10>.
10. Lickfett L, Bitzen A, Arepally A, et al (2004) Incidence of venous obstruction following insertion of an implantable cardioverter defibrillator: a study of systematic contrast venography on patients presenting for their first elective ICD generator replacement. *Europace* 6:25–31
11. Haghjoo M, Nikoo MH, Fazelifar AF, Alizadeh A, Emkanjoo Z, Sadr-Ameli MA (2007) Predictors of venous obstruction following pacemaker or implantable cardioverter-defibrillator implantation: a contrast venographic study on 100 patients admitted for generator change, lead revision, or device upgrade. *Europace* 9:328–332
12. Pradhan AK, Jain N, Dwivedi SK, Narain VS, Sethi R, Chandra S, Chaudhary G, Vishwakarma P (2017) Pacing lead induced pericardial effusion is common but often subclinical. *Europace*. 19(3):89. <https://doi.org/10.1093/ehjci/eux141.145>
13. Sofi NU, Sinha SK, Ali A, Samrat S, Razi MM, Sharma AK, Sachan M, Pandey U, Thakur R. Unguided temporary pacing via jugular/subclavian vein in an emergency department of a high-volume tertiary care hospital of India: its safety, efficacy, and practicability. *The Egyptian Heart Journal*. 2022 Apr 25;74(1):33.