

CASE REPORT

CASE REPORT ON A RARE MENINGITIS CAUSED BY *ELIZABETHKINGIA MENINGOSEPTICA* IN BABY AT THE BUEA REGIONAL HOSPITAL, SOUTH WEST REGION, CAMEROON

ABSTRACT:

Aim: This report was aimed at determining the possible source, risk factors, antimicrobial susceptibility pattern and clinical management of the first recorded case of meningitis in Cameroon caused by *Elizabethkingiameningoseptica*.

Presentation of case: A 10 months old baby previously diagnosed with otitis media was admitted at the Buea Regional Hospital on the 21st of October 2023 after a referral following unsuccessful treatment. Upon admission, the baby had persistent fever, catarrh (evidence of an upper respiratory tract infection) and abdominal discomfort. Patient developed decreased body movement, altered consciousness and neck stiffness even after being placed on ampicillin and cefotaxime for two days. Based on cerebrospinal fluid analysis, the patient was considered a probable meningitis case and put on ceftriaxone to no avail. CSF culture later revealed the presence of *Elizabethkingiameningoseptica* susceptible to ciprofloxacin and resistant to imipenem, amoxicillin-clavulanic acid, cotrimoxazole, ampicillin and ceftriaxone. Marked improvement was noticed and the patient was discharged following full recovery after treatment with ciprofloxacin for 21 days. Epidemiological investigations and active case search did not provide any evidence of the *E. meningoseptica* being acquired in the hospital.

Discussion and conclusion: The *E. meningoseptica* in this case was most likely community acquired associated with Acute Otitis media probably linked to a recent upper respiratory tract infection. The isolate was resistant to Ceftriaxone and susceptible to Ciprofloxacin. In case of meningitis caused by this pathogen, empirical treatment with Fluoroquinolones may most likely be an effective option in the absence of antimicrobial susceptibility testing (AST).

Keywords: *Elizabethkingiameningoseptica*, Meningitis, Otitis media, Cerebrospinal fluid

INTRODUCTION

Meningitis is a life-threatening infectious disease that affects millions of people of all ages worldwide [1]. It is considered a major global public health threat that requires prompt diagnosis and treatment [2]. Bacterial meningitis is classified as an epidemic prone disease which warrants immediate notification to the state or local public Health officials [3]. The most common aetiological agents of bacterial meningitis

include *Neisseria meningitidis*, *Streptococcus pneumoniae*, *Hemophilus influenzae*, *Listeria monocytogenes* and *Escherichia coli* [4]. A rare aetiologic agent of bacterial meningitis is *Elizabethkingiameningoseptica*[5]. *Elizabethkingiameningoseptica* is a gram negative, non-spore forming rod naturally found in soil, water, the hospital environment (on medical devices, sinks etc) [6] and known to be a common cause of Healthcare associated infection (HAI)[7]. To the best of our knowledge, no case of meningitis caused by *Elizabethkingiameningoseptica* has ever been reported in Cameroon. This case investigation presents a bacterial meningitis caused by *Elizabethkingiameningoseptica* in a 10 months old baby in Fako division, South West Region, Cameroon. This report was aimed at determining the possible source, risk factors, antimicrobial susceptibility pattern and clinical management of meningitis caused by *Elizabethkingiameningoseptica* so as to be able to formulate and implement reliable preventive and management strategies in our setting.

PRESENTATION OF CASE

Ten months old male weighing 10kg was brought to and admitted at the Buea Regional Hospital on the 21st of October 2023. Background information of the child prior to illness reveals that the HIV negative baby was usually very active (plays with his elder brother) although always left indoors, not allowed to play with soil (no ground around the vicinity of the house), and consumes either tap water or mineral water. From the records seen on the Child's vaccination card, all the expanded program on immunization (EPI) vaccines recommended for his age (the most recent one was given on the 26th of September 2023) had been administered.

Prior to hospitalization at the Buea Regional Hospital, the baby became unusually less active, developed fever, runny nose and kept crying on the 1st of October 2023 (table 1). On the 6th of Oct 2023, the mother took the child to a clinic in their neighborhood. A negative rapid diagnostic test (RDT) for malaria and a positive C-reactive protein test were the laboratory findings. The patient was placed on cefixime syrup and Artesunate/pyronaridine (antimalarial drug) and the mother was told to go home and continue the

treatment for 3 days. Three days later there was no sign of relieve on the child. The mother took the child to another clinic in their neighborhood on the 10th of October 2023. The child presented with persistent fever, abdominal discomfort, restlessness, runny nose, pink conjunctivae and anicteric sclerae. CSF analysis and Malaria test (microscopy and RDT) were done and all came back negative. Signs of acute inflammation of the tympanic membrane were noticed and a preliminary diagnosis of Acute otitis media (AOM) established. The child was hospitalized and put on Imipenem. After 8 days of hospitalization, the patient still had persistent fever and so was referred to the Buea Regional hospital to see a pediatrician.

The baby was brought to and admitted at the Buea Regional Hospital on the 21st of Oct 2023 (9:00 PM). Upon admission, the baby had persistent fever (38.5°C), catarrh and abdominal discomfort. Oxygen saturation ranged between 96-99%. Neurologic examinations revealed hypotonia. Patient was placed on Ampicillin 50mg/kg, Cefotaxime 50mg/kg and Paracetamol. On the 23rd of Oct 2023, patient presented with persistent fever, decreased body movement, altered consciousness, neck stiffness and mild hyperreflexia meeting the case definition of suspected meningitis. Cerebrospinal fluid (CSF) analysis, soluble antigen test for meningitis, blood culture, FBC and cerebral computed tomography (CT) scan were requested. Patient was then put on Ceftriaxone, Dexamethasone and Phenobarbital. The cloudy CSF sample had 260 WBC/mm³ (with 47% being Neutrophils), a protein level of 147mg/dl, glucose level of 25mg/dl (meeting the case definition of probable meningitis) and a chloride level of 110mmol/l. Blood culture came back negative. Soluble antigen assay (Pastorex Meningitis assay BIORAD, California-USA) was negative for *Neisseria meningitidis*, *Streptococcus pneumoniae*, *Hemophilus influenzae* and *Escherichia coli*. FBC revealed 13,300 WBC/ μ l and 46.2% neutrophil. CRP was 12mg/l (Positive). CT scan showed signs of diffused brain atrophy. CSF culture (automated VITEK 2 Advanced Expert system-Biomerieux, USA) revealed the presence of *Elizabethkingiameningoseptica* (meeting the case definition of confirmed meningitis) susceptible to ciprofloxacin and resistant to imipenem, amoxicillin-clavulanic acid, cotrimoxazole, cefixime, ampicillin and ceftriaxone. On the 17th of November 2023, all the previous antibiotics were discontinued and the patient was then put on Ciprofloxacin injectable 30mg/kg (table 1) in 2 divided doses (for 21 days) and paracetamol injectable 30mg/kg in 4 divided doses (in case of fever). Marked improvement could be seen in the patient under ciprofloxacin treatment. The patient was discharged following full recovery on 8th of December 2023 after 21 days of treatment with Ciprofloxacin.

Table 1: Summary of events and outcomes for the reported *E. meningoseptica* meningitis case

| Date | Symptoms | Taken to the hospital? | Admission date (duration) | Tests done | Diagnosis | Treatment and outcome |
|---------------------------|---|------------------------------|-------------------------------------|---|----------------------|--|
| 1 st Oct 2023 | less active, fever, runny nose | No | Not admitted | None | Unknown | Not stated: No improvement |
| 6 th Oct 2023 | fever, runny nose | Yes (Clinic) | Not admitted | Malaria: <i>Negative</i> CRP: <i>Positive</i> | Not clear | cefixime and Artesunate: No improvement |
| 10 th Oct 2023 | persistent fever, abdominal discomfort, runny nose, | Yes (another Clinic) | 10 th Oct 2023 (8 days) | CSF analysis: <i>Negative</i> Malaria: <i>Negative</i> | Acute otitis media | Imipenem: No improvement |
| 21 st Oct 2023 | fever (38.5°C), catarrh and abdominal discomfort | Yes (Buea Regional Hospital) | 21 st Oct 2023 (48 days) | Blood culture: <i>Negative</i> FBC: 13,300 WBC/ μ l and 46.2% neutrophil. CRP: <i>Positive</i> CSF culture : <i>E. meningoseptica</i> isolated | Bacterial meningitis | Ampicillin, cefotaxime (from 21 st Oct to 17 th Nov 2023) No improvement Ceftriaxone (from 24 th Oct to 17 th Nov 2023): No improvement Ciprofloxacin (from 17 th Nov to 8 th of Dec 2023): Recovery |

The area which the baby occupied in the pediatric ward of the Buea Regional Hospital (the bed, the bed handle, the wall, the tray used by the nurses to put the patient's medication, every area the baby touched during his stay as indicated by the mother) was swabbed and well labelled. After inoculation and incubation, the environmental samples grew colonies of varying sizes, texture and colours on blood agar. Although some colonies were pale yellow in colour as expected for *E. meningoseptica*[8], none of them turned out to be gram negative rods and so were all considered not *E. meningoseptica*.

An active case search was done in the pediatric unit of the Buea Regional hospital during the hospitalization period of the meningitis case and no other child presented with or developed symptoms similar to those found on the *E. meningosepticamenigitis* case.

Using an incubation period of 2-10 days (average of 4 days) [9] , the possible period of exposure was estimated to be 21st to 29th of Sept 2023 (figure 1)

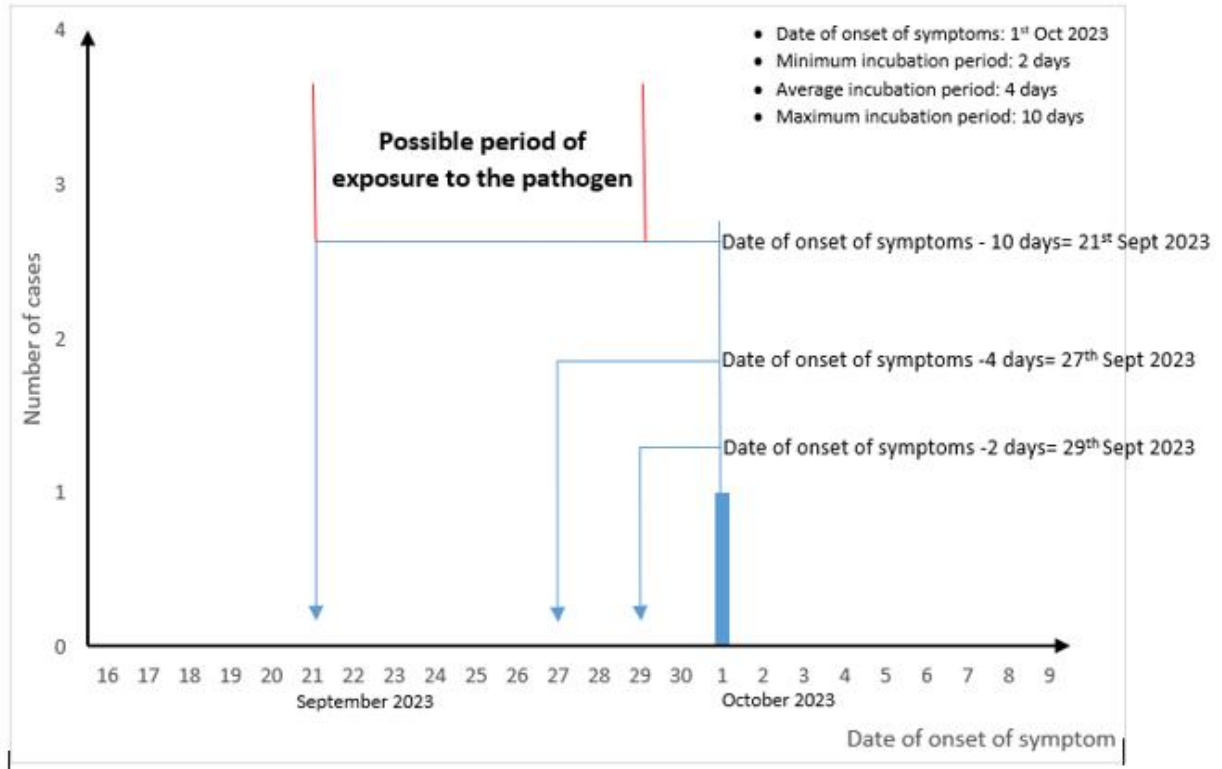


Figure 1: Estimation of period of exposure for the lone meningitis case caused by *Elizabethkingiameningoseptica* in Buea Regional Hospital (2023)

DISCUSSION

This report presents a rare case of Bacterial meningitis caused by *Elizabethkingiameningoseptica* in Fako division, South West Region of Cameroon. As compared to most of the other common etiological agents of bacterial meningitis, *E. meningoseptica* is a non-fastidious microorganism and this implies that it can easily survive in nutrient deficient areas and so can easily be picked up from environmental surfaces even in hospital settings. The mother admitted that the child is usually indoors and not allowed to play with soil or consume non-pipe borne water. No other person (whether from their neighborhood or in the pediatric ward) came down with or complained of symptoms similar to that of the child during their hospitalization. This could imply that the bacteria is not transmitted from person to person unlike the other bacteria that commonly cause meningitis (*Neisseria meningitidis*, *Streptococcus pneumoniae*, *Hemophilus influenzae*)[9].

The estimated period of exposure was 21st to 29th Sept 2023. During this period the child wasn't hospitalized so this indicates that the infection was mostly likely not acquired in the hospital. This point is further strengthened by the fact that none of the hospital environmental isolates turned out to be *Elizabethkingiameningoseptica*. Unfortunately, we could only swab and test the hospital environment of Buea Regional hospital and even at that, there is a possibility that the bacteria may have been missed because an enrichment broth was not used unlike in a similar study [7]

The child was clinically diagnosed with acute otitis media (AOM) on the 11th of October and this happens to be a risk factor for bacterial meningitis [10]. There is a possibility that the patient developed bacterial meningitis following the dissemination of the otitis media. Otitis media usually affects children and is caused by bacteria or viruses. Acute otitis media is usually associated with a current or recent upper respiratory tract infection (this can lead to problems with the Eustachian tube) [11]. On the 1st of October 2023, the child developed runny nose and this is usually one of the hall mark symptoms of an upper respiratory tract infection. There is a possibility that this runny nose was actually an indication of the presence of an upper respiratory tract infection which progressed to otitis media and eventually led to the development of meningitis in this child. At this point it is actually difficult to conclude on the source of the infection since it is just a case and not necessarily an outbreak with many cases that can be linked to a particular source.

It is quite important to understand the etiology of bacterial meningitis caused by *E. meningoseptica* as this could help in prescribing the right antibiotics promptly. Only fever as seen in our study was also found as a common symptom found in similar cases as reported elsewhere (Table 2). We did not come across any recorded case of *E. meningosepticamenigitis* or sepsis in Africa. *E. meningoseptica* happens to have a very unusual susceptibility pattern. It is a gram negative rod that is unexpectedly resistant to colistin but sensitive to vancomycin [7]. Most of the strains are resistant to beta-lactams and sensitive to fluoroquinolones as seen in this case report as well as other studies (table 2)

Table 2: Characteristics and comparison of bacterial Meningitis and Sepsis caused by *Elizabethkingiameningoseptica* as seen in different studies across the world

| Reference | Country | Number of cases | Age | Symptoms/signs | Possible source | Treatment | Outcome |
|-----------------|--------------|-----------------|--------------------|--|--------------------|---|---------------|
| [12] | India | 7 | neonates | RD* | Hospital acquired | Vancomycin, Rifampicin, cefoperazone tazobactam | Successful |
| [5] | USA | 1 | 70 yrs | Fever, lethargy, RD*, and sepsis. | Hospital acquired | Levofloxacin, Minocycline, Rifampin | Successful |
| [13] | USA | 1 | 5 yrs | Fever, neck stiffness, altered mental status | Hospital acquired | Ciprofloxacin | Successful |
| [14] | India | 1 | 1 day | convulsions, sepsis, RD* | Hospital acquired | Ciprofloxacin | Successful |
| [15] | Saudi Arabia | 1 | New born baby | Decreased consciousness, tachypnea, fever | Hospital acquired | Ciprofloxacin, vancomycin, rifampicin | Successful |
| [16] | India | 1 | 29 yrs | right-sided paucity and fever | Hospital acquired | Tigecycline | Died |
| [17] | | 1 | 78 yrs | Confusion, weak and shaky | Community acquired | Levofloxacin | Successful |
| [6] | China | 24 | 17 of them >45 yrs | Fever, cough, altered consciousness | Not determined | Cotrimoxazole, Levofloxacin, ciprofloxacin, | 10 cases died |
| Our case report | Cameroon | 1 | 10 months | fever, catarrh, abdominal discomfort | Community acquired | Ciprofloxacin | Successful |

*Respiratory distress

This is already an indication that bacterial meningitis caused by *Elizabethkingiameningoseptica* may not be successfully treated empirically following the treatment guideline for bacterial meningitis in Cameroon which mainly involves the use of Ceftriaxone. It is therefore very important to be able to detect the bacteria early enough and inform the medical doctor so that fluoroquinolones can be prescribed to the patient while awaiting AST results where applicable.

CONCLUSION

The *E. meningoseptica* in this case was most likely a community acquired infection associated with Acute Otitis media probably linked to a recent upper respiratory tract infection. The isolate was resistant to Ceftriaxone (first line treatment for bacterial meningitis based on national treatment guideline) and susceptible to ciprofloxacin as also seen in other reports and studies. As such, in case of meningitis caused by this pathogen, empirical treatment with fluoroquinolones like ciprofloxacin may most likely be an effective option in the absence of or while waiting for antimicrobial susceptibility testing (AST).

CONSENT

Written informed consent for publication of their clinical details and/or clinical images was obtained from the mother of the child. A copy of the consent form is available for review by the Editor of this journal

ETHICS APPROVAL

An ethical approval (2023/1032-03/UB/SG/IRB/FHS) was obtained from the University of Buea, Faculty of Health Science institutional review board

Disclaimer (Artificial intelligence)

Author(s) hereby declare that No generative AI technologies such as Large Language Models (ChatGPT, COPILOT, etc) and text-to-image generators have been used during writing or editing this manuscript.

REFERENCES

- [1] Kwambana-Adams B. Global burden of meningitis and implications for strategy. *The Lancet Neurology* 2023;22:646–8. [https://doi.org/10.1016/S1474-4422\(23\)00244-2](https://doi.org/10.1016/S1474-4422(23)00244-2).
- [2] Runde TJ, Anjum F, Wafner JW. Bacterial Meningitis - StatPearls - NCBI Bookshelf 2023.
- [3] Middleton MR. Bacterial meningitis is a notifiable disease. *BMJ* 2023;381:1470. <https://doi.org/10.1136/bmj.p1470>.
- [4] CDC. Bacterial meningitis/CDC 2023. <https://www.cdc.gov/meningitis/bacterial.html> (accessed November 26, 2023).
- [5] Waleed MS, Amba V, Varughese AA, Pathalapati R. Elizabethkingia meningoseptica Bacteremia and Meningitis: A Case Report. *Cureus* 2021;13:e19275. <https://doi.org/10.7759/cureus.19275>.
- [6] Li Y, Liu T, Shi C, Wang B, Li T, Huang Y, et al. Epidemiological, clinical, and laboratory features of patients infected with Elizabethkingia meningoseptica at a tertiary hospital in Hefei City, China. *Frontiers in Public Health* 2022;10:964046.
- [7] Ratnamani MS, Rao R. Elizabethkingia meningoseptica: Emerging nosocomial pathogen in bedside hemodialysis patients. *Indian J Crit Care Med* 2013;17:304–7. <https://doi.org/10.4103/0972-5229.120323>.
- [8] Shinha T, Ahuja R. Bacteremia due to Elizabethkingia meningoseptica. *IDCases* 2015;2:13–5. <https://doi.org/10.1016/j.idcr.2015.01.002>.
- [9] WHO. Meningitis 2023. <https://www.who.int/health-topics/meningitis> (accessed November 26, 2023).
- [10] Richardson MP, Reid A, Williamson TJ, Tarlow MJ, Rudd PT. Acute otitis media and otitis media with effusion in children with bacterial meningitis. *J Laryngol Otol* 1997;111:913–6. <https://doi.org/10.1017/s0022215100138964>.
- [11] Bakaletz LO. Otitis Media. *Polymicrobial Diseases*, ASM Press; 2002.
- [12] Goel S, Jhajra SD, Nangia S, Kumar A, Nanda D. Neonatal Meningitis Secondary to Elizabethkingia meningoseptica Infection. *J Glob Infect Dis* 2023;15:23–7. https://doi.org/10.4103/jgid.jgid_111_22.
- [13] Aragón JR, Acosta C, Valencia Y, Manrique V, Arias AF. Device-associated Meningitis due to Elizabethkingia meningoseptica: A Therapeutic Challenge. *The Pediatric Infectious Disease Journal* 2023;42:e360. <https://doi.org/10.1097/INF.0000000000003987>.
- [14] Murthy NS, Shivappa SG, Tejashree A, Karthik KMVS, Deepashree R. Neonatal Meningitis with Septicemia by Elizabethkingia meningoseptica : A Case Report. *J Lab Physicians* 2022;14:362–4. <https://doi.org/10.1055/s-0042-1742635>.
- [15] Barnawi AI, Kordy FN, Almuwallad OK, Kassarah KA. Early neonatal sepsis and meningitis caused by Elizabethkingia meningoseptica in Saudi Arabia. *Saudi Med J* 2020;41:753–6. <https://doi.org/10.15537/smj.2020.7.25720>.

- [16] Nagaraj S, Ravikumar R, Agrawal A, Varun CN, Rao M. Meningitis in a Hospitalized Trauma Patient Due to Elizabethkingia meningoseptica: An Emerging Nosocomial Pathogen. *Neurology India* 2022;70:2260.
<https://doi.org/10.4103/0028-3886.359290>.
- [17] Lee JW, Sun B, Hanna M, Rihawi A. A Case of Community-Acquired Elizabethkingia meningoseptica. *Cureus* 2023;15:e45183.
<https://doi.org/10.7759/cureus.45183>.

UNDER PEER REVIEW