

Case report

GENITAL NODULAR SCABIES: A CASE

REPORT

ABSTRACT

Scabies is a highly infectious skin disease caused by the ectoparasite; *Sarcoptes scabiei* var. *hominis*. It is an often neglected skin disease which is especially common in developing countries particularly, in poor hygienic conditions. It typically presents as erythematous, papular, vesicular or nodular rashes with crusts or excoriations. Nodular scabies is an uncommon variant seen in about 7% of patients with scabies. The most common sites of nodular lesions are the genitals and scrotum.

This case report explored a case of genital nodular scabies involving the phallus and scrotum of a man who complained of a rash on the phallus and scrotum. There was associated genital itching which was worse at night. Examination revealed erythematous, firm, nodular rash on the glans penis, penile shaft and scrotum. A diagnosis of genital nodular scabies was made. The risk factors identified were poor hygienic practices. Treatment included oral ivermectin and antihistamines with total resolution of symptoms.

Keywords: Genital nodules, Genital pruritus, Genital Scabies, Scabies, Nigeria

1. INTRODUCTION

Scabies is a highly infectious skin disease caused by the mite, *Sarcoptes scabiei* var. *hominis*. It is an often neglected skin disease with a global prevalence of 300 million cases annually [1,2]. It is common in developing countries especially, in poor hygienic conditions [3]. The hallmark of scabies infection is a pruritic, cutaneous eruption [4]. The pruritus is often severe and persistent and may result in sleep disturbance in affected persons [3]. The pruritus is due to an immune-mediated, antigen-specific, delayed hypersensitivity reaction to the presence of the mites, their eggs, faeces, and progeny in the stratum corneum [1,2]. The pruritus results in regular scratching which increases the possibility of secondary bacterial infections by *S. aureus* or *S. pyogenes*[2,3].

The skin lesions in scabies vary and may be seen as erythematous, papules, vesicles, pustules, nodules, scales, crusts, and burrows, with excoriation due to scratching [4]. These varying manifestations of scabies led to the description of the variants of scabies namely classical scabies and atypical scabies which include nodular scabies, crusted (Norwegian) scabies, vesiculobullous scabies and scabies incognito [6]. The typical lesions are usually located in inter-digital spaces, flexure of the wrists, extensor surface of the elbows, axillary folds, inframammary folds, umbilicus, belt line, nipples, areolae, buttocks and penile shafts [2,3]. Nodular scabies is an infrequent manifestation of scabies, characterized by firm, erythematous, pruritic, nodules [4,7]. It is usually seen on the groin, genitals and axilla [4,7]. It is seen in about 7% of patients with scabies [8]. Crusted or Norwegian scabies is seen as a hyperkeratotic rash with thick crusts, this variant is usually seen in immunocompromised patients [3] while scabies incognito is seen following treatment with oral or topical steroids with resultant alteration in the appearance of the rash [6]. Scabies is commonly transmitted by close skin contact,

such as from family members and sexual partners [1,9]. It can also be transmitted by fomites such as clothing and bedding, especially in crusted scabies [10].

Diagnosis is usually based on clinical history, physical signs and a history of close contact with confirmed scabies or similar symptoms or signs [4]. Skin biopsy with histopathologic examination is the gold standard of diagnosis. Other modes of diagnosis are dermatoscopic intradermal skin testing, skin scraping, antigen-antibody detection and Polymerase Chain Reaction (PCR)-based diagnosis [1,9,10]. Therapy can be administered topically or orally. Topical therapeutic options such as permethrin (5%) (which is the treatment of choice), benzyl benzoate (10-25%), crotamiton (10%), lindane (1%) (also known as gamma benzene hexachloride), malathion (0.5%), or sulphur ointment (6%) [1,6,10]. The oral therapeutic option is ivermectin (200µg/kg) [1]. Due to the relatively uncommon variant of scabies, a diagnosis of genital nodular scabies may be challenging and may not be achieved by healthcare workers with a low index of suspicion. Hence, we report a case of genital nodular scabies affecting the glans penis, penile shaft and scrotum to increase awareness of this form of presentation.

2. CASE REPORT

A 20-year-old male, presented with a penile rash of 3 weeks duration, the rash started on the glans penis as a solitary papule and increased in number with spread to the penile shaft. There was associated itching which was worse at night. He presented at a private hospital where he had a single dose of 1g of intramuscular ceftriaxone, 100mg of oral doxycycline daily for a week and oral ciprofloxacin 500 mg twice daily for a week, the diagnosis made at the hospital could not be ascertained. However, there was no improvement in symptoms upon completion of therapy. After which, the rash spread to the scrotum. There was no history of sexual intercourse before the onset of symptoms. There was a history of sharing underpants with his brother. He had a history of sharing towels with his roommate who he noticed had genital pruritus (the presence of cutaneous lesions in the genitals could not be ascertained). The patient is a student and resides in a hostel. He also had a history of infrequent change of underpants.

Examination findings revealed an erythematous, firm, nodular rash on the glans penis, penile shaft and scrotum (Figures 1, 2 and 3). Excoriation marks were also noted. There were no similar lesions in other parts of his body. A clinical diagnosis of genital nodular scabies was made. Topical benzyl benzoate (25%) and 10 mg of oral loratidine were prescribed. Retroviral screening and Venereal Disease Research Laboratory (VDRL) were requested and the results were negative. He was counselled on personal hygiene and told to return in a week. However, he returned two weeks later with the persistence of the symptoms. He was yet to procure the prescribed topical benzyl benzoate due to its unavailability at the pharmacy.

Examination revealed erythematous, firm, nodular rash on the glans penis, penile shaft and scrotum with some pustules and ulcerated lesions on the glans penis. A papular rash was also noticed in the inter-gluteal cleft with some areas of crusting and excoriation. An assessment of genital nodular scabies with superimposed bacterial infection was made. A dose of 200µg/kg of oral ivermectin and 625mg of oral amoxicillin-clavulanic acid twice daily for five days were prescribed. On his return to the clinic a week later, a few nodules persisted while the itching had subsided and the pustules were resolving (Figures 4,5 and 6). The patient was reassured and further counselled on hygiene. At a follow-up visit a week later, he reported a complete resolution of symptoms.

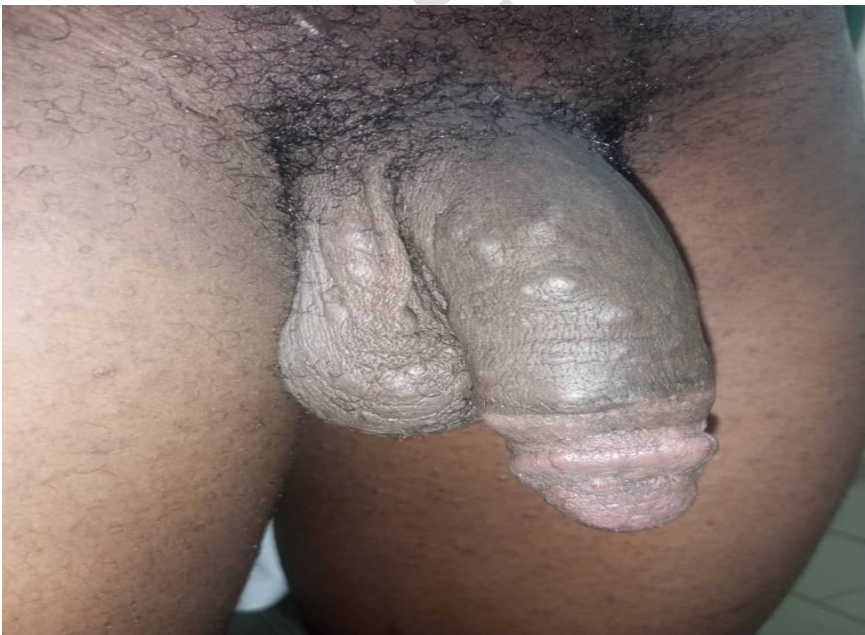

Figure 1: Image showing erythematous nodular rash on the glans penis, penile shaft and scrotum

UNDER PEER REVIEW



Figure 2: Image showing firm, nodular rash on the scrotum

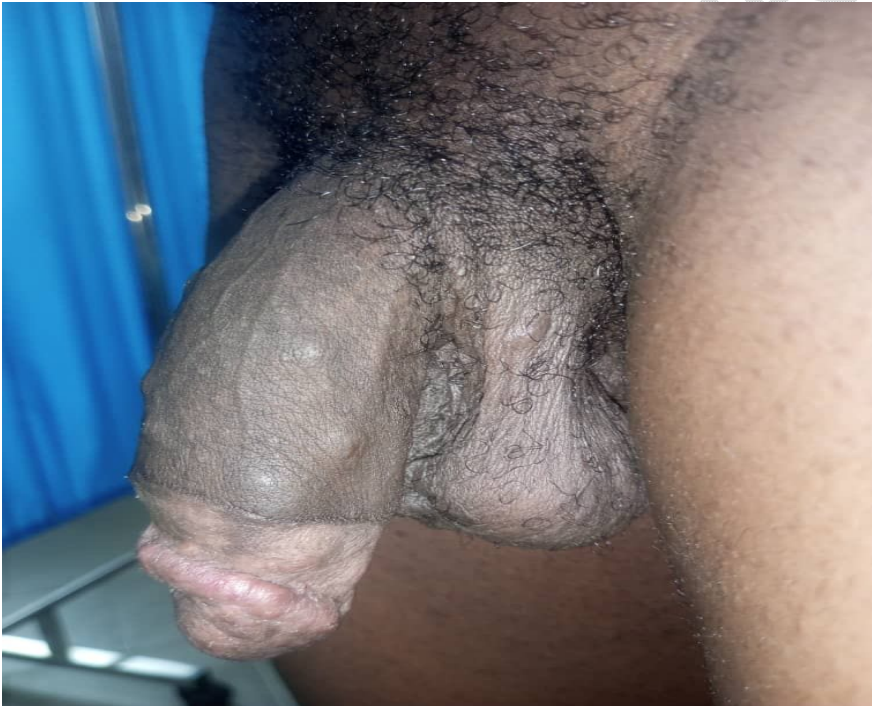

Figure 3: Image showing erythematous, nodular rash on the glans penis and the penile shaft



Figure 4: Image showing resolving nodular rash on the phallus and scrotum a week after treatment

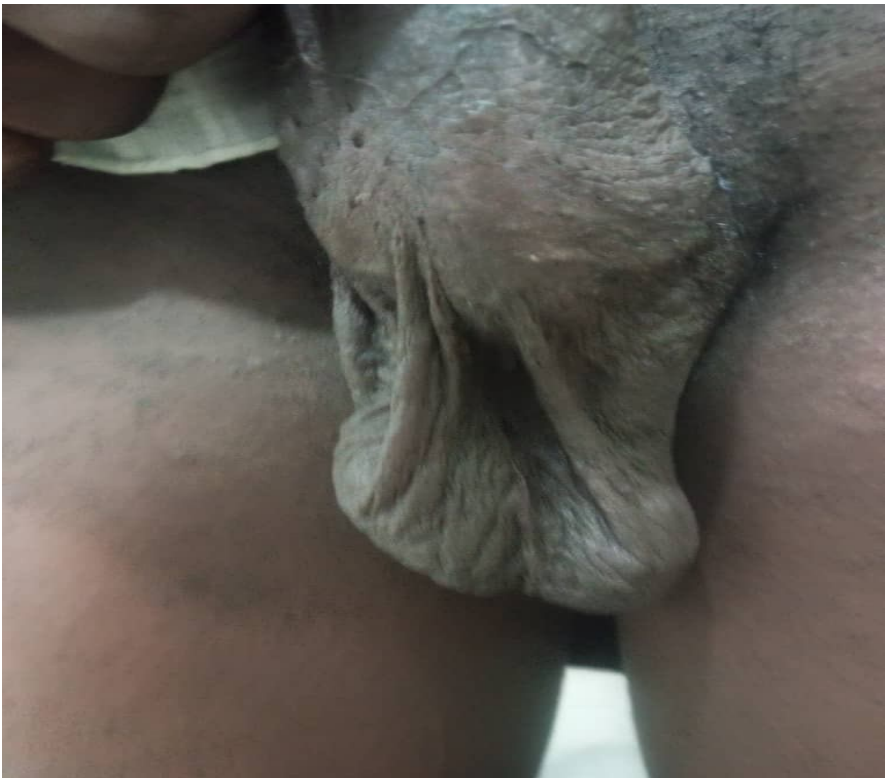

Figure 5: Image showing resolving nodular rash on the scrotum a week after treatment

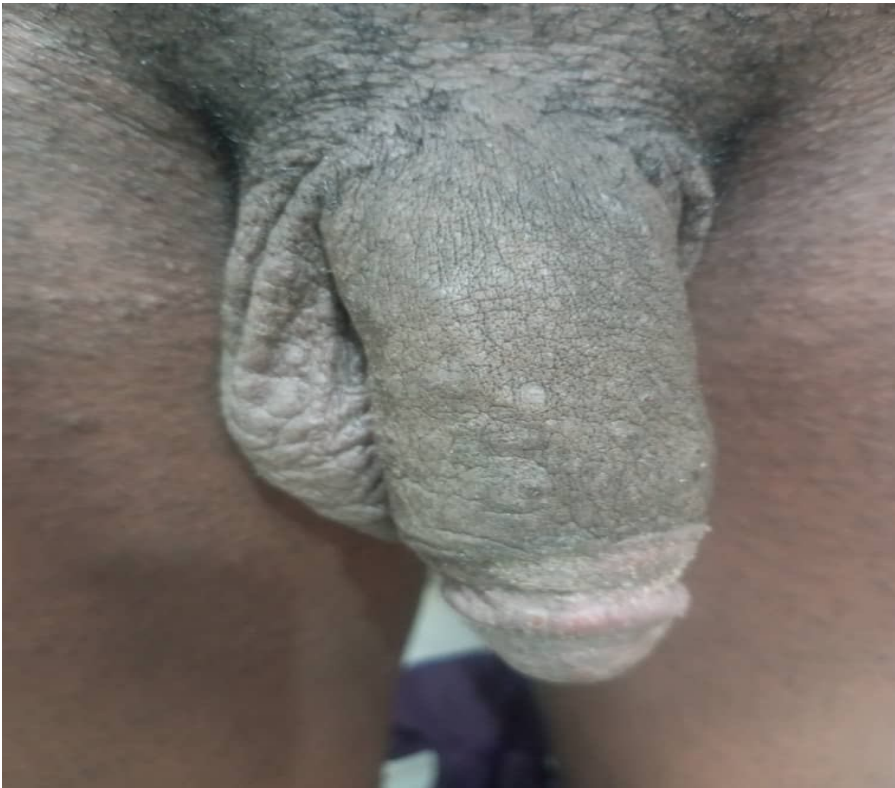


Figure 6: Image showing resolving nodular rash on the phallus and scrotum a week after treatment

3. DISCUSSION

Scabies remains a neglected tropical disease of poverty, despite the number of cases reported annually globally with many more individuals being at risk [1]. The diagnosis of genital nodular scabies in this man was made clinically based on the presence of a pruritic, erythematous, firm, nodular rash on the genitalia [4,7,8]. Risk factors identified included infrequent change of underpants, sharing of underpants and towels as well as living in a hostel [1]. Definitive diagnosis of the less common forms of scabies requires a high index of suspicion during examination supplemented by skin biopsies, scrapings or dermatoscopic intradermal skin testing [9]. However in many resource limited countries including Nigeria, clinical diagnosis is the main method of ascertaining the disease [1]. The case illustrated in this report is an uncommon variant of scabies as the lesions started from the penis and resulted in a firm, erythematous, nodular rash involving mainly the glans penis hence the diagnosis of genital nodular scabies [11]. The skin lesions observed in scabies resemble a wide variety of dermatological disorders therefore it should be routinely included in the differential diagnosis of pruritic rashes especially in individuals in endemic countries [5]. However, the typical lesions seen in scabies are pruritic, papules, vesicles and pustules (due to superimposed bacterial infection) with scales, crusts and excoriations. Nodular lesions may be observed in about 7% of scabies cases with the genitals, groin and axilla being commonly affected [4,13]. There are limited reports of nodular scabies globally [4,6–8,13,14]. The sites involved were the genital, groin and back. There have been reports of genital involvement in Nigeria [15,16] with few reports of the nodular variant [9,14]. Many reports on scabies in Nigeria focused on other characteristics of scabies rather than type/variant, thereby limiting the available information on the modes of presentation in this environment [15–17].

In this study, genital nodular scabies was defined as the presence of one or more typical scabies lesions (nodules or pustules) for more than two weeks, with associated pruritus worse at night, with or without a positive history of contact with an infected person [9]. The identified risk factor was infrequent change of underpants and sharing of towels. The diagnosis was based on the clinical judgment of the physicians as skin biopsy, scraping or dermatoscopy was not carried out. Clinical diagnosis is the main method of diagnosis in many developing countries and it relies on the clinical features, anatomical distribution as well as the presence of burrows [1]. However, burrows were not identified in this patient. Some studies have also considered nodular scabies, a hypersensitivity reaction to the mite antigens [6,8,14].

A secondary bacterial infection was observed in the index case. Secondary bacterial infection is a common occurrence due to the inoculation of microorganisms in abrasions which may occur during the frequent and often severe itching associated with the condition. This is common in individuals in the tropics resulting in pustular lesions [1,6,10]. The organisms implicated are usually *Staphylococcus aureus* and *Streptococcus pyogenes* [1]. The treatment of choice for scabies, topical permethrin (5%) is not readily available in pharmacies in this locality hence the prescription of benzyl

benzoate (25%). However, this therapy used in many developing countries including Nigeria [1,9,10] was unavailable in the pharmacy. The patient was treated with oral ivermectin, the only available option.

Compared to the alternatives for treatment, ivermectin has limited toxicity, and better compliance and it has also been reported to be more effective in the treatment of scabies [1]. However, this is not licensed for the treatment of scabies in Nigeria [1,5]. Some literature have recommended oral ivermectin or topical permethrin (5%) as the treatment of choice for the nodular variant of scabies [4]. A few studies in Nigeria have also reported successful treatment of scabies with oral ivermectin [18,19]. However, it is important to apply caution during therapy with oral ivermectin due to the fear of toxic encephalopathy which has been reported with its use in treating onchocerciasis and filariasis, both endemic in Nigeria[9]. Due to the highly infectious nature of the disease, It is essential to treat all close contacts, such as household contacts and sexual partners to prevent re-infestation and limit its spread to community [1,6,20]. However, in this case, the contact did not present at the clinic. In this patient, the nodules resolved shortly after treatment. However, it has been reported that the penile nodules may persist for months after successful treatment due to immunologic reaction to the presence of the mite antigens and may require intra-lesional injection of diluted triamcinolone (a steroid) for its resolution [21].

The case also shows a need for increased education on hygiene, especially for men with messages and interventions emphasizing the importance of personal hygiene. Furthermore, there also seems to exist the need to reiterate the importance of the frequent changing of underwear and avoidance of sharing of personal clothing.

4. CONCLUSION

Genital nodular scabies is an uncommon variant of scabies which should always be considered as a differential diagnosis of pruritic nodular rashes on the genitals in individuals living in endemic countries. More awareness about this manifestation of scabies is needed so that healthcare providers can recognize it and institute appropriate therapy.

CONSENT (WHEREEVER APPLICABLE)

Informed consent was obtained from the participant.

ETHICAL APPROVAL (WHEREEVER APPLICABLE)

Ethical approval was not applicable as this case was encountered during normal clinical practice. All identifiers have been completely removed from this article

DISCLAIMER (ARTIFICIAL INTELLIGENCE)

The Authors hereby declare that NO generative AI technologies such as Large Language Models (ChatGPT, COPILOT, etc.) and text-to-image generators have been used during the writing or editing of this manuscript.

REFERENCES

1. Hay R, Steer A, Engelman D, Walton S. Scabies in the developing world- its prevalence, complications and management. Clin Microbiol Infect 2012;18:313–23.
2. Micali G, Lacarrubba F, Verzi A, Chsidow O, Schwartz RA. Scabies: Advances in Noninvasive Diagnosis. PLoS Negl Trop Dis 2016;10:e0004691.
3. Sánchez-Borges M, González-Aveledo L, Capriles-Hulett A, Caballero-Fonseca F. Scabies, crusted (Norwegian) scabies and the diagnosis of mite sensitisation. Allergol Immunopathol (Madr) 2018;46:276–80.
4. Tai DBG, Saleh OA, Miest R. Genital nodular scabies. IDCases 2020;22:e00947.

5. Cassell JA, Middleton J, Nalabanda A, Lanza S, Head MG, Bostock J, et al. Scabies outbreaks in ten care homes for elderly people: a prospective study of clinical features, epidemiology, and treatment outcomes. *Lancet Infect Dis* 2018;18:894–902.
6. Gopinath H, Karthikeyan K. Genital scabies: Haven of an unwelcome guest. *Indian Journal of Sexually Transmitted Diseases and AIDS* 2020;41:10–6.
7. Suh KS, Han SH, Lee KH, Park JB, Jung SM, Kim ST, et al. Mites and burrows are frequently found in nodular scabies by dermoscopy and histopathology. *J Am. Acad. Dermatol.* 2014;71:1022–3.
8. Daye M, Temiz SA, Kılınc, F. A case of nodular scabies with atypical course. *Dermatologic therapy* 2020;33.
9. Oluwole TO, Ogunbiyi O, Fowotade A. A rare presentation of scabies balanitis. *Nigerian Journal of Parasitology* 2024;45:(In press).
10. Heukelbach J, Feldmeier H. Scabies. *The Lancet* 2006;367:1767–74.
11. Waugh MA. Balanitis. *Dermatologic clinics* 1998;16:757–62.
12. Thompson MJ, Engelman D, Gholam K, Fuller LC, Steer AC. Systematic review of the diagnosis of scabies in therapeutic trials. *Clin. Exp. Dermatol.* 2017;42:481–7.
13. Werbel T, Hinds BR, Cohen PR. Scabies presenting as cutaneous nodules or malar erythema: reports of patients with scabies surreptitious masquerading as prurigo nodularis or systemic lupus erythematosus. *Dermatol. Online J.* 2018;24.
14. Akolawole M, Ayosanmi OS, Akafa A, Njoku C, Adewuyi A, Alaga A. Genital Scabies with Granulomatous Dermatitis: A Case Report. *International Journal of Dermatology and Venereology* 2022;10.1097/JD9.000000000000239.
15. Okpala C, Ezejiofor O, Anaje C, Enechukwu N, Echezona DF, Umenzekwe C. Clinical Profile of Scabies: A Cross-Sectional Study in a Southeastern Nigerian Hospital. *Tropical Journal of Medical Research* 2023;22:173–9.
16. Emeka NK. Prevalence of scabies among secondary school students in Anambra State, Nigeria. *World J. Bio. Pharm. Health Sci.* 2021;8:001–7.
17. Ugbomoiko US, Oyediji SA, Babamale OA, Heukelbach J. Scabies in Resource-Poor Communities in Nasarawa State, Nigeria: Epidemiology, Clinical Features and Factors Associated with Infestation. *Trop. Med. Infect. Dis.* 2018;3:59.
18. Nnoruka EN, Agu CE. Successful treatment of scabies with oral ivermectin in Nigeria. *Trop Doct* 2001;31:15–8.
19. Sule HM, Thacher TD. Comparison of Ivermectin and Benzyl Benzoate Lotion for Scabies in Nigerian Patients. *Am J Trop Med Hyg.* 2007;76:392–5.
20. 10. Evidence and recommendations on scabies in Guidelines on the Treatment of Skin and Oral HIV-Associated Conditions in Children and Adults [Internet]. Geneva: World Health Organization; 2014 [cited 2019 Jun 11]. Available from: <https://www.ncbi.nlm.nih.gov/books/NBK305419/>
21. Alamalmi MAQ, Blada MBR. Balanitis due to bad hygiene in Yemeni Men's. *Journal of clinical case reports and clinical study* 2021;5.

UNDER PEER REVIEW