

Haematological and Histological Effects of Nanoplastics Released from Nonfood-grade Nonwoven Polyethene Bags on Mice

ABSTRACT

Nonfood-grade nonwoven polyethene (NFWP) bags which are frequently used in microwave cooking or carrying hot foods have been reported for releasing large amount of nanoplastics. Hence, the present study was designed to investigate the harmful effects of nanoplastics released from NFWP bags on mice. NFWP bags were cut into small pieces which were then boiled in water for 5 minutes. Then the boiled water was used as nanoplastic-contaminated drinking water for treated mice for 50 days. Surprisingly, the body weights and organ weight were increased remarkably for treated mice than control mice. The total Red Blood Cell (RBC) count decreased remarkably while total WBC count increased significantly in treated mice than incontrol. The percentage of neutrophils decreased remarkably while percentage of Monocytes increased significantly in treated mice as compared with control. The consumption of nanoplastics caused histological damage to intestine, heart, lung, kidney and liver of treated mice. The layers of intestinal muscles in the villi of treated mice were disrupted and infiltrated with foam cells. Destruction of alveoli and fibrosis was observed in the lungs of the treated mice. The heart muscles of treated mice were also disrupted and irregularly arranged with fibrosis. In the kidney of treated mouse, enhancement of renal spaces, shrinkage of glomeruli, eroded Bowman's capsule, deleted and congested glomeruli along with blood vessel were found. The liver of the treated mice was affected by apoptosis, fibrosis, vacuole formation in hepatocyte, congested in hepatic tissue and dilation of blood vessel. Therefore, it can be concluded that consumption of nanoplastics released from hot NFWP bags has serious deleterious effect on haematopoiesis and tissue integrity of different organs of Mice.

Keywords: Nanoplastics, Polyethene bag, Haematology, Histology, Mouse

1. INTRODUCTION

The widespread use of plastics has drastically changed our modern environment, making it primarily plastic-centric [1]. Plastics pollution is a major threat to world health [2]. While the entire effects of the pervasive plastic pollution are yet unknown, more focus is being placed on particles with sizes between 1 μm and 5 mm, and especially on nanoplastics. According to Gigault *et al.* (2018), nanoplastics are plastic particles that range in size from 1 to 1000 nm. Microplastics and nanoplastics are widely distributed throughout the environments by human activities resulting in emerging as the most notorious human-caused pollutants [3, 4]. However, nanoparticles pose a heightened risk compared to microplastics due to their capacity to traverse biological barriers [5]. Primary plastic waste and secondary byproducts are the two main causes of nanoplastic contamination [6]. Micromedicine, nanoimaging, nanosensors, and personal care products are some of the main sources of microplastics and nanoplastic emissions into the environment, with the emissions occurring at dimensions ranging from the microscale to the nanoscale [7]. Moreover, many other pollutants such as petroleum hydrocarbons, textile dye, industrial effluents can be degraded by microorganisms while plastics are very reluctant to microbial biodegradation causing their long-time existence in environment [8]. Hence, people are exposed to low quantities of nanoplastics for extended periods of time, often their whole lives, due to the widespread prevalence of plastic pollution [3]. Inhalation, ingestion, and skin contact are the three main ways that nanoplastics can enter the human body [9]. Food-grade polypropylene (PP) nonwoven bags have long been thought to be safe and non-hazardous for the environment. They are frequently used for filtering food residue. However, because of their tendency to leach plastic when in contact with hot water, microplastics and nanoplastics (MPs/NPs) have emerged, and their usage in culinary applications must be reevaluated. When food-grade nonwoven bags are boiled once, they can release 0.12 to 0.33 million microplastics ($>1 \mu\text{m}$) and 17.6 to 30.6 billion nanoplastics ($<1 \mu\text{m}$), or 2.25 to 6.47 mg in mass [10]. It has been reported that tens of thousands of MPs/NPs can be released when objects like tea bags and

disposable paper cups are exposed to hot water [11]. Even though, NFWP bags are widely used in everyday cooking operations in many countries like Bangladesh [12, 13].

It has been reported that the food-grade plastics, such as nonwoven bags, can emit a significant amount of microplastics and nanoplastics when heated [10]. The widespread use of NFWP bags raises concerns about potential health risks due to the release of nanoplastics. Moreover, microplastics and nanoplastics released from food-grade polythene bags may infiltrate into living organisms from their surroundings and build up in a few organs, such as the kidney, liver, heart, and lung [14, 15]. Hence, it has been hypothesized that non-food grade non-oven polythene (NFWP) bags might be more hazardous to animal health when these are used in microwaves cooking, and hot food processing and/or transportation. But information on the effect of nanoplastics released from NFWP bags on animal health is still inadequate. Hence, the present study was designed to investigate the harmful effects of nanoplastics released from NFWP bags on blood counts and histology of different organs *viz.* intestine, liver, heart, lung, and kidney in mice model.

2. MATERIALS AND METHODS

2.1 Collection of Polythene

Non-food grade non-oven polythene (NFWP) bags used in this study were collected from the neighborhood market located in Kazla, Rajshahi, Bangladesh.

2.2 Mice Rearing and Feeding

A total of six sexually mature female albino mice *Mus musculus* L. weighing 25-30g were collected from local market of Rajshahi. Then these mice, three for control and another three for treatment, were reared in two separate cages (20×14.50×15.50 inch) with saw dust bedding in the laboratory under constant temperature (33± 40C) for 50 days. The rearing cages were labeled accordingly as control cage and treatment cage. Poultry feed which was available in the local market was used to feed for both the mice. Collected NFWP bags were cut into small pieces, then these pieces were boiled for 5 minutes in mineral water in a microwave oven followed by

cooling into room temperature and filtration with a stainless-steel sieve to prepare nanoplastics contaminated water. Control mice were reared with normal drinking water while treated mice were reared with nanoplastics contaminated water. The weight of all studied mice was measured at the Day 0 and the Day 50.

2.3 Histological Examination

At day 50, both control and treated mice were sacrificed and then dissected for organs collection for histological studies of the tissues of heart, liver, lung, intestine, and kidney. Then, the weight of dissected organs was measured with electronic balance. The histological slides of those tissues were prepared and examined under light microscope as described previously [16]. Briefly, the dissected tissues were immediately fixed in 10% bouin's fluid and washed in distilled water, dehydrated in graded ethanol series (30%, 50%, 70%, 85% and 100%), infiltrated with xylene and embedded in paraffin wax at 56-60 °C. The tissues embedded in paraffin wax were sectioned using a rotator microtome machine, then the sections (5 µm) were placed on glass slides and treated with xylene to remove paraffin and subsequently washed in 90%, 70%, 50% and 30% alcohol. Finally, paraffin-free sections were washed with distilled water, stained with haematoxylin for 3 min and washed in running tap water for 1 min. Finally, the tissues were stained in eosin for 45 Sec., examined under microscope (Labomed, California) and photographed. Finally, histopathological changes in the studied organs of treated mice were recorded and compared with those of control mice.




Fig. 1. Different organs removed from sacrificed mice.

2.4 Hematological Test

For count of WBC and RBC, the blood was collected from tail vein of control and treated mice at the Day 0 and the Day 50. For the total count of WBC and RBC, blood was diluted with WBC and RBC diluting fluid respectively (Himedia, USA) and then diluted blood was placed on haemocytometer and the number of blood cell was counted under light microscope and calculated the blood cell number per cumm according to protocol of reagent manufacturer (Himedia, USA). For differential count the collected blood was used to prepare a blood film on slide which was air dried rapidly. Then, freshly prepared, and rapidly air-dried blood film was covered with Leishman's Stain (Himedia S018, USA) and allowed to act for 1 minute. Methanol in Leishman's Stain fixed the preparation. Then, double the volume of Leishman's Stain on the slide by adding distilled water with a dropper and mixing slowly. The diluted stain was allowed to act for 10-12 minutes. After that, the film was washed with distilled water or phosphate buffer of pH 7.0, then drained and dried in air. Finally, blood film was examined under microscope by using oil immersion lens.

2.5 Statistical Analysis

Unless indicated otherwise, all experiments were independently conducted at least in three control mice and three treated mice, and data were pooled for presentation as mean \pm SEM. All data were analyzed with Prism software (GraphPad, La Jolla, CA, USA) using two-tailed unpaired Student's *t*-tests. *P*-values <0.05 were considered significant.

3. RESULTS AND DISCUSSION

3.1 Evaluation of Morphological Effects in Control and Treated Mice.

The result indicated that, in comparison to the control mouse, the treated mouse's body weight was increased considerably (Fig. 2). The body weight of three control mice were 27.4 g, 29.7 g, and 26.5 g at the Day 0 which were comparable to the body weights of three treated mice *viz.* 28.4 g, 26.2 g, and 30.3 g on the Day 0 (Fig. 2). In contrast, the body weights of three control mice were 32.4 g, 31.5 g, and 35.1 g respectively on the Day 50 while body weights of treated mice were 39.9 g, 38 g, and 41 g respectively on the Day 50 indicating the significant effect of nanoplastics consumption on body weight of mice (Fig. 2).

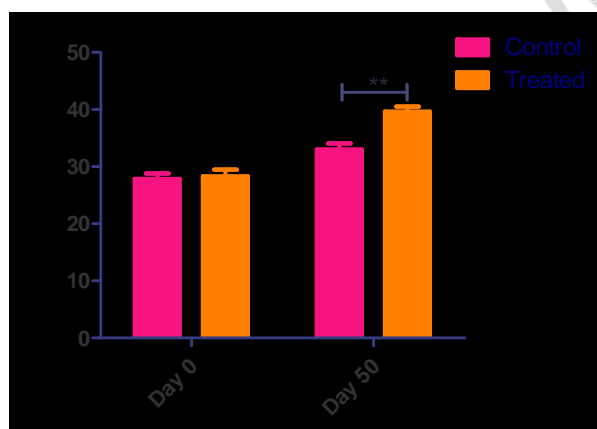


Fig. 2. Effect of nanoplastic on body weight of mice

On the day 50 the control and treated mice were sacrificed. Then, the organs such as lung, heart, kidney, liver were removed from the body and the weight (gm) of the organs was measured. It was found that the weight of the organs was significantly higher in a treated mouse than a control mouse (Fig. 3). Moreover, the organs weight was normalized to body weight to confirm that the higher weight of organs of treated mice had not directly resulted from the increase of their body weight. Similarly, we found a significant increase of weight of all studied organs except lung (Fig. 3).

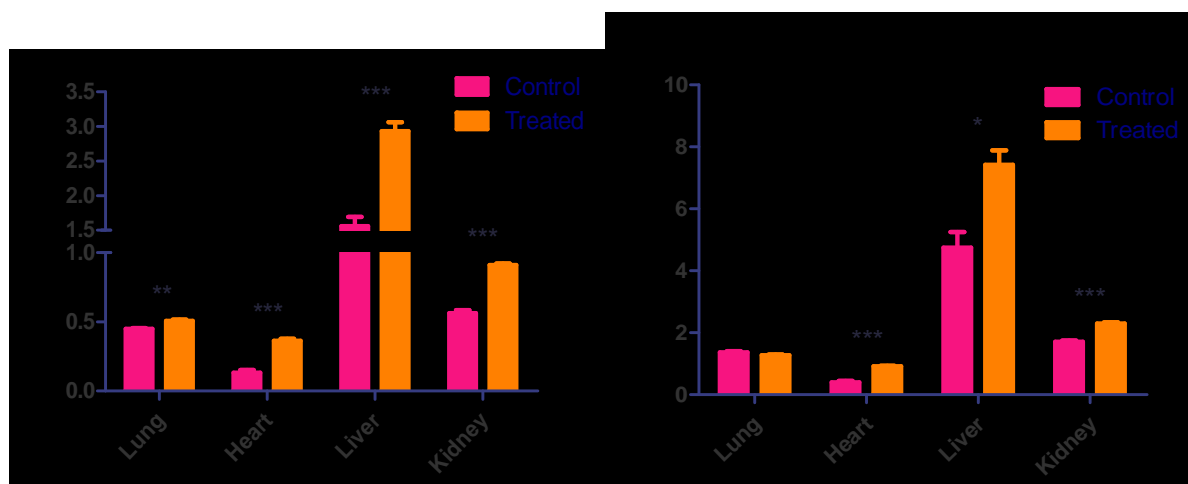


Fig. 3. Effect of nanoplastic on weight of different organs of mice.

Thus, the present study revealed that drinking of nanoplastic contaminated water caused weight gain of the mice significantly as compared with the mice reared with normal drinking water. Similarly, there was a noticeable increase in the weight of heart, liver and kidney of the treated mice than the control mice. As reported by other studies, the weight gain of the treated mice might be resulted from chronic inflammation related metabolic syndrome caused by deposition of nanoplastics in different organs [17].

3.2 Evaluation of Hematological Effects in Controlled and Treated Mice.

The total counts of RBC and WBC, and differential counts of WBC were assessed on the Day 0 and on the Day 50. The results of the hematological investigation demonstrated that there was no appreciable variation in the total counts of RBC and WBC between Days 0 and 50 for mice. In contrary, the total count of RBC decreased remarkably while the total count of WBC increased significantly in treated mice as compared with those of control mice (Fig. 4 and 5) indicating the adverse effects of nanoplastics on hematology. Decline of RBC in the treated mice might be resulted from increased rate of hemolysis and genotoxicity induced by nanoplastics infiltration [18]. Contrary, increase of total number of WBC in treated mice might be related to chronic inflammation [18].

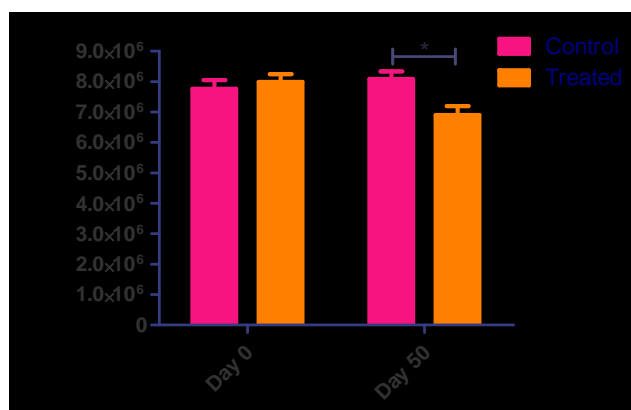


Fig. 4. Total counts of red blood cells in controlled and treated mice.

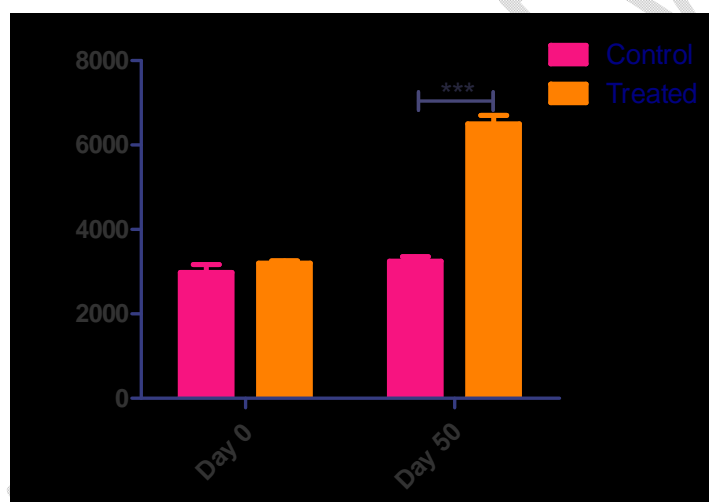


Fig. 5. Total counts of white blood cells in controlled and treated mice.

For differential count of WBC in control and treated mice, the stained blood film was observed under complex microscope in order to identify the different types of white blood cells viz. Neutrophil, Lymphocyte, Eosinophil, Basophil and monocyte. It was observed that Neutrophil had a multi-lobed nucleus while Eosinophil had bi-lobed nucleus. Grey blue coloured segmented nucleus is seen in mature monocyte while lymphocyte had round purple nucleus. Basophils were largest in size and had many cytoplasmic blue granules (Fig. 6).




Fig. 6. Representative images of different types of White Blood Cells (WBC) observed under light microscope for differential count of WBC in control and treated mice.

According to the results of the differential count of white blood cells in control mice, the percentage of neutrophils (53.33 ± 3.51) was the highest, followed by lymphocytes (20.66 ± 1.52), basophils (9.33 ± 1.52), monocytes (11.66 ± 1.52) and eosinophils (about 5.00 ± 2.00) on Day 0 (the first day of treatment) (Fig. 7). The proportion of various WBC counts between Day 0 and Day 50 did not significantly change (it varied by just 2-3%), indicating that the control mice were in good health after being raised in the lab. Every mouse displayed comparable outcomes.

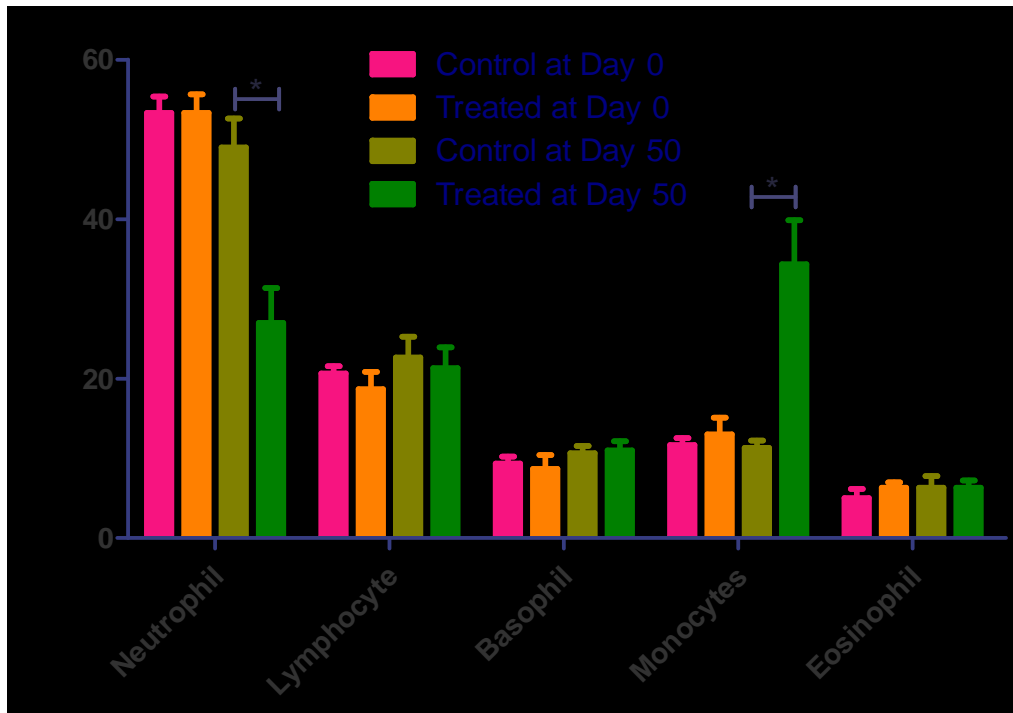


Fig. 7. Differential counts of white blood cells in controlled and treated mice.

The differential count of WBC in the treated mice showed that the highest proportion of WBC at Day 0 was found in neutrophils (53.33 ± 4.04), lymphocytes (18.66 ± 3.78), and monocytes (13.00 ± 3.60). On the other hand, on the Day 50, there was a sharp rise in the percentage of monocytes (34.33 ± 9.60) and lymphocytes (21.33 ± 4.50) in the treated mice (Fig. 7). On the other hand, the percentage of neutrophils (27.00 ± 7.54) dropped down significantly in the treated mice. Altogether, the count of Neutrophil and Monocyte was significantly affected by the consumption of nanoplastics released from NFWP bags (Fig. 7).

Neutrophils and Monocytes are phagocytic cells. Neutrophils make up more than half of all leukocytes in the bloodstream of healthy individuals. The results of differential count of WBC has been supported by other studies reporting that nanoplastics are phagocytosed by Neutrophils and induce their degranulation [19]. Moreover, the number of Monocyte can be modulated by nanoplastics induced cytokine production [20].

3.3 Evaluation of Histological Effect in Control and Treated Mice

The histological effect of consumption of nanoplastics on the heart, lung, kidney, liver, intestine of the mice was studied. The result revealed that consumption of nanoplastics disrupted the histological structure of different organs of mice. The histological slides of intestine of the Control mouse showed normal pattern of villi whereas significant changes have been observed in the intestine of treated mouse (Fig. 8). Tissues have been disrupted and infiltrated with foam cells (Fig. 8). Damages and disintegration of intestinal muscles, and infiltration with foam cells have been reported by Yanliang Wu (2023) and others for consumption of nanoplastics by different types of fishes and mammals [21]. In the case of control mouse, the histology of lung showed regular structure with veins. On the other hand, pathological features were observed in histology of the lung of treated mouse. It was found that the alveoli were disrupted in lung in treated mouse. Major fibrosis was also observed (Fig. 9). Destruction of alveoli and fibrosis was observed in the lungs of treated mice in this study which was also supported by other studies [22]. The histological slides of heart of the Control mouse showed a compact, well-organized heart muscle, proving that the mouse was healthy on the Day 50. On the contrary, heart muscles of treated mouse were disrupted and irregularly arranged with some pathological features. It was found that muscles became compact in some areas because of fibrosis (Fig. 10). Alteration cardiac muscles and myocardial inflammation resulted from nanoplastics pollution in different animals has been reported in many other studies [23]. Additionally, ingestion of nanoplastics affected the histological structure of kidney of mouse. The control mouse's kidney histology was regular in structure with renal tubules, Bowman's capsule, and glomerulus. However, these structures were altered in the treated mouse. In the kidney of treated mouse, enhancement of renal spaces, shrinkage of glomeruli, eroded Bowman's capsule, deleted and congested glomeruli along with blood vessel were found (Fig. 11). The liver of treated mice was affected by apoptosis, fibrosis, vacuole formation in hepatocyte, congested in hepatic tissue and dilation of blood vessel (Fig. 12). Similar effects of nanoplastics consumption on kidney and liver has been observed in human and other animals [24].




Fig. 8. Histological slide of Intestine. (a) control mouse, (b) treated mouse




Fig. 9. Histological slide of Lung. (a) control mouse, (b) treated mouse




Fig. 10. Histological slide of Heart. (a) control mouse, (b) treated mouse




Fig. 11. Histological slide of Kidney. (a) control mouse, (b) treated mouse




Fig. 12. Histological slide of Liver. (a) control mouse, (b) treated mouse

4. CONCLUSION

In summary, the consumption of nanoplastics caused an increase of body weights and organ weight of the mice. It also caused a decrease of RBC count and an increase of WBC count. The percentage of neutrophils declined while percentage of Monocytes increased by the consumption of nanoplastics. In addition, it also caused histological damage to the intestine, heart, lung, kidney and liver of treated mice. Taken together, it can be concluded that nanoplastics released from hot nonfood-grade nonwoven polyethylene bags can adversely affect total and differential count of RBC and WBC as well as morphology and histology of mice intestine, liver, heart, lung and kidney, leading to alterations of their body weight.

Ethical Approval

In compliance with the standard animal ethical guidelines, the present investigation was carried out at the Laboratory of Genetics and Molecular Biology, Department of Zoology, University of Rajshahi, Bangladesh.

Disclaimer (Artificial intelligence)

Authors hereby declare that NO generative AI technologies such as Large Language Models (ChatGPT, COPILOT, etc.) and text-to-image generators have been used during the writing or editing of this manuscript.

COMPETING INTERESTS

Authors have declared that no competing interests exist.

AUTHORS' CONTRIBUTIONS

This work was carried out in collaboration among all authors. Author MFH designed the study, wrote the protocols, performed the statistical analysis and finalized the manuscript. Author SIR wrote the first draft of the manuscript. Authors SIR, MSU, MNT, MA, SIT did the experimental works of the study. Authors MKM managed the literature searches. All authors read and approved the final manuscript.

REFERENCES

1. Comstock K, Farrell D, Godwin C and Xi Y. From hydrocarbons to carbohydrates: food packaging of the future. *Journal name* volume pages. 2004;
2. MacLeod M, Arp HPH, Tekman MB and Jahnke A. The global threat from plastic pollution. *Science*. 2021; 373(6550):61-65.
3. Gigault J, Ter Halle A, Baudrimont M, Pascal P-Y, Gauffre F, Phi T-L, El Hadri H, Grassl B and Reynaud S. Current opinion: what is a nanoplastic? *Environmental pollution*. 2018; 235(1030-1034).
4. Koelmans B, Pahl S, Backhaus T, Bessa F, van Calster G, Contzen N, Cronin R, Galloway T, Hart A and Henderson L, *A scientific perspective on microplastics in nature and society*. 2019: SAPEA.
5. Bouwmeester H, Hollman PC and Peters RJ. Potential health impact of environmentally released micro-and nanoplastics in the human food production chain: experiences from nanotoxicology. *Environmental science & technology*. 2015; 49(15):8932-8947.
6. Peng L, Fu D, Qi H, Lan CQ, Yu H and Ge C. Micro-and nano-plastics in marine environment: Source, distribution and threats—A review. *Science of the total environment*. 2020; 698(134254).
7. Wang F, Salvati A and Boya P. Lysosome-dependent cell death and deregulated autophagy induced by amine-modified polystyrene nanoparticles. *Open biology*. 2018; 8(4):170271.
8. Amran RH, Jamal MT, Pugazhendi A, Al-Harbi M, Ghandourah M, Al-Otaibi A and Haque MF. Biodegradation and Bioremediation of Petroleum Hydrocarbons in Marine Ecosystems by Microorganisms: A Review. *Nature Environment & Pollution Technology*. 2022; 21(3):
9. Rahman SMA, Saha AK, Ruhi RA, Haque MF and Mohanta MK. Decolourization of textile azo dye direct Red 81 by bacteria from textile industry effluent. *International Journal of Current Microbiology and Applied Sciences*. 2019; 8(4):1742-1754.
10. Saha AK, Sultana N, Mohanta MK, Mandal A and Haque F. Identification and characterization of azo dye decolourizing bacterial strains, *Alcaligenes faecalis* E5. Cd and A. *faecalis* Fal. 3 isolated from textile effluents. *American Scientific Research Journal for Engineering, Technology, and Sciences (ASRJETS)*. 2017; 31(1):163-175.
11. Nasrin T, Saha A, Mohanta M, Chaity A, Rahman S, Ruhi R, Sarker S and Haque M. Decolourization of azo dye by indigenous bacteria and its impact on seed germination. *Int. J. Biosci*. 2019; 14(197-210).
12. Nasrin T, Saha AK, Mohanta MK, Chaity AS, Alam MJ, Shawon MMH and Haque MF. Reduction of toxic effects of textile dye, basic red-18 on tilapia fish by bioremediation with a novel bacterium, *mangrovibacter yixingensis* strain AKS2 isolated from textile wastewater. *Annual Research & Review in Biology*. 2022; 37(11):12-29.
13. Ruhi RA, Saha AK, Rahman SMA, Mohanta MK, Sarker SR, Nasrin T and Haque MF. Decolourization of synthetic melanoidin by bacteria isolated from sugar mill effluent. *Univ. J. Zool. Rajshahi. Univ*. 2017; 36(12-21).
14. Nasrin T, Saha AK, Mohanta MK, Chaity AS, Alam MJ and Haque MF. Decolourization and detoxification of azo dye, malachite green by *Pseudomonas monteilii* Strain RZT1, a Bacterium Isolated from Textile Wastewater. *Annual Research & Review in Biology*. 2022; 37(12):1-16.
15. Jadaun JS, Bansal S, Sonthalia A, Rai AK and Singh SP. Biodegradation of plastics for sustainable environment. *Bioresource Technology*. 2022; 347(126697).
16. Rahman A, Sarkar A, Yadav OP, Achari G and Slobodnik J. Potential human health risks due to environmental exposure to nano-and microplastics and knowledge gaps: A scoping review. *Science of the Total Environment*. 2021; 757(143872).

17. Li J, Wang Q, Cui M, Yu S, Chen X and Wang J. Release characteristics and toxicity assessment of micro/nanoplastics from food-grade nonwoven bags. *Science of The Total Environment*. 2023; 883(163642).
18. Ranjan VP, Joseph A and Goel S. Microplastics and other harmful substances released from disposable paper cups into hot water. *Journal of Hazardous Materials*. 2021; 404(124118).
19. Hsieh S-L, Wu Y-C, Xu R-Q, Chen Y-T, Chen C-W, Singhania RR and Dong C-D. Effect of polyethylene microplastics on oxidative stress and histopathology damages in *Litopenaeus vannamei*. *Environmental pollution*. 2021; 288(117800).
20. Li Y, Shi T, Li X, Sun H, Xia X, Ji X, Zhang J, Liu M, Lin Y and Zhang R. Inhaled tire-wear microplastic particles induced pulmonary fibrotic injury via epithelial cytoskeleton rearrangement. *Environment International*. 2022; 164(107257).
21. Deji-Olorunboba O, Agidigbi TS and Jang M. Microplastics and Nano-plastics Contamination in Foods: Current Understanding of the Health Impact on Human and Potential Solutions. *European Journal of Nutrition & Food Safety*. 2024; 16(5):11-31.
22. Singh G, Thakur N and Kumar R. Nanoparticles in drinking water: Assessing health risks and regulatory challenges. *Science of The Total Environment*. 2024; 174940.
23. Haque MF, Shawon MMH, Alam MJ, Chaity AS, Mohanta MK, Saha AK and Nasrin T. Reduction of toxic effects of textile dye, basic red-18 on tilapia fish by bioremediation with a novel bacterium, *mangrovibacter yixingensis* strain AKS2 isolated from textile wastewater. *Annual Research & Review in Biology*. 2022; 37(11):12-29.
24. Mohanta MK, Hasi AS, Haque MF and Saha AK. Supplementation of Vitamin A and C can effectively recover the Histological and Haematological Alteration caused by Mosquito Coil Smoke and Aerosol in Mice Model. *Int. J. Curr. Microbiol. App. Sci*. 2019; 8(5):2223-2237.
25. Ćurčić M, Esteban J, Cakmak G, Durgo K, Baralić K, Živanović J, Marić D, Đorđević AB, Miljaković EA and Bulat Z. Environmental pollutants and the obesity: proven causalities and open questions. *Archives of Pharmacy*. 2024; 74(Notebook 3):426-435.
26. de Jesus Felismino C, Helal-Neto E, Portilho FL, Pinto SR, Sancenon F, Martinez-Manez R, de Assis Ferreira A, da Silva SV, Barja-Fidalgo TC and Santos-Oliveira R. Effect of obesity on biodistribution of nanoparticles. *Journal of controlled release*. 2018; 281(11-18).
27. Ballesteros S, Domenech J, Barguilla I, Cortés C, Marcos R and Hernández A. Genotoxic and immunomodulatory effects in human white blood cells after ex vivo exposure to polystyrene nanoplastics. *Environmental Science: Nano*. 2020; 7(11):3431-3446.
28. Arranz JA, Villacorta A, Rubio L, García-Rodríguez A, Sánchez G, Llorca M, Farre M, Ferrer J, Marcos R and Hernández A. Kinetics and toxicity of nanoplastics in ex vivo exposed human whole blood as a model to understand their impact on human health. *Science of the Total Environment*. 2024; 948(174725).
29. Sarma DK, Dubey R, Samarth RM, Shubham S, Chowdhury P, Kumawat M, Verma V, Tiwari RR and Kumar M. The biological effects of polystyrene nanoplastics on human peripheral blood lymphocytes. *Nanomaterials*. 2022; 12(10):1632.
30. Greven AC, Merk T, Karagöz F, Mohr K, Klapper M, Jovanović B and Palić D. Polycarbonate and polystyrene nanoplastic particles act as stressors to the innate immune system of fathead minnow (*Pimephales promelas*). *Environmental toxicology and chemistry*. 2016; 35(12):3093-3100.
31. Rajendran D and Chandrasekaran N. Journey of micronanoplastics with blood components. *RSC advances*. 2023; 13(45):31435-31459.

32. Weber A, Schwiebs A, Solhaug H, Stenvik J, Nilsen AM, Wagner M, Relja B and Radeke HH. Nanoplastics affect the inflammatory cytokine release by primary human monocytes and dendritic cells. *Environment international*. 2022; 163(107173).
33. Chen M, Yue Y, Bao X, Feng X, Ou Z, Qiu Y, Yang K, Yang Y, Yu Y and Yu H. Effects of polystyrene nanoplastics on oxidative stress, histopathology and intestinal microbiota in largemouth bass (*Micropterus salmoides*). *Aquaculture Reports*. 2022; 27(101423).
34. Gao D, Kong C, Liao H, Junaid M, Pan T, Chen X, Wang Q, Wang X and Wang J. Interactive effects of polystyrene nanoplastics and 6: 2 chlorinated polyfluorinated ether sulfonates on the histomorphology, oxidative stress and gut microbiota in Hainan Medaka (*Oryzias curvinotus*). *Science of The Total Environment*. 2023; 880(163307).
35. Chen G, Xiong S, Jing Q, van Gestel CA, van Straalen NM, Roelofs D, Sun L and Qiu H. Maternal exposure to polystyrene nanoparticles retarded fetal growth and triggered metabolic disorders of placenta and fetus in mice. *Science of The Total Environment*. 2023; 854(158666).
36. Wen S, Zhao Y, Wang M, Yuan H and Xu H. Micro (nano) plastics in food system: potential health impacts on human intestinal system. *Critical Reviews in Food Science and Nutrition*. 2024; 64(5):1429-1447.
37. Wu Y, Yao Y, Bai H, Shimizu K, Li R and Zhang C. Investigation of pulmonary toxicity evaluation on mice exposed to polystyrene nanoplastics: the potential protective role of the antioxidant N-acetylcysteine. *Science of the total environment*. 2023; 855(158851).
38. Jin YJ, Kim JE, Roh YJ, Song HJ, Seol A, Park J, Lim Y, Seo S and Hwang DY. Characterisation of changes in global genes expression in the lung of ICR mice in response to the inflammation and fibrosis induced by polystyrene nanoplastics inhalation. *Toxicological Research*. 2023; 39(4):575-599.
39. Yang S, Cheng Y, Chen Z, Liu T, Yin L, Pu Y and Liang G. In vitro evaluation of nanoplastics using human lung epithelial cells, microarray analysis and co-culture model. *Ecotoxicology and environmental safety*. 2021; 226(112837).
40. Gou D, Deng J-Y, Tang Q-P, Lu J, Bao L, Liu Y and Pei D-S. Elucidating the underlying toxic mechanisms of nanoplastics on zebrafish hematological and circulatory systems. *Environmental Science: Nano*. 2024;
41. Wu H, Guo J, Yao Y and Xu S. Polystyrene nanoplastics induced cardiomyocyte apoptosis and myocardial inflammation in carp by promoting ROS production. *Fish & Shellfish Immunology*. 2022; 125(1-8).
42. Lin P, Tong X, Xue F, Qianru C, Xinyu T, Zhe L, Zhikun B and Shu L. Polystyrene nanoplastics exacerbate lipopolysaccharide-induced myocardial fibrosis and autophagy in mice via ROS/TGF- β 1/Smad. *Toxicology*. 2022; 480(153338).
43. Lu G and Wei S. Nanoplastics trigger the aging and inflammation of porcine kidney cells. *Toxicology*. 2024; 506(153870).
44. Li Y, Li Y, Li J, Song Z, Zhang C and Guan B. Toxicity of polystyrene nanoplastics to human embryonic kidney cells and human normal liver cells: Effect of particle size and Pb²⁺ enrichment. *Chemosphere*. 2023; 328(138545).
45. Choi YJ, Park JW, Lim Y, Seo S and Hwang DY. In vivo impact assessment of orally administered polystyrene nanoplastics: biodistribution, toxicity, and inflammatory response in mice. *Nanotoxicology*. 2021; 15(9):1180-1198.
46. Yin J, Ju Y, Qian H, Wang J, Miao X, Zhu Y, Zhou L and Ye L. Nanoplastics and microplastics may be damaging our livers. *Toxics*. 2022; 10(10):586.

47. Meng X, Ge L, Zhang J, Xue J, Gonzalez-Gil G, Vrouwenvelder JS and Li Z. Systemic effects of nanoplastics on multi-organ at the environmentally relevant dose: The insights in physiological, histological, and oxidative damages. *Science of the Total Environment*. 2023; 892(164687).

UNDER PEER REVIEW